

Primary Failure of the Arteriovenous Fistula in Patients with Chronic Kidney Disease Stage 4/5

Nikola Gjorgjievski^{1*}, Pavlina Dzekova-Vidimljiski¹, Vesna Gerasimovska¹, Svetlana Pavleska-Kuzmanovska¹, Julija Gjorgjevska², Petar Dejanov¹, Aleksandar Sikole¹, Ninoslav Ivanovski³

¹University Hospital of Nephrology, Faculty of Medicine, Ss Cyril and Methodius University of Skopje, Skopje, Republic of Macedonia; ²University Children Hospital, Skopje, Republic of Macedonia; ³Zan Mitrev Clinic, Skopje, Republic of Macedonia

Abstract

Citation: Gjorgjievski N, Dzekova-Vidimljiski P, Gerasimovska V, Pavleska-Kuzmanovska S, Gjorgjevska J, Dejanov P, Sikole A, Ivanovski N. Primary Failure of The Arteriovenous Fistula in Patients with Chronic Kidney Disease Stage 4/5. Open Access Maced J Med Sci. <https://doi.org/10.3889/oamjms.2019.541>

Keywords: Primary failure; Arteriovenous fistula; Hemodialysis; Doppler ultrasound; Chronic kidney disease

***Correspondence:** Nikola Gjorgjievski, University Hospital of Nephrology, Skopje, Republic of Macedonia. E-mail: nikola_gjorgjievski@yahoo.com

Received: 23-Apr-2019; **Revised:** 18-May-2019; **Accepted:** 21-May-2019; **Online first:** 15-Jun-2019

Copyright: © 2019 Nikola Gjorgjievski, Pavlina Dzekova-Vidimljiski, Vesna Gerasimovska, Svetlana Pavleska-Kuzmanovska, Julija Gjorgjevska, Petar Dejanov, Aleksandar Sikole, Ninoslav Ivanovski. This is an open-access article distributed under the terms of the Creative Commons Attribution-NonCommercial 4.0 International License (CC BY-NC 4.0)

Funding: This research did not receive any financial support

Competing Interests: The authors have declared that no competing interests exist

Abbreviations: AVF: Arteriovenous fistula; HD: Hemodialysis; VA: Vascular access; CKD: Chronic kidney disease; TCC: Tunneled central venous catheters; AVG: Arteriovenous graft; DM: Diabetes mellitus; RRT: Renal replacement therapy; PD: Peritoneal dialysis; Tx: Transplantation; DOQI: Kidney Disease Outcomes Quality Initiative; GFR: Glomerular filtration rate; DOPPS: Dialysis Outcomes and Practice Patterns Study; SD: Standard deviation; ANOVA: Analysis of variance; POCUS: Preoperative point-of-care ultrasound; HBP: High blood pressure or Hypertension; ADPKD: Autosomal dominant polycystic kidney disease; ON: Obstructive nephropathy; GP: Glomerulopathy; OND: Unknown disease; ERA-EDTA: European renal association- European dialysis and transplant association

BACKGROUND: An Arteriovenous fistula (AVF) is a creation of the natural blood vessels. It is a "gate of life" for the patients on hemodialysis.

AIM: The study aimed to analyze the predictors for primary failure of AVF such as gender, age, number and location of AVF, and primary renal disease in patients with chronic kidney disease (CKD) stage 4/5.

MATERIAL AND METHODS: The medical records of 178 created arteriovenous fistulae in patients with CKD stage 4/5, were retrospectively studied. Primary failure of AVF was defined as thrombosis or inability for cannulation of AVF within 3 months. Adequate maturation of AVF was defined as successful cannulation of AVF treatment and blood flow of > 600 ml/min.

RESULTS: The mean age of the patients was 59.75 ± 14.65 years, and 65.16% (116/178) were men. Adequate maturation of AVF was achieved in 83.71% (149/178). Primary failure of AVF occurred in 16.29% (29/178) of the created fistulae, while 10.11% (18/178) had early thrombosis. The distal arteriovenous fistulae were significantly more frequently created in male patients (51 vs 18; p = 0.015). The female patients were significantly older than the male patients (63.27 vs 57.86 years; p = 0.018).

CONCLUSION: Male gender was associated with better maturation of AVF. The age, number and location of AVF, and primary renal disease in patients with CKD stage 4/5 were not associated with primary failure of AVF.

Introduction

Chronic kidney disease (CKD) is a condition of irreversible destruction of the renal parenchyma, with a continuous decline of kidney function [1]. The number of patients with CKD requiring renal replacement therapy (RRT) is increasing worldwide,

and it is the reason why we call CKD an international health problem [2]. Hemodialysis (HD) becomes the mainstay of treatment in patients with CKD requiring RRT, despite great medical and technological progress in transplantation (Tx) and peritoneal dialysis (PD). In our country in 2002 there were 1056 patients on RRT, most of them on HD 92%. In 2016 the number of patients on RRT increased to 1665. The

percentage on HD was 86% [3]. The data showed that the number of patients on RRT increased by 63.4 % and the number of patients on HD also increased by 67.4 % over the period between 2002 and 2016 (Figure 1).

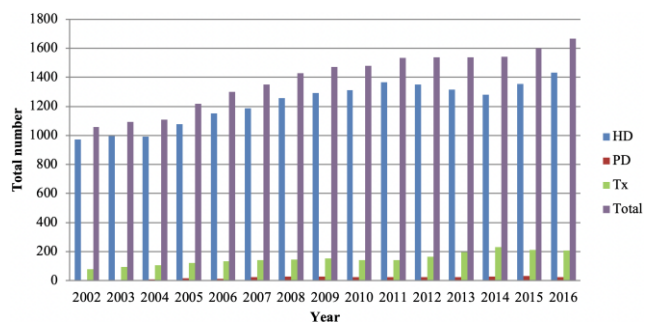


Figure 1: The number of patients with RRT per year for the Republic of Macedonia; *data from ERA-EDTA registry (annual reports); *unpublished registry data for 2012 and 2013 analyzed from national source; *HD (hemodialysis); *PD (peritoneal dialysis); *Tx (transplantation); *Total

An Arteriovenous fistula (AVF) is permanent vascular access (VA) for HD created from the native blood vessels. It is called “the gate of life” for the patients treated by HD because its survival is superior to any other permanent type of VA. The most common site for AVF creation is the forearm (radial-cephalic) fistula. The AVF could also be placed on the upper arm (brachial-cephalic) fistula.

The first AVF for HD was created by Brescia, Cimino and Appel in 1966 [4]. The creation of AVF ensures accessibility to HD as a chronic RRT. The Kidney Disease Outcomes Quality Initiative (KDOQI) guidelines recommended that the patients with glomerular filtration rate (GFR) less than 30 ml/min/1.73 m² (CKD stage 4/5) should be educated on all modalities of RRT [hemodialysis (HD), peritoneal dialysis (PD) and transplantation (Tx)], and an AVF should be placed at least 6 months before the anticipated start of HD treatment [5].

According to the Dialysis Outcomes and Practice Patterns Study (DOPPS) V study, in most DOPPS countries the prevalence of AVF is usually less than 80%, ranging from 49% in Canada up to 92% in Russia [6]. An “Arteriovenous fistula first” initiative is a strategy for the creation of permanent VA in patients on HD in our hospital. A total number of 4554 fistulae and 1016 tunnelled central venous catheters were created between 2002 and 2018. In the last 5 years, the percentage of created fistulae was more than 80%, out of all created permanent VA for HD (Figure 2).

The maintenance of adequate VA is crucial for patient survival on HD [7]. Thrombosis is the leading cause for primary failure of AVF. It is also the leading cause of permanent access loss. Access thrombosis accounts for 65% to 85% of cases of permanent access loss [8]. Early thrombosis occurs in 5% to 30% of all created fistulae within 24 hours [9].

Adequate AVF maturation occurs in 60% to 80% from all created fistulae. The insufficiency of VA reduces the efficiency of treatment and leads to reactivation of clinical uremic syndrome, which requires frequent hospitalisations and causes the death of patients.

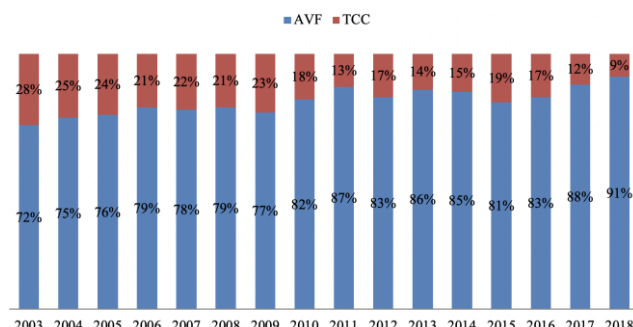


Figure 2: Distribution of permanent types of vascular access between 2002 and 2018 at the University Hospital of Nephrology, Skopje, Republic of Macedonia. *AVF – arteriovenous fistula; *TCC – tunnelled central venous catheters; *unpublished registry data for 2002 to 2018 analysed from a national source

The study aimed to analyse the predictors for primary failure of AVF such as gender, age, number and location of AVF, and primary renal disease in patients with CKD stage 4/5.

Material and Methods

The medical records of 178 created fistulae in patients with CKD stage 4/5, by one doctor in a single centre for the year 2018, were retrospectively studied. Preoperative Doppler ultrasound on the forearm was performed in all patients for assessment of the adequacy of blood vessels and to determine the site of AVF creation. A vein diameter > 2 mm and an artery diameter ≥ 1.6 mm on the forearm were considered adequate. The Doppler ultrasound (Mindray ® DC-T6 2010) was equipped with a linear probe with a minimum frequency of 7 MHz for B-mode examination, with setup for vascular access (Frequency Harmonic 10.0, Frame rate 47, Gain 69, Dynamic Range 70, Depth 3 cm). Calculation of the AVF blood flow by Doppler ultrasound used the formula (area x mean velocity x 60) (Figure 3), where area is the cross-sectional area of the vessel in square centimetres (since the vessel is cylindrical, its section is a circle whose area is calculated as the square of the radius $\pi = 3.14$) [10]. The examination by Doppler ultrasound was carried out in a comfortably warm room. The patients were seated in front of the doctor with the forearm resting on a stand, and the blood vessels were evaluated with transverse and longitudinal scans.

The creation of AVF was performed under local anaesthesia (2% Lidocaine-Xylocaine). A

longitudinal 3-4 cm skin incision was used, as this was found to give good access to both vein and artery. An end-to-side fistula was created between the cephalic vein and the radial or brachial artery, using continuous polypropylene sutures (6/0 Prolene) with the aid of 3.5x magnifying loupes (Figure 4). The length of anastomosis was 10 mm for (radio-cephalic) (Figure 5) and 5 mm for (brachial-cephalic) fistulae. A palpable date thrill was taken as an indicator for successful AVF creation. The primary failure of AVF was defined as thrombosis or inability for cannulation of fistula for HD within 3 months of creation. Early thrombosis of AVF was defined as an immediate failure due to thrombosis of the fistula within 24 hours of creation. Adequate maturation of AVF was defined as successful cannulation of AVF for efficient HD treatment and AVF blood flow of > 600 ml/min. The term maturation refers to the development of those physical characteristics that render an AVF suitable for venipuncture with large-gauge needles. Generally, the physical examination conducted by an experienced dialysis nurse is sufficiently reliable for determining whether the fistula is mature and therefore, ready for puncture [11], [12]. The problem arises when the AVF does not appear mature based on inspection alone, a situation that occurs with obese patients and with slow-maturing fistulae. In these cases, the ultrasound examination and assessment of hemodynamic parameters (AVF blood flow,) could help determine whether an AVF is suitable for cannulation or whether it has instead failed to mature and is therefore likely to undergo thrombosis or have a low flow volume. The ultrasound characteristics that confirm that an AVF is mature and, therefore, ready for use: a blood flow of > 600 ml/min, an outflow vein diameter of ≥ 6 mm, and an outflow vein depth of ≤ 6 mm below the skin surface [5]. Three different types of AVF were created: distal (radial-cephalic), middle-arm (radial-cephalic) and proximal (brachial-cephalic). The patients with created fistulae were grouped according to the aetiology of primary renal disease: diabetes mellitus (DM), high blood pressure or hypertension (HBP), autosomal dominant polycystic kidney disease (ADPKD), obstructive nephropathy (ON), glomerulopathy (GP) and unknown disease (UND).

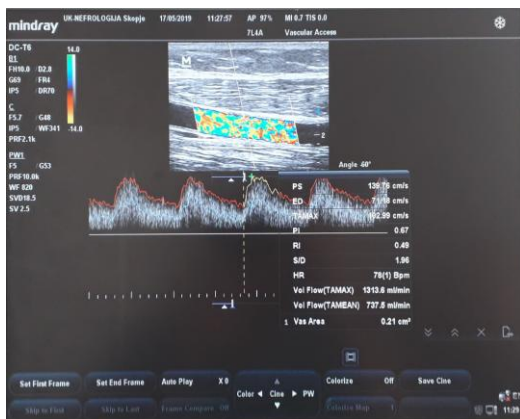


Figure 3: Blood flow of AVF after 28 days of creation

Statistical analysis was performed using the Statistic 8 software for Windows. Data from numerical variables were presented as mean values \pm standard deviation (SD). The means between the two groups were compared with a t-test. Analysis of variance (ANOVA) was used to test differences between two or more means.

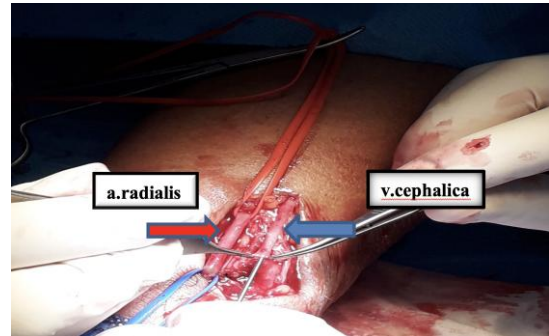


Figure 4: Location of a. radial and v. cephalic at the distal forearm site

A multiple logistic regression analysis was used to determine predictors of early thrombosis and primary failure of AVF in the study population. The p-value of less than 0.05 was considered statistically significant.

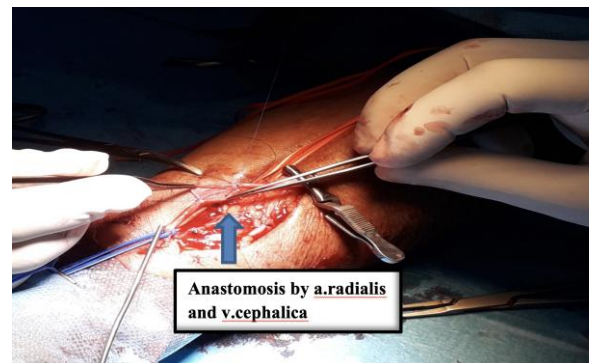


Figure 5: Creation of anastomosis by a. radial and v. cephalic at the distal forearm site

Results

The mean age of the patients was 59.75 ± 14.65 years, and 65.16% (116/178) were men. The female patients were significantly older than the male patients (63.27 vs 57.86 years; $p = 0.018$).

Adequate maturation of AVF was achieved in 83.71% (149/178). The primary failure occurred in 16.29% (29/178) of the created fistulae, while 10.11% (18/178) had early thrombosis.

The distal AVF (radio-cephalic) was the dominant site present with 38.76% (69/178) of all

created fistulae. Adequate maturation of distal AVF was achieved in 86.96% (60/69). Primary failure of AVF occurred in 13.04% (9/69), but early thrombosis of AVF occurred in 7.15% (5/69) (Figure 6).

The middle-arm AVF (radio-cephalic) was performed in 32.02% (57/178) of all created fistulae. Adequate maturation of middle-arm AVF was achieved in 77.19% (44/57). The primary failure occurred in 22.81% (13/57), while early thrombosis occurred in 15.79% (9/57) (Figure 6).

The proximal AVF (brachial-cephalic) was created in 29.22% (52/178) of all created fistulae. Adequate maturation of proximal AVF was achieved in 86.54% (45/52), primary failure occurred in 13.46% (7/52), out of which early thrombosis occurred in 7.69% (4/52) (Figure 6).

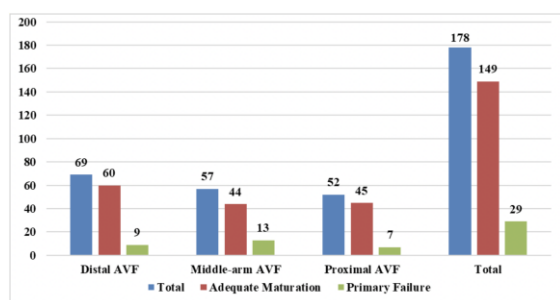


Figure 6: Primary outcome (adequate maturation and primary failure) of AVF in the three different locations on the forearm. *AVF – arteriovenous fistula

The distal fistulae were significantly more frequently created in men than in female patients (51 vs 18; $p = 0.015$). The mean number of previously created AVF was significantly higher in patients with middle-arm AVF than in patients with distal AVF (1.86 vs 1.24; $p = 0.003$). Also, the mean number of previously created AVF was significantly higher in patients with proximal AVF than in patients with distal AVF (3.19 vs 1.24; $p = 0.000$).

The distribution of the primary renal disease in patients with created fistulae was: diabetes mellitus (DM) in 29.21% (52/178), high blood pressure or hypertension (HBP) in 22.47% (40/178), autosomal dominant polycystic kidney disease (ADPKD) in 2.81% (5/178), obstructive nephropathy (ON) in 8.99% (16/178), glomerulopathy (GP) in 12.36% (22/178) and unknown disease (UND) in 24.16% (43/178). The patients with DM were significantly older than non-DM patients (63.27 vs 57.86 years; $p = 0.018$).

The multiple logistic regression analysis showed that age (OR = 1.1, 95%CI, 0.99-1.29, $p = 0.083$), number of AVF (OR = 0.92, 95%CI, 0.74-1.11, $p = 0.044$), location of AVF (OR = 1.0, 95%CI, 0.85-1.23, $p = 0.622$), and primary renal disease (OR = 1.0, 95%CI, 0.92-1.22, $p = 0.350$) in patients with CKD stage 4/5 were not associated with primary failure of AVF within 3 months.

Discussion

Successful creation and adequate maturation of AVF in patients with CKD stage 4/5 require a multidisciplinary approach in resolving the leading causes for primary failure. The process of AVF maturation is complex and remains poorly understood, despite numerous studies describing the pathophysiology of the process and biomechanical factors associated with maturation. The intimal hyperplasia (IH) has been identified as the main pathohistological change, which occurs in the blood vessels and was associated with the primary failure of AVF [13]. However, the creation of AVF is the first step for the patients who need a functional permanent VA for HD. Mc Lafferty et al., 2007 reported adequate AVF maturation of 82% and a primary failure rate of 18% in patients with AVF, enrolled in a comprehensive follow-up program [14]. In our study, adequate maturation was achieved in 83.71%, and primary failure occurred in 16.29% of the created fistulae.

A number of studies have focused on factors that predict a successful i.e. functional AVF [15], [16], [17], [18]. Bashar et al., 2015 reported 52 functionally matured fistula from a total of 97 fistulae (53.60%). In their study, the mean age of the patients was 60.9 ± 16.9 years, but the age was not significantly associated with the functionality of AVF. The female gender ($p = 0.004$), previous history of a kidney transplant ($p = 0.036$), patient on a calcium channel blocker at the time of AVF formation ($p = 0.01$) and lower haemoglobin levels were significantly associated with the functionality of AVF [19]. Also, Jemcov 2013 in her study reported that female gender was associated with prolonged AVF maturation (OR 0.35, 95% CI = 0.17-0.72; $p = 0.005$) and a significantly smaller size of a. radial (1.83 vs. 2.01 mm, $p = 0.01$) compared to the male gender [20]. Wasse et al., 2010 reported that females were 36% less likely than males to use an AVF at dialysis initiation [21]. The study by Miller et al., 2003 reported that fistula was more likely to be placed in the upper arm rather than in the forearm in women than in men (64% vs 36%) [22].

In our study, the distal fistulae were significantly more frequently created in male than in female patients (51 vs 18; $p = 0.015$). The diameter size of blood vessels in men was higher than in women. The number of previously created fistulae was significantly higher in patients with proximal AVF location (3.19 vs 1.24; $p = 0.000$) and middle-arm AVF site (1.86 vs 1.24; $p = 0.003$) compared to the patients with distal AVF site. The number and location of AVF were not significantly associated with the primary failure of AVF.

DM was the most common cause for CKD [23], but it was not associated with adverse outcome of fistula maturation during the first three months of its

creation, compared to the other primary renal diseases. The patients with DM were significantly older than the non-DM patients (63.27 vs 57.86 years; $p = 0.018$). The others etiologies of primary renal disease were also not significantly associated with primary failure of AVF. Sedlacek et al., 2001 reported that DM was not associated with adverse AVF maturation (67% matured in the diabetic group vs. 62% in non-diabetic group, chi-square = 0.27; $df = 1$; $p = 0.61$). The DM as a disease did not influence the prevalence of AVF creation in patients; 66% from the diabetic group underwent fistula placement compared to 60% from the non-diabetic group [24].

Specialists involved in the construction and maintenance of permanent VA for HD emphasise the crucial role of Doppler ultrasound for identifying blood vessels that are suitable for creation of AVF (preoperative mapping) and for early detection of complications (surveillance). One of the earliest studies was the work by Silva et al., 1998, who reported use of preoperative duplex imaging applied to forearm veins to identify usable sites for AVF construction [25]. Also, Hossain et al., 2018 reported that the primary failure rate in the ultrasound group was 18% compared with 47% ($P < 0.001$) in the group of patients who did not undergo ultrasound examination. In patients without preoperative ultrasound, there were higher rates of new access creation (31% vs 9%; $P < .001$) and fistula abandonment (66% vs 39%; $P < .001$). Multivariate analysis demonstrated that fistulae created without preoperative ultrasound were associated with a 3.56 greater risk of failure (95% confidence interval, 1.67-7.59; $P = 0.001$) compared to fistulae in the preoperative point-of-care ultrasound (POCUS) group [26]. Malovrh 1998 reported that the risk of AVF failure was increased when the internal diameter of the artery was ≤ 1.5 mm, with a success rate of 45%. His study demonstrated that duplex sonography, a non-invasive method, enabled sufficient investigation of the arteries before AVF construction [27].

Our strategy for the creation of AVF was “as many as possible” in the most distal location of the forearm, determined by preoperative doppler ultrasound. The diameter size of blood vessels analysed by preoperative Doppler ultrasound had a pivotal role in determining the location of AVF creation.

In conclusion, the hospital strategy for creating a permanent type of VA for HD was so-called “Arteriovenous fistula first”. A challenge was successful creation and adequate maturation of AVF in patients with CKD stage 4/5. The use of Doppler ultrasound had a crucial role in the creation and adequate AVF maturation. The distal forearm site dominated in the male gender, and it was in correlation with the diameter size of the blood vessels. The middle-arm AVF and the proximal AVF were more frequent sites in patients with multiple fistulae.

References

- Couser WG, Remuzzi G, Mendis S, Tonelli M. The contribution of chronic kidney disease to the global burden of major noncommunicable diseases. *Kidney international*. 2011; 80(12):1258-70. <https://doi.org/10.1038/ki.2011.368> PMID:21993585
- Jha V, Garcia-Garcia G, Iseki K, et al. Chronic kidney disease: global dimension and perspectives. *Lancet*. 2013; 382(9888):260-272. [https://doi.org/10.1016/S0140-6736\(13\)60687-X](https://doi.org/10.1016/S0140-6736(13)60687-X)
- Gjorgjievski N, Stojanoska A, Smokovska A, Dejanov P and Spasovski G. Challenges Facing the Improvement of Kidney Transplantation - Issues in a Developing Country, Republic of Macedonia. *Bantao*. 2018; 16(1):1-4.
- Brescia MJ, Cimino JE, Appel K, Hurwich BJ. Chronic hemodialysis using venipuncture and a surgically created arteriovenous fistula. *N Engl J Med*. 1966; 275(20):1089-92. <https://doi.org/10.1056/NEJM196611172752002> PMID:5923023
- National Kidney Foundation. KDOQI clinical practice guidelines and clinical practice recommendations for vascular access. *Am J Kidney Dis*. 2006; 48 suppl 1:S176-S322. <https://doi.org/10.1053/j.ajkd.2006.04.029> PMID:16813989
- Pisoni RL, Zepel L, Port FK, Robinosn BM. Trends in US vascular access use, patients preferences, and related practices: an update from US DOPPS practice monitor with international comparisons. *Am J Kidney Dis*. 2015; 65(6):905-915. <https://doi.org/10.1053/j.ajkd.2014.12.014> PMID:25662834
- Strategy for access creation Guidelines, EDTA. https://www.vascularaccesssociety.com/guidelines_edta
- Quencer KB, Friedman T. Dec clotting the Thrombosed Access. *Tech Vasc Interv Radiol*. 2017; 20:38-47. <https://doi.org/10.1053/j.tvir.2016.11.007> PMID:28279408
- Rooijens PPGM, Tordoir JHM, Stijnen T, Burgmans JPJ, Smet de AAEA, Yo TI. Radiocephalic wrist arteriovenous fistula for hemodialysis: meta-analysis indicates a high primary failure rate. *Fistulae for hemodialysis. Eur J Vasc Endovasc Surg*. 2004; 28:571-680. <https://doi.org/10.1016/j.ejvs.2004.08.014> PMID:15531191
- Wiese P, Nonnast-Daniel B. Colour Doppler ultrasound in dialysis access. *Nephrol Dial Transpl*. 2004; 19:1956-1963. <https://doi.org/10.1093/ndt/gfh244> PMID:15199165
- Malovrh M. The role of sonography in the planning of arteriovenous fistulas for hemodialysis. *Semin Dial*. 2003; 16:299-303. <https://doi.org/10.1046/j.1525-139X.2003.16069.x> PMID:12839503
- Davidson I, Chan D, Dolmatch B, Hasan M, Nichols D, Saxena R et al. Duplex ultrasound evaluation for dialysis access selection and maintenance: a practical guide. *J Vasc Access*. 2008; 9:1-9. <https://doi.org/10.1177/112972980800900101> PMID:18379973
- Pushevski V, Dejanov P, Gerasimovska V, Petrushevska G, Oncevski A, Sikole A, Popov Z, Ivanovski N. Severe endothelial damage in chronic kidney disease patients prior to haemodialysis vascular access surgery. *Prilozi*. 2015; 36(3):43-9. <https://doi.org/10.1515/prilozi-2015-0077> PMID:27442395
- McLafferty RB, Pryor RW, Johnson CM, Ramsey DE, Hodgson KJ. Outcome of a comprehensive follow-up program to enhance maturation of autogenous arteriovenous hemodialysis access. *J Vasc Surg*. 2007; 45(5):981-5. <https://doi.org/10.1016/j.jvs.2007.01.013> PMID:17466790
- Okamoto L, Gray K, Korn A, Parrish A, Kaji A, Howell EC, Bowers N, de Virgilio C. Careful Patient Selection Achieves High Radiocephalic Arteriovenous Fistula Patency in Diabetic and Female Patients. *Annals of vascular surgery*. 2019. <https://doi.org/10.1016/j.avsg.2018.12.057> PMID:30684628
- Allon M, Litovsky L, Young CJ, Deierhoi MH, Goodman J, Hanaway M et al. Medial fibrosis, vascular calcification, intimal hyperplasia, and arteriovenous fistula maturation. *Am J Kidney Dis*.

- 2011; 58:437-443. <https://doi.org/10.1053/j.ajkd.2011.04.018> PMID:21719173 PMCID:PMC3159759
17. Lee T, Ullah A, Allon M, Succop P, El-Khatib M, Munda R et al. Decreased cumulative access survival in arteriovenous fistulas requiring interventions to promote maturation. *Clin J Am Soc Nephrol*. 2011; 6:575-581. <https://doi.org/10.2215/CJN.06630810> PMID:21088288 PMCID:PMC3082416
18. Khavanin Z.M, Gholipour F, Naderpour Z, Porfakharan M. Relationship between Vessel Diameter and Time to Maturation of Arteriovenous Fistula for Hemodialysis Access. *Int J Nephrol*. 2012; 2012. <https://doi.org/10.1155/2012/942950> PMID:22187645 PMCID:PMC3236464
19. Bashar K, Zafar A, Elsheikh S, Healy DA, Clarke-Moloney M, Casserly L, Burke PE, Kavanagh EG, Walsh SR. Predictive Parameters of Arteriovenous Fistula Functional Maturation in a Population of Patients with End-Stage Renal Disease. *PLoS One*. 2015; 10(3):e0119958. <https://doi.org/10.1371/journal.pone.0119958> PMID:25768440 PMCID:PMC4358953
20. Jemcov TK. Morphological and functional vessels characteristic by assessed by ultrasonography for prediction of arteriovenous fistula maturation. *J Vasc Access*. 2013; 14(4):356-63. <https://doi.org/10.5301/jva.5000163> PMID:23817950
21. Wasse H, Hopson DS, McClellan W. Racial and Gender Differences in Arteriovenous Fistula Use among Incident Hemodialysis Patients. *Am J Nephrol*. 2010; 32(3):234-241. <https://doi.org/10.1159/000318152> PMID:20664254 PMCID:PMC2980520
22. Miller CD, Robbin ML, Allon M. Gender differences in outcomes of arteriovenous fistulas in hemodialysis patients. *Kidney international*. 2003; 63(1):346-52. <https://doi.org/10.1046/j.1523-1755.2003.00740.x> PMID:12472802
23. Polenakovic M, Sikole A, Nikolov IG, Georgiev D, Selim G, Dzekova-Vidimliski P, Gelev S, Amitov V, Onceviski A, Severova G, Pavleska S, Poposki A, Kovaceska V, Alceva M, Zdravkovska V, Antarov R, Dimitrov S, Janakievska P, Damjanovski M, Karceva Sarajlija E, Velinova B, Ivanovski K, Panova B, Neskovski J, Jovceviski D, Zafirovska M, Mat R, Filipovik R, Sela L, Lamova K. Diabetics on dialysis in the Republic of Macedonia: A nationwide epidemiological study. *Prilozi*. 2010; 31(1):261-77.
24. Sedlacek M, Teodorescu V, Falk A, Vassalotti JA, Uribarri J. Hemodialysis access placement with preoperative noninvasive vascular mapping: comparison between patients with and without diabetes. *Am J Kidney Dis*. 2001; 38:560-564. <https://doi.org/10.1053/ajkd.2001.26873> PMID:11532689
25. Silva MB, Hobson RW, Pappas PJ, Jamil Z, Araki CT, Goldberg MC, Gwertzman G, Padberg FT. A strategy for increasing use of autogenous hemodialysis access procedures: impact of preoperative noninvasive evaluation. *J Vasc Surg*. 1998; 27(2):302-7. [https://doi.org/10.1016/S0741-5214\(98\)70360-X](https://doi.org/10.1016/S0741-5214(98)70360-X)
26. Hossain S, Sharma A, Dubois L, DeRose G, Duncan A, Power AH. Preoperative point-of-care ultrasound and its impact on arteriovenous fistula maturation outcomes. *J Vasc Surg*. 2018; 68(4):1157-1165. <https://doi.org/10.1016/j.jvs.2018.01.051> PMID:29784566
27. Malovrh M. Non-invasive evaluation of vessels by duplex sonography prior to construction of arteriovenous fistulas for haemodialysis. *Nephrol Dial Transplant*. 1998; 13:125-129. <https://doi.org/10.1093/ndt/13.1.125> PMID:9481727