

Large Bowel Occlusion: Clinical and Imaging Characteristics - Caecum Volvulus

Danilo Coco^{1*}, Silvana Leanza²

¹Department of General surgery, Ospedali Riuniti Marche Nord, Pesaro, Italy, ²Division of General surgery, Carlo Urbani Hospital, Jesi, Italy

Abstract

Citation: Coco D, Leanza S. Large Bowel Occlusion: Clinical and Imaging Characteristics - Caecum Volvulus. Open Access Maced J Med Sci. <https://doi.org/10.3889/oamjms.2019.555>

Keywords: Caecum volvulus; Coffee beans; Beard beak; Whirl sign

***Correspondence:** Danilo Coco, Department of General Surgery, Ospedali Riuniti Marche Nord, Pesaro, Italy. E-mail: webcostruction@msn.com

Received: 14-Apr-2019; **Revised:** 08-Jul-2019; **Accepted:** 09-Jul-2019; **Online first:** 12-Jul-2019

Copyright: © 2019 Danilo Coco, Silvana Leanza. This is an open-access article distributed under the terms of the Creative Commons Attribution-NonCommercial 4.0 International License (CC BY-NC 4.0)

Funding: This research did not receive any financial support

Competing Interests: The authors have declared that no competing interests exist

BACKGROUND: Caecum volvulus (CV) is defined as an axial twisting that causes an inversion position of the caecum, ascending colon and terminal ileum. This anatomical finding is responsible for some clinical features. Obstruction and strangulation are the most important and life-threatening.

CASE PRESENTATION: We are presenting a 50 years old woman presented to the hospital with sudden acute severe abdominal pain and distension of about 24 hours associated with vomiting and no flatus.

CONCLUSION: Mortality in patients with CV can be kept near 10%-12% if operative intervention is accomplished before caecum strangulation. Once the cecum has become gangrenous, a death rate of 30 to 40% can be expected. Tailored made surgery on patients status is the strategy.

Introduction

Caecum volvulus (CV) is defined as the torsion of the caecum around its mesentery [1]. The incidence of CV account 1%-1.5% of intestinal obstruction with female predominance and account 25% of colonic volvulus with highly variable age presentation between 30 years to 60 years making it a difficult pathology to identify [1], [2]. That causes strange diagnosis and delayed decision making [3]. Caecum volvulus (CV) is a clear result of incomplete intestinal rotation during embryogenesis featured by an inadequate right colon fixation to retroperitoneal structures during the final clockwise step of colon embryogenesis [1], Figure 1.

Parietocolic ligaments laxity is the main cause of improve caecum motility up and down or right and left and axial rotation. Clinical reports suggest that 40% of caecum strangulation are found in patients with prior abdominal and pelvic surgery.

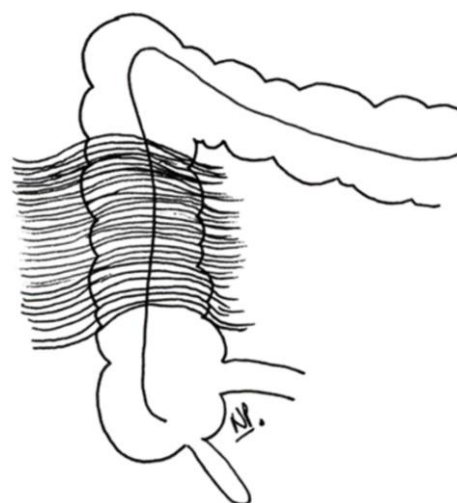


Figure 1: Normal Anatomy of Right Colon

Prior surgery causes adhesions and a new fulcrum of rotation [1]. Laxity of ligaments associated with pelvic surgery are the most important etiologies

of CV [3], [4], Figure 2.

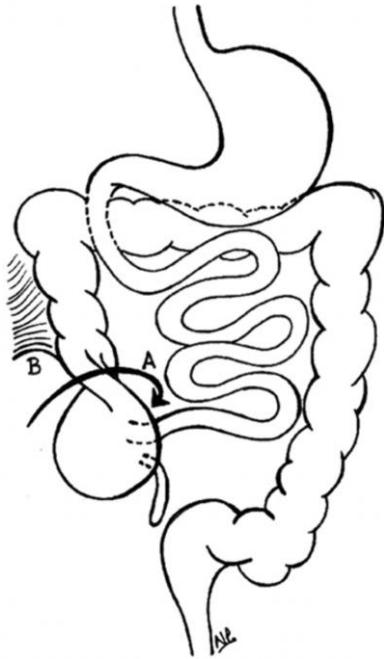


Figure 2: Mechanism of Cecal Volvulus

Case Report

A 50 years old woman presented to the hospital with sudden acute severe abdominal pain and distension of about 24 hours associated with vomiting and no flatus. In her clinical history, she has had a hysterectomy for myxomatosis. She denied other medical problems. On physical examination, we found altered vital signs and hemodynamic instability.

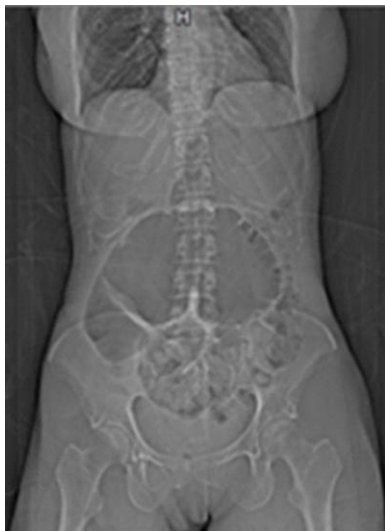

Figure 3: A 50-year woman CT scan: coffee bean sign

Abdominal examination noticed diffuse abdominal distension, tympanic sound and positive

Blumberg sign. Laboratory studies showed WBC 20 cell/mm³ and elevated PCR. Rx abdomen showed intestinal distension suggestive of sigma volvulus. CT scan confirmed caecum volvulus with bird beak sign Figures 3, 4, 5.

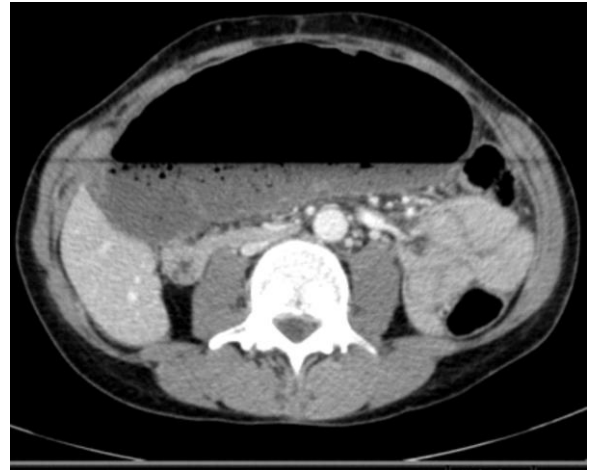

Figure 4: A 50-year woman TC scan: Bird Beak Sign

So, we performed an urgent colonoscopy to view mucosa and possible volvulus untwisting. Colonoscopy showed normal mucosa and no volvulus Figure 6.

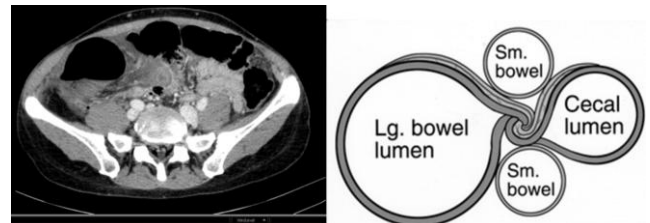


Figure 5: A 50-year woman ct scan: whirl sign

The patients underwent an urgent laparotomy with findings at the operation showing the axial rotation of the caecum and terminal ileum with ischemia extended from the terminal ileum to right colon flexure Figure 7 and Figure 8.

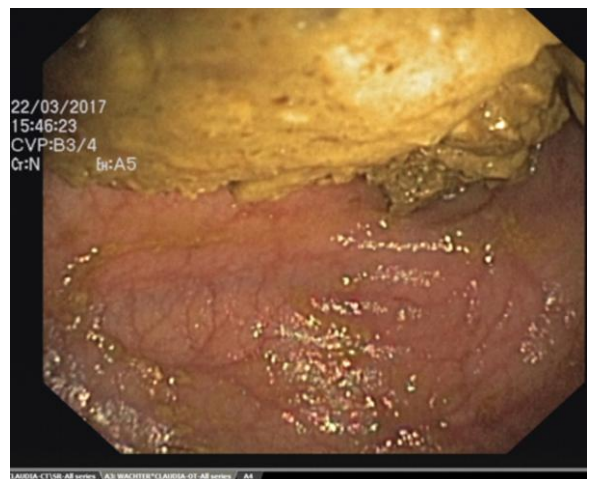


Figure 6: A 50-year woman: Colonoscopy

We performed a classical right colectomy with ileocecal mechanic side to side anastomosis for good patient status. The patient was discharged in seven postoperative days with no medical problems [3].

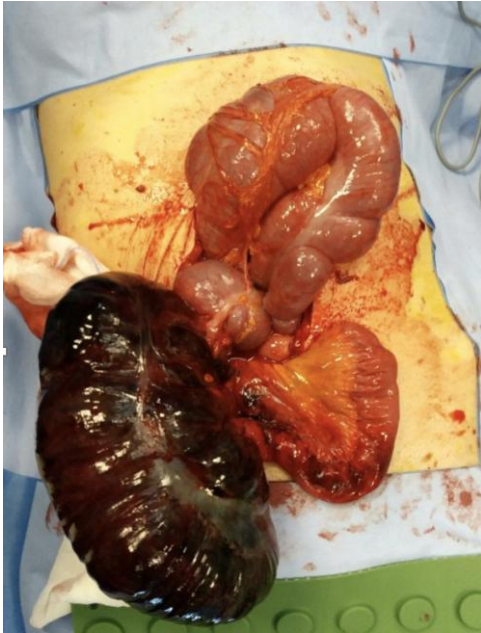

Figure 7: A 50-year-old woman: caecum volvulus

Discussion

The most urgent clinical features are acute obstruction and strangulation associated with sharp pain, no flatus, vomiting, abdominal distension.

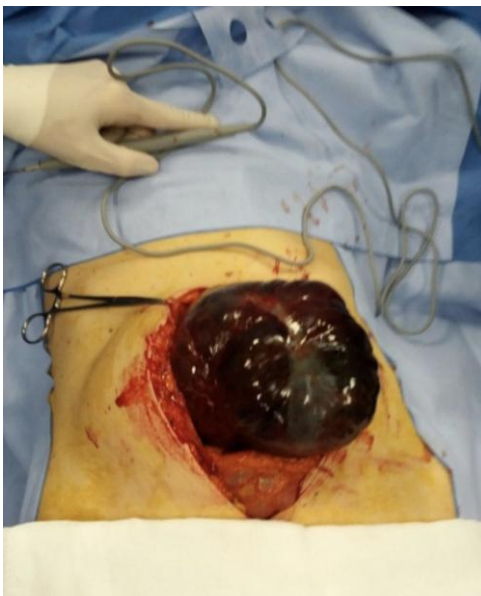

Figure 8: A 50-year-old woman: caecum volvulus

Differential diagnosis with left colon obstruction, small bowel obstruction, mesenteric

ischemia, aortic aneurysm, acute pancreatitis makes the diagnosis difficult. Untreated volvulus may progress in strangulation- ischemia and perforation with peritoneal irritation and hemodynamic instability presentation [3]. It is recommended that these patients must undergo early laboratory and radiological evaluations. Laboratory findings are nonspecific. Advanced obstruction may show high WBC, high PCR and fluid or electrolytes changes. Abdominal X-ray shows intestinal dilatation in 100% of cases, but for the rarity of this pathology, many of the patients are erroneously given the diagnosis of small bowel obstruction or sigma volvulus [5]. CT scan has 80%-90% sensibility / specificity. There are three clinical findings: "Coffee beans", "bird beak" and "whirl" signs. Coffee beans sign demonstrated an axial view of the dilated cecum with air. The loop may resemble a coffee bean, which has an appearance similar to that of the well-known radiographic sign sigmoid volvulus Figure 3 [6].

Bird beaks sign shows bowel loops Figure 4. Whirl sign shows fat attenuation of a soft tissue mass Figure 5 [7].

Colonoscopy may exclude sigma volvulus Figure 6 [8]. Barium enema CT may confirm the colon site of occlusion with 88% of accuracy [2], [3]. Advances in knowledge show: two defined transition points are seen in the minority of cases of caecum volvulus; a single transition point is more sensitive for caecum volvulus. CT findings of a whirl, ileocecal twist, the X-marks-the-spot sign and the split-wall sign are specific for CV. The coffee bean sign and a distended cecum directed toward the left upper quadrant on CT images are insensitive but specific for CV. Distal colonic decompression on CT images is relatively sensitive and specific for CV [6], [9]. Treatment choice is surgery.

The most appropriate strategy depends on the patient's status, the timing of volvulus treatment (early or delayed) and surgical team expertise. The clinical review recommended: manual or laparoscopic untwisting with caecopexy in the viable intestine [2] — Caecostomy in the viable intestine but low-grade patient status. Laparoscopic or open right colectomy is recommended in the non-viable ischemic or perforated colon in good performance status patient [2], [3], [10]. Caecum volvulus (CV) is a rare colonic obstruction. It is caused by a bad rotation of bowel during embryogenesis with ligaments laxity. Diagnosis is STRANGE for the rarity and nonspecific presentation: acute severe abdominal pain is the main clinical features associated with abdominal distension. CT scan has more accuracy. COFFEE BEAN sign is specific. WBC and PCR alteration associated with peritoneal irritation are signs of strangulation, ischemia or perforation. Surgical Treatment is the best choice with adhesiolysis and caecopexy in viable colon and resection in the non-viable colon [11].

In conclusion, mortality in patients with CV

can be kept near 10%-12% if operative intervention is accomplished before caecum strangulation. Once the cecum has become gangrenous, a death rate of 30 to 40% can be expected [11], [12]. Tailored made surgery on patient's status is the strategy [13], [14].

Patient Consent

The authors certify that they have obtained all appropriate patient consent forms. In the form, the patient(s) has/have given his/her/their consent for his/her/their images and other clinical information to be reported in the journal. The patients understand that their names and initials will not be published and due efforts will be made to conceal their identity, but anonymity cannot be guaranteed.

References

- Moore CJ, Corl FM, Fishman EK. CT of cecal volvulus: unraveling the image. *AJR*. 2001; 177:95-8. <https://doi.org/10.2214/ajr.177.1.1770095> PMID:11418405
- Rabinovici R, Simansky DA, Kaplan O, et al. Cecal volvulus. *Dis Colon Rectum*. 1990; 33:765-9. <https://doi.org/10.1007/BF02052323> PMID:2202566
- E T Consorti, T H Liu, Diagnosis and treatment of caecal volvulus, *Postgrad Med J*. 2005; 81:772-776. <https://doi.org/10.1136/pgmj.2005.035311> PMID:16344301 PMCid:PMC1743408
- Pirro N, Corroller LE, Solari C, Merad A, Sielezneff I, Sastre B, Champsaur P, Di VM. Cecal volvulus: anatomical bases and physiopathology. *Morphologie: bulletin de l'Association des anatomistes*. 2006; 90(291):197-202. [https://doi.org/10.1016/S1286-0115\(06\)74506-4](https://doi.org/10.1016/S1286-0115(06)74506-4)
- Theuer C, Cheadle WG. Volvulus of the colon. *Am Surg*. 1991; 57:145-50.
- Rosenblat et al. Findings of Cecal Volvulus at CT. *Radiology*. 2010; 256(1). <https://doi.org/10.1148/radiol.10092112> PMID:20574094
- Frank AJ, Goffner LB, Fruauff AA, et al. Cecal volvulus: the CT whirl sign. *Abdom Imaging*. 1993; 18:288-9. <https://doi.org/10.1007/BF00198126> PMID:8508096
- Renzulli P, Maurer CA, Netzer P, et al. Preoperative colonoscopic derotation is beneficial in acute colonic volvulus. *Dig Surg*. 2002; 19:223-9. <https://doi.org/10.1159/000064217> PMID:12119526
- Moore CJ, Corl FM, Fishman EK. CT of cecal volvulus: unraveling the image. *American Journal of Roentgenology*. 2001; 177(1):95-8. <https://doi.org/10.2214/ajr.177.1.1770095> PMID:11418405
- Madiba TE, Thomson SR. The management of cecal volvulus. *Dis Colon Rectum*. 2002; 45:264-7. <https://doi.org/10.1007/s10350-004-6158-4> PMID:11852342
- O'Mara CS, Wilson TH, Stonesifer GL, et al. Cecal volvulus. Analysis of 50 patients with long-term follow-up. *Ann Surg*. 1979; 189:724-31. <https://doi.org/10.1097/0000658-197906000-00008> PMID:453944 PMCid:PMC1397217
- Ballantyne GH, Brandner MD, Beart RW Jr, et al. Volvulus of the colon. Incidence and mortality. *Ann Surg*. 1985; 202:83-92. <https://doi.org/10.1097/0000658-198507000-00014> PMID:4015215 PMCid:PMC1250842
- Bhandarkar DS, Morgan WP. Laparoscopic caecopexy for caecal volvulus. *Br J Surg*. 1995; 82:323. <https://doi.org/10.1002/bjs.1800820312> PMID:7795996
- O'Toole A, Ruiz-Herrero AL, Lavelle MA. Laparoscopic caecopexy. *Minim Invasive Allied Technol*. 1995; 2:307-8. <https://doi.org/10.3109/13645709309152975>