

## Antiarthritic Activity of *Achyranthes Aspera* on Formaldehyde - Induced Arthritis in Rats

Velmurugan Chinnasamy<sup>1</sup>, Vetriselvan Subramaniam<sup>2\*</sup>, Sarath Chandiran<sup>3</sup>, Saminathan Kayarohanam<sup>4</sup>, Dhanapal Chidambaram Kannian<sup>5</sup>, Venkata Sathya Saiappala Raju Velaga<sup>6</sup>, Shafiulla Muhammad<sup>7</sup>

<sup>1</sup>Department of Chemistry, Toxicology Unit, College of Natural Sciences, Arba Minch University, Ethiopia; <sup>2</sup>Department of Pharmacology, Faculty of Medicine, MAHSA University, Malaysia; <sup>3</sup>School of Pharmacy, Sri Balaji Vidyapeeth Deemed University, India; <sup>4</sup>Faculty of Bio-economy and Health Sciences, Geomatika University College Kuala Lumpur, Malaysia; <sup>5</sup>Department of Pharmacy, Annamalai University, India; <sup>6</sup>Faculty of Pharmacy, MAHSA University, Malaysia; <sup>7</sup>Department of Pharmacology, Sri Krishna Chaithanya College of pharmacy, Madanapalle, Andhra Pradesh, India

### Abstract

**Citation:** Chinnasamy V, Subramaniam V, Chandiran S, Kayarohanam S, Kannian DC, Velaga VSSR, Muhammad S. Antiarthritic Activity of *Achyranthes Aspera* on Formaldehyde - Induced Arthritis in Rats. Open Access Maced J Med Sci. <https://doi.org/10.3889/oamjms.2019.559>

**Keywords:** *Achyranthesaspera*; Formaldehyde; Arthritis; Anti-arthritis

**\*Correspondence:** Vetriselvan Subramaniam, Faculty of Medicine, Department of Pharmacology, MAHSA University, Kuala Lumpur, Malaysia. E-mail: [dvvetriselvan@mahsa.edu.my](mailto:dvvetriselvan@mahsa.edu.my)

**Received:** 16-Apr-2019; **Revised:** 07-Jul-2019; **Accepted:** 20-Jul-2019; **Online first:** 30-Aug-2019

**Copyright:** © 2019 Velmurugan Chinnasamy, Vetriselvan Subramaniam, Sarath Chandiran, Saminathan Kayarohanam, Dhanapal Chidambaram Kannian, Venkata Sathya Saiappala Raju Velaga, Shafiulla Muhammad. This is an open-access article distributed under the terms of the Creative Commons Attribution-NonCommercial 4.0 International License (CC BY-NC 4.0)

**Funding:** This research did not receive any financial support

**Competing Interests:** The authors have declared that no competing interests exist

**AIM:** To determine the ameliorative potential of aqueous extract of *Achyranthesaspera*(AEAA) against arthritis using swiss albino mice and Wistar rats, and its possible mechanism of action.

**METHODS:** Swiss albino mice (25-30 g) and Wistar rats (150-180 g) under standard controlled conditions (24 ± 2°C, 50-70 humidity and 12 h light/dark cycle). The groups were divided into 6 groups (n = 6/group) and assigned as control, negative control, standard and, formaldehyde supplemented with two different test dose groups of *A. aspera* for 4 weeks. Arthritis induced by subplantar administration of 0.1 ml formaldehyde (2% v/v) into the left hind paw in all groups except normal control. Arthritis was assessed using serum Hb, ESR, paw volume, joint diameter, radiological and histopathological investigation.

**RESULTS:** Oral administration of AEAA shown a significant (p < 0.01) dose-dependent protection against formaldehyde induced arthritis. At 21st day, *A. aspera* shown an inhibition of paw volume in the different doses of 250 mg/kg and 500 mg/kg were found to be 30% and, 38.33% respectively. At 14th day the joint swelling was found to be 27.2% and 36.36 respectively. Diclofenac (10 mg/kg) had an effect of 36.61% inhibition of arthritis and joint swelling at 21st and 14th day.

**CONCLUSION:** Thus, the present study revealed that the aqueous extract of *A. aspera* offered significant protection against arthritis and joint inflammation.

### Introduction

Rheumatoid arthritis (RA) is a chronic systemic inflammatory autoimmune disease [1], [2]. Although many medicines are prescribed for the treatment of RA, they are known to produce various side effects. So, there is still a need to seek therapeutic agents with lower side effects that can be used for long-term administration [3], [4]. *Achyranthesaspera* belongs to the family Amaranthaceae; it is an annual shrub found distributed throughout the tropical and subtropical regions. In the recent past, there has been a

tremendous increase in the use of plant-based health products in developing as well as developed countries resulting in an exponential growth of herbal products globally. It is commonly found in India, Baluchistan, Sri Lanka, tropical Asia, Africa, Australia, and America [4], [5], [6]. Herbal drugs constitute a major part of all traditional systems of medicines [5]. The plant is a popular folk remedy in traditional system of medicine throughout the tropical Asian and African countries. The World Health Organization has attempted to identify all medicinal plants used globally and listed more than 20,000 species [6]. The plant is highly esteemed by traditional healers and used in treatment of asthma [5], [6], spermicidal activity [7], post-coital antifertility activity [8], anti-parasitic activity [9],

hypoglycaemic activity [10], hepatoprotective activity [11], anti-inflammatory [12], nephroprotective [13], anti-depressant [14], bronchoprotective [15], antiallergic [16]. Hence, the present study is made for the evaluation of aqueous extract of AA for anti-arthritis activity in rats fed with formaldehyde. In this study, we assessed the effects of *Achyranthesaspera* against rheumatoid arthritis.

## Material and Methods

### Collection and identification of the plant materials

The leaves of *Achyranthesaspera* collected from Tirumala Forest, Tirupathi, Chittoor District, Andhra Pradesh, India. Botanical identification was carried out at the Department of Botany, Sri Venkateswara University, Tirupathi. Where, voucher specimen No.SKCCP/2015/110a was deposited in the museum of the department of Pharmacognosy Sri Krishna Chaithanya College of pharmacy, Madanapalle, Andhra Pradesh, India

### Drugs and Chemicals

Serum kits were obtained from Span Diagnostics Ltd. Surat, India. Diclofenac sodium was supplied from Ajanta Pharma Limited, Maharashtra, India. Formaldehyde, purchased from Sigma Aldrich Chemical, India. Normal saline purchased from bio-aids scientific, Bangalore, India. All other chemicals were of analytical grade procured from reputed Indian manufacturers.

### Experimental animals

All the experiments were carried out using Swiss Albino mice (25-30 g) and Wister rats (150-180 g). The animals were placed at random and allocated to treatment groups in polypropylene cages with paddy husk as bedding. Animals were housed in a temperature of  $24 \pm 2^\circ\text{C}$  and relative humidity of 30–70%. A 12 hrs day: 12 hrs night cycle was followed. All animals were allowed free access to water and fed. Ethical clearance was obtained from the Institutional Animal Ethical Committee (IAEC) of Sri Krishna Chaithanya College of Pharmacy, Madanapalle, Andhra Pradesh.

### Preparation of the extracts

The collected leaves were dried completely and powder with a mechanical grinder. The powder was passed through sieve no. 60 to get uniform powdered. The 250 gm of dried powder of

*Achyranthesaspera* leaves was defatted with Petroleum ether. The defatted powder material (marc) thus obtained was successively extracted with aqueous solvent by maceration. The Maceration process involves the separation of medicinally active portions of the crude drugs. The drug material is taken in a stoppered container and immersed in the bulk of the solvents in the ratio of 1: 2 (Drug & Solvent) and allowed to stand for 7 days in room temperature with frequent shaking of every 30 minutes up to 6 hours on each day. The solvent was separated by filtration and concentrated under reduced pressure. The resulting semisolid mass was vacuum dried, and the percentage yield was calculated [17].

### Acute toxicity study

The acute toxicity study was carried out to extract of *Achyranthesaspera* as per OECD 423 Guidelines. Swiss albino mice with weight ranging (25-30 g) were taken for the experiment. The animals were made into a group of 3 each, dose of aqueous extract was given according to the bodyweight (mg/kg), starting dose of 5 mg/kg was given to the first group of animal, no death was occurring and higher doses were given to the next group of animals up to 5000 mg/kg. The animals were observed for a further 14 days for any signs for delayed toxicity [18].

The time at which signs of toxicity appear/disappear was observed systematically and recorded for each animal.

### Formaldehyde induced arthritis

Group 1: Normal control (1% v/v tween 80, p.o. for 28 days).

Group 2: Negative Control (Formaldehyde 0.1 ml 2% v/v by Sub-plantar region).

Group 3: Formaldehyde 0.1 ml 2% v/v + Standard (Diclofenac 10 mg/kg p.o. for 28 days).

Group 4: Formaldehyde 0.1 ml 2% v/v + Low dose of AEAA (125 mg/kg p.o. for 28 days).

Group 5: Formaldehyde 0.1 ml 2% v/v + Medium dose of AEAA (250 mg/kg p.o. for 28 days).

Group 6: Formaldehyde 0.1 ml 2% v/v + High dose of AEAA (500 mg/kg p.o. for 28 days).

Animals were divided into six groups (n = 6). Group I received the vehicle (2 ml/kg, 1% v/v tween 80) and served as the normal control. Group II received formaldehyde, served as a negative control. Group III received the standard drug diclofenac (10 mg/kg body weight), groups IV, V and VI received AEAA in doses of (125, 250 and 500 mg/kg body weight), respectively. Thirty minutes after oral administration of vehicle/drugs, arthritis was induced by subplantar administration of 0.1 ml formaldehyde (2% v/v) into the left hind paw of all the animals

except normal control. This was designated as day 1. Vehicle/drug treatment was continued for the duration of 28 more days. Formaldehyde (0.1 ml 2% v/v) was again injected into the same paw on the third day [19], [20].

Paw volume and paw thickness were measured at 0 days, 7th day, 14th day, 21st day and 28th day by using Plethysmometer and vernier calibre, respectively. The body weights of the animals were measured by digital balance to access the exact dose & course of the disease at the initial day after induction, 14<sup>th</sup> day and the end of 28<sup>th</sup> day.

% inhibition of paw oedema concerning untreated groups was calculated using the following formula:

$$i = [1 - (\Delta V_{\text{treated}} / \Delta V_{\text{untreated}})] \times 100$$

Where,

i = % inhibition of paw edema

$\Delta V_{\text{treated}}$  = mean change in paw volume of treated rat

$\Delta V_{\text{untreated}}$  = mean change in paw volume of untreated rat

#### Method for collection of a blood sample

On the 28<sup>th</sup> day, the blood (2 ml) collected by retro-orbital cavity under the influence of ether anaesthesia. Some of the collected blood was used to perform Hematological studies to estimate Hb gm/dl, & ESR mm/hr. The remaining blood was used to centrifuge at 3000 rpm at room temperature, and collected serum was used to perform the RA factor.

#### Radiography

Radiographic evaluation was performed based on radiographs and coned down views of lower limbs. Radiographs were taken with GE 500 mA, 40 kvp and 4 MAS.

#### Histopathological analysis

A portion of the bones was immediately kept in 10% formalin to fix the tissue after isolation. The bones were washed in running tap water, decalcified by placing in formic acid and dehydrated in the descending grades of alcohol and finally cleared in xylene. The tissues were embedded in molten paraffin wax.

Hard paraffin wax was melted and poured into square-shaped blocks. The knee joints were then dropped into the liquid paraffin quickly and allowed to cool. The blocks were cut using microtome to get sections of thickness 10  $\mu\text{m}$ . The section was dried completely before staining. Eosin an acidic stain and hematoxylin a basic stain was used for staining and observed under an electronic microscope for histopathological changes [21].

#### Statistical analysis

The statistical significance was assessed by using one-way analysis of variance (ANOVA) and followed by Dunnet's comparison test. All data are presented as mean  $\pm$  SEM, and  $p < 0.01$  was considered significant.

## Results

#### Preliminary phytochemical screening

The preliminary phytochemical analysis of aqueous extracts of *Achyranthes aspera* revealed the presence of Alkaloids, Carbohydrates, glycosides phenolic compound, flavonoids, tannin and proteins (Table 1).

**Table 1. Preliminary phytochemical screening of aqueous extract of *Achyranthes aspera***

Sl. No	Constituents	Observation in AEAA
1.	Alkaloids	Positive
2.	Carbohydrates	Positive
3.	Glycosides	Positive
4.	Phenolic compounds	Positive
5.	Flavonoids	Positive
6.	Tannin and Proteins	Positive

#### Blood and serum analysis

As a result of inflammation induced by formaldehyde, the levels of Hb mg/dl & ESR mm/hr were increased in all arthritis rats as compared to negative control rats. After extract treatment, the levels of these haematological parameters were significant ( $p < 0.01$ ) decreased in group V & VI rats as compared to negative control rats except Group IV revealed non-significant.

The dose of 500 mg/kg aqueous extract-treated group prevented haematological changes to a greater extent than the Diclofenac sodium (10 mg/kg). However, treated groups III, V & VI serum show RA factor negative results as compared to the negative control, which shows positive. The group IV shows the RA factor positive, the group V & VI proving its antiarthritic efficacy.

#### Effect of AEAA on joint swelling (paw volume) in formaldehyde induced arthritis

An increase in paw volume was seen in all animals throughout the observation period. Maximum paw volume was observed on day 21, after which there was a gradual decrease except in the negative control and AEAA (125 mg/kg) treated groups, which showed an increase in paw volume from Day 1 to day 28.

Although drug-treated groups showed a decrease in joint swelling as compared to the negative

control, the difference was significant ( $p < 0.01$ ) in Group III, V, VI on all observation day. AEAA at a dose of 125 mg/kg (Group IV) produced a nonsignificant reduction in paw volume on all observation day.

### Radiological studies

The radiographic features of the rat joints in formaldehyde induced arthritic model, as shown in Figure 1. In formaldehyde induced arthritis rats (group II), soft tissue swelling along with a narrowing of the joint spaces were observed which implies the bony destruction in arthritic condition [22]. The standard drug Diclofenac sodium treated groups have prevented this bony destruction and also there is decreased swelling of the joint. The AEAA 250 & 500 mg/kg treatment for 28 days have shown significant prevention against bony destruction by showing less soft tissue swelling and narrowing of joint spaces when compared with the negative control.

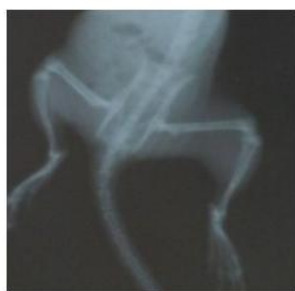

Fig. 1a

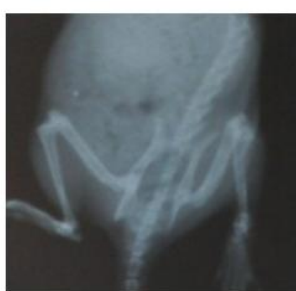

Fig. 1b

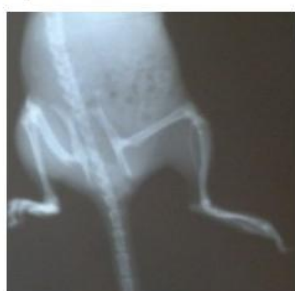

Fig. 1c

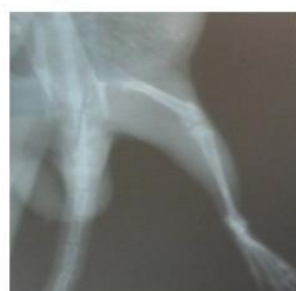

Fig. 1d

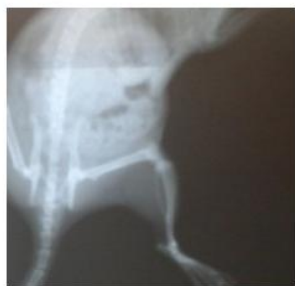

Fig. 1e

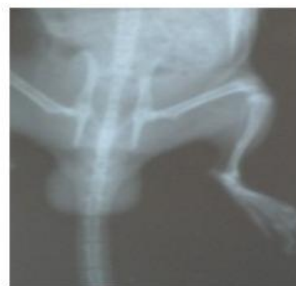

Fig. 1f

Figure 1: Radiography of the rat joints in formaldehyde induced arthritic model; A) Normal Control (DMSO 2 ml/kg); B) Negative control; C) Standard (Diclofenac 10 mg/kg); D) AEAA 125 mg/kg; E) AEAA 250 mg/kg; F) AEAA 500 mg/kg

### Effect of AEAA on joint diameter in formaldehyde induced arthritis

Administration of formaldehyde 0.1 ml 2% v/v produced an increase in the joint diameter of all the animals, which was persistent throughout the observation period (Figure 2). Maximum joint swelling was observed on day 14, after which there was a gradual decrease except in the negative control and AEAA (125 mg/kg) treated groups, which showed an increase in joint diameter from Day 1 to day 28. At the highest dose (500 mg/kg), AEAA was more efficacious as equal to Diclofenac in reducing the joint swelling.

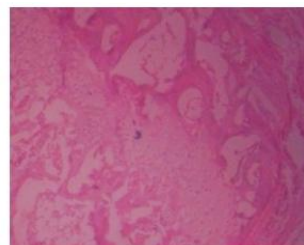


Fig. 2a

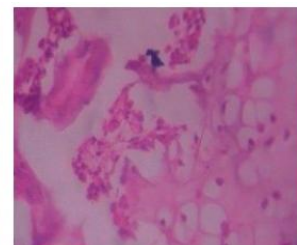


Fig. 2b

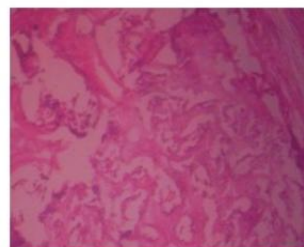

Fig. 2c

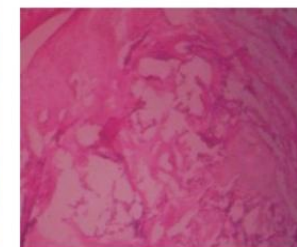

Fig. 2d

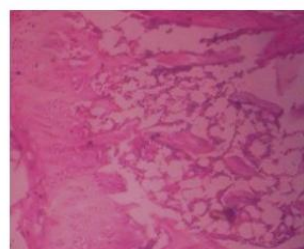


Fig. 2e

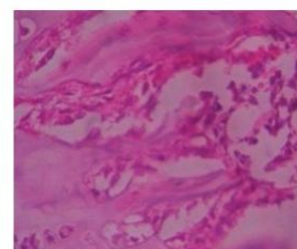


Fig. 2f

Figure 2: Histological examination of experimental rats; A) Normal Control (DMSO 2 ml/kg); B) Negative control; C) Standard (Diclofenac 10 mg/kg); D) AEAA 125 mg/kg; E) AEAA 250 mg/kg; F) AEAA 500 mg/kg

### Histopathological studies

Histological studies of ankle joint reports confirm that there is severe bone erosion with the presence of neutrophil infiltration and pannus formation in the negative control group, as shown in Figure 2b. The treatment groups AEAA 250 mg/kg and 500 mg/kg revealed a reduction in pannus formation and bone resorption, joint inflammation with reduced neutrophil infiltration. Among the two-dose group, 500 mg/kg proved a dose-dependent action that is comparable to that of standard diclofenac group and 125 mg/kg slide shows a moderate level of cells and mild effect on inflammation.

*Achyranthes aspera* not only reduced the progression of inflammation and arthritis in experimental animals but also improved several symptoms associated with the disease. This study highlights the potential of *Achyranthes aspera* as a reliable treatment for arthritis substantiating the claims of the *plant drugs*.

## Discussion

In our study, the AEAA exhibited significant anti-arthritic activity in a dose-dependent manner. In the present study, we showed that 250 & 500 mg/kg AEAA could significantly inhibit the progression of rheumatoid arthritis in treating animals. However, standard drug and aqueous extract significantly suppressed the swelling of the paws in the chronic phase, which may be due to the suppression of inflammatory mediator released due to induction of formaldehyde. Though the actual mechanism of suppressing inflammation is not known, it can be correlated with the presence of phenolic compound and flavonoids in suppressing the inflammation and antioxidant activity [23]. Numerous studies have suggested a role of oxidative stress in the pathogenesis of rheumatoid arthritis [24].

**Table 2: Effect of aqueous extract of *Achyranthesaspera* on Hb, ESR & RA factor**

Groups	Treatment & Dose	Hb mg/dl	ESR mm/hr	RA factor
1	Normal Control	16.8 ± 0.35	11.9 ± 0.54	Negative
2	Negative Control	9.58 ± 1.04	23.25 ± 1.49	Positive
3	Diclofenac (10 mg/kg)	14.56 ± 0.81**	8.96 ± .42**	Negative
4	AEAA 125 mg/kg	10.64 ± 0.7 <sup>ns</sup>	24.32 ± 0.31 <sup>ns</sup>	Positive
5	AEAA 250 mg/kg	12.86 ± 0.42**	7.73 ± .28**	Negative
6	AEAA 500 mg/kg	15.71 ± 0.28**	10.44 ± 0.57**	Negative

Therefore; It was assumed that the reported and well-established antioxidant properties of AEAA and its ability to block the COX2 pathway during the progression of inflammation justify the usage of the plant extract in the treatment of rheumatoid arthritis [25], [26].

**Table 3: Effect of AEAA on joint swelling (Paw volume)**

Groups	Treatment & Dose	Paw volume in ml					% inhibition of paw volume on 21 <sup>st</sup> day
		1 <sup>st</sup> day	7 <sup>th</sup> day	14 <sup>th</sup> day	21 <sup>st</sup> day	28 <sup>th</sup> day	
1	Normal Control	0.04 ± 0.00	0.04 ± 0.00	0.05 ± 0.00	0.05 ± 0.00	0.04 ± 0.00	-
2	Negative Control	0.26 ± 0.01	0.46 ± 0.01	0.55 ± 0.02	0.6 ± 0.02	0.67 ± 0.01	0
3	Diclofenac (10 mg/kg)	0.20 ± .02**	0.31 ± 0.03**	0.34 ± 0.01**	0.38 ± 0.02**	0.33 ± 0.01**	36.6
4	AEAA 125 mg/kg	0.25 ± 0.02 <sup>ns</sup>	0.42 ± 0.02 <sup>ns</sup>	0.52 ± 0.02 <sup>ns</sup>	0.54 ± 0.02 <sup>ns</sup>	0.65 ± 0.01 <sup>ns</sup>	10
5	AEAA 250 mg/kg	0.21 ± 0.00**	0.37 ± 0.01**	0.38 ± 0.00**	0.42 ± 0.02**	0.38 ± 0.02**	30
6	AEAA 500 mg/kg	0.18 ± 0.00**	0.30 ± 0.02**	0.35 ± 0.01**	0.37 ± 0.01**	0.31 ± 0.02**	38.33

As shown in Table 2, assessment of the levels of Hb and ESR provides an excellent and simple tool to measure the anti-arthritic activity [27] of the target drug. The activities of these parameters were significantly decreased and increased in arthritic

rats. These are good indicators, considered to be features of formaldehyde arthritis [28], [29]. There was a significant reduction in the paw volume and joint diameter in formaldehyde induced arthritic rats. The Shruti et al. study also revealed cardinal signs of the chronic inflammatory reactions like redness, swelling, arthralgia and immobility of affected joints were significantly less in the drug-treated animal than the negative control [30] (Table 3).

Radiographic changes in RA conditions are useful diagnostic measures which indicate the severity of the disease [31]. Soft tissue swelling is the earlier radiographic sign, whereas prominent radiographic changes like bony erosions and narrowing of joint spaces can be observed only in the development stages (final stages) of arthritis [31] (Table 4).

**Table 4: Effect of AEAA on the joint diameter**

Groups	Treatment & Dose	Joint diameter in mm					% inhibition of joint diameter 14 <sup>th</sup> day
		1 <sup>st</sup> day	7 <sup>th</sup> day	14 <sup>th</sup> day	21 <sup>st</sup> day	28 <sup>th</sup> day	
1	Normal Control	0.42 ± 0.02	0.42 ± 0.02	0.42 ± 0.02	0.42 ± 0.01	0.43 ± 0.01	-
2	Negative Control	0.55 ± 0.02	0.69 ± 0.01	0.77 ± 0.01	0.81 ± 0.02	0.89 ± 0.02	0
3	Diclofenac (10 mg/kg)	0.40 ± 0.03	0.42 ± 0.02	0.51 ± 0.03	0.47 ± 0.02	0.45 ± 0.02	36.61
4	AEAA 125 mg/kg	0.58 ± 0.02	0.66 ± 0.02	0.74 ± 0.01	0.78 ± 0.02	0.86 ± 0.01	3.89
5	AEAA 250 mg/kg	0.46 ± 0.01	0.48 ± 0.01	0.56 ± 0.03	0.55 ± 0.03	0.50 ± 0.03	27.2
6	AEAA 500 mg/kg	0.38 ± 0.01	0.42 ± 0.02	0.49 ± 0.02	0.45 ± 0.02	0.45 ± 0.02	36.36

Radiography result shows that the extract 500 mg/kg of *Achyranthesaspera* prevents joint destruction, swelling & narrowing of joint space. Haematological parameters RA factor results also showed a significant improvement of the arthritic condition. The pathogenesis or reasons for the development of arthritis following injection of formaldehyde are not fully understood. As shown in Figure 2, the treatment groups AEAA 250 mg/kg and 500 mg/kg showed a reduction in pannus formation and bone resorption, joint inflammation with reduced neutrophil infiltration. Formaldehyde induced arthritis is one of the most widely used models as it has been shown to share several clinical features with human arthritis [32]. Changes in haematological parameters were observed due to arthritic condition [33].

In conclusion, the present experimental findings of pharmacological, radiological, histological and hematological parameters observed from the current investigation, it is concluded that at the doses of 250mg/kg and 500 mg/kg AEAA possesses potentially useful anti-arthritic activity since it gives a positive result in controlling inflammation in formaldehyde induced arthritis model in rats. The high dose of AEAA reflected highly beneficial and treatment of inflammatory disorders.

## References

- Herlitz-Cifuentes HS, Garcés PC, Fernández L, Guzmán-Gutiérrez EA. Effect of Systemic Inflammation on the Function of Insulin and

- Glucose Metabolism in Rheumatoid Arthritis. *Curr Diabetes Rev.* 2015; 12:156-62. <https://doi.org/10.2174/1573399811666150602150325> PMID:26033386
2. Sodhi A, Naik S, Pai A, Anuradha A. Rheumatoid arthritis affecting temporomandibular joint. *Contemp Clin Dent.* 2015; 6:124-27. <https://doi.org/10.4103/0976-237X.149308> PMID:25684928 PMID:PMC4319332
3. Younger J, Parkitny L, McLain D. The use of low-dose naltrexone (LDN) as a novel anti-inflammatory treatment for chronic pain. *Clin Rheumatol.* 2014; 33:451-59. <https://doi.org/10.1007/s10067-014-2517-2> PMID:24526250 PMID:PMC3962576
4. Peponis V, Kytтары VC, Chalkiadakis SE, Bonovas S, Sitaras NM. Ocular side effects of anti-rheumatic medications: what a rheumatologist should know. *Lupus.* 2010; 19:675-82. <https://doi.org/10.1177/0961203309360539> PMID:20144965 PMID:PMC2926651
5. Susanne Renner S, Arun Pandey K. The Cucurbitaceae of India: Accepted names, synonyms, geographic distribution, and information on images and DNA sequences. *PhytoKeys.* 2013; 20:53-18. <https://doi.org/10.3897/phytokeys.20.3948> PMID:23717193 PMID:PMC3652411
6. Kadir SL, Yaakob H, Zulkifli RM. Potential anti-dengue medicinal plants: a review. *J Nat Med.* 2013; 67:677-89. <https://doi.org/10.1007/s11418-013-0767-y> PMID:23591999 PMID:PMC3765846
7. Avni Desai G, Ghulam Qazi N, Ramesh Ganju K, Mahmoud El-Tamer, Jaswant Singh, Ajit Saxena K, Yashbir Bedi S, Subhash Taneja C, Hari Bhat K. Medicinal Plants and Cancer Chemoprevention. *Curr Drug Metab.* 2008; 9:581-91. <https://doi.org/10.2174/138920008785821657> PMID:18781909 PMID:PMC4160808
8. Vasudeva N, Sharma SK. Post-coital antifertility activity of *Achyranthes aspera* Linn. root. *J Ethnopharmacol.* 2006; 107:179-81. <https://doi.org/10.1016/j.jep.2006.03.009> PMID:16725289
9. Zahir AA, Rahuman AA, Kamaraj C, Bagavan C, Elango G, Sangaran A, Kumar BS. Laboratory determination of efficacy of indigenous plant extracts for parasites control. *Parasitology Research.* 2009; 105:453-61. <https://doi.org/10.1007/s00436-009-1405-1> PMID:19308453
10. Talukder FZ, Khan KA, Uddin R, Jahan N, Alam MA. In vitro free radical scavenging and anti-hyperglycemic activities of *Achyranthes aspera* extract in alloxan-induced diabetic mice. *Drug Discov Ther.* 2012; 6:298-05. <https://doi.org/10.5582/ddt.2012.v6.6.298>
11. Bafna AR, Mishra SH. Effect of methanol extract of *Achyranthes aspera* Linn. on rifampicin-induced hepatotoxicity in rats. *ARS Pharmaceutica.* 2004; 45:343-51.
12. Krishna Chaitanya Anantha D, Reddy Challa Siva, Reddy Manohar A. Hepatoprotective effect of biherbaethanolic extract against paracetamol-induced hepatic damage in albino rats. *J Ayurveda Integr Med.* 2012; 3:198-03. <https://doi.org/10.4103/0975-9476.104436> PMID:23326091 PMID:PMC3545240
13. Kartik R, Ch Rao V, Trivedi SP, Pushpangadan P, Reddy GD. Amelioration effects against N-nitrosodiethylamine and CCl<sub>4</sub>-induced hepatocarcinogenesis in Swiss albino rats by whole plant extract of *Achyranthes aspera*. *Indian J Pharmacol.* 2010; 42:370-75. <https://doi.org/10.4103/0253-7613.71921> PMID:21189908 PMID:PMC2991695
14. ChandanaBarua C, Archana Talukdar, Shameem Ara Begum, Prabodh Borah, MangalaLahkar. Anxiolytic activity of methanol leaf extract of *Achyranthes aspera* Linn in mice using experimental models of anxiety. *Indian J Pharmacol.* 2012; 44:63-7. <https://doi.org/10.4103/0253-7613.91869> PMID:22345872 PMID:PMC3271542
15. Aggarwal A, Singla SK, Gandhi M, Tandon C. Preventive and curative effects of *Achyranthes aspera* Linn. extract in experimentally induced nephrolithiasis. *Indian J Exp Biol.* 2012; 50:201-08.
16. Tabassum N, Hamdani M. Plants used to treat skin diseases. *Pharmacogn Rev.* 2014; 8:52-60. <https://doi.org/10.4103/0973-7847.125531> PMID:24600196 PMID:PMC3931201
17. Sikarwar MS, Patil MB. Antidiabetic activity of *Crateva nurvala* stem bark extracts in alloxan-induced diabetic rats. *J Pharm Bioallied Sci.* 2010; 2:18-1. <https://doi.org/10.4103/0975-7406.62700> PMID:21814425 PMID:PMC3146085
18. Jonsson M, Jestoi M, Nathanail AV, Kokkonen UM, Anttila M, Koivisto P, Karhunen P, Peltonen K. Application of OECD Guideline 423 in assessing the acute oral toxicity of moniliformin. *Food Chem Toxicol.* 2013; 53:27-2. <https://doi.org/10.1016/j.fct.2012.11.023> PMID:23201451
19. Shivani Ghildiya, Manish Gautam K, Vinod Joshi K, Raj Goel K. Anti-inflammatory activity of two classical formulations of *Laghupanchamula* in rats. *J Ayurveda Integr Med.* 2013; 4:23-7. <https://doi.org/10.4103/0975-9476.109546> PMID:23741158 PMID:PMC3667429
20. Vinod Nair, Surender Singh, Gupta YK. Evaluation of disease modifying activity of *Coriandrum sativum* in experimental models. *Indian J Med Res.* 2015; 135:240-45.
21. Tatyana Taksir V, Jennifer Johnson, Colleen Maloney L, Emily Yand, Denise Griffiths, Beth Thurberg L, Susan Ryan. Optimization of a Histopathological Biomarker for Sphingomyelin Accumulation in Acid Sphingomyelinase Deficiency. *J Histochem Cytochem.* 2012; 60:620-29. <https://doi.org/10.1369/0022155412451129> PMID:22614361 PMID:PMC3460358
22. Dhanda S, Swee Tian QU, Bathla G, Jagmohan P. Intra-articular and Peri-articular Tumours and Tumour Mimics- What a Clinician and Onco-imaging Radiologist Should Know. *Malays J Sci.* 2014; 21:4-9.
23. Pandey KB, Rizvi SI. Plant polyphenols as dietary antioxidants in human health and disease. *Oxid Med Cell Longev.* 2009; 2:270-78. <https://doi.org/10.4161/oxim.2.5.9498> PMID:20716914 PMID:PMC2835915
24. Berthou F, Ceppo F, Dumas K, Massa F, Vergoni B, Alemany S, Cormont M, Tanti JF. The Tpl2 Kinase Regulates the COX-2/Prostaglandin E2 Axis in Adipocytes in Inflammatory Conditions. *Mol Endocrinol.* 2015; 29:1025-36. <https://doi.org/10.1210/me.2015-1027> PMID:26020725 PMID:PMC5414708
25. Wan SG, Taccioli C, Jiang Y, Chen H, Smalley KJ, Huang K, Liu XP, Farber JL, Croce CM, Fong LY. Zinc deficiency activates S100A8 inflammation in the absence of COX-2 and promotes murine oral-esophageal tumor progression. *Int J Cancer.* 2011; 129:331-45. <https://doi.org/10.1002/ijc.25688> PMID:20857495 PMID:PMC3015018
26. Kumar V, Al-Abbasi FA, Verma A, Mujeeb M, Anwar F. Umbelliferone  $\beta$ -D-galactopyranoside exerts an anti-inflammatory effect by attenuating COX-1 and COX-2. *Toxicol Res.* 2015; 4:1072-84. <https://doi.org/10.1039/C5TX00095E>
27. Vilela EG, da Gama Torres HO, Martins FP, de Abreu Ferrari MD, Andrade MM, da Cunha AS. Evaluation of inflammatory activity in Crohn's disease and ulcerative colitis. *World J Gastroenterol.* 2012; 18:872-81. <https://doi.org/10.3748/wjg.v18.i9.872> PMID:22408345 PMID:PMC3297045
28. Filippin LI, Vercellino R, Marroni NP, Xavier RM. Redox signalling and the inflammatory response in rheumatoid arthritis. *Clin Exp Immunol.* 2008; 152:415-22. <https://doi.org/10.1111/j.1365-2249.2008.03634.x> PMID:18422737 PMID:PMC2453196
29. Kamati M, Chandra RH, Veeresham C, Kishan B. Anti-arthritis activity of root bark of *Oroxylum indicum* (L.) vent against adjuvant-induced arthritis. *Pharmacognosy Res.* 2013; 5:121-28. <https://doi.org/10.4103/0974-8490.110543> PMID:23798888 PMID:PMC3685761
30. Srivastava S, Singh P, Jha KK, Mishra G, Srivastava S, Khosa RL. Evaluation of anti-arthritis potential of the methanolic extract of the aerial parts of *Costusspeciosus*. *J Ayurveda Integr Med.* 2012; 3:204-8. <https://doi.org/10.4103/0975-9476.104443> PMID:23326092 PMID:PMC3545241
31. Kim YM, Joo YB. Patellofemoral Osteoarthritis. *Knee Surg Relat Res.* 2012; 24:193-200. <https://doi.org/10.5792/ksrr.2012.24.4.193> PMID:23269956 PMID:PMC3526755
32. Nair V, Singh S, Gupta YK. Evaluation of disease modifying activity of *Coriandrum sativum* in experimental models. *Indian J Med Res.* 2012; 135(2):240-245.
33. Subramaniyan V. Bioactive Food as Dietary Interventions for Arthritis and Related Inflammatory Diseases, Second Edition, Academic press (Elsevier), 2019:507-521. <https://doi.org/10.1016/B978-0-12-813820-5.00029-5>