

A Unique Communicating Arterial Branch between the Celiac Trunk and the Superior Mesenteric Artery: A Case Report

Adegbenro Omotuyi John Fakoya^{1*}, Emilio Aguinaldo², Natalia M. Velasco-Nieves², Erica Barnes², Zachary T. Vandever², Nannette Morales-Marietti², Abayomi Gbolahan Afolabi¹, Thomas McCracken¹

¹Department of Anatomy, University of Medicine and Health Sciences, Basseterre, St. Kitts and Nevis; ²University of Medicine and Health Sciences, Basseterre, St. Kitts and Nevis

Abstract

Citation: Fakoya AOJ, Aguinaldo E, Velasco-Nieves NM, Vandever ZT, Morales-Marietti N, Mathew S, Afolabi AG, McCracken T. A Unique Communicating Arterial Branch between the Celiac Trunk and the Superior Mesenteric Artery: A Case Report. Open Access Maced J Med Sci. 2019 Jul 15; 7(13):2138-2141. <https://doi.org/10.3889/oamjms.2019.562>

Keywords: Abdominal Aorta; Celiac Trunk; Superior Mesentery Artery; Anterior Inferior Pancreaticoduodenal Artery

***Correspondence:** Adegbenro Omotuyi John Fakoya. Department of Anatomy, University of Medicine and Health Sciences, Basseterre, St. Kitts and Nevis. E-mail: afakoya@umhs-sk.net

Received: 30-Apr-2019; **Revised:** 22-Jun-2019; **Accepted:** 23-Jun-2019; **Online first:** 30-Jun-2019

Copyright: © 2019 Adegbenro Omotuyi John Fakoya, Emilio Aguinaldo, Natalia M. Velasco-Nieves, Erica Barnes, Zachary T. Vandever, Nannette Morales-Marietti, Abayomi Gbolahan Afolabi, Thomas McCracken, Thomas McCracken. This is an open-access article distributed under the terms of the Creative Commons Attribution-NonCommercial 4.0 International License (CC BY-NC 4.0)

Funding: This research was supported by the administration of the University of Medicine and Health Sciences, Basseterre, St. Kitts and Nevis

Competing Interests: The authors have declared that no competing interests exist

BACKGROUND: Many anatomical variations have been associated with the Celiac Trunk, of which most are classified as being asymptomatic.

CASE PRESENTATION: In this article, we describe yet another anatomical variation involving the Celiac Trunk, Superior Mesenteric artery and the Inferior Pancreaticoduodenal Artery during routine cadaveric dissection. We identified a fourth branch of the Celiac trunk (quadrication) that communicated with the Superior Mesenteric artery at the point of origin of the Inferior Pancreaticoduodenal artery which we concluded to be the Anterior Inferior Pancreaticoduodenal artery.

CONCLUSION: This anastomosis could be essential in the case of occlusion between the Celiac Trunk and the Superior Mesenteric artery.

Introduction

Being well-informed of the common variations that occur in the branches of the abdominal aorta decreases the risk of vascular injuries to them during an invasive surgical procedure or other interventional approaches in the abdomen. Among the several identified branching patterns, the most frequently seen branching variations of the abdominal aorta occur at the Celiac Trunk (CT) and Superior Mesenteric Artery (SMA); they are usually asymptomatic [1], [2]. These variations are generally expressed as branches not arising from their known anatomical location and are later classified as an aberrant or accessory vessel.

The CT and the SMA are unpaired branches

of the abdominal aorta which contribute to the abdominal viscera vasculature through a series of anastomoses in the region. The CT, which is the first ventral branch of the abdominal aorta, usually diverge from the level of T12-L1 vertebrae [1], [3] or from the level of T11-T12 vertebrae [4], where it normally gives out three terminal branches also named as Haller's tripod [5]: Common Hepatic Artery, Left Gastric Artery and Splenic Artery. These branches further supply the abdominal viscera derivatives of the foregut. Meanwhile, the SMA, the second ventral branch of the abdominal aorta, emerges from the lower border of the L1 vertebrae to give off branches that supply the abdominal viscera derivatives of the midgut [4].

Common variations of the CT branching pattern have been reported extensively in the

literature [Table 1]. However, another study has shown that the CT and SMA may arise from their normal origins and form a common trunk known as the celiacomesenteric trunk [6].

This case report shows a new branching variation of the CT not yet demonstrated in any literature to the best of our knowledge. It consists of an accessory branch, a communicating artery, arising from the CT and travelling directly into the SMA, in addition to the Haller's tripod. We attempt to explain how this new branching variation may have developmental correlations and impending clinical repercussions.

Table 1: Summary of the Celiac Trunk Branching Patterns Variants reported in the literature

Authors	Branching Pattern Variant	Number of Branches	Year	References
Cicekcibasi AE et al.	Left & Right IPA + LGA + SA + CHA + Left GEA	6	2005	[7]
Nayak SR, et al.	Left IPA + LGA + SA + GDA	4	2008	[7]
Mahajan A, et al.	RPA + LGA + SA + CHA + AHA	5	2009	[7]
Astik RB, Dave UH.	Left SSRA + Left MSRA + LGA + SA + CHA + Right IPA + GDA	7	2011	[7]
Kalthur SG, et al.	LGA + SA + CHA + DPA	4	2011	[7]
D'Souza AS, et al.	LGA + SA + CHA + AHA + APA	5	2012	[7]
Nayak SB, et al.	Left IPA + LGA + SA + CHA	4	2012	[7]
Sathidevi VK, Rahul UR.	LGA + SA + CHA + GDA	4	2013	[7]
Agarwal S, et al.	Left & Right IPA + LGA + SA + CHA + DPA	6	2016	[7]
Prasanna LC, et al.	CHA + GST (CT absent)	2	2016	[8]
Prasanna LC, et al.	CGPT + CHA + SA + LGA (CT absent)	4	2016	[8]
Daescu E et al.	Left IPA + LGA + Right AHA + CHA + SA	5	2017	[9]
Mahajan A, et al.	Left IPA + HGT + SA + CHA	4	2018	[5]
Hemamalini et al.	HMT (CT absent)	1	2018	[10]
Hemamalini et al.	LGA + CHA + SA + MCA	4	2018	[10]
Hemamalini et al.	LGA + CHA + SA + DPA	4	2018	[10]
Hemamalini et al.	LGA + CHA + SA + Left IPA	4	2018	[10]

CT: Celiac Trunk; LGA: Left Gastric Artery; SA: Splenic Artery; CHA: Common Hepatic Artery; IPA: Inferior Phrenic Artery; GEA: Gastroepiploic Artery; GDA: Gastrooduodenal Artery; DPA: Dorsal Pancreatic Artery; AHA: Accessory Hepatic Artery; APA: Accessory Pancreatic Artery; SMA: Superior Mesenteric Artery; cA: communicating artery; GST: Gastrosplenic trunk; CGPT: Common Gastrophrenic Trunk; HGT: Hepatogastric Trunk; HMT: Hepatomesenteric Trunk; MCA: Middle Colic Artery; HST: Hepatosplenic Trunk; RPA: Retroportal Artery; SSRA: Superior Suprarenal Artery; MSRA: Middle Suprarenal Artery.

Case Report

A routine cadaveric dissection of the abdomen of a 78-year-old Caucasian male cadaver by medical students at the Anatomy laboratory, University of Medicine and Health Sciences, St. Kitts & Nevis revealed a cadaveric dissection with a CT

quadrification anomaly. The dissection revealed the CT branches: Common Hepatic artery, Left Gastric artery and Splenic artery following their normal anatomical courses. Further exploration of the CT vessels revealed an additional branch which continued into the SMA with exploration.

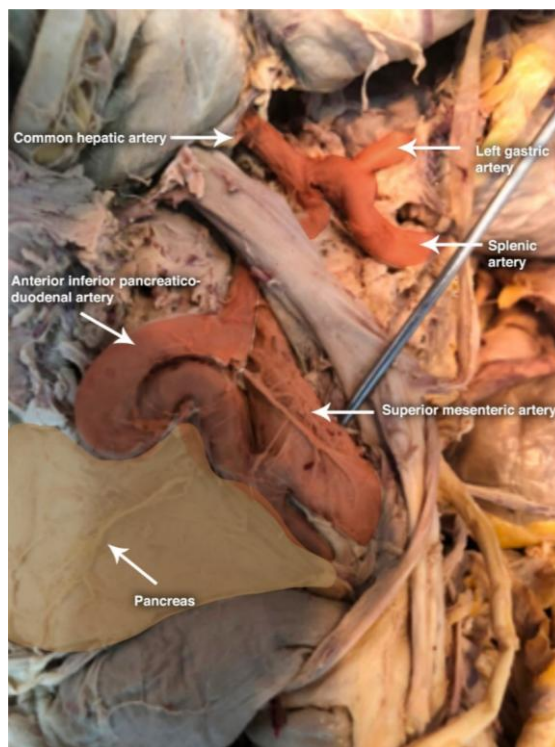


Figure 1: This figure shows the abnormal communication between the Celiac trunk (CT) and the Superior Mesenteric Artery (SMA), named the Anterior Inferior Pancreaticoduodenal Artery (AIPA)

This aberrant large vessel began at the Celiac Trunk and travelled inferiorly to communicate with the SMA at the region where the Inferior Pancreaticoduodenal artery branches off between the pancreas and the duodenum.

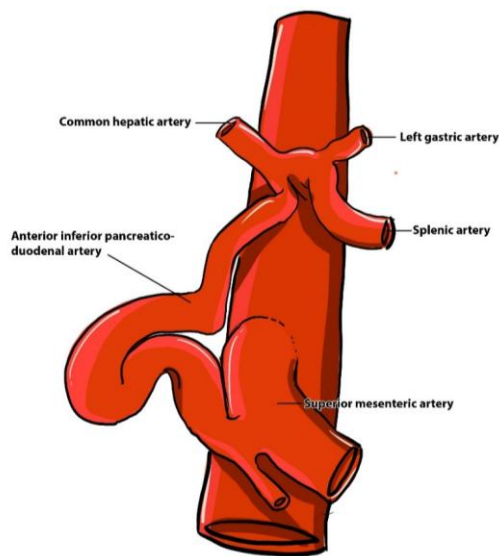


Figure 2: Schematic of the aberrant communicating Anterior Inferior Pancreaticoduodenal Artery (AIPA) with the Celiac trunk (CT)

Careful dissection revealed no other artery branching out within this region to supply the inferior part of the pancreas. With careful cleaning out of this aberrant communicating artery, we observed a bifurcation into anterior and posterior branches with the posterior branch running posteriorly to the pancreas to supply it. Thus, we concluded that the aberrant communicating artery was indeed the Anterior Inferior Pancreaticoduodenal artery (AIPA). Usually, the communication of the Inferior Pancreaticoduodenal artery is with the Superior Pancreaticoduodenal artery, a branch of the Gastroduodenal artery, which in turn is a branch of the Common Hepatic artery.

Discussion

The CT is the first of the three major branches of the abdominal aorta, which also includes the Superior Mesenteric and Inferior Mesenteric arteries, the CT branches off the Aorta at the T12/L1 level [11]. The CT is responsible for the blood supply to the lower part of the oesophagus, the stomach, the proximal duodenum, the liver and the pancreas, designated as the fore-gut [11].

The SMA bifurcates from the Abdominal Aorta at the level of L1 and is approximately 1 cm inferior to the celiac trunk. The SMA branches into the Inferior Pancreaticoduodenal, Intestinal, Middle colic, Right colic, and Ileocolic arteries. These arteries supply oxygenated blood to the jejunum and ileum [11].

The SMA is responsible for several looping and terminal branches in the middle abdominal area. These looping branches include the arterial arcades and vasa recta that supply the jejunum and ileum. The terminal branches include the Ileocolic artery that supplies the cecum and the Appendicular artery that supplies the appendix [11].

The development of both the CT and SMA are formed when the two dorsal aortas fuse and create one dorsal aorta by the middle of week five. The SMA is from the vitelline artery [12]. The lack of proper differentiation of the ventral segmental arteries that form the Celiac, Superior Mesenteric, and Inferior Mesenteric arteries most likely caused the abnormality observed in this cadaver.

CT abnormalities are quite common and have been categorized accordingly. Of the abnormalities that can occur in the celiac trunk, the least common is quadrification (8.33%) [13] of the artery, in which it has four branches.

Although there are many documented abnormal branches of the celiac artery as stated in the article by Alsharif et al., 2016 [14], there are very few documented cases of a connecting communicating

artery between the Celiac and Superior Mesenteric arteries as seen in the gross dissection of our cadaver.

Our cadaver presented with a communicating artery between the CT and the SMA. As discussed in the case report by Santos et al., 2018, there are many different variations that can be seen within the CT. Although CT variations are rather common, it is important to understand the different possibilities [13]. This qualification variation of the CT has not been documented before in any literature. The abnormal communication believed to be the AIPA is normally a small branch coming off the SMA with the Posterior Inferior Pancreaticoduodenal artery and supplies the lower head of the pancreas and anastomoses with the Superior Pancreaticoduodenal artery, which is, in turn, a branch of the Gastroduodenal artery. This aberrant communication was, however, abnormally large as well as the other abdominal vessels. This could be ascribed to a background vascular developmental problem. The size of the AIPA could have provided a significant anastomosis between the CT and SMA. This anastomosis would have been able to allow a more than normal blood flow from the CT directly to the SMA, which would be beneficial in some cases and detrimental in others. This anastomosis could allow for adequate blood supply to the SMA and the rest of the abdominal aorta if there were ever an occlusion in between the CT and SMA. However, this increased diameter of the AIPA could cause some relative ischemia to the organs supplied by the CT as some of the blood flow could be sent down this large bored AIPA instead of organs of the foregut. According to Santos et al., 2018 [13], being aware of the CT variations is important for surgeons during many procedures involving the arteries of the CT. These procedures range from laparoscopic surgery, hepatic transplantation, and abdomen trauma or lesions. Abnormalities in the CT, especially one of this rarity, may increase both the difficulty and the risk of radical surgical procedures.

In conclusion, knowledge of CT structure variations is important to clinicians in planning for surgical procedures. The quadrification of the CT with a communicating branch considered to be the AIPA of the SMA is a novel anatomical malformation never reported in the literature. This anastomosis is a potential alternative blood source in the case of occlusion between the CT and SMA. Of importance is how this aberrant communicating branch might have affected blood flow distribution within the foregut and midgut of the body. Fluid dynamics suggests that there should be generally decreased blood output to the organs supplied by the CT, secondary to this split. However, in vivo measurement of arterial blood flow to individual organs is needed to confirm this. Consequently, further research could look deeper into a global study of CT variations and the resultant blood flow in vivo using ultrasonic or electromagnetic techniques.

References

- Rachana K, Madhyastha S, Saralaya V, Joy T, Premchandran D, Rai S. Rare variation in arterial branching of the celiac trunk with three aberrant hepatic arteries - Case report. *Journal of Morphological Sciences*. 2014; 31(02):114-117. <https://doi.org/10.4322/jms.067114>
- Nayak S, Prabhu L, Krishnamurthy A, Kumar C, Ramanathan L, Acharya A et al. Additional branches of celiac trunk and its clinical significance. *Romanian Journal of Morphology & Embryology*. 2008; 49(2):247-249.
- Hemamalini. Variations in the branching pattern of the celiac trunk and its clinical significance. *Anatomy & Cell Biology*. 2018; 51(3):143. <https://doi.org/10.5115/acb.2018.51.3.143> PMID:30310705 PMCID:PMC6172596
- Pinal-Garcia D, Nuno-Guzman C, Gonzalez-Gonzalez M, Ibarra-Hurtado T. The Celiac Trunk and Its Anatomical Variations: A Cadaveric Study. *Journal of Clinical Medicine Research*. 2018; 10(4):321-329. <https://doi.org/10.14740/jocmr3356w> PMID:29511421 PMCID:PMC5827917
- Mahajan A, Tiwari S, Mishra S. A unique conglomeration of variations in the celiac, hepatic, and superior mesenteric artery: A clinico-embryological perspective. *International Journal of Applied & Basic Medical Research*. 2018; 8(4):256-258.
- Momeni M, Farghadani M, Hekmatnia A, Momeni F, Mahdavi M. Anatomical variation of celiac axis, superior mesenteric artery, and hepatic artery: Evaluation with multidetector computed tomography angiography. *Journal of Research in Medical Sciences*. 2016; 21(1):129. <https://doi.org/10.4103/1735-1995.196611> PMID:28331515 PMCID:PMC5348823
- Agarwal S. Unusual Variation in the Branching Pattern of the Celiac Trunk and Its Embryological and Clinical Perspective. *Journal of Clinical and Diagnostic Research*. 2016. <https://doi.org/10.7860/JCDR/2016/19527.8064> PMID:27504274 PMCID:PMC4963634
- Prasanna C, Alva R, Sneha G, Bhat K. Rare variations in the Origin, Branching Pattern and Course of the Celiac Trunk: Report of Two Cases. *Malays J Med Sci*. 2016; 23(1):77-81.
- Dăescu E, Sztika D, Lăpădatu A, Zăhoi D. Rare variant of celiac trunk branching pattern associated with modifications of hepatic arterial vascularization. *Rom J Morphol Embryol*. 2019; 58(3):969-975.
- Hemamalini. Variations in the branching pattern of the celiac trunk and its clinical significance. *Anatomy & Cell Biology*. 2018; 51(3):143. <https://doi.org/10.5115/acb.2018.51.3.143> PMID:30310705 PMCID:PMC6172596
- Bookshelf. Bookshelf Online [Internet]. Bookshelf.vitalsource.com, 2019.
- Pansky B. Review of medical embryology. Macmillan; 1982.
- Santos P, Barbosa A, Targino V, Silva N, Silva Y, Barbosa F, et al. Anatomical Variations of The Celiac Trunk: A Systematic Review. *ABCD Arquivos Brasileiros de Cirurgia Digestiva*. 2018; 31(4). <https://doi.org/10.1590/0102-672020180001e1403> PMID:30539978 PMCID:PMC6284376
- Alsharif M, Taha K, Elamin A, Al-Dosari K. Behavioral Anatomy of the Celiac Trunk Based on Human Embryology. *British Journal of Medicine and Medical Research*. 2016; 14(11):1-7. <https://doi.org/10.9734/BJMMR/2016/23879>