

A Rare Case of Partial Peripheral Thyroid Hormone Resistance Due to a Point Mutation in the Membrane Integrin A(V)B(3) and Concomitant Hashimoto's Thyroiditis

Martina Savovska^{1*}, Sinisa Stojanovski², Nevena Manevska²

¹Medical Faculty, Ss Cyril and Methodius University of Skopje, Skopje, Republic of Macedonia; ²Institute for Pathophysiology and Nuclear Medicine "Isak Tadzer", Medical Faculty, Ss Cyril and Methodius University of Skopje, Skopje, Republic of Macedonia

Abstract

Citation: Savovska M, Stojanovski S, Manevska N. A Rare Case of Partial Peripheral Thyroid Hormone Resistance Due to a Point Mutation in the Membrane Integrin A(V)B(3) and Concomitant Hashimoto's Thyroiditis. Open Access Maced J Med Sci. <https://doi.org/10.3889/oamjms.2019.582>

Keywords: peripheral resistance; hypothyroidism; secondary hyperthyroidism; Hashimoto's thyroiditis

***Correspondence:** Martina Savovska, Medical Faculty, Ss Cyril and Methodius University of Skopje, Skopje, Republic of Macedonia. E-mail: m.savovska98@gmail.com

Received: 27-May-2019; **Revised:** 26-Jun-2019; **Accepted:** 27-Jun-2019; **Online first:** 29-Jun-2019

Copyright: © 2019 Martina Savovska, Sinisa Stojanovski, Nevena Manevska. This is an open-access article distributed under the terms of the Creative Commons Attribution-NonCommercial 4.0 International License (CC BY-NC 4.0)

Funding: This research was financially supported by the Scientific Foundation SPIROSKI, Skopje, Republic of Macedonia

Competing Interests: The authors have declared that no competing interests exist

BACKGROUND: Peripheral resistance to thyroid hormones is a type of unresponsiveness of the peripheral cells or tissues to FT3 and/or FT4. Generalised resistance to thyroid hormones affects the pituitary gland and most of the peripheral tissues. Selective pituitary resistance or central resistance to thyroid hormones include unresponsiveness of the pituitary gland, but the peripheral tissues are responsive. Selective peripheral resistance involves peripheral tissue or cellular resistance to thyroid hormones, but the pituitary gland is responsive.

CASE PRESENTATION: We present a rare case of a female patient with partial peripheral resistance to thyroid hormones due to a point mutation coding for the beta subunit of the integrin molecule $\alpha(V)\beta(3)$ and concomitant Hashimoto's thyroiditis. Clinically, the patient's symptoms were in favour of hypothyroidism, and the laboratory results were in favour of the secondary hyperthyroid state. PCR protein amplification detected a point mutation coding for the membrane receptor, which mediates a signal via the MAPK pathway when bonded with thyroid hormones.

CONCLUSION: Peripheral resistance to thyroid hormones is a very rare condition and can often be misdiagnosed due to the broad spectrum of clinically similar differential diagnostic entities. Molecular analysis is required to confirm the exact underlying cause for the impaired peripheral sensitivity to thyroid hormones syndrome.

Introduction

Thyroid hormones, peptide-like in structure but both peptide-like and steroid-like in function, are indispensable for normal fetal development and responsible for the regulation of the tissues basal metabolism. The bioactive form at the cellular level is T3/FT3 (triiodothyronine/free triiodothyronine), a final product of the processes of the outer ring deiodination of the prohormone T4/FT4 (tetraiodothyronine/free tetraiodothyronine). Selenoenzymes (deiodinases) perform this peripheral conversion [1]. Even though

the structure of the thyroid hormones is peptide in nature (two iodotyrosine components are fused into one thyronine molecule), the peripheral effects are expressed or mimic the activity of both peptide-like hormones (via the membrane receptors or membrane transporter proteins and consecutive second messenger cascade activation) and steroid-like hormones (via the nuclear receptors and binding to hormone response elements (HREs) with consecutive induction of transcription and gene expression modulation) [2].

The nuclear receptors or thyroid hormones (THR) are presented in two different protein forms a

and β , encoded by the THRA and THRB genes located at chromosomes 3 and 17, respectively. Their tissue distribution is not equal, as they undergo splicing at several points and are positioned at different locations in the body. The main isoforms of the THR responsible for mediating cell response when bound to thyroid hormones are THR α 1 – widely expressed in the bones, skeletal and cardiac muscles, THR β 1 – expressed in the kidneys, brain, liver, and THR β 2 – expressed in the anterior pituitary, hypothalamus, and retina [3].

Thyroid hormone deficit (hypothyroidism) is not clinically manifested for a few months, even after total thyroidectomy being performed, mostly due to their steroid-like actions (induction of transcription and gene expression modulation) and also due to the release of free hormones fractions from the total hormones fractions bound to the specific hormone carriers: prealbumin, albumin or thyroxine-binding globulin (TBG). The fractions of thyroid hormones bound to their carriers are termed as circulating "thyroid hormone reserve" or total hormone fractions (TT4 and TT3), and those that circulate unbound in the bloodstream are referred to as free hormone fractions (FT4 and FT3). The peripheral cellular and tissue effects of thyroid hormones are mostly due to the levels and actions of the free hormone fractions [4].

Peripheral resistance to thyroid hormones is a type of unresponsiveness of the peripheral cells or tissues to FT3 and/or FT4. Thyroid hormone resistance (RTH) in general, or sometimes called as Refetoff syndrome, is a condition where thyroid hormone levels are elevated and fail to suppress the production of TSH (fully or partially) at the level of the pituitary gland. Refetoff et al. suggested using a new nomenclature referring to the condition as "impaired sensitivity to thyroid hormones" [5]. It can occur in several forms. Generalised resistance to thyroid hormones (GRTH), which is affecting the pituitary gland and most of the peripheral tissues, is usually consistent with a clinically euthyroid state but with elevated T3 and T4 levels in the blood, as well as high or normal TSH. Selective pituitary resistance or usually termed as central resistance to thyroid hormone (CRTH or PRTH), includes unresponsiveness of the pituitary gland to thyroid hormones, but the peripheral tissues are responsive. It is manifested with elevated serum thyroid hormone levels, and normal or elevated TSH levels, but the peripheral tissues experience an abnormal influx of thyroid hormones and is clinically associated with symptoms of hyperthyroidism. Selective peripheral resistance to thyroid hormone (PerRTH) involves peripheral tissue or cellular resistance to thyroid hormones, but the pituitary gland is responsive. Clinically the patients present symptoms typical for hypothyroidism, which usually does not correlate with the circulating hormone levels – elevated TSH, FT3, and FT4 [5].

Integrins are part of the transmembrane proteins family that are involved in the processes of adhesion between the cells and the extracellular matrix termed intercellular adhesion molecules (ICAMs). Generally, they recognise a tripeptide Arg – Gly – Asp (RGD) binding site when connected to their ligands. A typical integrin molecule is built by two non covalently connected glycoprotein subunits α and β , respectively [6]. The structure of the integrins encompasses unique heterodimers with an immense variety of ligand recognition, bondage, and response. Overall, they are built by at least eighteen α and eight β subunits, which are afterwards subgrouped depending on their specific role and tissue distribution. The most typical forms of integrin association include the β 1 integrins, β 2 integrins, and α v-containing integrins [7].

The integrin, α (V) β (3), is a heterodimer made up by an α (V) (also called CD51, MSK8, vitronectin receptor α (VNR α)) 1048 long amino acid sequence located on chromosome 2q31.32, and β (3) (also called CD61, GP3A, GPIIIa, platelet glycoprotein IIIa) with 788 long amino acid sequence, located on chromosome 17q21.32 [7]. Furthermore, the extracellular portion of the integrin consists of multiple domains, including RGD-recognizing site. It is widely distributed in the body, and upon binding to a specific ligand, it mediates a secondary intracellular response that modulates the cellular activity. Ligands for this specific integrin encompass: fibrinogen, vitronectin, vWF, thrombospondin, fibrillin, tenascin, PECAM-1, fibronectin, osteopontin, BSP, MFG-E8, ADAM-15, COMP, Cyr61, ICAM-4, MMP, FGF-2, uPA, uPAR, L1, angiostatin, plasmin, cardiotoxin, LAP-TGF- β , Del-1, including thyroid hormone peripheral recognition and bondage as well [8].

Case Presentation

A 36 years old female patient, I.I. was referred for evaluation of the function of the thyroid gland. The anamnesis gave information about a high degree of education, no children and a positive family history of hypothyroidism due to Hashimoto's thyroiditis in mother and sister. She presented symptoms and clinical signs that pointed towards a hypothyroid state such as recent weight gain, constipation, dryness of hair and fickle nails, but mostly, inability to do her daily routine due to feeling tired and sleepy all the time. A recent progressive swelling in the neck that resulted in having swallowing difficulties was also highlighted. There were no previous records of her having any thyroid hormone dysregulation, so a thyroid function laboratory panel was ordered in June 2015. The results presented extremely high levels of TSH, along with elevated FT3, FT4, TT3, and TT4. A biochemical laboratory panel that was typical for a severe possible

secondary hyperthyroid state (Table 1).

Table 1: Biochemical laboratory results

	Reference value	Patients results
TSH	0.4 - 4.0 mIU/L	>75 mIU/L
FT3	3.5 - 7.8 pmol/L	30.7 pmol/L
FT4	11 - 25 pmol/L	> 60 pmol/L
TT3	0.9-1.9 nmol/L	2.34 nmol/L
TT4	71-141 nmol/L	203 nmol/L
TGL	<1.7 mmol/L	3.65 mmol/L
Cholesterol	<5.5 mmol/L	6.6 mmol/L
Fe	17-30 micromol/L	2.9 micromol/L
Hgb	13.5 - 17.5 g/dL (m) 12 - 15.5 g/dL (f)	8.6 g/dL
Prealbumin	150 - 360 mg/L	213 mg/L
Albumin	3.3-5.7 g/dL	4.1 g/dL
TBG	150-360 nmol/ml	256 nmol/ml
aTPO	>35 IU/mL	>1000 IU/mL
aTg	>20 IU/mL	>3000 IU/mL
Prolactin	1.9-25 ng/ml	14.3 ng/ml
Progesterone	Follicular phase: 0,10-1,13; Ovulation: 0.48 - 1,72; Post menopause: 0.36 -1,0; On oral contraceptives: 0.34-0.90 ng/ml	> 0.2 ng/ml
SHBG	15 - 100 nmol/L	19,57 nmol/L
Estrogen	Follicular phase: 26.5-160; Ovulation: 186 - 400; Post menopause: >30; On oral contraceptives: >102 pg/ml	55.0 pg/ml
FSH	Follicular phase: 1.98-11.3; Ovulation: 7.5 - 21; Post menopause: 9.7 - 111; On oral contraceptives: 1.7- 4.9 mIU/L	3.88 mIU/L
LH	Follicular phase: 1,1-11.6; Ovulation: 17-77; Post menopause: 11,3-39.8; On oral contraceptives: 0.5-8.0 mIU/L	5.57 mIU/L
Estradiol	26.5-160 pg/mL	55 pg/mL
CK	24-173 U/L	178 U/L

Clinically, the patient's symptoms were in favour of hypothyroidism, which did not correlate with the laboratory results in favour of possible secondary hyperthyroid state or maybe hashitoxicosis.

The ultrasonography of the thyroid gland (performed on Phillips H.D. 6, Version 1.1, probe 7,5 Hz) gave information about an enlarged, nonhomogeneous thyroid gland with hypoechoic structure, initial fibrosis and visible pseudonodules (Fig. 1).

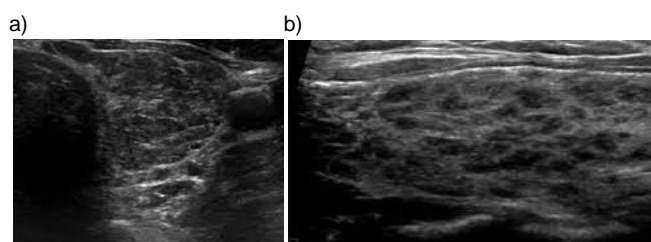


Figure 1: An ultrasonographic cross-sectional and longitudinal image of the thyroid gland presenting a nonhomogeneous thyroid gland with hypoechoic structure and pseudonodules

Fine needle aspiration biopsy (FNAB) was conducted for a cytopathological examination (H&E staining) due to the presence of pseudonodules on ultrasonography. The results pointed towards the presence of prominent germinal follicles with active germinal centres, lymphocytic infiltration, oncocytic cells with Hurthle cell metaplasia, and initial fibrosis. These findings in correlation with the high aTPO and aTg laboratory values revealed underlying (previously unsuspected) Hashimoto's thyroiditis – interpreted by

the pathologist as group III by the BETHESDA system of classification (Fig. 2).

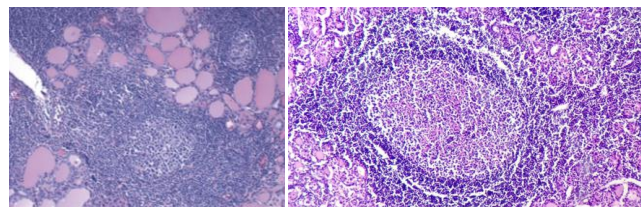


Figure 2: Microscopic features of the FNAB presenting germinal centres and lymphocytic infiltration - Hashimoto's thyroiditis

Thyroid scintigraphy performed with ^{99m}Tc -pertechnetate (185 MBq/5 mCi tracer activity, images obtained 30 min post-injection on dual-headed gamma camera MEDISO DHV Nucline Spirit, with 140 keV photopeak and low-energy, high resolution (LEHR) parallel collimator) was the following step. The patient's thyroid gland was enlarged with increased tracer accumulation intensity in favour of hyperthyroidism caused by the elevated TSH levels (Fig. 3).

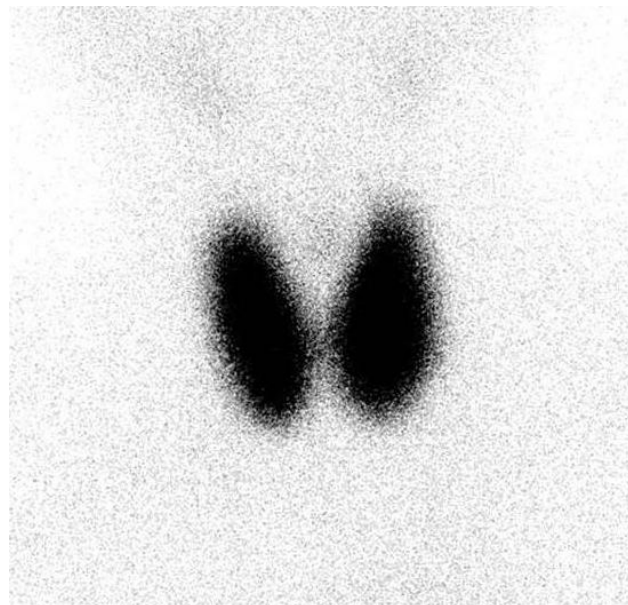


Figure 3: Thyroid scintigraphy with ^{99m}Tc -pertechnetate presenting diffusely increased tracer accumulation

An MRI study followed, and the pituitary gland was visualised as normal, in a standard and additional sequences, in a native and post contrast study series and the suspicion for possible adenoma (TSH-oma) of the pituitary gland was ruled out (Fig. 4).

To combine the anatomical examinations with functional ones, to exclude or to confirm the possible differential diagnosis, a TRH test and T3 suppression test were also conducted.

The TRH stimulation test included administration of small amounts of TRH intravenously, following which levels of TSH were measured at several subsequent points (15-30 minutes post-

injection) using samples of blood taken from a peripheral vein. Before the test, TRH levels were measured and were slightly suppressed. The test was performed to differentiate the possible abnormality in the hypothalamus-pituitary axis. The results presented an increase in TSH levels.

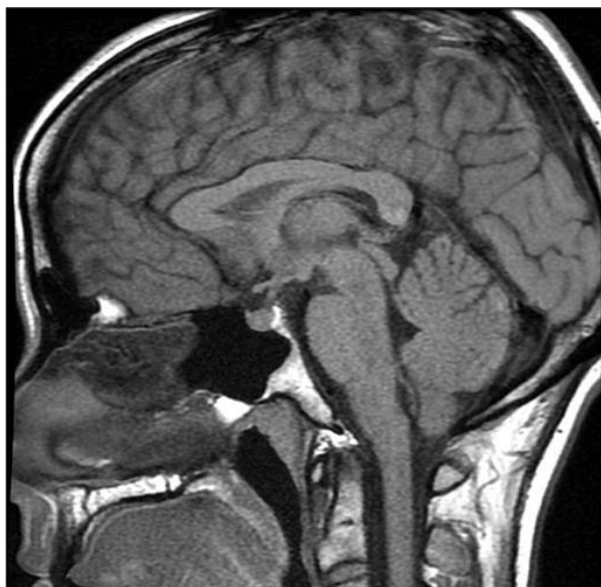

Figure 4: Normal MRI study of the pituitary gland

Considering the T3 suppression test, T3 was given to the patient during whom TSH levels were measured. In our case, the levels of TSH remained high.

With rT3 levels within the normal range and a normal FT4 to FT3 conversion, deiodinase enzyme abnormality and selenium deficiency were excluded.

PCR protein amplification was afterwards ordered for the class of integrins $\alpha(V)\beta(3)$, involved in T3 bondage and signal transduction. It presented a point mutation coding for the beta subunit of the membrane receptor molecule, which was later confirmed to be the exact reason for the impaired sensitivity to thyroid hormones syndrome (ISTHS) in the patient (Fig. 5).

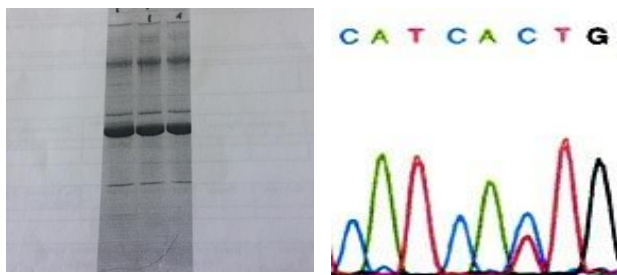


Figure 5: PCR presenting point mutation

The patient was prescribed substitution therapy of 50 $\mu\text{g}/\text{day}$ of levothyroxine sodium and is regularly followed on check-ups up to date, adjusting

the dosage of the therapy depending on the clinical signs and symptomatology of the patient.

Discussion

The presented case is part of the broad spectrum of impaired sensitivity to thyroid hormones syndrome - ISTHS or to be more precise a rare partial peripheral resistance to thyroid hormones due to a point mutation coding for the beta subunit of the integrin molecule $\alpha(V)\beta(3)$. The ISTHS has an incidence of 1:40000 and usually the underlying cause is due to different thyroid hormone receptors mutations. Several case reports have been previously published in the literature with various types of mutations in question featuring a broad spectrum of unusual and misleading clinical and biochemical manifestations [9], [10], [11], [12].

Our patient was admitted with a recently formed goitre which in correlation with her ultrasonography findings (enlarged thyroid gland with hypoechoic structure and fibrosis - most likely due to Hashimoto thyroiditis) and the clinical symptoms of hypothyroidism, pointed towards the decreased activity of the thyroid gland as the probable initial diagnosis. A hormone panel typical for secondary hyperthyroidism, with extremely high TSH, FT4, and FT3, also with the accented presence of aTPO and aTg (indicating an autoimmune component to the condition - in favour of Hashimoto thyroiditis) was obtained. Also, the patient had elevated creatine kinase (CK) levels, high cholesterol, and triglyceride levels (pointing towards dyslipidemia), which along with the iron deficiency anaemia (very low iron and haemoglobin levels) indicated a hypothyroid metabolic state. The symptoms presented by the patient, together with the detected dyslipidemia, anaemia and elevated CK levels were in favour of hypothyroidism, which did not correlate with the thyroid biochemical panel which was in favor of the secondary hyperthyroid laboratory state [13], [14], [15].

The cellular architectonic of the tissue provided via the FNAB (due to the pseudonodules detected on the US) correlated with the elevated antibody levels. Adding the information of the positive family history of hypothyroidism in mother and sister (due to Hashimoto thyroiditis) gave rise to the differential diagnosis of a possible primary hypothyroid diagnostic entity with autoimmunity in nature - Hashimoto's thyroiditis in the initial phase of hashitoxicosis.

The diagnostic dilemma of the pathological thyroid hormone panel, which did not correlate with the patient's symptoms, the underlying Hashimoto thyroiditis, and the metabolic biomarkers, remained unclear mostly due to the still unexplained reason for

elevated TSH levels. Additionally, the results of the thyroid scintigraphy presented information about an enlarged in volume and hyperactive thyroid gland with diffusely increased intensity of tracer accumulation. This result confirmed the prolonged TSH hyperstimulation effect on the thyroid gland tissue, correlated with the elevated FT4, FT3, TT4, and TT3 levels and did not exclude the presence of possible secondary hyperthyroidism [16].

To resolve the underlying reason that might have been responsible for the high TSH levels, an MRI imaging was performed, focusing on sella turcica and the pituitary gland. Anatomically sound pituitary at native and post-contrast slice series was visualised. The possible presence of autonomous hyperfunctional pituitary adenoma (TSH-oma) was excluded. ISTHS can be misleading and very difficult for diagnostic differentiation from autonomous TSH-producing adenomas of the pituitary gland. Clinically, the patients with TSH-omas are usually hyperthyroid, and the ISTHS patients present euthyroid or hypothyroid clinical features, but both entities have a similar or almost identical thyroid functional laboratory profile. Teng X et al. have published a rare case of concomitant TSH-oma and peripheral resistance to thyroid hormones, which was not the case with our patient [17].

To confirm or exclude the malfunctioning of the negative feedback loop, functional tests were performed. The TRH test gave important and relevant information. It revealed a normally responsive pituitary gland (TSH levels increased) by exogenous stimulation with TRH.

T3 suppression test, on the other hand, proved that neither the hypothalamus nor the pituitary gland responded to the exogenous elevated T3 values with decreasing the secretion of TSH and/or TRH, as normally would have been expected. In turn, TSH levels remained high despite the addition of T3, which indicated for the first time the presence of possible impaired responsiveness of the peripheral tissues to thyroid hormones. This also confirmed that the central regulation of the hypothalamus-pituitary gland-thyroid gland axis was sound.

Thyroid hormones are normally transported in the bloodstream bound with specific hormone carriers such as albumin, prealbumin, and thyroid binding globulin (TBG). Only a small amount of the total hormone release in the circulation is present in its free form, and that fraction is responsible for their peripheral effect manifestations. Abnormal protein bondage could be the reason for a euthyroid hyperthyroxinemia, as seen as in thyroid binding globulin (TBG) excess or familial dysalbuminemic hyperthyroxinemia (FDH) [18]. But in these conditions, the patients usually have normal TSH levels and are euthyroid considering the clinical symptoms. Furthermore, our patient had normal protein carrier levels. Also, the estrogen levels in the patient were

very low, which in turn was contradictory to the normal protein carrier levels since estrogen is the hormone which influences the regulation of their levels.

Thyroid hormone cell membrane transport defect (THCMTD) [19] refers to an abnormality of the MCT8 (monocarboxylate transporter 8), responsible for the cellular transport of the thyroid hormones so that they can express their effect when binding to nuclear receptors. They are mostly found in the brain and liver. But a mutation of the MCT8 generally affects males, since it is X chromosome-linked. Also, patients with MCT8 mutations usually show symptoms of hormone deficiency in the organs in which they are mostly distributed. In our patient, there were neither cognitive nor mental disabilities, which were supported by the fact of her reaching a high level of education. Also, MCT8 abnormality would have presented itself with an elevated T3 level, but low rT3 level, low T4 level and normal or slightly elevated TSH level [20]. Reverse T3 (rT3) levels in our patient were normal, with elevated T4 and TSH, as stated previously.

Thyroid hormone metabolism defect (THMD) refers to the abnormal deiodinase activity, due to a defect in the enzyme itself (qualitative or quantitative) or a condition of selenium deficiency as an essential cofactor of the enzyme. Considering these two, our patient had normal rT3 levels and obvious peripheral conversion of FT4 into FT3. Selenium deficiency presents itself with high TSH and T4 levels, but low T3 levels due to absent conversion [1]. This was not something that we diagnosed in our patient.

There are 3 types of deiodinase enzymes. Deiodinase I is present in the kidney, liver, thyroid and is responsible for 80% of the circulating T3, converted from T4. In this manner, any abnormal deiodinase I activity would have given low T3 levels - also not something we could see in our patient. Deiodinase II is found mostly in the pituitary gland, generally in the central nervous system, and is predominantly found inside the cell. In the pituitary gland, it mediates the negative feedback loop from the thyroid hormone levels. If an abnormality is present in this type of deiodinase, it will give rise to high values of rT3 and TSH, due to a lack of pituitary suppression of TSH production. Deiodinase III, found in CNS, placenta, etc., is responsible for converting T3 and T4 to its inactive form rT3. The decreased activity would result in low rT3 levels - something that was not present in our patient.

Considering the above-mentioned diagnostic analysis performed in our patient, we were able to confirm that the thyroid hormones could enter the cell, had a proper conversion to T3 and rT3 accordingly and that the patient had a weak, but yet an existing response to peripheral effects of the thyroid hormones. Though their effects had been progressively decreasing as of lately, most probably due to the development of the Hashimoto's thyroiditis

(impaired thyroid hormone production at primary level) in the patient, we considered the possibility of present congenital qualitative or quantitative abnormality in the membrane receptor - the integrin $\alpha(V)\beta(3)$. Therefore this receptor became the target for the PCR amplification technique as the final diagnostic procedure performed to conclude the exact patient diagnosis.

The PCR results revealed the diagnosis of impaired sensitivity to thyroid hormones syndrome (ISTHS). A point mutation coding for the beta subunit of the integrin molecule $\alpha(V)\beta(3)$ was the reason why the patient's peripheral tissues were metabolically hypothyroid with high T3/FT3 and T4/FT4 circulating levels [21]. This qualitative change in the structure prevented its normal responsiveness to thyroid hormone stimulus, and its peptide-like action, except in very high quantities of the hormones present. It also resulted in absent suppression of TSH secretion from the pituitary - with extremely high TSH levels, but with near normal or slightly suppressed TRH due to the suppression of the hypothalamus from the elevated TSH. The treatment of the patient was by her symptomatology - substitutional therapy, but not focused on lowering the T4 and T3 levels.

In conclusion, peripheral resistance to thyroid hormones is a very rare condition and can often be misdiagnosed due to the broad spectrum of possible similar differential diagnostic entities. Molecular diagnostic procedures are usually required to confirm the exact underlying cause for the ISTHS. The definitive diagnostic algorithm should include not only the biochemical parameters but also the clinical patient's symptomatology, especially in cases where there is a miss match between those above.

Acknowledgements

The paper was awarded the Best Case Report Presentation at the 42. International Medical Congress, May 27-29, 2019, Ohrid, the Republic of Macedonia by the Scientific Foundation SPIROSKI, Skopje, Republic of Macedonia.

References

- Bianco, AC, Kim BS. Pathophysiological relevance of deiodinase polymorphism. *Curr Opin Endocrinol Diabetes Obes.* 2018; 25(5):341-346.
- Singh BK, Sinha RA, Yen PM. Novel transcriptional mechanisms for regulating metabolism by thyroid hormone. *Int J Mol Sci.* 2018; 19(10): 3284. <https://doi.org/10.3390/ijms19103284> PMID:30360449 PMCID:PMC6214012
- Cyril S. Anyetei-Anum, Vincent R. Roggero, Lizabeth A. Allison. Thyroid hormone receptor localization in target tissues. *J Endocrinol.* 2018; 237(1):19-34. <https://doi.org/10.1530/JOE-17-0708> PMID:29440347 PMCID:PMC5843491
- Rohit A. Sinha, Brijesh K. Singh, Paul M. Yen. Direct effects of thyroid hormones on hepatic lipid metabolism. *Nat Rev Endocrinol.* 2018; 14(5):259-269. <https://doi.org/10.1038/nrendo.2018.10> PMID:29472712 PMCID:PMC6013028
- Refetoff S. et al. Classification and Proposed Nomenclature for Inherited Defects of Thyroid Hormone Action, Cell Transport, and Metabolism. *Thyroid.* 2014; 24(3):407-409. <https://doi.org/10.1089/thy.2013.3393.nomen> PMID:24588711 PMCID:PMC3950730
- Takada Y, Ye X, Simon S. The integrins. *Genome Biology.* 2007; 8:215. <https://doi.org/10.1186/gb-2007-8-5-215> PMID:17543136 PMCID:PMC1929136
- Leith JT, Mousa SA, Hercbergs A, Lin HY, Davis PJ. Radioreistance of cancer cells, integrin $\alpha v \beta 3$ and thyroid hormone. *Oncotarget.* 2018; 9(97):37069. <https://doi.org/10.18632/oncotarget.26434> PMID:30651936 PMCID:PMC6319341
- Krashin E, Piekiełko-Witkowska A, Ellis M, Ashur-Fabian O. Thyroid hormones and cancer: A comprehensive review of preclinical and clinical studies. *Frontiers in endocrinology.* 2019;10. <https://doi.org/10.3389/fendo.2019.00059> PMID:30814976 PMCID:PMC6381772
- Weiss RE, Weinberg M, Refetoff S. Identical mutations in unrelated families with generalized resistance to thyroid hormone occur in cytosine-guanine-rich areas of the thyroid hormone receptor beta gene. Analysis of 15 families. *J Clin Invest.* 1993; 91(6): 2408-2415. <https://doi.org/10.1172/JCI116474> PMID:8514853 PMCID:PMC443299
- McDermott MT, Ridgway EC. Thyroid hormone resistance syndromes. *Am J Med.* 1993; 94 (4): 424-432. [https://doi.org/10.1016/0002-9343\(93\)90155-1](https://doi.org/10.1016/0002-9343(93)90155-1)
- Dumitrescu AM, Refetoff S. The syndromes of reduced sensitivity to thyroid hormone. *Biochim Biophys Acta.* 2013; 1830(7): 3987-4003. <https://doi.org/10.1016/j.bbagen.2012.08.005> PMID:22986150 PMCID:PMC3528849
- Gonçalves AP, Aragúes JM, Nobre E, Barbosa AP, Mascarenhas M. A case of thyroid hormone resistance: a rare mutation. *Arq Bras Endocrinol Metabol.* 2014; 58(9): 962-966. <https://doi.org/10.1590/0004-2730000003297> PMID:25627054
- Fan W, Tandon P, Krishnamurthy M. Oscillating hypothyroidism and hyperthyroidism - a case-based review. 2014. *J Community Hosp Intern Med Perspect.* 2014; 4 (5): 10. <https://doi.org/10.3402/jchimp.v4.25734> PMID:25432652 PMCID:PMC4246140
- Wong M, Inder W. Alternating hyperthyroidism and hypothyroidism in Graves' disease. *Clin Case Rep.* 2018 Sep; 6(9): 1684-1688. <https://doi.org/10.1002/ccr3.1700> PMID:30214742 PMCID:PMC6132101
- Drummond J, Roncaroli F, Grossman AB, Korbonits M. Clinical and pathological aspects of silent pituitary adenomas. *The Journal of Clinical Endocrinology & Metabolism.* 2018; 104(7):2473-89. <https://doi.org/10.1210/jc.2018-00688> PMID:30020466 PMCID:PMC6517166
- De Leo S, Lee YS, Braverman EL. Hyperthyroidism. *Lancet.* 2016; 388 (10047): 906-918. [https://doi.org/10.1016/S0140-6736\(16\)00278-6](https://doi.org/10.1016/S0140-6736(16)00278-6)
- Teng X, Jin T, Brent GA, Wu A, Teng W, Shan Z. A patient with a thyrotropin-secreting microadenoma and resistance to thyroid hormone (P453T) *J Clin Endocrinol Metab.* 2015; 100(7):2511-2514. <https://doi.org/10.1210/jc.2014-3994> PMID:25867808 PMCID:PMC5393528
- Kobayashi S, Yoshimura Noh J, Shimizu T, Sato T, Kurihara I, Sugino K, Itoh H, Ito K. A case of familial dysalbuminemic hyperthyroxinemia (FDH) in Japan: FDH as a possible differential diagnosis of syndrome of inappropriate secretion of thyroid-

stimulating hormone (SITSH). *Endocr J.* 2017; 64: 207-212.
<https://doi.org/10.1507/endocrj.EJ16-0135> PMID:27904073

19. Mullur R, Liu YY, Brent GA. Thyroid hormone regulation of metabolism. *Physiological reviews.* 2014; 94(2):355-82.
<https://doi.org/10.1152/physrev.00030.2013> PMID:24692351
PMCID:PMC4044302

20. Jiao Fu, Alexandra M. Dumitrescu. Inherited defects in thyroid hormone cell-membrane transport and metabolism. *Best Pract*

Res Clin Endocrinol Metab. 2014 March; 28 (2): 189-201.
<https://doi.org/10.1016/j.beem.2013.05.014> PMID:24629861
PMCID:PMC3959653

21. Rivas MA, Lado-Abeal J. Thyroid hormone resistance and its management. *Proc (Bayl Univ Med Cent).* 2016; 29:209-211.
<https://doi.org/10.1080/08998280.2016.11929421> PMID:27034574