

Simultaneous Presentation of Benign Paroxysmal Positional Vertigo and Meniere's Disease – Case Report

Marina Davcheva-Chakar*, Gabriela Kopacheva-Barsova, Nikola Nikolovski

University Clinic of Ear, Nose and Throat, University Campus "St. Mother Theresa", Skopje, Republic of Macedonia

Abstract

Citation: Davcheva-Chakar M, Kopacheva-Barsova G, Nikolovski N. Simultaneous Presentation of Benign Paroxysmal Positional Vertigo and Meniere's Disease – Case Report. Open Access Maced J Med Sci. <https://doi.org/10.3889/oamjms.2019.600>

Keywords: Benign paroxysmal positional vertigo; Meniere's disease; Dix-Hallpike manoeuvre; Epley manoeuvre

***Correspondence:** Marina Davcheva-Chakar. University Clinic of Ear, Nose and Throat, University Campus "St. Mother Theresa", Skopje, Republic of Macedonia. E-mail: marinacakar@yahoo.com

Received: 20-Sep-2019; **Revised:** 05-Oct-2019; **Accepted:** 06-Oct-2019; **Online first:** 14-Oct-2019

Copyright: © 2019 Marina Davcheva-Chakar, Gabriela Kopacheva-Barsova, Nikola Nikolovski. This is an open-access article distributed under the terms of the Creative Commons Attribution-NonCommercial 4.0 International License (CC BY-NC 4.0)

Funding: This research did not receive any financial support

Competing Interests: The authors have declared that no competing interests exist

BACKGROUND: Benign paroxysmal positional vertigo (BPPV) is one of the most common clinical entities, which develops spontaneously in most of the cases, but it can be secondary as a result of different conditions such as head injuries, viral neurolabyrinthitis, Meniere's disease and vertebrobasilar ischemia. The aim of presenting this case is to point out to the need of taking a precise clinical history and performing Dix-Hallpike manoeuvre in all patients who complain about vertigo regardless of the previously diagnosed primary disease of the inner ear.

CASE PRESENTATION: A 63-year-old female patient presented with the classical triad of symptoms for Meniere's disease (fluctuating sensorineural hearing loss in the right ear, tinnitus and fullness in the same ear and rotary vertigo), two years later complained of brief episodes of vertigo linked to changes in head position relative to gravity. Dix-Hallpike manoeuvre showed a classical response in the head-hanging right position. Benign paroxysmal positional vertigo (BPPV) in the same ear was diagnosed in this patient. After treatment with Epley's canal repositioning manoeuvre for a few days, the symptoms of positional vertigo resolved.

CONCLUSION: The authors recommend complete audiological and otoneurological evaluation in all patients with vertigo for timely recognition/diagnosis of any inner ear associated pathology.

Introduction

Vertigo is a symptom of many diseases that involve the inner ear, which is not surprising having in mind its complex constitution and function. Benign paroxysmal positional vertigo (BPPV) is one of the most common clinical entities that can be easily treated, but unfortunately in many cases, it is not recognised by the doctors [1], [2], [3]. The annual incidence of BPPV ranges from 0.06 to 0.6%, and its prevalence increases proportionally with the age of patients [4], [5], [6]. It is rarely found in children and population younger than 35 years, where it is often associated with head injuries [7]. It is considered that pathophysiological mechanisms that cause positional vertigo are detached otoconia floating inside the semicircular canals (canalithiasis) or otoconia adhering to the cupula, most often in the posterior semicircular canal (cupulolithiasis) [8], [9], [10]. Although its pathogenesis is still not yet elucidated, in general, it is assumed that it develops spontaneously in 85% of cases as a result of degeneration of

utricle neuroepithelium [11]. In 25% of cases, BPPV can be associated with other different conditions in the inner ear that might cause otoconia detachment or secondary BPPV [12], [13], [14].

Meniere's disease is an inner ear disease that is characterised by episodes of vertigo, fluctuating and progressive hearing loss, tinnitus, sense of fullness in the affected ear. The aetiology and pathophysiology of Meniere's disease are still unknown although 156 years have passed since it was recognised for the first time by Prosper Meniere, after whom this disease was named. Schuknecht's theory is about the rupture of membranous labyrinth and spilling of potassium-rich endolymph through the rupture, causing a potassium intoxication of the vestibular nerve. His theory is based on pathohistological findings of numerous temporal bone specimens from patients with Meniere's disease [15]. Recent studies based on the documented age when the symptoms of Meniere's disease appear, an age that is similar to that when BPPV prevalence is the highest, consider detached saccular otoconia to be the fundamental cause of

Meniere's disease [16], [17].

The frequency of BPPV in MD in N Macedonia is unclear. BPPV is largely underdiagnosed, while Menière's disease, which is about 10 times less frequent than BPPV, appears to be overdiagnosed.

The latest studies have indicated the possible coexistence of these two conditions in the inner ear and suggest their interaction [18]. BPPV, along with MD, was mostly observed in the ear affected by hydrops in females and patients with more advanced disease. Canalolithiasis of the horizontal semicircular canal was more common in patients with BPPV associated with MD than in idiopathic BPPV. BPPV in MD was more prone to recurrence and required more canal repositioning manoeuvres [19].

According to Taura et al., about one-third of patients with Meniere's disease developed benign paroxysmal positional vertigo (BPPV)-like attacks [20]. Thus, vertigo attacks in patients with Meniere's disease must be carefully treated because the therapy for such vertigo attacks is different from the therapy for BPPV.

Case Report

In March 2014, a 62-year-old woman came to the University Clinic of Ear, Nose and Throat, accompanied by her husband. The patient was pale, scared and with difficulty walking. She complained about vertigo, which she explained as if subjects moved in a circle from right to left; she felt ringing in the right ear similar to "ocean whisper", fullness in the right ear and the need of permanent swallowing and making Valsalva manoeuvre. Her six-month-clinical history revealed episodes of vertigo in several hours. In the beginning of the disease, auditory symptoms in the period between vertigo episodes had resolved, but later they became permanent.

The patient underwent a neurological evaluation, tonal audiometry, tympanometry and standard test protocol for visual and vestibular stimulation [21]. Neurological evaluation revealed normal mental status, speech and normal function of cranial nerves. The patient was unstable while standing, and the Romberg test showed lateralisation towards the side of the affected ear. The first audiometric examination registered a conductive hearing loss of 10 db at 250 Hz in the right ear and normal hearing in the left ear. The check-up made at 6 months showed sensorineural hearing loss of 10 db at 250 and 500 Hz; 2 months later sensorineural hearing loss was found for low and high frequencies except at 2000 Hz, and the check-up after 24 months since the

onset of symptoms showed a moderate sensorineural hearing loss for all frequencies (flat audiometric curve) Figure 1.

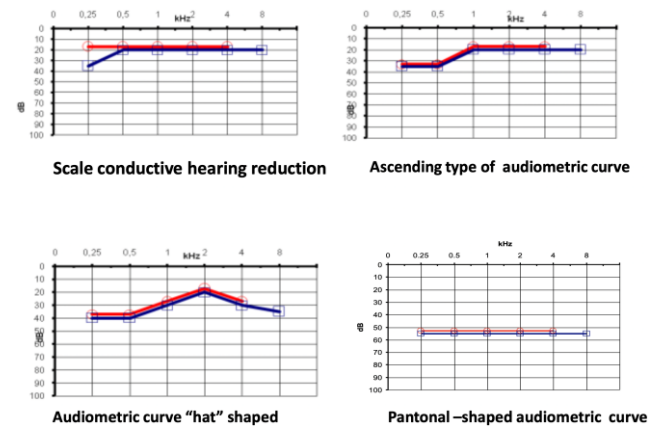


Figure 1: Pure tone results

Type A curve, Figure 1, according to Jeger's classification, was seen in both ears on tympanometry, confirming normal admittance and tympanometric peak pressure, [22].

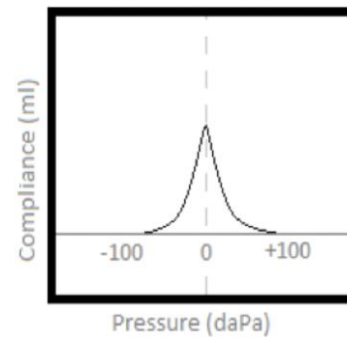


Figure 2: Tympanogram type A

Unilateral, rhythmic, conjugated horizontally rotary nystagmus was registered in a reverse direction from the affected ear. A caloric test with hot and cold water was realised. The test showed an asymmetric horizontal canal function of 25% and confirmed a depressed response on the disease side. The diagnosis of definitive Meniere's disease was made based on the guidelines of the American Academy of Otolaryngology-Head and Neck Surgery Foundation (AAO-HNS) [23].

After 24 months since the beginning of the symptoms, the patient came to our Clinic complaining about brief attacks of vertigo, which had appeared two weeks after the first vertigo attack that differed from the previous attacks. She described vertigos as sudden sensation as if "the room was spinning", very often accompanied by nausea and short-term instability. She had this kind of vertigo most often in the morning when she got up from bed or when turning over to the right in bed. She did not have vertigo while standing or turning the head.

Based on patient's anamnesis Dix Hallpike manoeuvre was realised and it showed a classical response when in head-hanging-right position. A short time of about 5 seconds after repositioning the head, geotropic, torsional rotary nystagmus of about 30 sec. Was registered. The patient complained of vertigo and nausea. When the test was repeated, the response was significantly weaker, and after several repetitions, it completely disappeared. Complete symptom remission was achieved after 7-day-treatment with Epley's manoeuvre. At the check-up visit after several months, the patient said she had no vertigo when changing the position of the head.

Discussion

The association between BPPV and Meniere's disease has been described in the literature, but there are still some unresolved questions related to the possible pathophysiological mechanisms and the exact incidence of this combination. The incidence of BPPV among patients with Meniere's disease has been presented in a wide range from 0.3 to 30% [24], [25].

In a study including 718 patients with diagnosed BPPV, 9% of patients had existing inner ear disease, of which one third had Meniere's disease [26]. Lately, the incidence increase of patients with concomitant Meniere's disease and BPPV might be due to the higher awareness of the doctors about the possible coexistence of these two different conditions in the affected ear.

In our patient, the symptoms of Meniere's disease preceded the symptoms of BPPV in the affected ear, which is in conjunction with the results of others suggesting that Meniere's disease predispose patients to BPPV [27], [28].

The matter of argument is whether there is a possible relation between these conditions or their association is accidental. According to many authors, simultaneous existence/appearance of Meniere's disease and BPPV in the same ear indicates an association between these two disorders [26], [29].

In our patient, BPPV symptoms appeared two weeks after the last vertigo attack and receded after the 7-day-treatment with Epley's manoeuvre. Lee *et al.* reported that in the largest percentage of patients, the BPPV symptoms appear one week after the vertigo attack. According to these authors, the simultaneous onset of symptoms is unusual and is found in a small percentage [26]. Regarding the rate of symptoms resolution after repositioning procedures, literature data show a higher rate in patients with idiopathic BPPV than in those with BPPV associated with Meniere's disease or other disorders in the inner ear. These authors also state that it might be due to

different pathophysiological mechanisms associated with different diseases of the inner ear [30], [31], [32]. Contrary to these reports, BPPV in MD can affect either ear and be not associated with poorer outcomes than idiopathic BPPV [33].

The symptoms of BPPV in our patient appeared in the late phase of Meniere's disease, which is similar to other studies that indicate a higher secondary BPPV rate in patients during the late stages of Meniere's disease [24], [34]. Concerning the pathophysiological mechanism, we think that the common hydropical attacks are the possible cause for the damage to the maculae of the utricle and saccule, which results in detached otoconia in the endolymph and are the cause of simultaneous development of these two different entities in the affected ear. Our assumptions are similar to those of other authors [24], [25].

According to other authors, the sleep position is in a tight relation and cause for the coexistence of these two different conditions in the same ear. Patients with Meniere's disease usually sleep on the head-lying side with reduced hearing so that the ear with a good hearing is free. These authors say that otoconia dislodged from the utricle can fall in the lateral or posterior semicircular canal in the lower portion of the inner ear during sleep [29], [30]. Our patient did not tell us that she usually/often sleeps on her right ear.

In conclusion, authors think that due to the possible association of two different clinical entities in the same ear, the initial diagnosis of Meniere's disease should not be considered definitive, emphasising the need of taking Dix Hallpike test in all patients with vertigo.

References

1. Neuhauser HK. The epidemiology of dizziness and vertigo. *Handb Clin Neurol.* 2016; 137:67-82. <https://doi.org/10.1016/B978-0-444-63437-5.00005-4> PMID:27638063
2. Froehling DA, Silverstein MD, Mohr DN, Beatty CW, et al. Benign positional vertigo: incidence and prognosis in a population-based study in Olmsted County, Minnesota. *Mayo Clinic Proc.* 1991; 6:596-601. [https://doi.org/10.1016/S0025-6196\(12\)60518-7](https://doi.org/10.1016/S0025-6196(12)60518-7)
3. van der Zaag-Loonen HJ, van Leeuwen RB, Tjasse Bruintjes TD, van Munster BC. Prevalence of nonrecognized benign paroxysmal positional vertigo in older patients. *Eur Arch Otorhinolaryngol* 2015; 272(6):1521-4. <https://doi.org/10.1007/s00405-014-3409-4> PMID:25488279
4. Murdin L, Schilder AG. Epidemiology of balance symptoms and disorders in the community: a systematic review. *Otol Neurotol.* 2015; 36(3):387-92. <https://doi.org/10.1097/MAO.0000000000000691> PMID:25548891
5. Pal'chun VT, Mel'nikov OA, Levina YV, Guseva AL. The peculiar features of the clinical course of Meniere's disease associated with benign paroxysmal positional vertigo. *Vestm Otorinolaringol.* 2018; 83(1):32-36. <https://doi.org/10.17116/otorino201883132-35> PMID:29488493

6. Ciorba A, Cogliandolo C, Bianchini C, Aimoni C, Pelucchi S, Skarzynski Ph, Hatzopoulos S. Clinical features of benign paroxysmal positional vertigo of the posterior semicircular canal. *SAGE Open Med.* 2019; 2(7):1-5. <https://doi.org/10.1177/2050312118822922> PMID:30637105 PMCID:PMC6317147
7. Suarez H, Alonso R, Arocena M, Suarez A, et al. Clinical characteristics of positional vertigo after mild head trauma. *Acta Otolaryngol.* 2011; 131:377-81. <https://doi.org/10.3109/00016489.2010.534113> PMID:21189053
8. Welling DB, Parnes LS, O'Brien B, Bakaletz LO, Brackmann DR, Hinojosa R. Particulate matter in the posterior semicircular canal. *Laryngoscope.* 1997; 107(1):90-4. <https://doi.org/10.1097/00005537-199701000-00018> PMID:9001271
9. McClure JA. Horizontal canal BPV. *J Otolaryngol.* 1985; 14:30-35.
10. Parnes LM, Aqrawal SK, Atlas J. Diagnosis and management of benign paroxysmal positional vertigo (BPPV). *CMAJ.* 2003; 169(7):681-93.
11. Parnes LS, McClure JA. Free floating endolymph particles. A new operative finding during posterior semicircular canal occlusion. *Laryngoscope.* 1992; 102:989-92. <https://doi.org/10.1288/00005537-199209000-00006> PMID:1518363
12. Baloh R, Honrubia V, Jacobson K. Benign positional vertigo: clinical and oculographic features in 240 cases. *Neurology.* 1987; 37:371-378. <https://doi.org/10.1212/WNL.37.3.371> PMID:3822129
13. Aron M, Lea J, Naku D, Westerberg BD. Symptom Resolution Rates of posttraumatic versus Nontraumatic Benign Paroxysmal positional Vertigo. A Systematic Review. *Otolaryngol Haed Neck Surg.* 2015; 153(5):721-30. <https://doi.org/10.1177/0194599815594384> PMID:26183524
14. Atacan E, Sennaroglu L, Genc A, Kaya S. Benign paroxysmal positional vertigo after stapedectomy. *Laryngoscope.* 2001; 111:1257-9. <https://doi.org/10.1097/00005537-200107000-00021> PMID:11568550
15. Baloh R. Harold Schuknecht and pathology of the ear. *Otology Neurotol.* 2001; 22:113-122. <https://doi.org/10.1097/00129492-200101000-00021> PMID:11314705
16. Hornibrook J, Bird P. A New Theory for Meniere's Disease: Detached Saccular Otoconia. *Otolaryngol Haed Neck Surg.* 2017; 156(2):360-62. <https://doi.org/10.1177/0194599816675843> PMID:28145833
17. Hornibrook J. Saccular otoconia as a cause of Meniere's disease: hypothesis based on two theories. *J Laryngol.* 2018; 132(9): 771-774. <https://doi.org/10.1017/S0022215118001366> PMID:30149814
18. Psillas G, Triaridis S, Markou K, Tsalighopoulos M, Vital V. Benign paroxysmal positional vertigo in the first acute attack of Meniere's disease. *B-ENT.* 2011; 7:131-5.
19. Kutlubaev MA, Xu Y, Hornibrook J. Benign paroxysmal positional vertigo in Meniere's disease: systematic review and meta-analysis of frequency and clinical characteristics. *Neurol.* 2019; 1-7. <https://doi.org/10.1007/s00415-019-09502-x> PMID:31410549
20. Taura A, Funabiki K, Ohgita H, Ogino E, torii H, Matsunaga M, Ito, J. One third of vertiginous episodes during the follow - up period are caused by benign paroxysmal positional vertigo in patients with Menier'e disease. *Acta Otolaryngol.* 2014; 134(11):1140-5. <https://doi.org/10.3109/00016489.2014.936624> PMID:25166020
21. Jongkees LBW, Maas JPM, Fillipszoon AJ. Clinical nystagmography. *Practica Otorhinolaryngol.* 1962; 24:65-93. <https://doi.org/10.1159/000274383>
22. Jeger J. Clinical experience with impedance audiometry. *Arch Otolaryngol.* 1970; 92:314-324. <https://doi.org/10.1001/archotol.1970.04310040005002> PMID:5455571
23. Committee on Hearing and Equilibrium guidelines for the diagnosis and evaluation of therapy in Meniere's disease. American Academy of Otolaryngology - Head and Neck Foundation Inc. *Otolaryngol Head Neck Surg.* 1995; 113:181-5. [https://doi.org/10.1016/S0194-5998\(95\)70102-8](https://doi.org/10.1016/S0194-5998(95)70102-8)
24. Kalberg M, Hall K, Quickert N, Hinson J, Halmagyi GM. What inner ear disease cause benign paroxysmal positional vertigo. *Acta Otolaryngol.* 2000; 120:380-5. <https://doi.org/10.1080/000164800750000603> PMID:10894413
25. Dimitros G, Balatsouras DG, Ganelis P, Aspris A, Economou NC, Moukos A, Koukoutsis G. Benign Paroxysmal positional vertigo associated with Meniere's disease: Epidemiological, Pathophysiological, Clinical and Therapeutic Aspects. *Ann Otol Rhinol Laryngol.* 2012; 121:682-8. <https://doi.org/10.1177/000348941212101011> PMID:23130545
26. Lee NH, Ban JH, Lee KC, Kim SM. Benign paroxysmal positional vertigo secondary to inner ear disease. *Otolaryngol Head Neck Surg.* 2010; 143:413-7. <https://doi.org/10.1016/j.otohns.2010.06.905> PMID:20723780
27. Gross EM, Ress BD, Viirre ES, Nelson JR, Harris JP. Intractable benign paroxysmal positional vertigo in patients with Meniere's disease. *Laryngoscope.* 2000; 110(4):655-659. <https://doi.org/10.1097/00005537-200004000-00022> PMID:10764014
28. Yetiser S. Co-existence of Benign Paroxysmal Positional Vertigo and Meniere's syndrome. *J Int Adv Otol.* 2017; 13(1):65-68. <https://doi.org/10.5152/jao.2016.2906> PMID:28085000
29. Hughes CA, Procor L. Benign paroxysmal positional vertigo. *Laryngoscope.* 1997; 107:607-13. <https://doi.org/10.1097/00005537-199705000-00010> PMID:9149161
30. Gordon CR, Levite R, Joffe V, Gadoth N. Is posttraumatic benign paroxysmal positional vertigo different of idiopathic form? *Arch Neurol.* 2004; 61(10):1590-1593. <https://doi.org/10.1001/archneur.61.10.1590> PMID:15477514
31. Pollak L, Davies RA, Luxon LL. Effectiveness of the particle repositioning maneuver in benign paroxysmal positional vertigo with and without additional vestibular pathology. *Otology Neurotol.* 2002; 23(1):79-83. <https://doi.org/10.1097/00129492-200201000-00018> PMID:11773852
32. Zhu M, Yu F, Zhou F, Wang H, Jiao Y, Wang M, Huang L et all. Benign paroxysmal positional vertigo associated with Meniere's disease. *J Vestib Res.* 2019; 28(3-4):359-364. <https://doi.org/10.3233/VES-180638> PMID:30149485
33. Luryi AL, Lawrence J, Bojrab D, LaRouere M, Babu S, Hong R, Zappia J, Sargent E, et al. Patient,disease, and outcome characteristics of benign paroxysmal positional vertigo with and without Meniere's disease. *Acta Otolaryngol.* 2018; 138(10):893-897. <https://doi.org/10.1080/00016489.2018.1484566> PMID:30016894
34. Li P, Zeng X, Li Y, Zhang G, Huang X. Clinical analysis of benign paroxysmal positional vertigo secondary to Meniere's disease. *Scientific Research and Essays.* 2010; 5(23):3672-3675.
35. Sato G, Sekine K, Matsudo K, Takeda N. Effects of sleep position on time course in remission of positional vertigo in patients with benign paroxysmal positional vertigo. *Acta Otolaryngol.* 2012; 132:614-7. <https://doi.org/10.3109/00016489.2012.655860> PMID:22384815
36. Shim DB, Kim JH, Park KC, Song MH, Park HJ. Correlation between the head-lying side during sleep and the affected side by benign paroxysmal positional vertigo involving the posterior and horizontal semicircular canal. *Laryngoscope.* 2012; 122:873-6. <https://doi.org/10.1002/lary.23180> PMID:22344794