

# Neo Adjuvant Chemotherapy on Testicular Cancer after Scrotal Exploration: A Case Report

Andhika H. Novianda\*, Fauriski Febrian Prapiska

*Department of Urology, Faculty of Medicine, Universitas Indonesia, H. Adam Malik Hospital, Medan, Indonesia*

## Abstract

**Citation:** Novianda AH, Prapiska FF. Neo Adjuvant Chemotherapy on Testicular Cancer After Scrotal Exploration: A Case Report. Open Access Maced J Med Sci. <https://doi.org/10.3889/oamjms.2019.604>

**Keywords:** Neo Adjuvant Chemotherapy; Testicular Cancer; Scrotal Exploration

**\*Correspondence:** Andhika H. Novianda. Department of Urology, Faculty of Medicine, Universitas Indonesia - H. Adam Malik Hospital, Medan, Indonesia. E-mail: [andhikahernawannovianda@gmail.com](mailto:andhikahernawannovianda@gmail.com)

**Received:** 16-Apr-2019; **Revised:** 08-Jul-2019; **Accepted:** 09-Jul-2019; **Online first:** 13-Jul-2019

**Copyright:** © 2019 Andhika H. Novianda, Fauriski Febrian Prapiska. This is an open-access article distributed under the terms of the Creative Commons Attribution-NonCommercial 4.0 International License (CC BY-NC 4.0)

**Funding:** This research did not receive any financial support

**Competing Interests:** The authors have declared that no competing interests exist

**BACKGROUND:** A case of testicular cancer treated with neo adjuvant therapy in a patient in male is rare. When testicular cancer presents, it is usually directly operated due to the size of cancer which presented within the order of operable size.

**CASE PRESENTATION:** Here, we report a rare case of a 5-year-old male patient presented to the emergency room (ER) due to mass on the scrotum without the difficulty of urination. From clinical findings, mass with a size of 15 x 10 cm was found with multiple abscesses on both sides of the scrotum. Pathological Anatomy Examination confirmed yolk sac tumour present within the scrotal mass. Initially, palliative chemotherapy took place to reduce the growth rate of the tumour. However, due to the responsiveness of testicular cancer to chemotherapy drugs, it reduced into operable size testicular cancer. Wide excision and Orchidectomy was then performed, followed by adjuvant chemotherapy.

**CONCLUSION:** This case report showed the possibility of using neo adjuvant chemotherapy as an alternative treatment when inoperable testicular cancer presented in hospital.

## Introduction

In children, testicular tumours are uncommon, with an incidence of approximately 0.5 – 2.0 per 100,000 individuals and comprise about 1 – 2% of pediatric malignancies [1], [2], [3]. One study suggested that testicular tumours may be more common in Asian than in Caucasian children [4].

Testicular cancer represents the most common malignancy in males aged 15-34 years [5]. Histopathologically, testicular germ cell tumours are divided into two major groups: pure seminoma and nonseminoma. The pathogenesis of testicular germ cell tumours remains unknown; however, although recently questioned [6], cryptorchidism is the main risk factor, and molecular studies have shown strong evidence of an association between genetic alterations and testicular germ cell tumours [7]. Nearly 40% of the cases correspond to seminomas, and three-quarters of them are diagnosed with stage I of the disease [5]. Although testicular cancer has

excellent cure rates, the choice of treatment centre is of utmost importance. Expert centres achieve better results for both the early-stage testicular cancer (lower relapse rates) and overall survival (higher stages within clinical trials) [8].

Seminomas are more sensitive to chemotherapy and radiation therapy; therefore, they are easier to cure than non-seminomas. The surgical treatment is either orchiectomy or orchidectomy plus lymph node dissection of the involved ganglia followed by adjuvant chemotherapy. Testicular cancer treated with neo adjuvant therapy was rare, due to the operable size of commonly found testicular cancer.

## Case Report

A 5-year-old Indonesian male with a size of 15 x 10 cm soft tissue mass with multiple abscesses on

both side of the scrotum was presented to the emergency room. The patient stated that the lesion had been presented for 2 years. It appeared initially as an itchy mass appeared on the left side of the scrotum and grew bigger. The overlying skin surface was presented with erythema, multiple abscesses and sinus tracts. The lesion was indurated and tender (Figure 1). The bilateral testis cannot be identified even though penile and meatal can be identified. The patient had no difficulty of micturition.

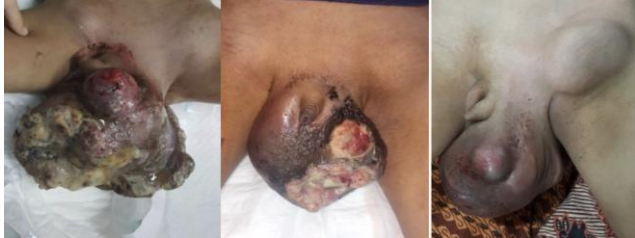

Figure 1: Lesion of the Scrotum Pre

Secondary examinations such as blood test as well as Ultrasonography, Chest x-ray and Computed Tomography (CT) scan was performed to the scrotum. The blood test result showed increased zero marker value, which ensured the presence of testicular cancer. Ultrasonography of the scrotum showed enlargement of the left testis while right testis was found within normal limit. Abdominal CT-scan examination also showed enlargement on the left testis but limited only to the scrotum (Figure 5).

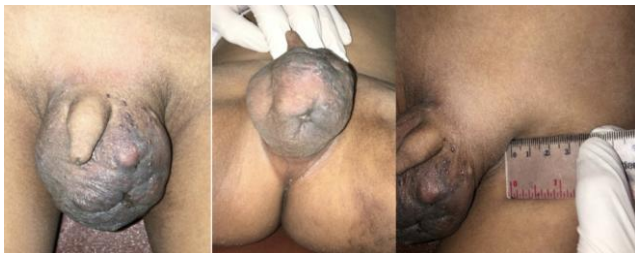

Figure 2: Lesion of the Scrotum Post Neo Adjuvant

Chest x-ray showed coin lesion as it was already metastasised to the lungs. Based on the examination results, we decided to do palliative chemotherapy due to the inoperable size of testicular cancer.

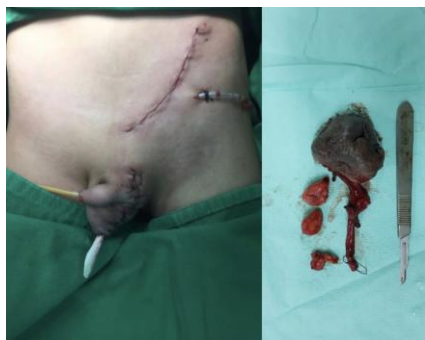

Figure 3: Lesion of the Scrotum Post

However, after four chemotherapy treatments, the size of testicular cancer was significantly reduced to operable size (Figure 2) as it was confirmed by the abdominal CT-scan (Figure 6).

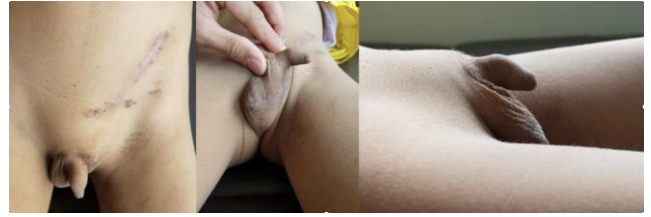

Figure 4: Lesion of the Scrotum Post Adjuvant Chemotherapy

Therefore, we decided to do wide excision and orchidectomy on the left testis (Figure 3). Lymphadenectomy was also done in conjunction with previous surgery to remove an enlarged lymph node. It was then followed by four times adjuvant chemotherapy.

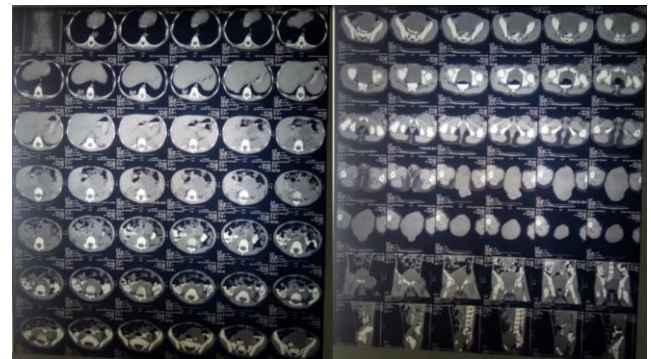


Figure 5: Computed Tomography of Lower Abdomen Pre

One month after the last chemotherapy, a patient came control to the outpatient clinic. The scrotum was appeared to be within normal limit. There was neither induration nor tenderness found in the scrotum.

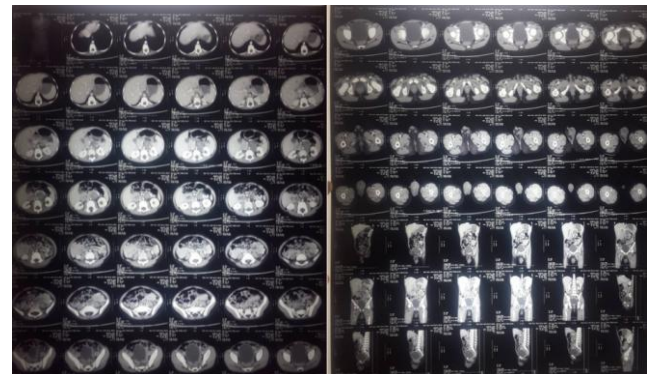

Figure 6: Computed Tomography of Lower Abdomen Post Neo Adjuvant

The overlying skin surface was also presented within the normal limit (Figure 4). A chest x-ray also showed lungs within normal limit.

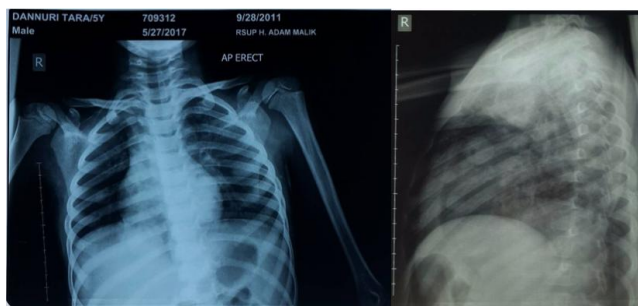


Figure 7: Chest X-Ray Pre

## Discussion

This case suggested neo adjuvant chemotherapy usage in inoperable testicular cancer. The patient was delayed in presentation due to limited access to appropriate medical facilities as well as the patient's ignorance of the massive scrotal swelling that had been persisting for at least 12 months. In this case, the inoperable scrotal mass was then presented with multiple abscesses in the emergency room.

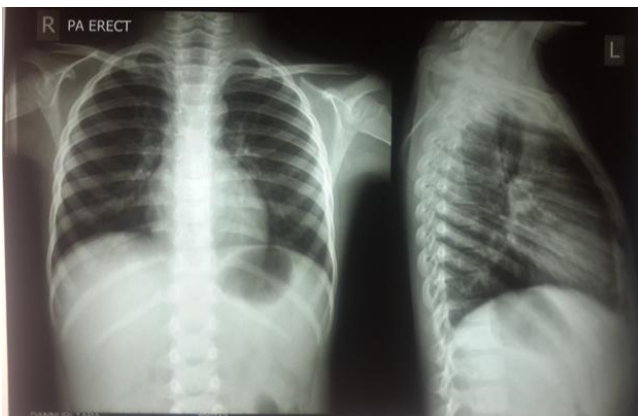


Figure 8: Chest X-Ray Post Operation

A review of the literature showed that this form of presentation is rare [9], [10], [11]. Although the recent diagnostic and therapeutic developments have altered the prognosis in this disease, the delay in diagnosis and occasional mismanagement of patients continue to inhibit further improvement in survival rate. A high index of suspicion and an aggressive approach to its management are advocated to improve long-term survival [12].

Testicular cancer has a higher responsiveness to chemotherapy compared to other cancer. The key to such success appears to lie in cancer's stem cells, which are more sensitive to chemotherapy than stem cells found in other types of cancer. Defining why testicular cancers are so susceptible to chemotherapy could eventually provide

insights for treating other, more resistant cancers [13].

Most types of tumours contain distinct populations of cells. A small fraction of these is stem cells, which can grow new tumours from a single cell and are extremely resistant to therapy. Often, other types of tumour cells are killed off during treatment, but cancer stem cells survive, then drive relapse by re-growing new tumours. However, when testicular cancer stem cells are exposed to chemotherapy, those stem cells are more sensitive to it than other cells in the tumour [14].

The use of neo adjuvant chemotherapy has led to a dramatic improvement in the cure rate of patients with metastatic germ cell tumours (GCTs). The high responsiveness of testicular cancer was achieved even in inoperable size of testicular cancer. After that, the goals of the patient changed from palliative into curative by the introduction of neo adjuvant chemotherapy, followed by surgical treatment and adjuvant chemotherapy.

In conclusion, testicular cancer treated with neoadjuvant chemotherapy is unusual as the mainstay treatment for testicular cancer is directly surgical and followed by adjuvant chemotherapy. This case presented the inoperable size of testicular cancer in which palliative chemotherapy takes place to reduce the growth rate of testicular cancer. However, due to the responsiveness of testicular cancer to chemotherapy agent, it reduced the initial size into an operable size, which later on able to follow the treatment stated in guidelines. This case report showed the possibility of using neo adjuvant chemotherapy as an alternative treatment when inoperable testicular cancer presented in hospital.

## References

1. Brosman SA. Testicular tumors in prepubertal children. *Urology*. 1979; 13:581-8. [https://doi.org/10.1016/0090-4295\(79\)90375-3](https://doi.org/10.1016/0090-4295(79)90375-3)
2. Lee SD. Epidemiological and clinical behavior of prepubertal testicular tumors in Korea. *J Urol*. 2004; 172:674-8. <https://doi.org/10.1097/01.ju.0000129571.13955.6b> PMID:15247758
3. Kaplan GW, Cromie WC, Kelalis PP, Silber I, Tank ES Jr. Prepubertal yolk sac testicular tumors-report of the testicular tumor registry. *J Urol*. 1988; 140:1109-12. [https://doi.org/10.1016/S0022-5347\(17\)41974-4](https://doi.org/10.1016/S0022-5347(17)41974-4)
4. Tummala MK, Hussain A. Recent developments in germ cell tumors of the testes. *Curr Opin Oncol*. 2008; 20:287-293. <https://doi.org/10.1097/CCO.0b013e3282f8b064> PMID:18391628
5. Aparicio J. SEOM clinical guidelines for diagnosis and treatment of testicular seminoma (2010) *Clin Transl Oncol*. 2011; 13:560-564. <https://doi.org/10.1007/s12094-011-0697-7> PMID:21821490
6. Wood HM, Elder JS. Cryptorchidism and testicular cancer: separating fact from fiction. *J Urol*. 2009; 181:452-461. <https://doi.org/10.1016/j.juro.2008.10.074> PMID:19084853
7. Winter C, Albers P. Testicular germ cell tumors: pathogenesis, diagnosis and treatment. *Nat Rev Endocrinol*. 2011; 7:43-53.



- <https://doi.org/10.1038/nrendo.2010.196> PMID:21116298
8. Albers P. EAU guidelines on testicular cancer: 2011 update. *Eur Urol.* 2011; 60:304-319. <https://doi.org/10.1016/j.eururo.2011.05.038> PMID:21632173
9. Harada Y. A case of testicular tumor presenting as acute scrotum. *Hinyokika Kiyo.* 1989; 35:1243-1245.
10. Ojea Calvo A. Acute scrotum as clinical presentation form of testicular tumor. *Actas Urol Esp.* 1993; 17:501-502.
11. Parra Muntaner L. Acute scrotum secondary to testicular tumor. *Arch Esp Urol.* 2002; 55:71-73.
12. Post GJ, Belis JA. Delayed presentation of testicular tumors. *South Med J.* 1980; 73:33-35. <https://doi.org/10.1097/00007611-198001000-00013> PMID:6243192
13. Cornell University. Why testicular cancer is so responsive to chemo. *ScienceDaily.* 2017.
14. Pierpont TM, Lyndaker AM, Anderson CM, Jin Q, Moore ES, Roden JL, Braxton A, Bagepalli L, Kataria N, Hu HZ, Garness J. Chemotherapy-induced depletion of OCT4-positive cancer stem cells in a mouse model of malignant testicular cancer. *Cell reports.* 2017; 21(7):1896-909. <https://doi.org/10.1016/j.celrep.2017.10.078> PMID:29141221 PMCID:PMC5695237