

The Possible Associations of Nasal Septal Deviation with Mastoid Pneumatization and Chronic Otitis

Sharareh Sanei Sistani¹, Alireza Dashipour², Laleh Jafari¹, Bahareh Heshmat Ghahderijani^{1*}

¹Department of Radiology, School of Medicine, Zahedan University of Medical Sciences, Zahedan, Iran; ²Department of Nutrition and Food Sciences, Zahedan University of Medical Sciences, Zahedan, Iran

Abstract

Citation: Sistani SS, Dashipour A, Jafari L, Ghahderijani BH. The Possible Associations of Nasal Septal Deviation with Mastoid Pneumatization and Chronic Otitis. Open Access Maced J Med Sci. <https://doi.org/10.3889/oamjms.2019.670>

Keywords: Nasal septum deviation; Mastoid cells; Chronic Otitis

***Correspondence:** Bahareh Heshmat Ghahderijani. Department of Radiology, School of Medicine, Zahedan University of Medical Sciences, Zahedan, Iran. E-mail: bahar.heshmatmd@gmail.com

Received: 16-Jun-2019; **Revised:** 03-Jul-2019; **Accepted:** 04-Jul-2019; **Online first:** 8-Aug-2019

Copyright: © 2019 Sharareh Sanei Sistani, Alireza Dashipour, Laleh Jafari, Bahareh Heshmat Ghahderijani. This is an open-access article distributed under the terms of the Creative Commons Attribution-NonCommercial 4.0 International License (CC BY-NC 4.0)

Funding: This research did not receive any financial support

Competing Interests: The authors have declared that no competing interests exist

BACKGROUND: The nasal septum deviation is the most common deformity of the nasal, and that can be congenital or acquired. Despite many studies exist about the impact of nasal septum deviation on chronic sinusitis and also association between chronic otitis and mastoid pneumatization; few studies exist about the impact of nasal septum deviation on chronic otitis and mastoid pneumatization.

AIM: The aim of this study was to evaluate the associations of nasal septum deviation and mastoid pneumatization and chronic otitis.

METHODS: In this study review, all CT scans of PNS and Mastoid View in the imaging section from Imam Ali hospital in 2016-2017 years and cases of nasal septum deviation were enrolled. The nasal septum deviation was recorded, and the degree of nasal septum deviation in the coronal plane that showed the maximum deviation of the nasal septum was recorded. The volume of the mastoid cells automatically and directly was calculated using three diameter measurements (2 coronal diameters and 1 axial diameter) by the program. The software of SPSS 22 was used for statistical analysis.

RESULTS: There was no relationship between nasal septum deviation severity and incidence of mastoid pneumatization in patients with nasal septum deviation ($P > 0.05$). There was relationship between nasal septum deviation severity and chronic otitis in patients with nasal septum deviation ($P < 0.05$). In patients with moderate and severe intensity of nasal septum deviation, the volume of mastoid air cells in deviation side was lower than the front side ($P < 0.05$).

CONCLUSION: Based on the results of the CT scan, in patients with moderate and severe nasal septum deviation intensity, the volume of mastoid air cells in deviation side was lower than the front side. Also, there was a relationship between nasal septum deviation severity and chronic otitis.

Introduction

Nasal septum deviation is the most common nasal deformity that can be congenital or acquired abnormality. The prevalence of nasal septal deviation based on computer tomography (CT scan) is reported to be 40% [1]. There was a *relatively high prevalence* of nasal deviation, and its possible complications include sinusitis, nasal obstruction, meningitis, cavernous sinus thrombosis (CST), etc.

Nasal septum deviation and its complications in the early stages are visible in the imaging and can be easily treated at this stage [2]. The temporal bone consists of three parts, and the bone segments are separated at birth, and then combined into a single

bone. The mastoid is a part of the temporal bone that lies behind the ear and at birth is a cavity at the centre of the bone, but within 2 years, many air cells develop in the mastoid by a process termed pneumatization. Compression of mastoid cells begins at the thirty-third week of pregnancy and continues until the age of 9-8.

The *mastoid antrum* is an air space at the petrous part of the temporal bone, which reaches their adult maturity at the 35th week of pregnancy [3]. Full development of pneumatization can be divided into three stages: the period of childbirth from birth to two years, the transitional period from 2 to 5 years and adulthood [4]. There are two theories about the pneumatization of mastoid air cells. The first theory, "genetic theory", emphasises on the genetical extent of pneumatization. The "environmental theory" is

based on the fact that pneumatization of mastoid air cells depends on postnatal pathologies and involvement of the middle ear, where the pneumatization can be decreased via middle ear inflammation or tubal dysfunction.

According to this theory, any factor that changes the pressure of the middle ear is effective in the level of pneumatization of mastoid air cells. For example, a deviation of nasal septum causes a change in the amount of air passing through the nose. Regarding the relationship of the nasopharynx to the middle ear through the Eustachian tube, this change in the airflow rate causes a change in the pressure of the middle ear and therefore affects the pneumatization of the mastoid [6], [7].

Due to the proximity of the mastoid with the middle ear, middle ear infections can easily inflammation mastoid and cause some degree of mastoiditis associated with middle ear infections. Several studies have been conducted to determine the relationship between middle ear disease and *mastoid air cell system*.

High air in the *mastoid air cell system* is a dangerous factor for the development of multiple diseases of the middle ear [8]. Ear diseases during infancy and early childhood can stop the normal flow of air into the mastoid. This process may cause problems in the *mucoous* membrane of the *ear*, which will make it more susceptible to recurrent infections than normal ear. Most patients with chronic suppurative otitis have a small, cell-free *mastoid* in temporal bone radiography.

Chronic suppurative otitis media is one of the most common chronic infectious diseases all over the world, which affects not only developing societies but also industrial societies [9].

In spite of many studies on the effect of nasal septum deviation on chronic sinusitis and association of mastoid pneumatization with chronic otitis media, few studies have been conducted regarding the effect of nasal septum deviation on mastoid pneumatization or chronic otitis media, while its impact has not been proven yet.

Therefore, the current study was aimed to determine the effect of nasal septum deviation with pneumatization of mastoid cells and its possible association with chronic otitis media.

Material and Methods

This prospective cross-sectional study was conducted at Imam Ali Hospital in Zahedan between 2016 and 2017.

The study population included all paranasal

sinuses (*PNS*) scans and mastoid views, which were archived in the imaging section. The inclusion criteria were the presence of *deviated septum* in radiography films. Exclusion criteria were: 1- Presence of history of nasal sinus, middle ear and mastoid surgery, 2- the presence of nasal polyp, 3- presence of cleft palate or other congenital anatomical disorders [12]. The sample size was determined as 50 people in each group. Finally, 150 people were enrolled in this study.

The *nasal deviation direction* and *the angle of septal deviation (ASD)* in coronal sections were recorded, which showed the maximum deviation of nasal septum. The *NSA* was defined as the angle between a line drawn from the crista Galli to the lower portion of the nasal septum in the maxillary spine and another line drawn from the upper nasal septum in the crista Galli to the most deviated point of the nasal septum. The patients were divided into 3 groups based on the *ASD*: 1- Mild (less than 9). 2-medium (between 15-9). 3. Severe (more than 15), [13].

The volume of mastoid cells was measured directly and automatically by measuring 3 diameters (two coronal diameters and one axial diameter) via certain program which is briefly called the 3DMPVR (*three-dimensional multiplanar rendering technique*), [14]. The size of the mastoid cells is defined as the volume of the air cells in the *aditus* and *antrum* located in the mastoid part of the temporal bone. Criteria for the definition of chronic otitis media in this study were: 1- bone destruction or sclerosis in the temporal bone, 2- massive fluid or structural changes in the temporal air cells [4].

Following the above-mentioned measures, the relationships between *ASD* and pneumatization of mastoid and chronic otitis were investigated.

In this study, data collection form was used to record variables. This form was completed on the basis of the information in the patient records. The data collection form included various variables such as age, sex, *ASD*, presence or absence of mastoid pneumatization, the volume of mastoid cells and chronic otitis media. Using *GE Light Speed 16 Slice CT Scanner*, *PNS* and mastoid View were visualised based on coronal and axial sections.

Data analysis

Statistical analysis was performed using *SPSS 22 software*. Descriptive statistics were used to calculate the mean and standard deviation of variables related to the characteristics of individuals and disease. Before analysing quantitative data, the normal distribution of data was assessed using *KS* test. The analysis was performed using Chi-square test for qualitative variables and T-test or variance analysis for quantitative variables. Similar nonparametric tests were used in the case of non-normal distribution. For all tests, a significant level of 0.05 was considered.

Results

In this study, 150 patients with nasal septal deviation were enrolled who referred to the radiology section of Imam Ali Hospital in Zahedan for CT scan. Fifty patients (33.3%) had mild nasal septum deviation, followed by moderate nasal septum deviation (50%, 33.3%), and severe nasal septum deviation (50%, 33.3%).

The age of the patients was determined to be between 18-72 years with a mean and standard deviation of 39.6 ± 14.07 years (Figure 1). Furthermore, 90 (60%) of the patients were male, and 60 (40%) were female. Also, deviation of nasal septum has been determined as to the right in 98 (65.3%) patients, and to the left in 52 (34.7%).

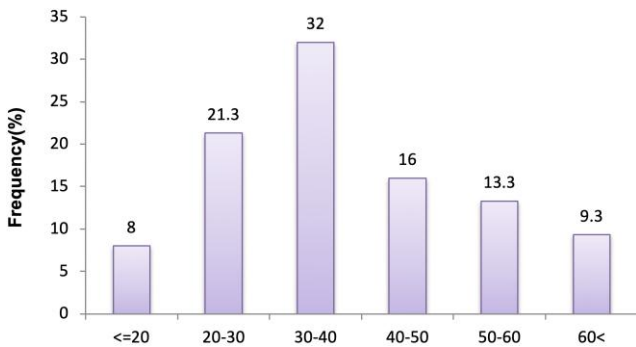


Figure 1: Distribution of patients' age

The ASD in patients was between 23.5 to 4.5 degrees with a mean and standard deviation of 12.27 ± 5.39 degrees (Figure 2).

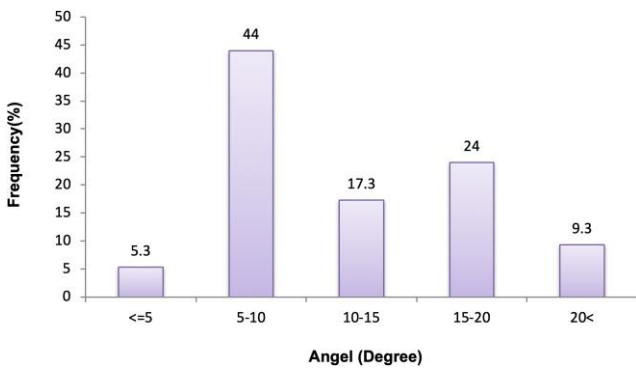


Figure 2: Distribution of the angle of the septal deviation (ASD) in patients

Our findings revealed that 146 (97.3%) patients had mastoid pneumatization and 4 (2.7%) had no mastoid pneumatization. Moreover, the direction of mastoid pneumatization was bilateral in 148 (98.7%), and two (1.7%) was unilateral. Additionally, 98 (65.3%) patients did not show chronic otitis media, and 52 (34.7%) revealed chronic otitis media.

Descriptive features and comparison of age,

gender and direction of nasal septal deviation in 3 groups with the severity of nasal septal deviation are summarized in Table 1.

As indicated in Table 1, age, sex, and direction of deviation of the nasal septum in patients in 3 groups did not show a significant association with severity of nasal deviation (mild, moderate and severe), ($P < 0.05$). The frequency of gender profiles in patients with nasal septum deviation and the frequency of deviation.

Table 1: Descriptive characteristics and comparison of age, gender and direction of nasal septal deviation with the severity of nasal septal deviation

Property	Severity			P-Value
	Mild	Moderate	Severe	
Age (Year)	42.28±13.58	39.44±11.41	37.08±16.78	0.289
Standard deviation ± Mean				
Sex	26(% 52)	30(%60)	34(% 68)	0.513
Male	24(48%)	20(40%)	16(% 32)	
Female				
Direction for deviation of nasal	36(% 72)	28(%56)	34(%68)	0.465
Right	14(%28)	22(%44)		
Left			16(% 32)	

The occurrence of mastoid pneumatization in patients with a deviated septum

In order to compare the incidence of mastoid pneumatization in patients suffering from deviated septum with the severity of the nasal septal deviation, chi-square test was used (Table 2).

Based on the results of Table 2, there was no significant difference between the incidences of mastoid pneumatization in the three groups with severity nasal septum deviation.

Table 2: Frequency and comparison of the incidence of mastoid pneumatization with septal deviation

Property	The severity of nasal septal deviation		
	Mild Frequency (%)	Moderate Frequency (%)	Severe Frequency (%)
Mastoid pneumatization			
Yes	50 (100%)	50 (100%)	46 (92%)
No	0 (0%)	0 (0%)	4 (8%)

Frequency of chronic otitis media

Chi-square test showed that the severity of septal deviation was significantly correlated with chronic otitis media in patients with nasal septum deviation ($P < 0.05$, Table 3).

Table 3: Comparison of chronic otitis media with nasal septal deviation in 3 groups

Property	The severity of nasal septal deviation			Test statistic	P-Value
	Mild Frequency (%)	Moderate Frequency (%)	Severe Frequency (%)		
Chronic otitis				7/18	0/028
No	42 (84%)	32 (64%)	24 (48%)		
Yes	8 (16%)	18 (36%)	26 (52%)		

The difference in the volume of mastoid air cells on the side of the deviation and opposite side of patients

Chi-square test showed that the volume of mastoid air cells in the side of the deviation and the

opposite side had a significant relationship with the severity of nasal septal deviation (mild, moderate and severe) ($P < 0.05$; Table 4). Therefore, it can be said that in patients with moderate and severe deviations, the volume of airborne mastoid cells on the side of the deviation is less than the opposite side.

Table 4: Comparison of the differences in the volume of mastoid air cells on the side of the deviation and the opposite side with the severity of nasal septal deviation

the volume of mastoid air cells	The severity of nasal septal deviation			Test statistic	P-Value
	Mild Frequency (%)	Moderate Frequency (%)	Severe Frequency (%)		
Side deviation is less than the opposite side	24 (48%)	38 (76%)	40 (80%)	6.98	0.03
Side deviation is more than the opposite side	26 (52%)	12 (24%)	10 (20%)		

Discussion

Our study revealed that there was no correlation between the severity of nasal septum deviation and the occurrence of mastoid pneumatization in patients with nasal septum deviation. Furthermore, there was a relationship between the severity of nasal septal deviation and chronic otitis media. In patients with moderate and severe deviation of nasal septum, the volume of mastoid cells in the side of the deviation is less than the opposite side. Consistent with our findings, Kapusuz Gencer et al. reported that there is a relationship between nasal deviation on both sides and chronic otitis media [4].

Chronic otitis exerted on the side with a deviation of septal nose. The results also showed that the mastoid air cell volumes tend to be larger at the contralateral side of the severe septum deviations [4]. Lee et al. evaluated the association of nasal septal deviation with the volume of mastoid air cell pneumatization in a pediatric subject. They indicated that mastoid air cell volume of the deviated side was smaller in comparison with contralateral side, indicating nasal septal deviation is capable of influencing both aerations [15], this finding is in agreement with our results.

In a study by Raman et al., 2016, a significant correlation of septal spur with mastoiditis was found on the same side. Mastoiditis is significantly associated with sinonasal pathologies, and mastoiditis is linked to sinonasal pathologies, which this result was in line with our study [17].

Other study indicated a moderate but remarkable negative association between the ASD and volumes of ethmoid cell. Ethmoid cell volume on the ipsilateral side tends to be reduced by increasing the degree of nasal septal deviation compared with

the contralateral side [18]. This can be due to the lack of development of the secondary mastoid air cells to the severe deviation of the nasal septum. Nasal septal deviation, concha bullosa, and Haller's cells do not show to play a key role in sinus's inferior pneumatization [16], which was in line with our findings.

During the development of paranasal sinuses, there are two active pneumatizations, first between birth and age 4, and second between 8 and 12 years. The stages of growth are amid the two stages [19]. Similar to the development of paranasal sinuses, the mastoid cell system has three stages. The first stage is rapid pneumatization during the first year of life, the second stage is linear pneumatization between 1 and 6 years old, and the third stage is a slow stage until puberty [20].

Some researchers have reported the relationship between paranasal sinuses and mastoid and found that the development of the ethmoid, mastoid and sphenoid occurs at the age of 3 to 14 years [21]. Another study indicated that maxillary sinus volumes increased in the contralateral side of the severe septum deviations. Furthermore, maxillary sinusitis on ipsilateral to the severe septum deviation has been found to be remarkably enhanced [22]. CT scan is a gold standard for evaluating chronic sinusitis. Awareness of various anatomical deviations for surgeons and radiologists is essential to avoid possible complications and to improve the success of therapeutic strategies [23]. In addition, CT scan images can be used to reconstruct the *axilla* designs for data collection. This method is quicker and less costly than the MRI, which provides more information about soft tissue than the bone. CT scans information is capable of showing more detail in the posterior sinuses [24]. One of the strengths of this study is to investigate the relationship between nasal septum deviation and mastoid pneumatization. However, a small number of similar studies have limited the possibility of comparing our study with other studies. Therefore, it is suggested that further studies be developed in the future. Finally, it seems that there was no relationship between the severity of the nasal deviation and the incidence of mastoid pneumatization based on CT scan in patients with nasal septum deviation.

There was a correlation between the severity of nasal deviation and chronic otitis media in these patients. In patients with moderate and severe deviation, the volume of mastoid cells in the side of the deviation is less than the opposite side. Therefore, it can be concluded that as the severity of septal deviation increases, the pneumatization of mastoid air cells showed decreasing trend. These air cells act on gas reserves so that the middle ear is less dependent on the eustachian tube to maintain a balance of pressure. Reducing their *de-airing* disturbs the ear mucus, and thus the affected ear becomes more susceptible to recurrent infections than the normal

ear.

In conclusion, regarding the high prevalence of nasal septum deviations and its complications and sometimes the effects on the inner and outer ear and auditory nerves, more attention should be given to this issue. Based on the finding presented herein, increasing the severity of nasal septal deviation is capable of increasing the likelihood of chronic otitis at a higher deviation side. There is a significant relationship between the severity of nasal septum deviation and the development of chronic otitis media and the percentage of the mastoid pneumatization. Early surgical repair of nasal septal deviation can prevent chronic otitis and its many complications particularly in cases where the severity of this deviation is moderate to severe. A careful study of the severity of nasal septum deviation in PNS CT scans can help ENT specialists to decide for early surgical repair of nasal septum deviation and to prevent the onset of chronic otitis media and many other complications.

References

- Uygun K, Tuz M, Dogru H. The correlation between septal deviation and concha bullosa. *Otolaryngol Head Neck Surg.* 2003;129(1):33-6. [https://doi.org/10.1016/S0194-5998\(03\)00479-0](https://doi.org/10.1016/S0194-5998(03)00479-0)
- Deweese S. Nose and paranasal sinuses. In: Cummings CHW, editor. *Otolaryngology - head and neck surgery.* Philadelphia : Mosby, 1998: 89-100.
- Koc A, Karaaslan O, Ko T. Mastoid air cell system. *Otoscope.* 2004; 144:54.
- Kapusuz Gencer Z, Ozkıriz M, Okur A, Karaoavus S, Saydam S. The Possible Associations of Septal Deviation on Mastoid Pneumatization and Chronic Otitis. *Otology & Neurotology.* 2013; 34(6):1052-57. <https://doi.org/10.1097/MAO.0b013e3182908d7e> PMID:23820794
- Doyle W. The mastoid as a functional rate-limiter of middle ear pressure change. *Int J Pediatr Otorhinolaryngol.* 2007; 71:393-402. <https://doi.org/10.1016/j.ijporl.2006.11.004> PMID:17174408 PMID:PMC2905545
- Sade j. The correlation ear aeration with mastoid pneumatization. the mastoid as a pressure buffer. *Eur Arch Otorhinolaryngol.* 1992; 249:301-4. <https://doi.org/10.1007/BF00179376> PMID:1418937
- Todd NW. Mastoid pneumatization in patients with unilateral aural atresia. *Eur Arch Otorhinolaryngol.* 1994;251:196-8. <https://doi.org/10.1007/BF00628422> PMID:7917250
- Mey K, SLrensen M, HomLe P. Histomorphometric estimation of air cell development in experimental otitis media. *Laryngoscope.* 2006; 116:1820-3. <https://doi.org/10.1097/01.mlg.0000233540.26519.ba> PMID:17003720
- Sheikhi M, Yasrebi M, Torkzadeh A. Evaluation of the effect of nasal septum deviation on chronic sinusitis. *J Isfahan Den Sch.* 2011; 6(5):568-73.
- Majidi M, Taheri A. Correlation between location of lateral sinus and sever of otitis media *The Iranian Journal of Otorhinolaryngology.* 2007; 18(46):175-80.
- Tos M, Stangerup S, Andreassen U. Size of the mastoid air cells and otitis media. *Ann Otol Rhinol Laryngol.* 2000; 94(4):386-92.
- Lee DH, Jin KS. Effect of nasal septal deviation on pneumatization of the mastoid air cell system: 3D morphometric analysis of computed tomographic images in a pediatric population. *The Journal of International Advanced Otolaryngology.* 2014 Oct 1;10(3):251-5. <https://doi.org/10.5152/iao.2014.276>
- Koc A, Ekinci G, Bilgili AM, Akpınar H, Yakut H, Han T. J *Laryngol Otol.* 2003; 117(8):595-8. <https://doi.org/10.1258/002221503768199906> PMID:12956911
- Lee DH, Jin KS. Effect of Nasal Septal Deviation on Pneumatization of the Mastoid Air Cell System: 3D Morphometric Analysis of Computed Tomographic Images in a Pediatric Population. *Journal of International Advanced Otolaryngology.* 2014; 10(3):251-5. <https://doi.org/10.5152/iao.2014.276>
- Göçmen G, Borahan MO, Aktop S, Dumlu A, Pekiner FN, Göker K. Effect of Septal Deviation, Concha Bullosa and Haller's Cell on Maxillary Sinus's Inferior Pneumatization; a Retrospective Study. *Open Dent J.* 2015; 9:282-286. <https://doi.org/10.2174/1874210601509010282> PMID:26464596 PMID:PMC4598377
- Raman R, Murthy N, Galag S, Diwakar S. Mastoiditis and Sinonasal Pathologies on Cranial Computed Tomography Imaging: A Correlative Study. *Int J Sci Stud.* 2016; 4(1):165-168.
- Firat AK, Miman MC, Firat Y, Karakas HM, Ozturan O, Altınok T. Effect of nasal septal deviation on total ethmoid cell volume. *J Laryngol Otol.* 2006; 120(3):200-4. <https://doi.org/10.1017/S0022215105007383> PMID:16372990
- Adibelli ZH, Songu M, Adibelli H. Paranasal sinus development in children: a magnetic resonance imaging analysis. *American journal of rhinology & allergy.* 2011; 25(1):30-5. <https://doi.org/10.2500/ajra.2011.25.3552> PMID:21711972
- Cinamon U. The growth rate and size of the mastoid air cell system and mastoid bone: a review and reference. *European Archives of Oto-Rhino-Laryngology.* 2009; 266(6):781-6. <https://doi.org/10.1007/s00405-009-0941-8> PMID:19283403
- O'Tuama LA, Swanson MS. Development of paranasal and mastoid sinuses: a computed tomographic pilot study. *Journal of child neurology.* 1986; 1(1):46-9. <https://doi.org/10.1177/088307388600100107> PMID:3598107
- Gencer ZK, Özkırış M, Okur A, Karaçavuş S, Saydam L. The effect of nasal septal deviation on maxillary sinus volumes and development of maxillary sinusitis. *European Archives of Oto-Rhino-Laryngology.* 2013; 270(12):3069-73. <https://doi.org/10.1007/s00405-013-2435-y> PMID:23512432
- Gupta S, Gurjar N, Mishra HK. Computed tomographic evaluation of anatomical variations of paranasal sinus region. *International Journal of Research in Medical Sciences.* 2016; 4(7):2909-13. <https://doi.org/10.18203/2320-6012.ijrms20161975>
- Kumar P, Rakesh BS, Prasad R. Anatomical variations of sinonasal region: a CT scan study. *IJCMR.* 2016; 3(6):2601-4.