

Preparation and Histological Study of Multi-Walled Carbon Nanotubes Bone Graft in Management of Class II Furcation Defects in Dogs

Ahmed A. Haroun¹, Basma Mostafa Zaki^{2*}, Mahmoud Shalash², Reham A. A. Morsy²

¹Chemical Industries Research Division, National Research Centre, Cairo, Egypt; ²Oral and Dental Research Division, National Research Centre, Cairo, Egypt

Abstract

Citation: Haroun AA, Zaki BM, Shalash M, Morsy RAA. Preparation and Histological Study of Multi-Walled Carbon Nanotubes Bone Graft in Management of Class II Furcation Defects in Dogs. *Open Access Maced J Med Sci.* 2019 Nov 15; 7(21):3634-3641. <https://doi.org/10.3889/oamjms.2019.738>

Keywords: Multi-walled carbon nanotubes; Bone graft; Furcation defects; Bone regeneration; Histological analysis

***Correspondence:** Basma Mostafa Zaki. Oral and Dental Research Division, National Research Centre, Cairo, Egypt. E-mail: boshta@hotmail.com

Received: 03-Jul-2019; **Revised:** 25-Sep-2019; **Accepted:** 26-Sep-2019; **Online first:** 11-Oct-2019

Copyright: © 2019 Ahmed A. Haroun, Basma Mostafa Zaki, Mahmoud Shalash, Reham A. A. Morsy. This is an open-access article distributed under the terms of the Creative Commons Attribution-NonCommercial 4.0 International License (CC BY-NC 4.0)

Funding: This research did not receive any financial support

Competing Interests: The authors have declared that no competing interests exist

BACKGROUND: The main target of periodontal disease and alveolar bone defeat treatment is the regeneration of the lost structures.

AIM: This work deals with the evaluation of the effect of functionalised multi-walled carbon nanotubes (MWCNTs), as grafting material in the management of furcation defects created in dogs.

MATERIAL AND METHODS: Potential cytotoxicity of the grafting material was assessed. Scanning electron microscope (SEM) and energy dispersive x-ray (EDX) analysis after incubation of the grafting material in simulated body fluid (SBF) at pH 7.4 and 37°C for one week was done. In six healthy mongrel dogs' full-thickness mucoperiosteal flaps were raised on the buccal aspects to create two walls intrabony defects at the furcation areas. The mandibular premolar area received the grafting material. Histological evaluation was carried out at 1, 2- and 3-months' period.

RESULTS: Cytotoxicity results proved the safety of grafting material application. The prepared material exhibited good Ca-apatite crystal patterns at the surface revealed by SEM and high calcium content showed by EDX results. Good bone formation ability was also apparent histologically.

CONCLUSION: The prepared grafting material (MWCNTs) can serve as a delivery vehicle for osteogenic cells and osteogenic growth factor proteins in the bone development process.

Introduction

The ultimate goal of periodontal disease treatment and alveolar bone reconstruction is the regeneration of defeated structures as a result of infection, trauma or congenital abnormalities [1]. The renovation of the lost structures to reach optimum aesthetics and function is a major patients' demand [2]. The innate potential of bone regeneration or remodelling allows the impulsive repair of small bone defects. However, in multiple situations, the existing defect may be severe or the local environment is not favourable for adequate self-repair of the damaged or missing tissues [3], [4]. Bone grafts or bone graft substitutes are thus required to aid the healing of such decisive size or non-healing bone defects [5]. Various grafting materials contain most of the essential

elements required for stimulating bone regeneration, and therefore have been superior in current clinical practice for restoring damaged, diseased or resorbed bone tissue. These materials have been used effectively in the management of intrabony defects [6]. Filling the regenerative defect sites with a biocompatible substance offers a scaffold for host inhabitant cells to assist in the regenerative process via osseointegration or osseointegration pathways [7].

Since the autografting procedure has several disadvantages, not only because of the limited amount of the available bone that can be harvested, but also because the surgery is time-consuming and causes invasion of the intra or extraoral donor structures to increase the risk of donor site morbidity. The use of other bone substitute materials such as allografts and xenografts although numerous

documented as being osteoinductive/osteoconductive is still controversial due to the graft material resorption and the possible immunogenic reactions that might occur [8]. Therefore, the search for an ideal synthetic graft material continues [9]. In hard tissue management, a diversity of materials has been developed to imitate the explicit highly organised nanoscale structure of the bone, which consists of collagenous fibres and mineralised apatite nanocrystals [10]. Nanocomposite materials and natural polymers are getting a great deal of attention with the vision that these composite systems can offer a variety of benefits in preserving the structural and biological functions of the damaged tissues like or superior to the naturally present system [11], [12].

Carbon nanotubes (CNTs) have been under research in the precedent decade for a variety of applications due to their exceptional and multipurpose properties [13]. In the meadow of regenerative medicine, they have demonstrated immense promise to improve the quality of tissue engineering scaffolds [14]. CNTs a multi-functional nano-material have been introduced due to the outstanding electronic, mechanical, optical and chemical properties. Recently the use of CNTs or CNTs based composites (i.e. associated with different biological molecules or polymers) classified as single-walled carbon nanotubes (SWCNT) and multi-walled carbon nanotubes (MWCNT) in bone repair/regeneration has been documented as an innovative biomaterial in the reconstruction or regeneration of tissues [15], [16], [17].

Functionalisation of MWCNTs using different materials such as beta-cyclodextrin and natural plant extracts led to lowering of the cytotoxic behaviour of the resulting composites and allow using them as carriers according to the different previous reported works [18], [19], [20], [21], [22], [23].

The aim of this work deals with evaluating the effect of functionalised MWCNTs, as grafting material in the management of furcation defects created in dogs.

Material and Methods

In the present study, functionalised MWCNTs material was prepared and used as grafting material in created furcation defects in dogs. Histological evaluation of this material on the surrounding tissues, the signs of its biodegradation, and the evidence of new bone formation was investigated.

This study was carried out according to the ethical guidelines of the World Medical Association; Declaration of Helsinki as revised in 2000 for studies involving animal subjects and the study protocol was approved by the Medical Ethical Committee at the

National Research Centre (NRC) with a code no. 16467. Sample size calculation revealed that ($n = 6$) was enough to detect the main effects of the grafted material with a satisfactory level of power set at 80% and a 95% confidence.

Functionalisation of the MWCNTs grafting material

Pristine MWCNT (100 mg) was dispersed in mixed concentrated sulphuric and nitric acids (3:1, v/v) at a ratio of 50 ml acid mixture. The resulted mixture was then heated at 110°C overnight with continuous stirring to produce oxidised carbon nanotubes (MWCNTs-COOH). The sample was washed with ultrapure water until getting a neutral filtrate (pH 7). The collected solid was dried under vacuum at 70°C for 12 h and kept for further functionalisation and analysis [24].

Measurement of Potential Cytotoxicity

Potential Cytotoxicity of the studied material was examined using the method of Skehan et al., [25] in the Clinical Pharmacy Department at the National Cancer Institute, Egypt, to obtain the IC50 value which is the half-maximal inhibitory concentration to measure the potency of a substance in inhibiting a specific biological or biochemical function. Normal cell line (baby hamster kidney cells, BHK-21, Sigma-Aldrich, Germany) was plated in 96-multiwell plate (104 cells/well) for 24 h before application of the tested material to allow attachment of the cells to the wall of the plate. Different concentrations of the attested material (0, 1, 2.5, 5, and 10 µg/ml) were added to the cell monolayer triplicate wells prepared for each dose. Monolayer cells were incubated with the material for 24 h at 37°C and in an atmosphere of 5% CO₂. After 48 h, cells were fixed, washed, and stained with sulforhodamine B stain. Excess stain was washed with acetic acid, and the attached stain was removed with Tris-EDTA buffer. Colour intensity was measured in an enzyme-linked immunosorbent assay reader (ELISA reader, BioTek, USA). The relation between surviving fraction and material concentration is plotted to get the survival curve of each cell line after specified compound concentration.

In vitro bone bioactivity testing

The attested material was soaked in simulated body fluid (SBF) for 7 days then removed, rinsed using de-ionized water, and dried to complete the investigations. The material surface after soaking was examined via scanning electron microscope (SEM) and Electron dispersive x-ray (EDX) to confirm the formation of apatite. The bioactivity test was carried out three times for the sample to ensure the bioactivity behaviour [26].

Characterisation

Scanning electron micrographs (SEM) were recorded using JXA-840A Electron Probe Micro analyser JEOL-SEM. For SEM, the substrate was mounted on metal stubs and coated with gold-palladium with the thickness of deposit about 75Å at vacuum 7×10^{-2} millibar and 2.4-kilovolt cathodic voltage before being examined using Polaron SEM Coating Instrument.

Experimental Design

Six healthy young adult male mongrel dogs with age range 19-24 months and weighing from 13 to 16 kg, were selected for the study. Before the experiment, all dogs were examined by a vet, and those having good systemic and periodontal health were included in the study. The mandibular right third premolar (RP3) was considered as the control group and after the creation of the bony defect, it was left to undergo normal healing, while the mandibular right fourth premolar (RP4) on the same side received the CNT material (study group). Initially scaling and tooth brushing were performed for the selected teeth to control gingival inflammation for one week. During this period, plaque control was maintained by daily topical application of 0.12% chlorhexidine solution.

Surgical procedures

All surgical procedures were performed under systemic anaesthesia with an intravenous injection of sodium thiopental solution following sedation. The systemic anaesthesia was complemented with infiltration anaesthesia to ensure local homeostasis. Following the intrasulcular incisions around the selected teeth, full-thickness mucoperiosteal flap was raised on the buccal aspect to create two-wall intrabony defects "box- type" (4 mm inferior, 3 mm horizontal from the buccal surface of the roots in a buccolingual direction to the lingual bone wall, using a line tangential to the buccal root surface as reference and 5 mm height from the alveolar crestal bone to the base of the defect) at the furcation area using a water-cooled diamond fissure bur [12]. Each root surface was scaled and planed completely to remove remaining cementum and periodontal ligament. An experimental notch was placed at the most apical part of the exposed root using a round diamond bur with abundant irrigation. These notches were placed on the buccal aspects of the roots and extended interproximally and into the furcation areas as deep as the involvement of the furcation defect permitted, as a guideline for histological analysis. Following placement of the notches, the surgical sites were thoroughly irrigated with sterile saline. The study material was inserted in the created defect and the created defect at the control site was left to heal normally. The flaps were repositioned and sutured with non-absorbable sutures. From the evening before

surgery and for 4 days after surgery intramuscular injections with Vibramycin (0.1 g/15kg weight) were administered. The animals were fed only water-softened dog food to reduce the possibility of local trauma to the site of operation. After 7 days, the sutures were removed. Plaque control was maintained by daily topical application of 0.12% chlorhexidine solution until the time of sacrifice, which was performed by a thiopental overdose at 1, 2, and 3 months after surgery.

Tissue Processing

After euthanasia, which was performed by a thiopental sodium overdose 1, 2 and 3 months after the regenerative surgeries, the mandibles were dissected, and the tissues containing the experimental specimens were obtained.

The specimens were fixed in 10% buffered natural formaldehyde for 24 hours. The samples were kept in separate coded dishes containing 10% ethylene diamine tetraacetic acid (EDTA) for 8 weeks. As decalcification is completed, the specimens were washed in running water to remove all traces of EDTA. The specimens were gradually dehydrated in ascending concentration of ethyl alcohol (50%, 70%, 90%) and 2-3 changes of absolute alcohol to ensure replacement of water by alcohol. The specimens were defatted in two changes of xylene under vacuum. The specimens were infiltrated with paraffin into a constant temperature furnace, at about 60°C, until the xylene in the tissues was replaced completely by paraffin. The specimens were cut parallel to the long axis of the tooth so that serial sections could be performed and representing most of the induced defective area. Semiserial 7-mm-wide histological sections were made in a mesiodistal direction and the sections were stained with hematoxylin and eosin (H&E) for histological examination for signs of biodegradation as well as bony graft integration of the graft material and evidence of new bone formation.

Histological Analysis

Nine non-serial histological sections of each block, corresponding to the first three, central and last three sections, which contained notches in the roots were examined with a light microscope under conventional and polarised light to evaluate the areas of new bone formation in the induced furcation defects. Histological analysis was performed using the Leica Qwin 500 Image Analyzer Computer System (Leica Microsystems, Switzerland) with optical magnification of 100 and 200 x on the H & E slides.

The presence of the following reparative criteria was subjectively assessed: new woven bone formation, osteocytes and variability in their size, in addition to attempts of new mature bone (osteon) formation.

Measuring the area percent of newly formed bone

The area percent of newly formed bone was estimated using Leica Qwin 500 Image Analyzer Computer System, (Leica Microsystems, Switzerland). The cursor was used to outline the areas of newly formed bone trabeculae, which were then masked by a binary colour that could be measured by the computer. The image analyser is calibrated automatically to convert the measurement units (pixels) produced by the image analyser program into actual micrometre units. The area percent of newly-formed bone was estimated in 8 different fields in each group using magnification (x 100). Mean values and standard deviation (SD) were calculated for each group.

Statistical analysis

The data obtained from computer image analysis were tabulated and statistically analysed. Analysis of variance (ANOVA) test was used for statistical analysis of the difference between groups. Tukey's post hoc test was performed to reveal any significant difference. The unpaired t-test was used for pair-wise comparisons. P-value ≤ 0.05 was considered statistically significant.

Results

Potential cytotoxicity results

In vitro cytotoxic behaviour of the grafting material (MWCNTs) showed that the toxicity was increased with increasing the material concentration. The results revealed that the IC50 of MWCNTs was almost 73.1 $\mu\text{g/ml}$. These results were within the safety level of the application according to previous studies [27], [28].

Scanning electron microscope (SEM) results

SEM-micrographs showed the morphology of the prepared grafting material after incubation in SBF. It can be observed that calcium-apatite was formed with excellent crystal-like structures, as shown in Figure 1.




Figure 1: Scanning electron microscope (SEM) micrographs of the prepared FMWCNT

Energy dispersive x-ray (EDX) results

EDX results presented in Table 1 showed the high level of calcium content (Ca) of the grafted material.

Table 1: Energy dispersive x-ray (EDX) results showing the high calcium content after incubation of the grafted material

Element	Weight %	Atomic %
Carbon	11.14	27.38
Oxygen	2.63	4.86
Sulfur	22.92	21.11
Calcium	63.31	46.65

Clinical results

Clinical healing proceeded uneventfully. The animals tolerated the surgical procedures well, and postoperative signs were consistent with these following a localised periodontal flap surgery. At the time of sacrifice, all dogs showed a healthy periodontal condition without gingival recession or inflammation. There was no difference between the different experimental surgical sites based on clinical observation.

Histological results

Control group

One month after surgery: collagen-rich connective tissue (CT) matrix suggesting granulation tissue formation with little fibroblast and inflammatory cells was seen. At the lesion's edge, there were areas of condensed non-mineralized tissue within the undifferentiated CT, revealing the beginning of the new formation of bone tissues (Figure 2).

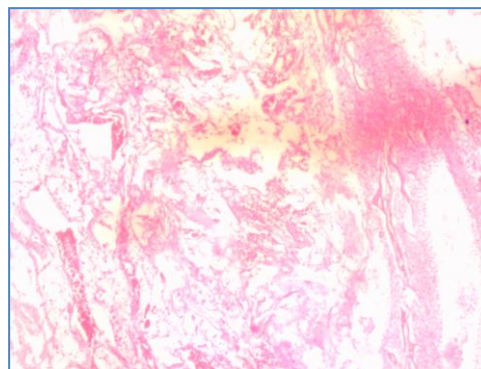


Figure 2: Photomicrograph of the control group (1 month) showing condensed collagen fibres with little fibroblast, inflammatory cells in collagen-rich CT matrix suggesting granulation tissue & ectopic bone formation within the granulation tissue (H & E)

Two months after surgery: the results showed mild bone remodelling which could be detected at the expense of granulation tissue in the form of ectopic in-growth of osteoid bone formation that was highly vascularised, irregular and with a limited number of entrapped bones forming cells (Figure 3).

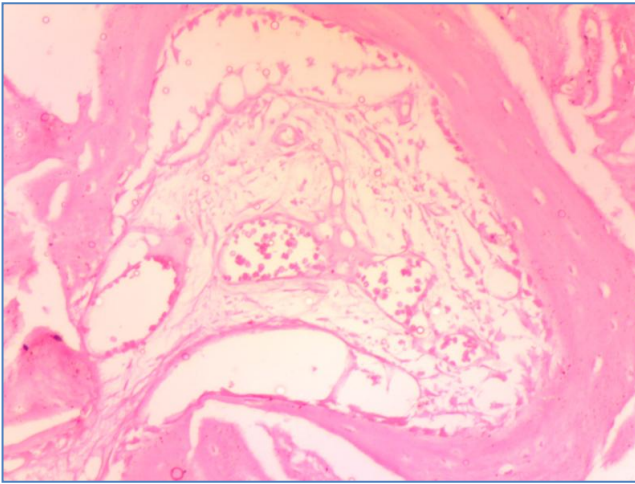


Figure 3: Photomicrograph of the control group (2 months) showing newly formed osteoid bone trabeculae replacing the granulation tissue with little number & small entrapped rounded osteocytes. Dilated blood vessels are seen within the granulation tissue (H & E)

Three months after surgery: newly formed tissue consisting of interconnected islands of newly formed bone trabeculae containing flattened osteoblasts, consistent with maturation into bone-lining cells was revealed. A complex layer of connective tissue comprised of blood vessels and collagen fibres oriented haphazardly to the bone surface covering the external aspect of the newly formed alveolar bone. Attempts of incomplete Haversian systems were also observed. No evidence of inflammatory reaction or fibrosis was detected (Figure 4).

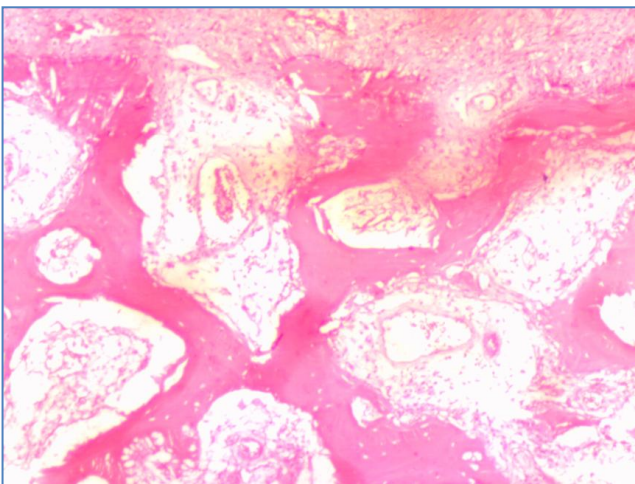


Figure 4: Photomicrograph of the control group (3 months) showing interconnected islands of thin trabeculae of new bone formation with flattened osteoblasts. Attempts of an incomplete Haversian system were also observed (H & E)

Study group (CNT group)

One month after surgery: the grafted material remained in the surgical area. The unresorbed material was predominantly surrounded by granulation tissue which demonstrated significant inflammatory

cell infiltration. Bone festooning (an indicator of resorption) and multinucleated giant cells having the histological features of osteoclasts were seen residing in their lacunae on the brink of the grafted material. Residual bone spicules bordered the bone defect and extended into the graft area as seen in Figure 5.

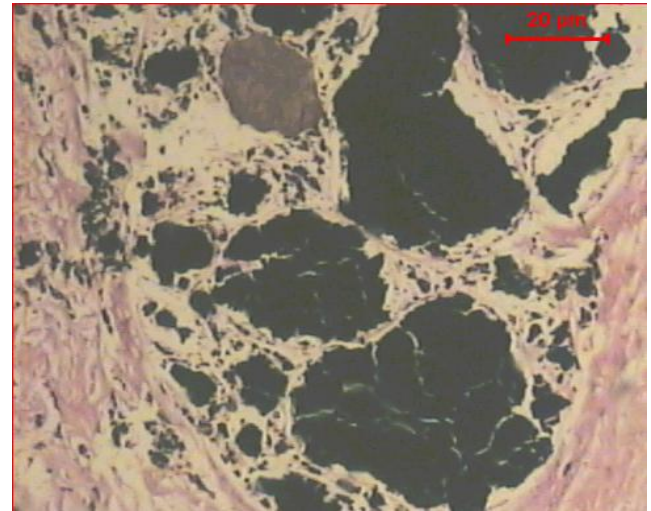


Figure 5: Photomicrograph of CNT group (1 month) showing big and small areas of the implanted material which appear black enclosed in fibrous capsules. Areas of collagenous fibres are also seen (H & E)

Two months after surgery: the outsized amount of the grafted material can still be seen in the surgical area. Little amount of newly formed bone was seen in the area. Some granulation tissue reaction can be seen next to the grafted material. A dense accumulation of fibrous tissue was observed walling off the material from the surrounding tissues. Heavy infiltration of inflammatory cells predominates in the surgical field (Figure 6).

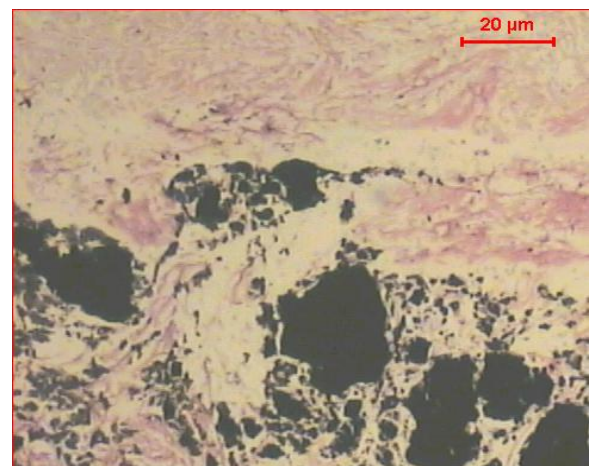


Figure 6: Photomicrograph of CNT group (2 months) showing signs of resorption of the implanted material. Evidence of newly formed bone and blood vessels are also apparent (H & E)

Three months after surgery: thinned bone trabeculae are seen radiating from the CNT material. Some of the grafted material can be seen in the surgical area. Mild inflammatory reaction was demonstrated. These slim trabeculae enclosed

irregular sized and shaped marrow spaces and widened osteocytic lacunae. A considerably thick collagen bundle is seen walling off the material from the surrounding bone tissues, as reported in Figure 7.

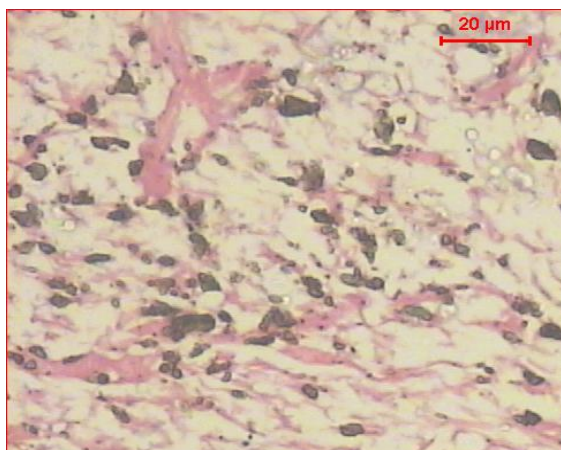


Figure 7: Photomicrograph of CNT group (3 months) showing lamellae of newly formed bone which are still associated with small areas of the grafting material (H & E)

Area percent of the newly formed bone

The greatest mean area percent of newly formed bone was recorded in the control group, whereas the least mean value was recorded in the study group. ANOVA test revealed a statistically significant difference ($p < 0.0001$).

Table 2: Mean area percent of newly formed bone and the significance of the difference between the groups

Group	Mean ± SD	Unpaired t-test	
		P-value of the different control group	P-value of difference study group
Control group	67.16 ± 2.27	-----	< 0.0001*
Study group	40.6 ± 5.73	< 0.0001*	-----
P value (ANOVA)	< 0.0001*		

*statistically significant at $p < 0.05$.

Comparing the control group with the study group using the unpaired t-test revealed a statistically significant difference ($p < 0.0001$) (Table 2).

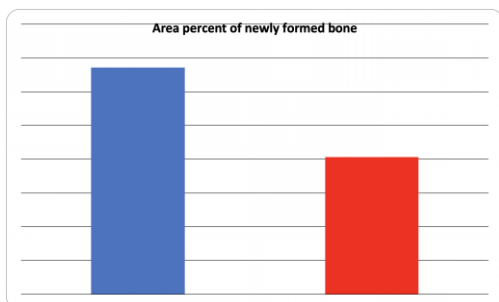


Figure 8: Column chart showing mean area percent of newly formed bone in different groups

Discussion

Bone tissue engineering has evolved as a substitution approach that depends on the use of biodegradable polymers which are of interest in medicine because of their commercial availability, biocompatibility, degradation into non-toxic products and the ability to control the material's characters as mechanical properties, porosity and surface charges [1].

Carbon nanotubes considered as one of the most important materials in nanotechnology and nanoscience nowadays. CNTs for bone regeneration are being developed, which use negatively charged functional groups with calcium bonded to them. This can provide a scaffold to which hydroxyapatite, the majority of the inorganic component of bone, can join. CNTs act as an exceptional substrate for cell growth and differentiation [29], [30], [31].

Little attention has been focused on the histological behaviour following grafting of CNTs in such a bony defect orally. Hence, it is of great interest to validate the healing and the potential for bone formation in a two walled bony defect created in the bifurcation of the mandibular premolar area in mongrel dogs using CNTs.

For any material to be used as a graft, it should have a strong mechanical and physical integrity to be able to function properly; it should also be biocompatible [12]. To test the material biocompatibility and tissue response in vivo, animal studies are considered to be the best assessment method. Dogs which were implanted with CNTs subcutaneously had no mortality, evident inflammation, behavioural changes or noticeable signs of physical self-mutilation during the post-operative examinations and at the time they were scarified. This is by the findings of Martins-Junior et al., [23] and Rajesh et al., [32].

The study design included a control group where the defects created are going to heal normally and a study group where CNTs were placed into the defects. The defects in both groups were left to heal for a similar time interval after which the animals were sacrificed, and the healing of both defects was assessed histologically.

In the control group evidence of woven bone formation was seen at the edge of the defect by the end of the first month, which became vascularised and denser at the end of the second month. Subsequently, by the end of the third month, the newly formed bone trabeculae were found to be lined by flattened osteoblasts denoting the formation of lamellar bone. These findings are consistent with those of Streitzel et al., [22] and conform to the normal healing pattern expected to be seen in such a bony defect.

It was obvious that the material resulted in a strong tissue response at the end of the second month. This was evident by the infiltration of the defect by multinucleated giant cells and fibrous encapsulation of the material walling it off from the surrounding bone. At the end of the third month, tiny traces of CNTs were still present in the defect with scarce evidence of new bone formation. The rate and amount of bone formation were slow when compared to the natural healing in the control group. This is contradictory with other results which demonstrate the higher potentiality of CNTs for bone regeneration [32].

This could be explained by the fact that the most frequent applications for these carbon materials are their inclusion as reinforcement in polymer matrices due to its weak mechanical properties. This was evident in the results of Mwenifumbo et al., [33] and White et al., [34] who used CNTs to reinforce hydroxyapatite which was then implanted in a bone defect in the rabbit's femur. Their four months' results demonstrated the growth of a web-like soft callus from the host bone towards the reinforced CNTs with a hydroxyapatite implant, indicating a strong host bone interaction.

In conclusion, the results obtained from the proposed study demonstrated the potential of CNTs for bone regeneration applications. It concluded that more time interval might be needed to achieve a better bone regenerative effect. Also, reinforcement of CNTs as a carrier in polymer matrices could attain enhanced bone modelling in PDL bony defect and might have a significant impact on the ability to restore functional activity in injured patients. Further investigation is needed to validate the potential role of CNTs in periodontal ligament bony defects.

References

- Zaky SH, Cancedda R. Engineering craniofacial structures: facing the challenge. *Journal of Dental Research*. 2009; 88:1077-91. <https://doi.org/10.1177/0022034509349926> PMID:19897785
- Park H, Choi B, Hu J, Lee M. Injectable chitosan hyaluronic acid hydrogels for cartilage tissue engineering. *Acta Biomaterialia*. 2013; 9:4779-86. <https://doi.org/10.1016/j.actbio.2012.08.033> PMID:22935326
- Ravichandran R, Venugopal JR, Sundarajan S, Mukherjee S, Ramakrishna S. Minimally invasive cell-seeded biomaterial systems for injectable/epicardial implantation in ischemic heart disease. *International Journal of Nanomedicine*. 2012; 7:5969-94. <https://doi.org/10.2147/IJN.S37575> PMID:23271906 PMID:PMC3526148
- Robey PG. Stem cells near the century mark. *The Journal of Clinical Investigation*. 2000; 105:1489-91. <https://doi.org/10.1172/JCI10256> PMID:10841501 PMID:PMC300867
- Miron RJ, Zhang YF. Osteoinduction: a review of old concepts with new standards. *Journal of Dental Research*. 2012; 91:736-44. <https://doi.org/10.1177/0022034511435260> PMID:22318372
- Tai YY, Chen RS, Lin Y, Ling TY, Chen MH. FGF-9 accelerates epithelial invagination for ectodermal organogenesis in real time bioengineered organ manipulation. *Cell Communication and Signaling*. 2012; 10:1-10. <https://doi.org/10.1186/1478-811X-10-34> PMID:23176204 PMID:PMC3515343
- Fujinami K, Yamamoto S, Ota M, Shibukawa Y, Yamada S. Effectiveness of proliferating tissues in combination with bovine-derived xenografts to intrabony defects of alveolar bone in dogs. *Biomed Res*. 2007; 28:107-13. <https://doi.org/10.2220/biomedres.28.107> PMID:17510496
- Brunsvold MA, Mellonig J. Bone grafts and periodontal regeneration. *Periodontol*. 2000; 1:80-91. <https://doi.org/10.1111/j.1600-0757.1993.tb00209.x>
- Shirakata Y, Kawada M, Fujiki Y, Sano H, Oda M, Yaginuma K, Kobayashi M, Koike K. The X-gene of hepatitis B virus induced growth stimulation and tumorigenic transformation of mouse NIH3T3 cells. *Japanese Journal of Cancer Res*. 2002; 80: 617-21. <https://doi.org/10.1111/j.1349-7006.1989.tb01686.x> PMID:2507484 PMID:PMC5917810
- Boskey AL. Will biomimetics provide new answers for old problems of calcified tissues? *Calcif Tissue Int*. 2000; 63:179-82. <https://doi.org/10.1007/s002239900511> PMID:9701619
- Mathieu S, Jeanneau C, Shebat-Othman N, Kalaji N, Fessi H, About I. Usefulness of controlled release of growth factors in investigating the early events of dentin-pulp regeneration. *Journal of Endodontics*. 2013; 39:228-35. <https://doi.org/10.1016/j.joen.2012.11.007> PMID:23321236
- Ahmed A. Haroun, Amany H. Neamat, Sherine A. Nasry, Basma M. Zaki. Histological Study of Novel Bone Grafts Based on β -Cyclodextrin/ Hydroxyapatite for Class II Furcation Defects in Dogs *Journal of Applied Sciences Research*. 2013; 9:3820-33.
- Namgung S, Baik KY, Park J, Hong S. Controlling the growth and differentiation of human mesenchymal stem cells by the arrangement of individual carbon nanotubes. *ACS Nano*. 2011; 5:7383-90. <https://doi.org/10.1021/nn2023057> PMID:21819114
- Ogihara N, Usui Y, Aoki K, Shimizu M, Narita N, Hara K, et al. Biocompatibility and bone tissue compatibility of alumina ceramics reinforced with carbon nanotubes. *Nanomedicine-Uk*. 2012; 7:981-93. <https://doi.org/10.2217/nnm.12.1> PMID:22401267
- Usui Y, Aoki K, Narita N, Murakami N, Nakamura I, Nakamura K, et al. Carbon nanotubes with high bone-tissue compatibility and bone-formation acceleration effects. *Small*. 2008; 4:240-6. <https://doi.org/10.1002/smll.200700670> PMID:18205152
- Abarrategi A, Gutierrez MC, Moreno-Vicente C, Hortiguera MJ, Ramos V, Lopez-Lacomba JL, et al. Multiwall carbon nanotubes scaffolds for tissue engineering purposes. *Biomaterials* 2008; 29:94-102. <https://doi.org/10.1016/j.biomaterials.2007.09.021> PMID:17928048
- Scheller EL, Krebsbach PH, Kohan DH. Tissue engineering: state of the art in oral rehabilitation. *J Oral Rehabil*. 2009; 36:368-389. <https://doi.org/10.1111/j.1365-2842.2009.01939.x> PMID:19228277 PMID:PMC2744808
- Zanello LP, Zhao B, Hu H, Haddon RC. Bone cell proliferation on carbon nanotubes. *Nano Lett*. 2006; 6:562-7. <https://doi.org/10.1021/nl051861e> PMID:16522063
- Haroun AA, Hala A. Amin, Sameh H Abd El-Alim. Preparation, Characterization and In vitro Biological Activity of Soyasapogenol B Loaded onto Functionalized Multi-walled Carbon Nanotubes. *Current Bioactive Compounds*. 2018; 14:364-72. <https://doi.org/10.2174/1573407213666170407165917>
- Haroun AA, Hala A. Amin, Sameh H Abd El-Alim. Immobilization and in vitro evaluation of soyasapogenol B onto functionalized multi-walled carbon nanotubes. *IRBM*. 2018; 39:35-42. <https://doi.org/10.1016/j.irbm.2017.12.003>
- Haroun AA, Abdel-Tawab H Mossa, Samia MM Mohafrash. Preparation and biochemical evaluation of functionalized multi-walled carbon nanotubes with Punica granatum extract. *Current Bioactive Compounds*. 2019; 15:138-44. <https://doi.org/10.2174/1573407214666180530095912>
- FP, Pathawee Khongkhunthian, Rutch Khattiya, Prapas

- Patchanee Peter A. Reichart. Healing Pattern of Bone Defects Covered by Different Membrane Types-A Histologic Study in the Porcine Mandible. *J Biomed Mater Res.* 2006; 78B:35-46. <https://doi.org/10.1002/jbm.b.30452> PMID:16362958
23. Martins-Junior PA, Alcantara CE, Resende RR, Ferreira AJ. Carbon nanotubes: directions and perspectives in oral regenerative medicine. *Journal of Dental Research* 2013; 92: 575-83. <https://doi.org/10.1177/0022034513490957> PMID:23677650
24. Marshall MW, Popa-Nita S, Shapter JG. Measurement of functionalized carbon nanotubes carboxylic acid groups using a simple chemical process. *Carbon.* 2006; 44:1137. <https://doi.org/10.1016/j.carbon.2005.11.010>
25. Skehan P, Storeng R, et al. New colometric Cytotoxicity assay for anti-cancer drug screening. *J Natl Cancer Inst.* 1990; 82:1107-12. <https://doi.org/10.1093/jnci/82.13.1107> PMID:2359136
26. Oyane A, H-M Kim, T. Furuya, T. Kokubo, T. Miyazaki and T. Nakamura,. Preparation and assessment of revised simulated body fluid. *J. Biomed. Mater. Res.* 2003; 65A:188-95. <https://doi.org/10.1002/jbm.a.10482> PMID:12734811
27. Haroun AA, Taie HA. Cytotoxicity and antioxidant activity of beta vulgaris extract released from grafted carbon nanotubes based nanocomposites. *Macromolecular Symposia.* 2014; 337:25-33. <https://doi.org/10.1002/masy.201450303>
28. Ahmed AA, Amany M Elnahrawy, Howaida I Abd-Alla. Sol-gel preparation and in vitro cytotoxic activity of nanohybrid structures based on multi-walled carbon nanotubes and silicate. *Inorganic and Nano-Metal Chemistry.* 2017; 47:1023-27. <https://doi.org/10.1080/24701556.2017.1284087>
29. Haroun AA, Migonney V. Synthesis and in vitro evaluation of gelatin/hydroxyapatite graft copolymers to form bionanocomposites. *Int J Biological Macromolecules.* 2010; 46:310-16. <https://doi.org/10.1016/j.ijbiomac.2010.01.005> PMID:20083133
30. Haroun AA, Beheri HH, Abd El-Ghaffar MA. Preparation, characterization and in vitro application of composite films based on gelatin and collagen from natural resources. *J Appl Polym Sci.* 2010; 116:2083-94. <https://doi.org/10.1002/app.31714>
31. Mercer RR, Hubbs AF, Scabilloni JF, Wang L, Battelli LA, Schwegler-Berry D, Castranova V, Porter DW. Distribution and persistence of pleural penetrations by multi-walled carbon nanotubes. *Particle and Fibre Toxicology.* 2010; 7(1):28. <https://doi.org/10.1186/1743-8977-7-28> PMID:20920331 PMID:PMC2958975
32. Rajesh R, Senthilkumar N, Hariharasubramanian A, Ravichandran YD. Review on hydroxyapatite-carbon nanotube composites and some of their applications. *International Journal of Pharmacy and Pharmaceutical Sciences.* 2012; 4:23-7.
33. Mwenifumbo S, Shaffer MS, Stevens MM. Exploring cellular behaviour with multi-walled carbon nanotube constructs. *J Mater Chem.* 2007; 17:1894-902. <https://doi.org/10.1039/b617708e>
34. White AA, Best SM, Kinloch IA. Hydroxyapatite-carbon nanotube composites for biomedical applications: A review. *International Journal of Applied Ceramic Technology.* 2007; 4:1-13. <https://doi.org/10.1111/j.1744-7402.2007.02113.x>