

# Oral Health-Related Quality of Life in Single Implant Mandibular Overdenture Retained by CM LOC versus Ball Attachment: A Randomized Controlled Trial

Marwa AbdelAal<sup>\*</sup>, Ahmed Fayyad, Nora Sheta, Nouran AbdelNabi, Mahmoud Mokhtar ELFar

*Department of Prosthodontics, Faculty of Dentistry, Cairo University, Cairo, Egypt*

## Abstract

**Citation:** AbdelAal M, Fayyad A, Sheta N, AbdelNabi N, ELFar MM. Oral Health-Related Quality of Life in Single Implant Mandibular Overdenture Retained by CM LOC versus Ball Attachment: A Randomized Controlled Trial. Open Access Maced J Med Sci. <https://doi.org/10.3889/oamjms.2019.792>

**Keywords:** Single implant; Mandibular; Overdenture; Quality of life

**\*Correspondence:** Marwa AbdelAal. Department of Prosthodontics, Faculty of Dentistry, Cairo University, Cairo, Egypt. E-mail: [marwa.abdelaal1@gmail.com](mailto:marwa.abdelaal1@gmail.com)

**Received:** 04-Aug-2019; **Revised:** 21-Sep-2019; **Accepted:** 22-Sep-2019; **Online first:** 11-Oct-2019

**Copyright:** © 2019 Marwa AbdelAal, Ahmed Fayyad, Nora Sheta, Nouran AbdelNabi, Mahmoud Mokhtar ELFar. This is an open-access article distributed under the terms of the Creative Commons Attribution-NonCommercial 4.0 International License (CC BY-NC 4.0)

**Funding:** This research did not receive any financial support

**Competing Interests:** The authors have declared that no competing interests exist

**AIM:** This randomised clinical study aimed to detect whether CMLOC attachment could improve Oral Health-Related Quality of Life (OHRQOL) when compared to ball attachment.

**METHODS:** Eighty edentulous patients were recruited to receive a single symphyseal implant for mandibular overdenture, after three months, randomisation was done to divide them into two groups; Dalbo ball (control group) and Cendres and Metaux locator (CM-LOC) (intervention) attachments respectively, oral health impact profile for edentulous patients (OHIP-EDENT) questionnaire was recorded before implant placement, two weeks after pick up, at 3, 6, 9, and 12 months.

**RESULTS:** Results revealed a lack of statistical significance between the two groups except for psychological discomfort at 2 weeks after pick-up (p-value = 0.029)

**CONCLUSION:** Single implant overdenture is a simple, reliable treatment modality for treating edentulous mandible and both CM LOC and Ball attachments are good alternatives for such treatment modality.

## Introduction

The dental implant had offered a fixed prosthetic treatment modality for edentulism and added retention to complete dentures [1].

The introduction to single mandibular implant overdenture (SMIOD) went back to Cordioli et al., in 1997, it was only preceded with a single report in 1991 where Naert et al., had used an overdenture attached to one implant until an additional implant installation [2].

SMIOD had offered minimal surgical procedure with less expected postoperative complications, and fewer expenses compared to two or more MIOD. It also offered a prosthetic implant solution in case of insufficient bone at the canine

region and saved the patient a longer duration more complicated grafting procedure [3].

Ball attachment is commonly employed in single implants because its elastic retainer allows for the slight rotation of the overdenture transmitting the load to surrounding bone tissue and balancing the axial load resulting in less implant-bone tissue damage [4]. On the other hand, it had expressed high maintenance frequency, and inability to use with divergent implants as it is impossible to establish an axis of rotation [5].

A novel locator attachment system with a matrix made from polyether ketone (PEKK), was manufactured by Cendres and Métaux which claimed to offer high chemical and mechanical resistance against wear and high tensile, fatigue and flexural strengths [6].

CMLOC attachment (the commercial name) had expressed high initial retention values for both vertical (22.5N) and tilted (27.4 N) implants [7].

Patient-relevant outcomes are becoming increasingly popular in dentistry in assessing dental service and prosthesis [8]. The term "quality of life" was preferred by Locker and Allen as it was defined as being broader than merely "health" or "disease" [9]. Oral health impact profile (OHIP) was justified for being a sensitive OHRQOL tool to record clinically significant differences between different prosthodontic treatments [10].

OHIP-EDENT is a modified form of (OHIP) addressing edentulous subject [9]. It stands for 19 questions denoting seven domains: functional limitation, physical pain, psychological discomfort, physical disability, psychological disability, social disability, and handicap [11].

The OHIP-EDENT could detect changes in the OHRQoL among denture wearers before and after they receive new prostheses [10].

This study was therefore conducted to assess the improvement of the CM-LOC over ball attachments regarding ORQOL in patients receiving SMIOD.

## Methods

The study was Randomized controlled, 1: 1 allocation ratio, Parallel grouped with superiority frame.

Eighty eligible patients of age range 50-69 years, were recruited in the out-patient prosthodontics clinic, at faculty of Dentistry-Cairo university.

Patients with absolute contraindication for implant placement were excluded (i.e., recent myocardial infarction, valvular prosthesis surgery, immunosuppression, active treatment of malignancy, drug abuse and psychiatric illness) [12]. Patients with a recent glycosylated haemoglobin analysis test (HbA1c) (i.e., less than a month test) results that showed greater than 8% were also excluded (According to American Association of Diabetes) [13].

Based on Bilhan et al., 2011 [14], the absolute difference of total score of QOL  $6.4 \pm 8.3$ . A total sample size of 58 patients (29 in each group) was sufficient. This number had to be increased to 66 to correct for non-parametric usage and again to 78 patients to compensate for losses during follow up. The sample size was calculated by the G power program.

The selected patients were informed about all procedures and asked to sign an informed consent

before study joining. Dentures assessment and reconstruction (when necessary) were guaranteed followed by adaptation period for denture settling. OHIP-EDENT was recorded for complete denture wearers before implant installation

Dentures were duplicated resulting in a clear acrylic resin stent with Radiopaque auto polymerising resin (Jet XR™ Opaque Powder, Lang Dental Mfg Co Inc, USA) at the lower central incisors space to act as a reference for the implant site after cone beam radiograph. A CBCT scan was used for surgical planning. This radiographic template was modified during surgery to act as a surgical stent. A dose of 2g amoxicillin-clavulanic (Augmentin, Egypt) was given 1 hour before surgery [15]. Zero-point two percent Chlorohexidine mouth wash (Hexitol, Egypt) preoperative oral rinse was also instructed.

Crestal incision was cut in the inter-canine region using surgical blade number 15 (Swann-Morton-England). If the bone width was less than 5 mm, a short releasing incision was done for better accessibility to bone plateauing. A full-thickness flap was reflected using a mucoperiosteal elevator (Martin-Germany). Drilling was started with a cortical drill (if no plateauing was done), followed by a pilot, intermediate and final drill of a size 3.4 mm in diameter and 10 mm length. All implants installed in this study were Zimmer Dental (Implants ZDI, Tapered screw vent Indiana America) of diameter 3.7 mm, and length 10 mm. Soft tissue depth over the implant was measured by a periodontal probe to select the height of the healing cap before its placement. The flap was repositioned and properly adapted with either interrupted or continuous mattress suture Figure 1.

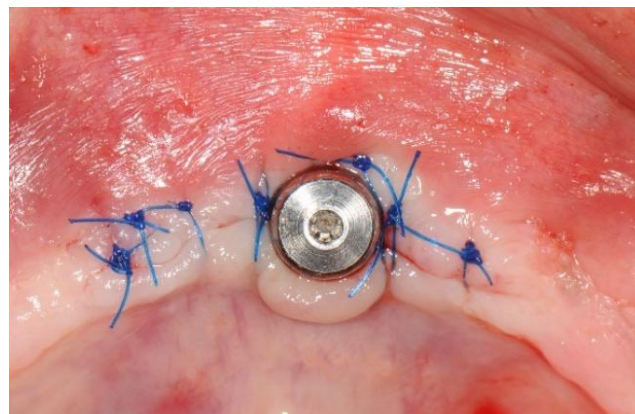


Figure 1: A single midline implant with a healing cap

Denture adjustments were made to suit the new condition with adequate relief opposite the healing cap, a small amount of soft liner (Coe soft, GC America, USA) was used anteriorly in the fitting surface of the mandibular denture. Post-operative instructions and oral hygiene measures were emphasised for all patients.

The healing phase lasted for three months after which patients were assigned to one of the two

attachments groups (ball or CM-LOC) using non-transparent sealed envelopes for randomisation.

Blinding was impossible due to the difference in the attachment shape.

After selecting the proper attachment height (with a plastic periodontal probe) the attachment was torqued, and a housing was seated over it, denture was relieved until lacking housing interference, dryness, bonding and light-curing then pick up with self-curing bis-acrylate resin material (Luxa-pick up, DMG, Hamburg, Germany) was done Figure 2.

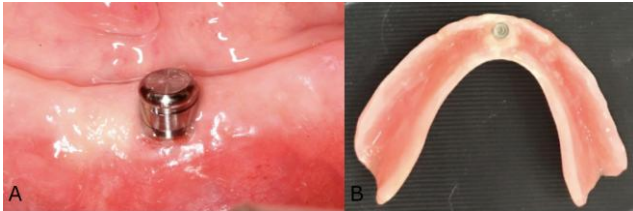


Figure 2: A) CM-LOC attachment; B) Nylon cap and housing (of Dalbo ball)

A translated form from a validated questionnaire was used to address the Egyptian population; all patients had to answer the same questionnaire two weeks after pickup, 3, 6, 9, 12 months respectively. Each answer was given a score from 0 to 4 where the lesser the score the better the quality of life, data was collected, and privacy was ensured Figure 3.

<b>A-functional limitation.</b> 1. Have you had difficulty chewing any foods because of problems with your denture?	
2. Have you had food catching in your dentures?	
3. Have you felt that your dentures haven't been fitting properly?	
<b>B-physical pain.</b> 4. Have you had painful aching in your mouth?	
5. Have you found it uncomfortable to eat any food because of problems with your dentures?	
6. Have you had sore spots in your mouth?	
7. Have you had uncomfortable dentures?	
<b>C-Psychological disorder.</b> 8. Have you been worried by dental problems?	
9. Have you been self-conscious because of your dentures?	
<b>D- Physical disability</b> 10. Have you had to avoid eating some food because of problems with your dentures?	
11. Have you been un able to eat with your dentures because of problems with them?	
12. Have you had to interrupt meals because of problems with your dentures?	
<b>E- Psychological disability</b>	
13. Have you been upset because of problems with your dentures?	
14. Have you been a bit embarrassed because of problems with your dentures?	
<b>F- Social disability</b>	
15. Have you avoided going out because of problems with your dentures?	
16. Have you been less tolerant of your spouse or family because of problems with your dentures?	
17. Have you been a bit irritable with other people because of problems with your teeth, mouth or denture?	
<b>G Handicap</b>	
18. Have you been unable to enjoy other people company as much because of problems with your dentures?	
19. Have you felt that life in general was less satisfying because of problems with your dentures?	
0=never	1=hardly ever
2=occasionally	3=fairly often
4=very often	

Figure 3: OHIP-EDENT questionnaire

## Results

Eighty patients were grouped equally into either ball, or CM-LOC 6 failures occurred after implant installation (lack of osseointegration), and three dropouts (two travelled and one jailed) before attachment placement, after pickup one patient died in the ball group and five dropouts (2 from ball and 3 from CM-LOC group) through a whole year either due to hospitalisation, travelling, starting a distant job and post-divorce depression. The summary of the flowchart is in Figure 4.

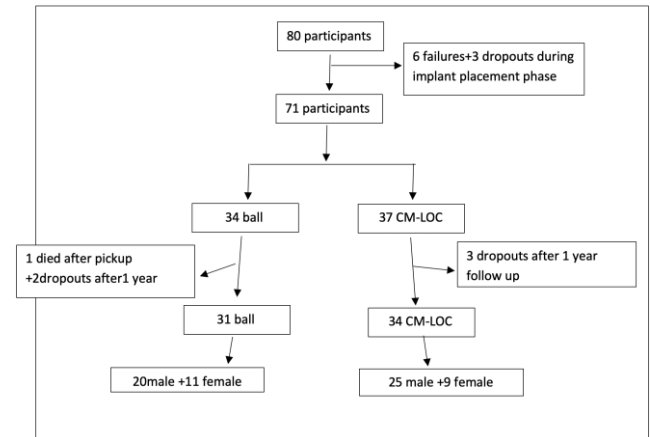


Figure 4: Participants flow chart

Scores of OHIP EDENT were tabulated in an excel sheet. Data were statistically described in terms of mean ± standard deviation (± SD) Comparison of numerical variables between the study groups was done using Mann Whitney U test for independent samples. Within group, comparison of numerical variables was done using Wilcoxon signed rank test for paired (matched) samples.

To detect the effect of gender variability in each group, exact test was used instead of Chi-square ( $\chi^2$ ) test as the expected frequency was less than 5. p values < 0.05 was considered statistically significant. In this study, p value was > 0.05 denoting lack of statistical significance between groups regarding the gender.

Table 1: Mean score of OHIP-EDENT of both groups at different time intervals

Group		Total-Baseline	Total-2w	Total-3m	Total-6m	Total-9m	Total-12m
Ball	Mean	23.50	9.05	8.04	8.11	10.96	10.11
	Std. Deviation	17.065	9.437	8.324	8.750	14.339	14.436
CM LOC	Mean	18.71	11.04	7.76	6.86	7.44	5.45
	Std. Deviation	12.770	12.252	8.155	9.058	9.791	7.037
	p value	0.258	0.859	0.783	0.748	0.367	0.327

All statistical calculations were done using computer program IBM SPSS ((Statistical Package for the Social Science; IBM Corp, Armonk, NY, USA) release 22 for Microsoft Windows. The effect of time

on each group was shown in Table 1; the base line denoted scores before implant placement i.e. during complete denture (CD) period, 2 w = 2 weeks after pick-up, (m) referred to months, i.e., 3 m meant three months follow up results.

From the above table, it was observed the lack of statistical significance in both groups, despite the statistically significant improvement of both groups when compared to complete denture ( $p < 0.05$ ).

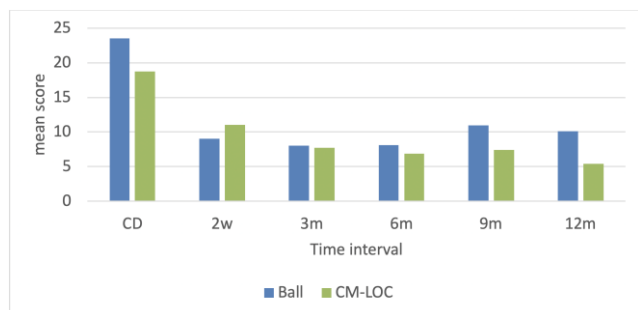


Figure 5: Mean score of OHIP-EDENT between the ball and CM-LOC expressing statistical significance compared to baseline and lack of significance through 1 year follow up

Clinically, patients with CM-LOC attachment had expressed relatively better results than those with ball group except two weeks after pick-up where CM-LOC patients found difficulty in insertion and removal of the attachment which had significantly affected the psychological discomfort domain ( $p = 0.029$ ) when compared to ball group Figure 6.

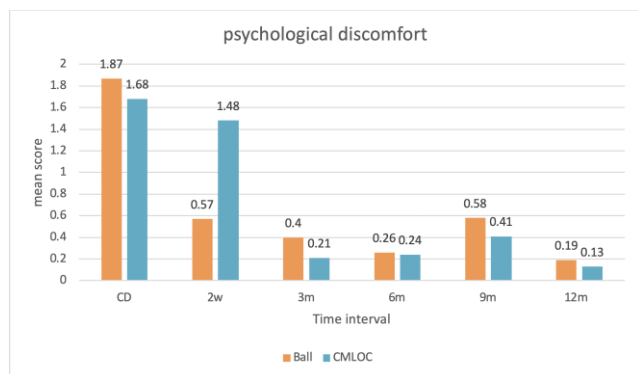


Figure 6: Psychological discomfort domain between two groups at a different time interval

## Discussion

When comparing SMIOD with a complete denture, a statistically significant difference was observed at all domains regardless of the attachment type, the attachment insertion highly improved patient mastication, decreased pain due to decrease in denture motion (better fixation) which had reflected positively on patient comfort and social interaction.

This result confirmed with Cheng et al., 2012, where both locator and magnet attachments were interchanged in a cross-section study to find improvement from complete denture regardless of the attachment fastened [16]. It also confirmed with Ismail et al., 2015, in two years of study where ball and magnets had shown similar improvement from the complete denture baseline records [17].

Ball had shown relatively better results 2 weeks after pickup (zero mean score) due to high initial retention values compared to CMLOC, that added confidence and psychological stability to the patient in addition to the ease of insertion and removal caused by its spherical geometry unlike the cylindrical CM-LOC this conformed with Harder et al., 2011, in his three years study which had shown significant improvement in chewing ability and quality of life with ball attachment [18]. The quality of life improvement of SMIOD was also proven by Passia et al., 2014, systematic review [19].

The total score of the whole questionnaire had exhibited similar results in both groups except at nine and 12 months, where it favoured the CM-LOC group. This was related to the change of PEKK matrices at six months causing retention promotion compared to the nylon cap which necessitates changing at nearly 12 m follow up.

In conclusion, Single implant overdenture is a simple, reliable treatment modality for treating edentulous mandible and both CM LOC and Ball attachments are good alternatives for such treatment modality. CM-LOC seemed to offer promising results, but care should be given to the frequency of matrix changing and maintenance.

## References

- Misch CE. Dental Implant Prosthetics. 2 edition. St. Louis, Missouri: Elsevier Mosby; 2015. <https://doi.org/10.1016/B978-0-323-07845-0.00016-6>
- Naert I, Quirynen M. Prosthetic aspects of osseointegrated overdentures. A 4-year report. J Prosthet Dent. 1991; 65(5):671-680. [https://doi.org/10.1016/0022-3913\(91\)90205-B](https://doi.org/10.1016/0022-3913(91)90205-B)
- Schneider GB, Synan WJ. Use of a single implant to retain a mandibular complete overdenture on the compromised atrophic alveolar ridge : a case report. 2011; 1:138-142. <https://doi.org/10.1111/j.1754-4505.2011.00196.x> PMID:21729123
- Cehreli MC, Karasoy D, Kokat AM, Akca K, Eckert SE. Systematic review of prosthetic maintenance requirements for implant-supported overdentures. Int J Oral Maxillofac Implants. 2018; 25(1):163-180.
- Cepa S, Koller B, Spies BC, Stampf S, Kohal RJ. Implant-retained prostheses: ball vs. conus attachments - A randomized controlled clinical trial. Clin Oral Implants Res. 2017; 28(2):177-185. <https://doi.org/10.1111/clr.12779> PMID:26813242
- Fuhrmann G, Steiner M, Freitag-Wolf S, Kern M. Resin bonding to three types of polyaryletherketones (PAEKs) - Durability and influence of surface conditioning. Dent Mater. 2014; 30(3):357-363.

- <https://doi.org/10.1016/j.dental.2013.12.008> PMID:24461250
7. Passia N, Ghazal M, Kern M. Long-term retention behaviour of resin matrix attachment systems for overdentures. *J Mech Behav Biomed Mater.* 2016; 57:88-94. <https://doi.org/10.1016/j.jmbbm.2015.11.038> PMID:26705935
8. Aarabi G, John MT, Schierz O, Heydecke G, Reissmann DR. The course of prosthodontic patients' oral health-related quality of life over a period of 2 years. *J Dent.* 2015; 43(2):261-268. <https://doi.org/10.1016/j.jdent.2014.09.006> PMID:25242099
9. Allen F, Locker D. A modified short version of the oral health impact profile for assessing health-related quality of life in edentulous adults. *Int J Prosthodont.* 2002; 15(5):446-450.
10. Awad M, Al-Shamrany M, Locker D, Allen F, Feine J. Effect of reducing the number of items of the Oral Health Impact Profile on responsiveness, validity and reliability in edentulous populations. *Community Dent Oral Epidemiol.* 2008; 36(1):12-20.
11. Sivakumar I, Sajjan S, Ramaraju AV, Rao B. Changes in Oral Health-Related Quality of Life in Elderly Edentulous Patients after Complete Denture Therapy and Possible Role of their Initial Expectation: A Follow-Up Study. *J Prosthodont.* 2015; 24(6):452-456. <https://doi.org/10.1111/jopr.12238> PMID:25523793
12. Hwang D, Wang HL. Medical contraindications to implant therapy: part I: absolute contraindications. *Implant Dent.* 2006; 15(4):353-360. <https://doi.org/10.1097/01.id.0000247855.75691.03> PMID:17172952
13. Naujokat H, Kunzendorf B, Wiltfang J. Dental implants and diabetes mellitus-a systematic review. *Int J Implant Dent.* 2016; 2(1):1-10. <https://doi.org/10.1186/s40729-016-0038-2> PMID:27747697 PMCid:PMC5005734
14. Mumcu E, Bilhan H, Geckili O. The effect of attachment type and implant number on satisfaction and quality of life of mandibular implant-retained overdenture wearers. *Gerodontology.* 2012; 29(2):e618-23. <https://doi.org/10.1111/j.1741-2358.2011.00531.x> PMID:21726276
15. Andrade NK, Ramacciato JC, Carvalho PS, Groppo FC, Motta RH. Evaluation of two amoxicillin protocols for antibiotic prophylaxis in implant placement surgeries. *RGO-Revista Gaúcha de Odontologia.* 2017; 65(3):249-53. <https://doi.org/10.1590/1981-863720170002000103371>
16. Cheng T, Ma L, Liu XL, et al. Use of a single implant to retain mandibular overdenture: A preliminary clinical trial of 13 cases. *J Dent Sci.* 2012; 7(3):261-266. <https://doi.org/10.1016/j.jds.2012.02.001>
17. Ismail HA, Mahrous AI, Banasr FH, Soliman TA, Baraka Y. Two Years Retrospective Evaluation of Overdenture Retained by Symphyseal Single Implant Using Two Types of Attachments. *J Int oral Heal JIOH.* 2015; 7(6):4-8.
18. Harder S, Wolfart S, Egert C, Kern M. Three-year clinical outcome of single implant-retained mandibular overdentures-Results of preliminary prospective study. *J Dent.* 2011; 39(10):656-661. <https://doi.org/10.1016/j.jdent.2011.07.007> PMID:21821093
19. Passia N, Kern M. The single midline implant in the edentulous mandible: a systematic review. *Clin Oral Investig.* 2014; 18(7):1719-1724. <https://doi.org/10.1007/s00784-014-1248-8> PMID:24872321