

# Short Term Effectiveness of Gamma Knife Radiosurgery in the Management of Brain Arteriovenous Malformation

Bassam Mahmood Flamerz Arkawazi<sup>1</sup>, Moneer K. Faraj<sup>2</sup>, Zaid Al-Attar<sup>3\*</sup>, Hayder Ali A. Hussien<sup>1</sup>

<sup>1</sup>Al-Kindy College of Medicine, University of Baghdad, Baghdad, Iraq; <sup>2</sup>College of Medicine, University of Baghdad, Baghdad, Iraq; <sup>3</sup>Pharmacology Department, Al-Kindy College of Medicine, University of Baghdad, Baghdad, Iraq

## Abstract

**Citation:** Arkawazi BMF, Faraj MK, Al-Attar Z, Hussien HAA. Short Term Effectiveness of Gamma Knife Radiosurgery in the Management of Brain Arteriovenous Malformation. Open Access Maced J Med Sci. <https://doi.org/10.3889/oamjms.2019.802>

**Keywords:** Arteriovenous malformations; Radiosurgery; Gamma knife

**\*Correspondence:** Zaid Al-Attar. Pharmacology Department, Al-Kindy College of Medicine, University of Baghdad, Baghdad, Iraq. E-mail: [zaidattar@kmc.uobaghdad.edu.iq](mailto:zaidattar@kmc.uobaghdad.edu.iq)

**Received:** 12-Jul-2019; **Revised:** 12-Sep-2019; **Accepted:** 13-Sep-2019; **Online first:** 14-Oct-2019

**Copyright:** © 2019 Bassam Mahmood Flamerz Arkawazi, Moneer K. Faraj, Zaid Al-Attar, Hayder Ali A. Hussien. This is an open-access article distributed under the terms of the Creative Commons Attribution-NonCommercial 4.0 International License (CC BY-NC 4.0)

**Funding:** This research did not receive any financial support

**Competing Interests:** The authors have declared that no competing interests exist

**AIM:** To evaluate the short-term effectiveness of Gamma knife radiosurgery as a modality of treatment of brain arteriovenous malformation.

**METHODS:** Sixty-three patients with arteriovenous brain malformations underwent Gamma knife radiosurgery included in this prospective study between April 2017 and September 2018 with clinical and radiological with MRI follow up was done at three months and six months post-Gamma knife radiosurgery. By the end of the 12th-month post-Gamma knife radiosurgery, the patients were re-evaluated using digital subtraction angiography co-registered with M.R.I. During the 12 months follow up, CT scan or MRI was done at any time if any one of the patients' condition deteriorated or developed signs and symptoms of complications. The mean volume of the arteriovenous malformations treated was  $26.0 \pm 5 \text{ cm}^3$  (range 12.5–39.5  $\text{cm}^3$ ) in The Neurosciences Hospital, Baghdad/Iraq.

**RESULTS:** By the end of the 12th month of follow up, the overall obliteration of the arteriovenous malformations was seen in six patients only (9.5%), while shrinkage was noticed in 57 patients (90.5%). Improvement or clinical stability was found in 24 out of 39 patients (61.5%) presented with epilepsy as a chief complaint before Gamma knife radiosurgery and 21 out of 24 patients (87.0%) complained of a headache before Gamma knife radiosurgery. Post-Gamma knife radiosurgery bleeding was found in only three patients (5.0%).

**CONCLUSION:** Even with the short term follow up, Gamma knife radiosurgery has an excellent clinical outcome in most patients with arteriovenous brain malformations. The clinical symptoms like headache and seizure were either diminished or controlled with the same medical treatment dose before Gamma knife radiosurgery. Long term clinical and radiological follow up is recommended.

## Introduction

Brain arteriovenous malformation (AVM), is a complex of abnormal arteries and veins that directly communicate without an intervening capillary bed, with an incidence of 1.12 – 1.42 cases per 100,000 people each year [1], [2]. Haemorrhage is the most common presentation, occurring in 40 – 50% patients at initial diagnosis. The annual risk of haemorrhage ranges from 1.3 to 4%. The second most common presentation is a seizure, occurring in 20 – 30% of patients, followed by headache (5%–14%) and focal neurological deficits (around 5%) [3], [4]. AVM is the second most common cause of intracerebral haemorrhage in people < 35 years of age, following trauma. Treatment options for cerebral AVM include surgery, endovascular treatments, and radiosurgery. Among these, stereotactic radiosurgery (SRS)

showed great benefit in the treatment of small- to medium-sized AVMs, by minimising the risk of future intracranial haemorrhage with a reduction in treatment-related morbidity. The benefit in appropriately selected patients who undergo SRS reaches approximately 80 – 85% [4].

We aimed to evaluate the short-term effectiveness of Gamma knife radiosurgery (GKR) is a modality of treatment of brain AVM.

## Patients and Methods

This prospective clinical study which included sixty-three outpatients, referred for radio-surgical

treatment of an AVM using GKR in The Neurosciences Hospital, Baghdad/Iraq for the period between April 2017 and September 2018.

The inclusion criteria were any patient diagnosed (clinically and radiologically) to have an AVM. All the patients were older than 18, as shown in Table 1. All sizes of AVMs included.

The exclusion criteria were any previous AVM intervention, including vascular intervention, microsurgery, or previous GKR.

The average volume of the AVMs was 26.0 cm<sup>3</sup> (range, 12.5 – 39.5 cm<sup>3</sup>). The G.K.R. dose was 16-25 Gy (mean = 20 Gy) — the dose of the radiation delivered as a single dose in one session and the target was the nidus. The model of the GKR was Leksell Gamma Knife, Elekta, Perfexion model.

All procedures performed without general anaesthesia. Instead, intravenous sedative agents (i.e., midazolam, thiopental, and/or pentazocine) used before frame fixation and local anaesthesia (lidocaine 2%) applied at the sites of frame fixation. The procedure was performed with the patient either fully conscious or under sedation, as considered appropriate.

The study protocol approved by our institutional review board and conformed to the principles of the Declaration of Helsinki. All patients provided written informed consent for the use of their data.

### Follow-up

Clinical and radiological (MRI) follow up was done at three months and six months post-GKR. By the end of the 12<sup>th</sup>-month post-GKR, the patients were re-evaluated using digital subtraction angiography co-registered with MRI. During the 12 months follow up, CT scan or MRI was done at any time if any one of the patients' condition deteriorated or developed signs and symptoms of complications.

The policy of our institution is to re-evaluate the patients three years post-GKR using DSA and MRI then decide accordingly if the AVM is obliterated or further intervention is required.

### Statistical analysis

Descriptive analysis in the form of percentage was calculated using Excel and presented in the relevant tables shown below. Chi-Square test was used for statistical analysis by utilising the Statistical Package for Social Sciences (S.P.S.S.) version17 ( $p$ -value < 0.05 was considered significant).

## Results

The patients' characteristics included in this study were summarised in Table 1.

**Table 1: Characteristics of the patients included in the study**

Characteristics	Number of patients (%)
Male	39 (62%)
Female	24 (38%)
	Total 63 (100%)
Mean age (years)	47 (range 21-72)
Mean AVM volume (cm <sup>3</sup> )	26.0 ± 5 (range, 12.50-39.50)
Presentation:	
Haemorrhage	36 (57%)
Epilepsy	39 (61%)
Headache	24 (38%)
Other (Dizziness, vertigo, focal symptoms)	9 (14%)
Location	
-Hemispheric	18 (85%)
-frontal	3 (14%)
-parietal	10 (47%)
-temporal	2 (9.5%)
-occipital	2 (9.5%)
-cerebellar	1 (5%)
-Deep (brain stem, thalamus)	3 (15%)

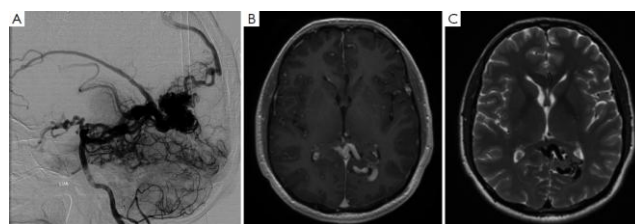
The results were concluded using the follow-up radiological studies (DSA, MRI, and CT Scans) and patients' objective presentation of symptoms.

**Table 2: AVM size post-GKR at 12 months follow-up**

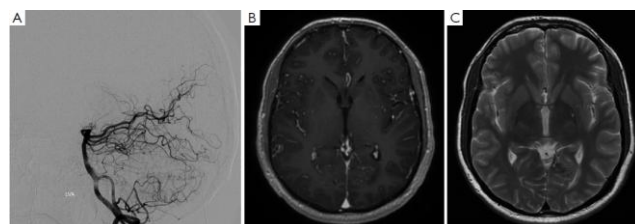
AVM size follow up radiologically	Total cases 63	%	P-value
Obliteration	6	9.5%	$P = 0.1$
Shrinkage	57	90.5%	$P = 0.01$
No change	0	0.0%	

By the end of the 12<sup>th</sup> month of follow up, the overall obliteration of the A.V.M. was seen in six patients only (9.5%,  $P = 0.1$ ), while shrinkage was noticed in 57 patients (90.5%,  $P = 0.01$ ) (the shrinkage ratio was 32.2-78.4%, mean = 68.8%) (Table 2, Figures).

Pre-GKR imaging



One-year follow-up post-GKR



**Figure 1: Pre-GKR imaging of left occipital AVM; A) DSA; B) MRI T1 weighted image with contrast; C) MRI T2 weighted image without contrast (top); One-year follow up post-GKR; A) DSA; B) MRI T1 weighted image with contrast; C) MRI T2 weighted imaging without contrast. Showing resolution of left occipital AVM (bottom)**

Improvement or clinical stability at 12 months, without changing the dose of anti-epileptic drugs, was found in 24 out of 39 patients presented with epilepsy (free of attacks 15.5%,  $P = 0.01$  with decreased amplitude time and frequency 46.0%,  $P = 0.02$ ) as a chief complaint before GKR (Table 3).

**Table 3: Seizure attacks post-GKR at 12 months follow-up**

Seizure attacks post-GKR	Total of 39 cases	%	P-value
Free of attacks	6	15.5%	$P = 0.01$
Decreased amplitude-time-frequency	18	46.0%	$P = 0.02$
No change	15	38.5%	

Improvement or clinical stability at 12 months, without changing the dose of anti-epileptic drugs in 21 out of 24 patients who complained of headache (free of headache 62.5%,  $P = 0.001$  with decreased frequency and severity 25.0%,  $P = 0.01$ ) before GKR (Table 4).

**Table 4: Headache attacks post-GKR at 12 months follow-up**

Headache attacks post-GKR	Total of 24 cases	%	P-value
Free of headache	15	62.5%	$P = 0.001$
Decreased frequency and severity	6	25.0%	$P = 0.01$
No change	3	12.5%	

Post-GKR bleeding found in only three patients (5.0%). These three cases had complained of a sudden deterioration in the level of consciousness and severe headache after six months of the GKR. They were admitted to the hospital and managed conservatively (Table 5).

**Table 5: Post-GKR haemorrhage**

Post-GKS haemorrhage	Total of 36 cases	P-value
In 3 months	0	
In 6 months	0	
In 12 months	3	$P = 0.1$
No haemorrhage	60	

The complications encountered during the 12 months post-GKR follow up were hemianesthesia in 7 cases (11.1%), hemiparesis in 5 cases (7.9%), diplopia in 4 cases (6.3%), hemianopsia in 2 cases (3.1%), and ataxia in 1 case (1.5%). CT scan or MRI applied for each case. The duration of the symptoms was 2-10 days (mean = seven days). All were transient and responded well to steroid (dexamethasone).

## Discussion

The most controversial issue on brain AVM treatment is the choice of interventional therapy modes. G.K.R. treatment could increase the safety of interventional surgeries for ruptured or unruptured brain AVMs, which are difficult to access by micro-neurosurgery, high Spetzler Martin (SM) grade, and eloquent in location [5].

The reported obliteration rate of the nidus in the brain AVMs after radiosurgery varies between 43 and 92%, [5], [6], [7], [8]. In our study, complete obliteration was achieved in six of the 63 patients (9.5%). This is explained by the short period of follow up (12 months).

Pollock et al., reported that serial MRI was predictive of total obliteration in 84% of patients in a period of two to four years [9]. Because of its low risk and high reliability, it is reasonable to use MRI to evaluate obliteration after radiosurgery[10].

Kano et al. found that factors associated with a higher rate of total obliteration on angiography included smaller target volume, smaller maximum diameter [8].

Friedman et al. reported that complete obliteration was obtained in 81% of AVMs between 1 ml and 4 ml in volume, in 89% of AVMs between 4 ml and 10 ml, and 69% of AVMs > 10 ml [11]. Murray et al. published increased volume was significantly associated with non-obliteration. Volume was a more critical factor than eloquent location, patient age, or gender [12]. Morphological features of the AVM and its density influence the success of AVM obliteration. Diffuse AVM structure is associated with a higher risk of radiosurgery failure [12], [13]. In our study, the size of the lesions was an essential factor as most AVMs were large (12.5-39.5 cm<sup>3</sup> with mean = 26 ± 5 cm<sup>3</sup>).

The risk of bleeding remains in 1.8-5% of patients per year until obliteration can be confirmed [9], [11], [14]. The exact mechanisms through which radiosurgery reduces the chance of bleeding not entirely elucidated. However, the histopathological studies of AVM after radiosurgery have suggested some theories: A) progressive thickening of the intimal layer, which begins as early as three months after radiosurgery, appears to decrease the stress to the vessel walls, and B) partial or complete thrombosis of the irradiated vessels may decrease the number of patent vessels in the malformation [5], [15].

Der-JenYen et al. reported that concerning seizure control, significant seizure reduction found following the first 6-months period after GKR. A 28–66.7% seizure reduction rate compared with that before G.K.R. was achieved and no initial worsening of seizures in any of the patients after GKS [16]. In our study, the post-GKR seizure rate was somehow similar to those results, whereas 15.5% were seizure-free, and about 46.0% were with fewer symptoms. Also, no worsening was reported.

In conclusion, even with the short term follow up, GKR has an excellent clinical outcome in most patients with brain AVM. The clinical symptoms like headache and seizure were either diminished or controlled with the same medical treatment dose before the GKR. Long term clinical and radiological follow up is recommended.

## References

1. Kurita H, Kawamoto S, Sasaki T, Shin M, Tago M, Terahara A, et al. Results of radiosurgery for brain stem arteriovenous malformations. *J Neurol Neurosurg Psychiatry*. 2000; 68(5):563-70. <https://doi.org/10.1136/jnnp.68.5.563> PMID:10766883 PMCID:PMC1736919
2. Maruyama K, Kondziolka D, Niranjan A, Flickinger JC, Lunsford LD. Stereotactic radiosurgery for brainstem arteriovenous malformations: factors affecting the outcome. *Journal of neurosurgery*. 2004; 100(3):407-13. <https://doi.org/10.3171/jns.2004.100.3.0407> PMID:15035275
3. Park HR, Lee JM, Kim JW, Han J-H, Chung H-T, Han MH, et al. Time-Staged Gamma Knife Stereotactic Radiosurgery for Large Cerebral Arteriovenous Malformations: A Preliminary Report. *PLoS One*. 2016; 11(11):e0165783-e. <https://doi.org/10.1371/journal.pone.0165783> PMID:27806123 PMCID:PMC5091869
4. Al-Shahi R, Bhattacharya JJ, Currie DG, Papanastassiou V, Ritchie V, Roberts RC, et al. Scottish Intracranial Vascular Malformation Study (S.I.V.M.S.): evaluation of methods, ICD-10 coding, and potential sources of bias in a prospective, population-based cohort. *Stroke*. 2003; 34(5):1156-62. <https://doi.org/10.1161/01.STR.0000069012.23858.69> PMID:12702840
5. Shaffrey ME. Neurosurgery, History and Technical Overview, Development of the Gamma Knife: The University Of Virginia, 2019. [cited 2019 1/2/2019]. Available from: <https://med.virginia.edu/neurosurgery/services/gamma-knife/for-physicians/history-and-technical-overview/>.
6. Moosa S, Chen CJ, Ding D, Lee CC, Chivukula S, Starke RM, et al. Volume-staged versus dose-staged radiosurgery outcomes for large intracranial arteriovenous malformations. *Neurosurgical focus*. 2014; 37(3): E18. <https://doi.org/10.3171/2014.5.FOCUS14205> PMID:25175437
7. Kiran NA, Kale SS, Kasliwal MK, Vaishya S, Gupta A, Singh Sharma M, et al. Gamma knife radiosurgery for arteriovenous malformations of basal ganglia, thalamus and brainstem--a retrospective study comparing the results with that for A.V.M.s at other intracranial locations. *Acta neurochirurgica*. 2009; 151(12):1575-82. <https://doi.org/10.1007/s00701-009-0335-0> PMID:19415175
8. Sasaki T, Kurita H, Saito I, Kawamoto S, Nemoto S, Terahara A, et al. Arteriovenous malformations in the basal ganglia and thalamus: management and results in 101 cases. *Journal of neurosurgery*. 1998; 88(2):285-92. <https://doi.org/10.3171/jns.1998.88.2.0285> PMID:9452237
9. Pollock BE, Flickinger JC, Lunsford LD, Bissonette DJ, Kondziolka D. Hemorrhage risk after stereotactic radiosurgery of cerebral arteriovenous malformations. *Neurosurgery*. 1996; 38(4):652-9; discussion 9-61. <https://doi.org/10.1227/00006123-199604000-00004> PMID:8692381
10. Bitaraf MA, Katozpour R, Azar M, Nouri M, Mortazavi SA, Amirjamshidi A. Radiosurgery in treatment of cerebral arteriovenous malformation: Mid-term results of 388 cases from a single center. *Asian J Neurosurg*. 2017; 12(2):159-66.
11. Friedman WA, Blatt DL, Bova FJ, Buatti JM, Mendenhall WM, Kubilis PS. The risk of hemorrhage after radiosurgery for arteriovenous malformations. *Journal of neurosurgery*. 1996; 84(6):912-9. <https://doi.org/10.3171/jns.1996.84.6.0912> PMID:8847584
12. Murray G, Brau RH. A 10-year experience of radiosurgical treatment for cerebral arteriovenous malformations: a perspective from a series with large malformations. *Clinical article. Journal of neurosurgery*. 2011; 115(2):337-46. <https://doi.org/10.3171/2011.3.JNS10814> PMID:21548746
13. Zipfel GJ, Bradshaw P, Bova FJ, Friedman WA. Do the morphological characteristics of arteriovenous malformations affect the results of radiosurgery? *Journal of neurosurgery*. 2004; 101(3):393-401. <https://doi.org/10.3171/jns.2004.101.3.0393> PMID:15352595
14. Geibprasert S, Pongpech S, Jiarakongmun P, Shroff MM, Armstrong DC, Krings T. Radiologic assessment of brain arteriovenous malformations: what clinicians need to know. *Radiographics: a review publication of the Radiological Society of North America, Inc*. 2010; 30(2):483-501. <https://doi.org/10.1148/rq.302095728> PMID:20228330
15. Nataf F, Ghossoub M, Schlienger M, Moussa R, Meder JF, Roux FX. Bleeding after radiosurgery for cerebral arteriovenous malformations. *Neurosurgery*. 2004; 55(2):298-305; discussion -6. <https://doi.org/10.1227/01.NEU.0000129473.52172.B5> PMID:15271235
16. Yen D-J, Chung W-Y, Shih Y-H, Chen C, Liang J-F, Yiu C-H, et al. Gamma knife radiosurgery for the treatment of recurrent seizures after incomplete anterior temporal lobectomy. *Seizure*. 2009; 18(7):511-4. <https://doi.org/10.1016/j.seizure.2009.05.005> PMID:19505832