

## Autologous Fat Graft: Not Only an Aesthetic Solution

Jacopo Scala<sup>1</sup>, Aleksandra Vojvodic<sup>2</sup>, Petar Vojvodic<sup>3</sup>, Tatjana Vlasovic-Jovicevic<sup>3</sup>, Zorica Peric-Hajzler<sup>4</sup>, Dusica Matovic<sup>4</sup>, Sanja Dimitrijevic<sup>5</sup>, Jovana Vojvodic<sup>3</sup>, Goran Sijan<sup>6</sup>, Nenad Stepic<sup>7</sup>, Uwe Wollina<sup>8</sup>, Michael Tirant<sup>1</sup>, Nguyen Van Thuong<sup>9</sup>, Massimo Fioranelli<sup>10</sup>, Torello Lotti<sup>11</sup>

<sup>1</sup>University G. Marconi, Rome, Italy; <sup>2</sup>Department of Dermatology and Venereology, Military Medical Academy, Belgrade, Serbia; <sup>3</sup>Clinic for Psychiatric Disorders "Dr. Laza Lazarevic", Belgrade, Serbia; <sup>4</sup>Military Medical Academy, Belgrade, Serbia; <sup>5</sup>Department of Gynecology, Military Medical Academy, Belgrade, Serbia; <sup>6</sup>Clinic for Plastic Surgery and Burns, Military Medical Academy, Belgrade, Serbia; <sup>7</sup>Chief of Clinic for Plastic Surgery and Burns, Military Medical Academy, Belgrade, Serbia; <sup>8</sup>Department of Dermatology and Allergology, Städtisches Klinikum Dresden, Dresden, Germany; <sup>9</sup>Vietnam National Hospital of Dermatology and Venereology, Hanoi, Vietnam; <sup>10</sup>Department of Nuclear Physics, Sub-nuclear and Radiation, G. Marconi University, Rome, Italy; <sup>11</sup>Department of Dermatology, University of G. Marconi, Rome, Italy

### Abstract

Subcutaneous adipose tissue was defined as the "perfect filler" as is soft and malleable and is usually enough present in the body for correcting volume defects and small remodelling purposes. The first attempts to implant autologous adipose tissue dates back to the end of the twentieth century, and with the refinement of harvesting, processing and replanting techniques today a uniform and predictable amount of survival rate were achieved. Those improvements have led to wider use of autologous fat grafts in many medical specialties not only in aesthetic or reconstructive treatments.

**Citation:** Scala J, Vojvodic A, Vojvodic P, Vlasovic-Jovicevic T, Peric-Hajzler Z, Matovic D, Dimitrijevic S, Vojvodic J, Sijan G, Stepic N, Wollina U, Tirant M, Thuong NV, Fioranelli M, Lotti T. Autologous Fat Graft: Not Only an Aesthetic Solution. Open Access Maced J Med Sci. 2019 Sep 30; 7(18):2961-2963. <https://doi.org/10.3889/oamjms.2019.781>

**Keywords:** Autologous; Fat; Fat graft; Aesthetic

**\*Correspondence:** Massimo Fioranelli. Department of Nuclear Physics, sub-nuclear and radiation, G. Marconi University, Rome, Italy. E-mail: [massimo.fioranelli@gmail.com](mailto:massimo.fioranelli@gmail.com)

**Received:** 12-Jun-2019; **Revised:** 16-Jul-2019;  
**Accepted:** 17-Jul-2019; **Online first:** 30-Aug-2019

**Copyright:** © 2019 Jacopo Scala, Aleksandra Vojvodic, Petar Vojvodic, Tatjana Vlasovic-Jovicevic, Zorica Peric-Hajzler, Dusica Matovic, Sanja Dimitrijevic, Jovana Vojvodic, Goran Sijan, Nenad Stepic, Uwe Wollina, Michael Tirant, Nguyen Van Thuong, Massimo Fioranelli, Torello Lotti. This is an open-access article distributed under the terms of the Creative Commons Attribution-NonCommercial 4.0 International License (CC BY-NC 4.0)

**Funding:** This research did not receive any financial support

**Competing Interests:** The authors have declared that no competing interests exist

### Introduction

Subcutaneous adipose tissue was defined as the "perfect filler" as is soft and malleable and is usually enough present in the body for correcting volume defects and small remodelling purposes. The first attempts to implant autologous adipose tissue dates back to the end of the twentieth century [1] and after those initial attempts was proposed by many authors to correct many defects with variable results but the real change in application of fat transplantation was possible after the publication of Coleman's studies [2], [3], [4]. Coleman modified and corrected the methods of his predecessors and proposed a protocol for the treatment of adipose tissue that

insured standardised results. According to Coleman's studies, the key to successful fat grafting lies in harvesting, refinement, and transfer technique to provide pure, intact parcels of fat, essential for successful grafting. Also, those refined fat parcels must be infiltrated into the recipient site in very small amounts to be integrated into the host tissues and to survive predictably and uniformly. Having achieved a good survival rate of transplanted fat, many Authors started to use it to treat many different conditions.

### *The biology of transplanted fat survival*

Coleman and other Authors focused on the main problem after adipose tissue auto-

transplantation, namely its absorption rate over time (reported reduction varies from 25 to 70% of the total implanted volume) [4], [5], [6]. The “Cellular survival theory” introduced by Peer argues that the final volume that can be obtained after an adipose tissue transplant depends on the number of vital adipocytes present at the time of transplantation [5], but further studies have shown that mature adipocytes are very fragile cells and have a low level of resistance to trauma and ischemia. In autologous fat graft there are other cellular populations more resistant to hypoxia and traumatic insults caused by the procedures for harvesting, processing and replanting: the preadipocytes or adipose-derived stromal cells (ASCs), this is because all immature progenitor cells have a minimal metabolic activity and thus are able to survive much longer without having all metabolic requirements fulfilled [7], [8].

Recent Authors identify three zones in fat grafting: a thin outer zone with the best chances of survival, an intermediate zone where regeneration takes place and a central zone doomed to necrosis. According to Eto et al., the biggest volume of a fat graft retained depends on the degree of survival in regenerating zone, which contains ASCs with the potential for differentiation and replacement of adipocytes lost in the necrotic zone [9], [10].

In addition to contributing to adipogenesis within transplanted adipose tissue, ASCs have an important role in graft revascularisation via paracrine effects that act in combination with another cellular population the Stromal Vascular Fraction (SVF). Both ASCs and SVF have a role in long-term survival of the transplanted fat tissue because exerting paracrine secretion of several factors such as VEGF, HGF and TGF- $\beta$ , which are released due to many stimuli, including hypoxia and inflammation, and those stimuli strongly affect the differentiation of stem cells and induce angiogenesis causing an overall remodelling of host tissue. Also, thanks to the angiogenic factors released from ASCs and SVF, lipofilling helps to interrupt the vicious circle of vascular lesion caused by ischaemia, hyperpermeability, and fibrosis leading to more ischaemia, helping the growth of a microvascular bed with the correct ratio of adipocytes to capillaries [10], [11], [12].

### **Recent applications of autologous fat grafts**

Many studies demonstrated the capacity, provided by their unique cytokine and growth factor profiles of ASCs to undergo multilineage differentiation, not just into fat but also into bone, cartilage, skeletal muscle, cardiac muscle, blood vessels, nerves and skin [13], [14]. For this reason recent studies have shown the utility of transplanted ASCs contained in lipoaspirate as an highly effective therapeutic approach to treat many different kinds of conditions including degenerative, chronic lesions,

late effects of oncologic radiation treatments, scleroderma and burns in addition to the well-known role in the treatment of lipodystrophy of face and body, recontouring and rejuvenation of the aging face and hands or treatment of depressed or altered scars [15], [16], [17], [18], [19], [20].

There are also many works supporting the efficacy of fat grafting in surgical applications like in temporomandibular joint surgery, for treatment and prevention of ankylosis, fibrosis or heterotopic ossification in total joint prosthesis; in neurosurgery to treat or prevent cerebrospinal fluid leaks in spine and skull base surgeries; in otolaryngology for obliteration of ear, frontal sinus cavities, vocal cord surgery and cleft lip and palate reconstruction and in breast oncology as a vehicle for antiestrogens [21], [23], [24].

Since from early Coleman’s observations, an improvement of pigmentation has also been recorded therefore in the latest proposals for the application of autologous fat grafting is used in vitiligo and grey hair in combination with other treatments. Initial attempts to use ASCs to treat alopecia with good results were also made [25], [26], [27].

In conclusion, fat is the closest to the ideal filler because it is readily available; easily obtainable, with low donor-site morbidity; repeatable; inexpensive; versatile, and biocompatible. Also, its use can help to treat a wide variety of condition aside from reconstructive and cosmetic procedures making it an invaluable tool in regenerative medicine and surgery.

## **References**

1. Billings JE, May JJ. Historical review and present status of free fat graft auto transplantation in plastic and reconstructive surgery. *Plast Reconstr Surg.* 1989; 83:368-381. <https://doi.org/10.1097/00006534-198902000-00033> PMID:2643129
2. Coleman SR. Structural fat grafts: the ideal filler? *Clin Plast Surg.* 2001; 28:111.
3. Coleman SR. Hand rejuvenation with structural fat grafting. *Plast Reconstr Surg.* 2002; 110:1731-45. <https://doi.org/10.1097/00006534-200212000-00017> PMID:12447057
4. Coleman SR. Long-term survival of fat transplants: controlled demonstrations. *Aesthet Plast Surg.* 1995; 19:421. <https://doi.org/10.1007/BF00453875>
5. Peer LA. Loss of weight and volume in human fat graft, with postulation of a cell survival theory. *Plast Reconstr Surg.* 1950; 5:217. <https://doi.org/10.1097/00006534-195003000-00002>
6. Tremolada C, Palmieri G, Ricordi C. Adipocyte transplantation and stem cells: plastic surgery meets regenerative medicine. *Cell transplant.* 2010; 19(10):1217-23. <https://doi.org/10.3727/096368910X507187> PMID:20444320
7. von Heimburg D, Hemmrich K, Haydarlioglu S, Staiger H, Pallua N. Comparison of viable cell yield from excised versus aspirated adipose tissue. *Cells Tissues Organs.* 2004; 178(2):87-92. <https://doi.org/10.1159/000081719> PMID:15604532

8. Wolter TP, von Heimburg D, Stoffels I, Groeger A, Pallua N. Cryopreservation of mature human adipocytes: in vitro measurement of viability. *Ann Plast Surg.* 2005; 55(4):408-13. <https://doi.org/10.1097/01.sap.0000181345.56084.7d> PMID:16186709
9. Eto H, Kato H, Suga H, Aoi N, Doi K, Kuno S, Yoshimura K. The fate of adipocytes after nonvascularized fat grafting: evidence of early death and replacement of adipocytes. *Plast Reconstr Surg.* 2012; 129(5):1081-92. <https://doi.org/10.1097/PRS.0b013e31824a2b19> PMID:22261562
10. Kato H, Mineda K, Eto H, Doi K, Kuno S, Kinoshita K, Kanayama K, Yoshimura K. Degeneration, regeneration, and cicatrization after fat grafting: dynamic total tissue remodeling during the first 3 months. *Plastic and reconstructive surgery.* 2014; 133(3):303e-13e.
11. J Salgado A, L Reis R, Sousa N, M Gimble J. Adipose tissue derived stem cells secretome: soluble factors and their roles in regenerative medicine. *Current stem cell research & therapy.* 2010; 5(2):103-10. <https://doi.org/10.2174/157488810791268564>
12. Cervelli V, Scioli MG, Gentile P, Doldo E, Bonanno E, Spagnoli LG, Orlandi A. Platelet-rich plasma greatly potentiates insulin-induced adipogenic differentiation of human adipose-derived stem cells through a serine/threonine kinase Akt-dependent mechanism and promotes clinical fat graft maintenance. *Stem cells translational medicine.* 2012; 1(3):206-20. <https://doi.org/10.5966/sctm.2011-0052> PMID:23197780 PMID:PMC3659852
13. Simonacci F, Bertozzi N, Raposio E. Off-label use of adipose-derived stem cells. *Annals of medicine and surgery.* 2017; 24:44-51. <https://doi.org/10.1016/j.amsu.2017.10.023> PMID:29123656 PMID:PMC5671395
14. Justesen J, Pedersen SB, Stenderup K, Kassem M. Subcutaneous adipocytes can differentiate into bone-forming cells in vitro and in vivo. *Tissue engineering.* 2004; 10(3-4):381-91. <https://doi.org/10.1089/107632704323061744> PMID:15165455
15. Wollina U, Goldman A, Abdel-Naser MB, Philipp-Dormston WG. Adipose tissue, fillers, and skin tightening. *Dermatol Ther.* 2019; 32(2). <https://doi.org/10.1111/dth.12626> PMID:30175548
16. Uyulmaz S, Sanchez Macedo N, Rezaeian F, Giovanoli P, Lindenblatt N. Nanofat Grafting for Scar Treatment and Skin Quality Improvement. *Aesthet Surg J.* 2018; 38(4):421-428. <https://doi.org/10.1093/asj/sjx183> PMID:29365061
17. Bellini E, Grieco MP, Raposio E. The science behind autologous fat grafting. *Ann Med Surg.* 2017; 24:65-73. <https://doi.org/10.1016/j.amsu.2017.11.001> PMID:29188051 PMID:PMC5694962
18. Virzi F, et al. Combined platelet-rich plasma and lipofilling treatment provides great improvement in facial skin-induced lesion regeneration for scleroderma patients. *Stem Cell Res Ther.* 2017; 8(1):236. <https://doi.org/10.1186/s13287-017-0690-3> PMID:29058626 PMID:PMC5651639
19. Gheisari M, Ahmadzadeh A, Nobari N, Iranmanesh B, Mozafari N. Autologous Fat Grafting in the Treatment of Facial Scleroderma. *Dermatol Res Pract.* 2018; 2018:6568016. <https://doi.org/10.1155/2018/6568016> PMID:30154838 PMID:PMC6093005
20. Lee G, Hunter-Smith DJ, Rozen WM. Autologous fat grafting in keloids and hypertrophic scars: a review. *Scars Burn Heal.* 2017; 3:2059513117700157. <https://doi.org/10.1177/2059513117700157> PMID:29799555 PMID:PMC5965318
21. Mojallal A, Veber M, Shipkov C, Ghetu N, Foyatier JL, Braye F. Analysis of a series of autologous fat tissue transfer for lower limb atrophies. *Annals of plastic surgery.* 2008; 61(5):537-43. <https://doi.org/10.1097/SAP.0b013e318164088f> PMID:18948782
22. Zimmermann S, Fakin RM, Giesen T, Giovanoli P, Calcagni M. Stromal vascular fraction-enriched fat grafting for the treatment of symptomatic end-neuromata. *JoVE (Journal of Visualized Experiments).* 2017; (129):e55962. <https://doi.org/10.3791/55962> PMID:29286436
23. Segreto F, Marangi GF, Persichetti P. Autologous Fat Grafting as a Novel Antiestrogen Vehicle for the Treatment of Breast Cancer. *Plast Reconstr Surg.* 2018; 141(6):965e-966e. <https://doi.org/10.1097/PRS.0000000000004387> PMID:29608518
24. Baum SH, Mohr C. Autologous dermis-fat grafts in head and neck patients: Indications and evaluation in reconstructive surgery. *J Craniomaxillofac Surg.* 2018; 46(10):1834-1842. <https://doi.org/10.1016/j.jcms.2018.07.009> PMID:30097407
25. Lotti TM, Hercogová J, Schwartz RA, Tsampau D, Korobko I, Pietrzak A, Mitrevska NT, Valle Y, Buggiani G. Treatments of vitiligo: what's new at the horizon. *Dermatologic Ther.* 2012; 25(1):S32-40. <https://doi.org/10.1111/dth.12011> PMID:23237036
26. Goren A, Bolanča Ž, Lotti T, Šitum M. Novel technique for repigmentation of senescence grey hair. *Dermatol Ther.* 2017; 30(2). <https://doi.org/10.1111/dth.12436> PMID:27917579
27. Gentile P, Garcovich S. Advances in Regenerative Stem Cell Therapy in Androgenic Alopecia and Hair Loss: Wnt pathway, Growth-Factor, and Mesenchymal Stem Cell Signaling Impact Analysis on Cell Growth and Hair Follicle Development. *Cells.* 2019; 8(5). <https://doi.org/10.3390/cells8050466> PMID:31100937 PMID:PMC6562814

# Eosinophilic Fasciitis – Report of Three Cases and Review of the Literature

Uwe Wollina<sup>1\*</sup>, Gesina Hansel<sup>1</sup>, Jacqueline Schönlebe<sup>2</sup>, Birgit Heinig<sup>3</sup>, Ivanka Temelkova<sup>4</sup>, Georgi Tchernev<sup>4</sup>, Aleksandra Vojvodic<sup>5</sup>, Torello Lotti<sup>6</sup>

<sup>1</sup>*Städtisches Klinikum Dresden, Department of Dermatology and Allergology, Dresden, Germany;* <sup>2</sup>*Institute of Pathology "Georg Schmorl", Städtisches Klinikum Dresden, Academic Teaching Hospital, Dresden, Germany;* <sup>3</sup>*Center of Physical and Rehabilitative Medicine, Städtisches Klinikum Dresden, Academic Teaching Hospital, Dresden, Germany;* <sup>4</sup>*Onkoderma - Clinic for Dermatology, Venereology and Dermatologic Surgery, General Skobelev 26, 1606, Sofia, Bulgaria;* <sup>5</sup>*Department of Dermatology and Venereology, Military Medical Academy of Belgrade, Belgrade, Serbia;* <sup>6</sup>*University of Rome Guglielmo Marconi Rome, Italy*

## Abstract

**Citation:** Wollina U, Hansel G, Schönlebe J, Heinig B, Temelkova I, Tchernev G, Vojvodic A, Lotti T. Eosinophilic Fasciitis – Report of Three Cases and Review of The Literature. Open Access Maced J Med Sci. 2019 Sep 30; 7(18):2964-2968.  
<https://doi.org/10.3889/oamjms.2019.296>

**Keywords:** Eosinophilic fasciitis; Fibrotic disorders; Scleroderma; Treatment; Corticosteroids; Methotrexate

**\*Correspondence:** Uwe Wollina. Städtisches Klinikum Dresden, Department of Dermatology and Allergology, Dresden, Germany. E-mail: uwollina@gmail.com

**Received:** 05-Apr-2019; **Revised:** 03-May-2019; **Accepted:** 04-May-2019; **Online first:** 15-May-2019

**Copyright:** © 2019 Uwe Wollina, Gesina Hansel, Jacqueline Schönlebe, Birgit Heinig, Ivanka Temelkova, Georgi Tchernev, Aleksandra Vojvodic, Torello Lotti. This is an open-access article distributed under the terms of the Creative Commons Attribution-NonCommercial 4.0 International License (CC BY-NC 4.0)

**Funding:** This research did not receive any financial support

**Competing Interests:** The authors have declared that no competing interests exist

**BACKGROUND:** Eosinophilic fasciitis is a rare fibrosing disorder of muscle fascia with rapid onset of erythema, induration, oedema and tenderness affecting extremities bilaterally.

**CASE REPORT:** We report three cases of eosinophilic fasciitis in 3 females aged 64, 65 and 73 years, in two of them in association with morphea. They fulfilled the proposed diagnostic criteria. Associated malignancies could be excluded in all of them. They were treated by systemic corticosteroids. In the two females with associated morphea higher prednisolone dosages and a combination with methotrexate was necessary.

**CONCLUSIONS:** Eosinophilic fasciitis is a differential diagnosis of systemic scleroderma. Response to treatment is often delayed. Systemic corticosteroids are the first line therapy. Patients with associated morphea need combined drug therapy, in our patients with methotrexate. There is no close correlation between laboratory signs of inflammation and clinical response to treatment.

## Introduction

Eosinophilic dermatosis was described first by Shulman in 1975 as diffuse fasciitis with hypergammaglobulinemia and eosinophilia [1], [2]. The disease is now also known as Shulman syndrome. It is characterised by abrupt onset with bilateral oedema on the limbs, peau d'orange appearance of the skin, linear depression along the veins (groove sign), and tenderness.

The induration is progressive and may lead to

joint contractures in about 50% of patients [3]. In Caucasians, women are affected twice as often as men, in Japan, the male to female ratio is 1.5:1 [4]. In about 25% of cases, only the lower legs are involved, but most often all four limbs become affected. Raynaud's phenomenon is typically absent [5]. Although cases with trunk involvement have been reported, the face is always spared [4].

The disease is rare with only 63 patients in the largest series reported so far [5].

## Case reports

**Case 1:** A 65-year-old woman developed plaque-like, erythematous induration on all four extremities with tenderness since March 2017. She reported a feeling of tension on the ankles with limited mobility, muscular pain and weakness, and fatigue. She had already unintended lost 7 kg of her body weight within 3 months.

Her medical history was positive for diabetes mellitus type II (no medications), arterial hypertension, hyperlipoproteinemia, and hyperuricemia. She was a smoker with 10 cigarettes per day.

On examination, we observed symmetric brownish hyperpigmentation on lower legs and lower arms, and the lower trunk. The skin appeared thickened, and it was impossible to crease the skin. The groove sign was positive on the legs (Figure 1). She had no Raynaud's phenomenon.

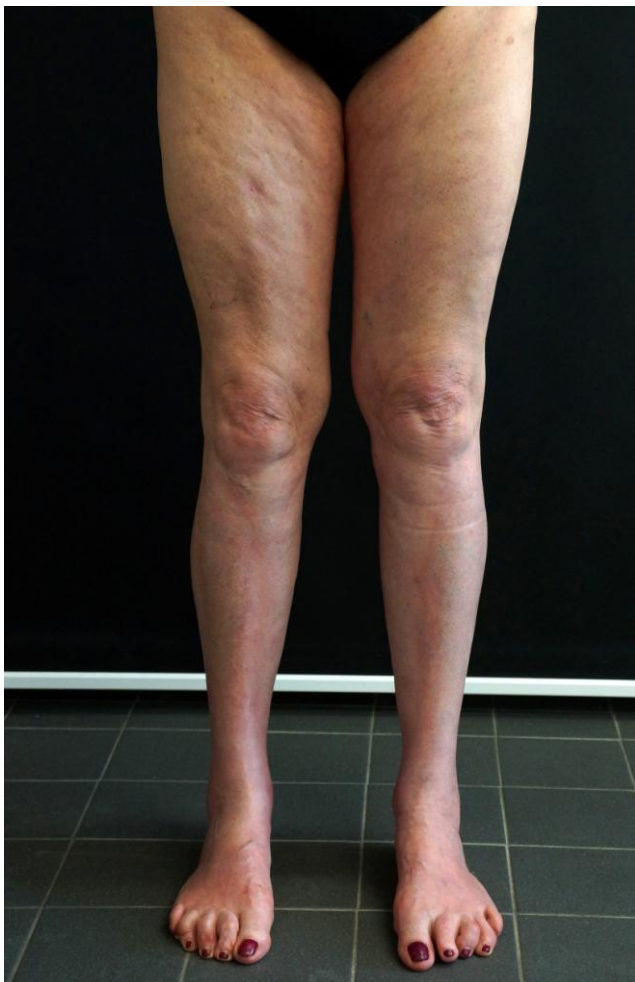

Figure 1: Eosinophilic fasciitis in a 65-year-old woman. Positive groove sign on her leg

We took a skin biopsy from the lower arm that showed epidermal atrophy and band-like melanin pigmentation of the basal layer. Along the border of cutis and subcutis, inflammatory infiltrates composed

of lymphocytes and monocytes were visible.

A bone marrow biopsy demonstrated increased production of eosinophils.

Molecular cytogenetic diagnostics excluded an eosinophilic myeloproliferative malignancy.

Laboratory findings: Leukocytosis of 14.3 Gpt/L, erythrocytes 3.6 Tpt/L, eosinophilia of 8%, C-reactive Protein 67.1 mg/L.

Imaging: Computerized tomography (CT) scan of the trunk remained unremarkable. Esophago-duodenoscopy: Helicobacter-associated (HP) pangastritis. Colonoscopy: Benign colon polyps (Biopsy).

Treatment and course: Initially we suspected a malignancy. The pangastritis was eradicated by triple therapy of HP gastritis. The clinical findings with peripheral eosinophilia confirmed the diagnosis of eosinophilic fasciitis. The patients treated initially with 60 mg prednisolone/d with slow tapering down the doses. We started pantoprazole and cholecalciferol therapy to protect the stomach and prevent osteoporosis. She responded well.

**Case 2:** A 64-year-old woman noted a progressive and painful thickening of the soft tissue on her lower arms and legs. She suffered from diffuse pain of muscles and bones. Her medical history was remarkable for allergic asthma. She was treated with mepolizumab for one year. The treatment was withdrawn in March 2018 because of the suspicion of drug-related toxicity. She underwent a corrective nasal surgery because of nasal stenosis in May 2018. She suffered from pollen allergy, glaucoma and liver hemangiomas.

On examination, we observed erythematous lesions with livedo reticularis. The subcutaneous soft tissue was fibrotic and thickened. On her lower arms, plate-like indurations were noted. The affected limbs were painful. Peau d'orange appearance of upper legs was obvious (Figure 2). Hands and feet remained unaffected. There was no Raynaud's phenomenon.

We took a skin biopsy that revealed a superficial and deep perivascular and interstitial dermatitis with the involvement of eosinophils. The subcutaneous adipose tissue presented septal panniculitis.

Laboratory findings: C-reactive protein 24 mg/L, eosinophilia of 32%, lymphocytes 13%,  $\beta$ 2-microglobulin 4.6 mg/L, interleukin-2-receptor 2,380 U/mL. Serology for infections remained negative. Antinuclear antibodies 1:160.

Bone-marrow biopsy: Eosinophilia (31.8%), lymphocytes 14%. Molecular cytogenetics and FISH – no malignancy, no aberrant cell clone in the bone marrow.

Imaging: X-Ray Thorax: Diffuse fibrotic pulmonary changes, mild emphysema. Body plethysmography: Minor alterations of diffusion. MRI

abdomen: Steatosis hepatitis, liver hemangioma. MRI right lower arm: Hyperintense fascial signals. Mammography: Involution. No malignancy.

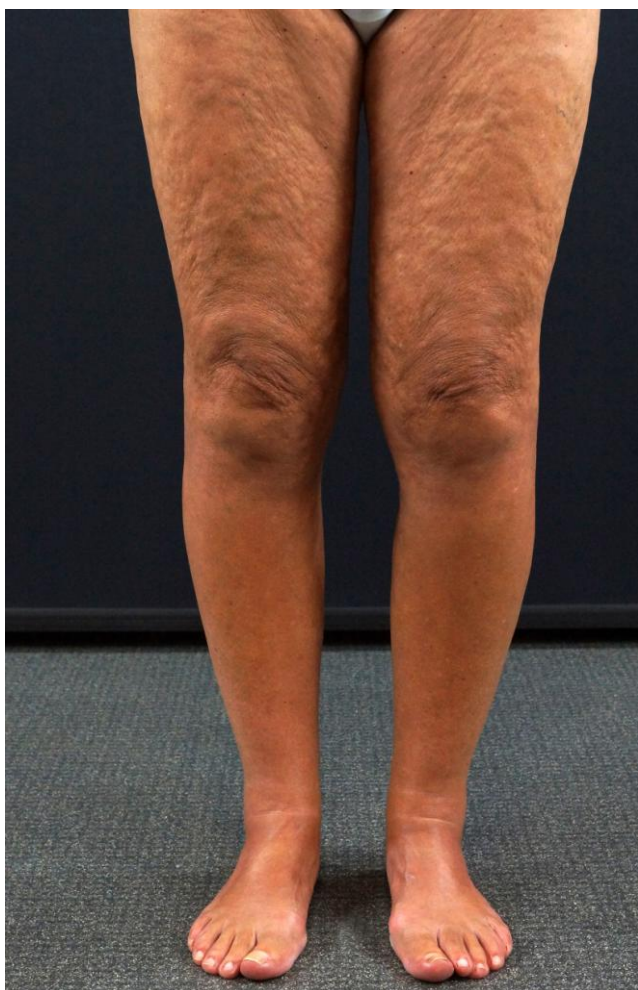

Figure 2: Eosinophilic fasciitis in a 64-year-old woman. Peau d'orange sign

Treatment and course: After confirmation of the diagnosis of eosinophilic fasciitis by clinical finding, MRI and eosinophilia, we started initially with 100 mg prednisolone/d and 20 mg pantoprazole/d. Ten days later, the prednisolone dosage could be reduced to 75 mg/d and methotrexate 15 mg per week plus 5 mg folate on the following day. Pain management was realised using metamizole and hydromorphone. Physical therapy with mobilisation and manual lymph drainage was initiated. Within 10 days, the inflammatory parameters normalised. A very slow dose of tapering was recommended for outpatient treatment.

In October 2018, the patient returned to the hospital with a worsening of her complaints. At that time, she received prednisolone 5 mg/d and methotrexate 10 mg/week. We repeated tumour screening including colonoscopy, esophagogastroscope and CT scans from the head and the trunks that remained inconspicuous. MRI of the right lower arm demonstrated the improvement of her fasciitis. We

performed a high-dose pulse therapy with 1000 mg prednisolone intravenous infusion on 4 consecutive days and increased the methotrexate dosage to 15 mg/week. On the following days, the dosage of prednisolone was 100 mg/d and later 75 mg/d. In January 2019 we repeated the high-dose pulse therapy on 3 consecutive days. We noted an improvement of the thickness of the tissue and tenderness on the extremities. On the trunk, however, she developed symptomless plaque-type morphea.

**Case 3:** A 73-year-old woman developed in April 2018 multiple circumscribed plaques on her trunk diagnosed as morphea. She was treated by a combination of 10 mio U penicillin i.v. And psoralen plus UVA therapy (PUVA) resulting in complete remission. During the following months, she noted relapsing oedema on the extremities with subsequent thickening, fibrosis and tenderness on lower arms and lower legs. Her medical history was positive for hypothyroidism and cataract.

On examination, we observed symmetrical plaque-like subcutaneous indurations on lower arms and lower legs. There was a peau d'orange appearance of her upper legs (Figure 3). Hands and feet remained unaffected. She had no Raynaud's phenomenon.

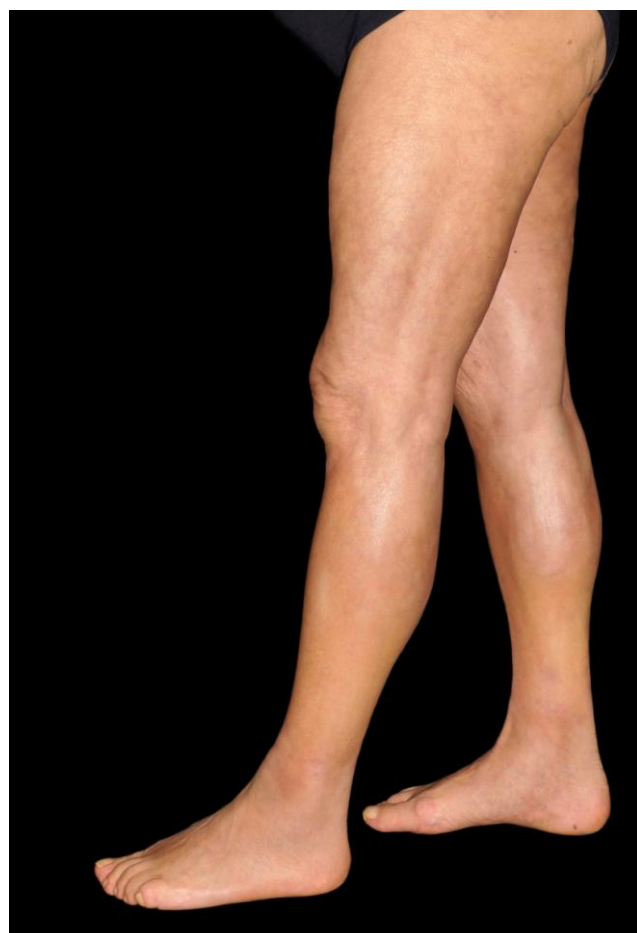

Figure 3: Eosinophilic fasciitis in a 73-year-old woman. Peau d'orange sign

A skin biopsy revealed some inflammatory infiltrate in the reticular dermis. In the deep dermis, it was perivascular, periadnexal and interstitial composed of mononuclear cells and some eosinophils. In the subcutaneous adipose tissue septal tissue became enlarged and presented with interstitial cellular infiltrates. Some foreign-body granulomas were described. Elastic fibres were preserved.

Laboratory findings: Eosinophilia 7.1% and lymphopenia 10%. Gamma-globulins were increased (21.6%), lactate dehydrogenase (4.24  $\mu$ kat/L) and C-reactive protein (7.28 mg/L) were slightly increased.

Imaging: An MRI of the right lower arm demonstrated fibrosis of the proximal ulnar part and generalised enhanced signalling of the fascia.

Treatment and course: After confirmation of eosinophilic fasciitis we performed a high-dose prednisolone pulse therapy with 1000 mg/ on 4 consecutive days with protective pantoprazole medication. Afterwards, we switched to oral treatment with 100 mg prednisolone/d and 15 mg methotrexate/week plus 5 mg folate on the other day after methotrexate.

Pain management was realised with ibuprofen. She was also treated with physical therapy (manual lymph drainage and mobilisation). A control MRI disclosed improvement of the fasciitis and nearly completes remission of the fibrosis. Tissue hardening could be reduced, and pain relief was achieved (Figure 4). The prednisolone dosage could further be tapered down.

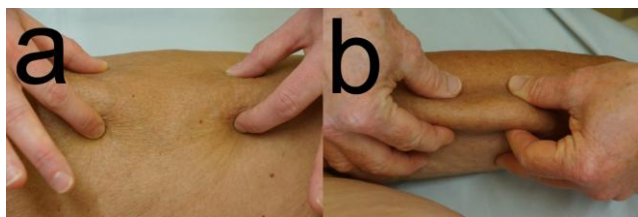


Figure 4: Patient #3 Improvement of soft tissue tenderness (thigh). (a) Before treatment. (b) After high-dose prednisolone pulse therapy

## Discussion

Eosinophilic fasciitis is a rare disease of the fibrous spectrum but distinct from systemic scleroderma. Diagnostic criteria have been proposed by different groups of investigators (Table 1 and 2) [6], [7]. Patients with eosinophilic fasciitis are often initially misdiagnosed leading to delayed treatment. We performed skin biopsies to exclude other dermatoses.

Table 1: Diagnostic criteria for eosinophilic fasciitis [6]

Major criteria	(a) symmetric or asymmetric diffuse or localised swelling, induration and thickening of the skin and subcutaneous tissue (b) Histology showing fascial thickening with an accumulation of lymphocytes and macrophages with or without eosinophils
Minor criteria	(a) Peripheral eosinophilia ( $> 0.5 \times 10^9/L$ ) (b) Hypergammaglobulinemia ( $> 1.5 g/L$ ) (c) Muscular weakness and/or elevated serum aldolase (d) Groove sign and/or peau d'orange appearance of skin (e) T2-weighted MRI showing hyperintense fascia
Exclusion criterion	Diagnosis of systemic scleroderma

The pathogenesis of eosinophilic fasciitis is not completely understood. Autoimmune mechanisms have been suggested, but strenuous exercise or labour may trigger the onset. Dermal fibroblasts are hyperactive overexpressing type I collagen and fibronectin [8].

Table 2: Japanese diagnostic criteria of eosinophilic fasciitis [7]

Major criterion:	Symmetrical plate-like sclerotic lesions are present on the four limbs. However, this condition lacks Raynaud's phenomenon, and systemic sclerosis can be excluded.
Minor criteria 1:	The histology of a skin biopsy that incorporates the fascia shows fibrosis of the subcutaneous connective tissue, with thickening of the fascia and cellular infiltration of eosinophils and monocytes.
Minor criteria 2:	Thickening of the fascia is seen using imaging tests such as magnetic resonance imaging (MRI).
A definitive diagnosis is made when a patient has the major criterion and one of the minor criteria, or the major criterion and two of the minor criteria.	

Levels of tissue inhibitor of metalloproteinase-1 (TIMP-1), an inhibitor of the extracellular matrix-degrading enzyme matrix metalloproteinase-1, are also increased, supporting tissue fibrosis [9]. There are reports on altered levels of certain interleukins, interferon-gamma, transforming growth factor- $\beta$ 1 mRNA, and TH17+ cells [4], [5].

Diagnosis is confirmed by fascial biopsy and histopathology demonstrating fascial thickening, fibrosis, and lymphocytic infiltrate [6], [7]. Involvement of muscles and adipose tissue may also be present. Another diagnostic tool is the MRI that shows hyperintense fascia on T2-weighted images [10] (Table 3).

Table 3: Findings of our patients with eosinophilic fasciitis

Criteria	Patient 1	Patient 2	Patient 3
Major criteria			
(a) Clinical findings	+	+	+
(b) Fascial histology	not done	not done	not done
Minor criteria			
(a) Eosinophilia	+	+	+
(b) Hypergammaglobulinemia	-	-	+
(c) Muscular weakness	+	+	+
(d) Groove sign and / or peau d'orange	+	(+)	(+)
(e) MRI hyperintense fascia	+	+	+

Treatment is not standardised. It is known that concurrent morphea is associated with a 1.4 to 3 times higher risk of resistance to systemic corticosteroid therapy [8], [11]. Our experience with two patients with associated morphea supports this finding. Both did not respond to oral corticosteroids

and needed a combined medication with methotrexate and intravenous high-dose pulse steroids. Medical treatment was supported by pain management and physical therapy. The latter is of importance to prevent joint contractures [5]. Since eosinophilic fasciitis may be a facultative paraneoplastic disorder, exclusion of underlying malignancies is of importance [3], [4], [5]. We performed imaging investigations and bone-marrow biopsies. In all three of our patients, a malignant background could be excluded.

The course of the disease often needs many months to several years of treatment. The keystones of drug therapy are systemic corticosteroids and methotrexate. Other drugs that have been occasionally used are mycophenolate mofetil, cyclosporin A, dapson, azathioprine, tumour necrosis factor-inhibitors, sirolimus, immunoglobulins, and D-penicillamine. Photo(chemo)therapy with either UVA1, PUVA or extracorporeal photochemotherapy has also been reported [12]. There are some case reports about the successful but off-label use of interleukin-6 antagonist tocilizumab [13], anti-CD-antibody rituximab [14], and Janus kinase inhibitor tofacitinib [15]. In some of the cases, these new drugs have been used in combination with either methotrexate or prednisolone. We achieved improvement with systemic corticosteroids with or without methotrexate.

In conclusion, eosinophilic fasciitis is rare but probably underdiagnosed. The disease should not be mistaken for systemic scleroderma since treatment and prognosis are different. Careful clinical investigation, histopathology, eosinophilia in peripheral blood, and MRI allow the confirmation of diagnosis. Keystones of treatment are systemic corticosteroids and methotrexate, although other compounds have also been used occasionally. Physical therapy is essential to prevent joint contractures that develop in half of the patients.

## References

1. Shulman LE. Diffuse fasciitis with hypergammaglobulinemia and eosinophilia: a new syndrome? *J Rheumatol.* 1974; 1(1):46.
2. Shulman LE. Diffuse fasciitis with eosinophilia: a new syndrome? *Trans Assoc Am Physicians.* 1975; 88:70-86.
3. Wright NA, Mazori DR, Patel M, Merola JF, Femia AN, Vleugels RA. Epidemiology and Treatment of Eosinophilic Fasciitis: An Analysis of 63 Patients From 3 Tertiary Care Centers. *JAMA Dermatol.* 2016; 152(1):97-9. <https://doi.org/10.1001/jamadermatol.2015.3648> PMID:26559760
4. Ihn H. Eosinophilic fasciitis: From pathophysiology to treatment. *Allergol Int.* 2019; S1323-8930(19)30021-8. <https://doi.org/10.1016/j.alit.2019.03.001> PMID:30910631
5. Mazori DR, Femia AN, Vleugels RA. Eosinophilic Fasciitis: an Updated Review on Diagnosis and Treatment. *Curr Rheumatol Rep.* 2017; 19(12):74. <https://doi.org/10.1007/s11926-017-0700-6> PMID:29101481
6. Pinal-Fernandez I, Selva-O' Callaghan A, Grau JM. Diagnosis and classification of eosinophilic fasciitis. *Autoimmun Rev.* 2014; 13(4-5):379-82. <https://doi.org/10.1016/j.autrev.2014.01.019> PMID:24424187
7. Jinnin M, Yamamoto T, Asano Y, Ishikawa O, Sato S, Takehara K, Hasegawa M, Fujimoto M, Ihn H. Diagnostic criteria, severity classification and guidelines of eosinophilic fasciitis. *J Dermatol.* 2018; 45(8):881-90. <https://doi.org/10.1111/1346-8138.14160> PMID:29235676
8. Jinnin M, Ihn H, Yamane K, Asano Y, Yazawa N, Tamaki K. Serum levels of tissue inhibitor of metalloproteinase-1 and 2 in patients with eosinophilic fasciitis. *Br J Dermatol.* 2004; 151(2):407-12. <https://doi.org/10.1111/j.1365-2133.2004.06062.x> PMID:15327548
9. Lebeaux D, Francès C, Barete S, Wechsler B, Dubourg O, Renoux J, Maisonobe T, Benveniste O, Gatifossé M, Bourgeois P, Amoura Z, Cacoub P, Piette JC, Sène D. Eosinophilic fasciitis (Shulman disease): new insights into the therapeutic management from a series of 34 patients. *Rheumatology (Oxford).* 2012; 51(3):557-61. <https://doi.org/10.1093/rheumatology/ker366> PMID:22120602
10. Kirchgessner T, Dallaudière B, Omoumi P, Malghem J, Vande Berg B, Lecouvet F, Houssiau F, Galant C, Larbi A. Eosinophilic fasciitis: typical abnormalities, variants and differential diagnosis of fasciae abnormalities using MR imaging. *Diagn Interv Imaging.* 2015; 96(4):341-8. <https://doi.org/10.1016/j.diii.2014.06.018> PMID:25746223
11. Endo Y, Tamura A, Matsushima Y, Iwasaki T, Hasegawa M, Nagai Y, Ishikawa O. Eosinophilic fasciitis: report of two cases and a systematic review of the literature dealing with clinical variables that predict the outcome. *Clin Rheumatol.* 2007; 26(9):1445-51. <https://doi.org/10.1007/s10067-006-0525-6> PMID:17345001
12. Tull R, Hoover WD 3rd, De Luca JF, Huang WW, Jorizzo JL. Eosinophilic fasciitis: a case series with an emphasis on therapy and induction of remission. *Drugs Context.* 2018; 7:212529. <https://doi.org/10.7573/dic.212529> PMID:30302114 PMID:PMC6172017
13. Espinoza F, Jorgensen C, Pers YM. Efficacy of Tocilizumab in the treatment of Eosinophilic fasciitis: Report of one case. *Joint Bone Spine.* 2015; 82(6):460-1. <https://doi.org/10.1016/j.jbspin.2015.02.008> PMID:26162635
14. Nahhas AF, Alam M, Lim HW. Rituximab as a therapeutic consideration for refractory eosinophilic fasciitis. *Int J Dermatol.* 2018; 57(5):614-615. <https://doi.org/10.1111/ijd.13940> PMID:29446454
15. Kim SR, Charos A, Damsky W, Heald P, Girardi M, King BA. Treatment of generalized deep morphea and eosinophilic fasciitis with the Janus kinase inhibitor tofacitinib. *JAAD Case Rep.* 2018; 4(5):443-445. <https://doi.org/10.1016/j.jidcr.2017.12.003> PMID:29984277 PMID:PMC6031588



# Immunocompromised Districts of Skin: A Case Series and a Literature Review

Aleksandra Vojvodic<sup>1</sup>, Michael Tirant<sup>2,3</sup>, Veronica di Nardo<sup>2</sup>, Torello Lotti<sup>2</sup>, Uwe Wollina<sup>4\*</sup>

<sup>1</sup>Department of Dermatology and Venereology, Military Medical Academy of Belgrade, Belgrade, Serbia; <sup>2</sup>Department of Dermatology, University of Rome "G. Marconi", Rome, Italy; <sup>3</sup>Hanoi Medical University, Hanoi, Vietnam; <sup>4</sup>Department of Dermatology and Allergology, Städtisches Klinikum Dresden, Academic Teaching Hospital, Dresden, Germany

## Abstract

**Citation:** Vojvodic A, Tirant M, di Nardo V, Lotti T, Wollina U. Immunocompromised Districts of Skin: A Case Series and a Literature Review. Open Access Maced J Med Sci. 2019 Sep 30; 7(18):2969-2975. <https://doi.org/10.3889/oamjms.2019.680>

**Keywords:** Immunocompromised districts of the skin; Macromorphology of skin diseases; Koebner phenomenon; Wolf's isotopic response

**\*Correspondence:** Uwe Wollina, Department of Dermatology and Allergology, Städtisches Klinikum Dresden, Academic Teaching Hospital, 01067 Dresden, Germany. E-mail: [uwollina@gmail.com](mailto:uwollina@gmail.com)

**Received:** 08-Aug-2019; **Revised:** 07-Sep-2019; **Accepted:** 08-Sep-2019; **Online first:** 10-Sep-2019

**Copyright:** © 2019 Aleksandra Vojvodic, Michael Tirant, Veronica di Nardo, Torello Lotti, Uwe Wollina. This is an open-access article distributed under the terms of the Creative Commons Attribution-NonCommercial 4.0 International License (CC BY-NC 4.0)

**Funding:** This research did not receive any financial support

**Competing Interests:** The authors have declared that no competing interests exist

**BACKGROUND:** The concept of immunocompromised districts of skin has been developed by Ruocco and helps to explain certain aspects of the macromorphology of skin diseases. This concept unites the isomorphic response of Koebner and the isotopic response of Wolf.

**CASE REPORTS:** We present different cutaneous conditions which can lead to immunocompromised districts of skin such as scars, radiodermatitis, lymphedema, disturbed innervation or mechanical friction etc. Typical and rarer skin disorders associated with them are discussed and illustrated by their observations.

**CONCLUSION:** At this moment, we wish to inform dermatologists and non-dermatologists about Ruocco's concept and its implications.

## Introduction

The skin is one of our main protective tissues to support body homeostasis. Protection is generated by the dynamic structure of the outmost part of skin, the stratum corneum, and supported by specific cells such as melanocytes (UV-protection), Langerhans cells (antigen control), Mast cells and macrophages (innate immunity), lymphocytes (including  $\gamma\delta$  T cells, innate lymphoid cells - specific immunity), and Merkel cells (neuroimmunology). Keratinocytes, sweat glands and sebaceous glands are part of the innate immune system [1], [2], [3].

Skin failure is one of the most important causes of mortality in the intensive care units [4], [5]. It has been defined as loss of temperature control with the inability to maintain the core body temperature, and failure to prevent percutaneous loss of fluid,

electrolytes and protein, and failure of the skin barrier function [6].

However, impairment of skin function is quite often seen in a sectorial area. Different pathways may lead to sectorial skin function impairment such as trauma, infection, or vascular dysfunction. The sectorial impairment of immune and other functions of skin has been described by the term Ruocco's immunocompromised districts (ICD's) [7]. It unites different phenomena such as isomorphic (Koebner) and isotopic (Wolf) responses of skin and helps to understand macromorphology of dermatoses. Although the concept had been developed during the last decade, it has yet to gain widespread knowledge [8], [9].

In this review article, we will provide a collection of clinical examples supporting the concept ICD from our departments.

## Skin grafts as ICD's

Autologous split skin grafts are a mainstay for defect closure after trauma and tumour surgery. Split skin is not a primary vascularized graft. Grafts survive initially by the oxygen supply from the wound bed. Skin grafts have to establish their blood vascularisation. Grafts are not passive but can secrete soluble mediators involved in wound healing [10]. During the first 48 h after transplantation, the graft is bulged by plasmatic fluid. Neo-angiogenesis leads to improved supply of oxygen and nutrients. Pre-vascularization of grafts further enhances therapeutic effects [11].

Graft-associated wound healing may show some peculiarities compare to "normal" wound healing. For instance, there is no involvement of sweat gland progenitors in grafts [12]. Skin grafts are not primarily vascularized. Both T and B lymphocytes, natural killer cells, and last not least antigen-presenting cells will infiltrate the graft only after successful neovascularisation. This results in changes of local immunity, as demonstrated by case reports on localised bullous pemphigoid in sites of grafting [13]. Nevertheless, split skin grafts preserve peculiarities of functionality for a long period [14].

The occurrence of eczema restricted donor sites of split skin grafts has rarely been observed [15], [16], [17]. Eczema or atopic dermatitis is a common disease. The basic pathogenetic mechanism is disturbances of skin barrier function, dysregulated immune response, and disturbances of gut and skin associated microbiome. The leading symptom is itch [18], [19], [20].

Split skin grafts are characterised by a barrier function impairment, demonstrated by increased transepidermal water loss (TEWL) [14]. In split skin grafts, cutaneous adnexae such as hair follicles, sebaceous and sweat glands are absent. Sweat and sebaceous glands, however, are involved in innate immunity and regulate skin hydration among other functions. This creates a certain vulnerability.

## Disturbances of local innervation as a cause of ICD – SKINTED and acquired nevus teleangiectaticus

Sympathetic neurons localised in the spinal cord project to paravertebral or prevertebral ganglia and synapse with relatively long postganglionic fibres innervating blood vessels, lymphoid tissue and organs. The vagus nerve, with cell bodies residing in the brainstem medulla oblongata, is the main nerve of the parasympathetic division of the autonomic

nervous system, innervating peripheral visceral sites. Vagus nerve efferent cholinergic fibres project to visceral organs. Acetylcholine represents the principal neuro mediators released from postganglionic fibres. This molecule interacts with G protein-coupled muscarinic acetylcholine receptors that mediate among others exocrine function of skin glands. The availability of molecular sensors for detecting pathogen fragments and inflammatory molecules on both neurons and immune cells allows their simultaneous involvement in inflammatory responses [21]. If neural components are impaired, this will harm the control of tissue homeostasis

The infrapatellar branches of the saphenous nerve may be damaged by either trauma or surgery with resultant anterior or anteromedial pain and an associated lateral area of altered sensation. The acronym SKINTED (surgery of the knee, injury to the infrapatellar branch of the saphenous nerve, traumatic eczematous dermatitis) describes the eruption of eczematous lesions in the skin after total knee endoprosthesis [22].

Acquired nevoid telangiectasia results from a segmental dilatation of papillary plexus vessels. It is asymptomatic. The disease indicates spinal or neuromuscular complaints with disturbed autonomic vascular nerve function (Figure 1) [23].

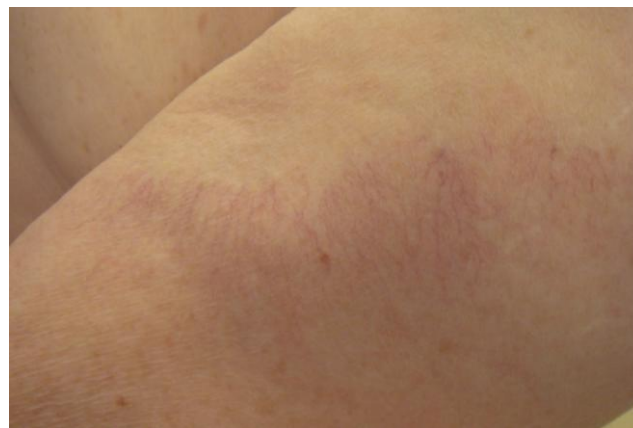

Figure 1: Acquired nevoid telangiectasia

In addition to trauma, infections of the nervous system have to be considered as a cause of ICD. Herpes zoster is caused by the varicella-zoster virus (VZV or herpes virus type 3). The primary infection leads to varicella. During the viraemic period of primary infection, VZV infects sensible dorsal spinal nerve ganglia and/or cephalic nerve ganglia. VZV lies dormant in the nervous system – neurons and glia satellite cells – for years. Endogenous reactivation of viral infection occurs after impairment of immune surveillance. Herpes zoster temporarily alters the function of neurons and ganglia leading to a painful inflammatory response [24].

Wolf's isotopic response describes the onset of secondary skin disease on the site of healed

herpetic lesions [25], [26]. We observed the development of hypertrophic scars and keloids four weeks after herpes zoster infection in a 28-year-old female while she was pregnant. She had not been treated by antiviral drugs during the acute infection and suffered from post-herpetic neuralgia [27].

A 66-year-old male patient with severe facial herpes zoster developed 5 days after zoster remission specific cutaneous zosteriform lesion of his pre-existent B-cellular chronic lymphatic leukaemia [28].

## Lymphatic impairment as a cause of ICD

Lymphedema is caused by failure to drain protein-rich interstitial fluid and can be primary or secondary. Chronic lymph stasis has several consequences, including lipogenesis, fibrosis, inflammation, lymphangiogenesis, and immunosuppression. Lymphedema disrupts immune cell trafficking which leads to localised immunosuppression, predisposing to chronic inflammation, infection, and malignancy. Thus, lymphatic impairment can result in localised skin disease in an ICD [8].

We observed intralymphatic histiocytosis (IH), a rare disease with livedoid, erythematous to violaceous patches and plaques near articular metal implants [29]. The development of Stewart-Treves syndrome (angiosarcoma) in chronic arm lymphedema of breast cancer patients illustrates the importance of an intact lymphatic vasculature for cancer surveillance and prevention (Figure 2) [30].

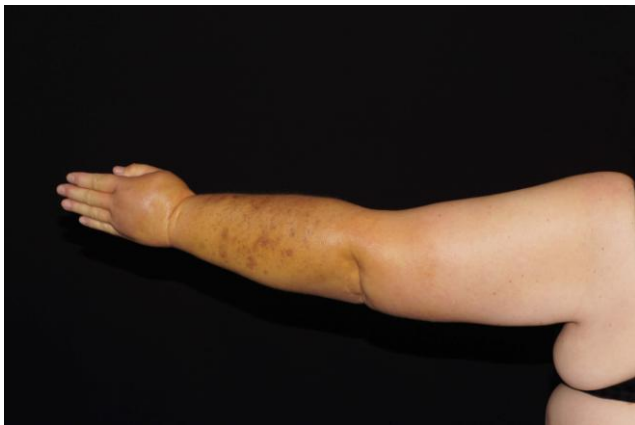

Figure 2: Stewart-Treves syndrome in a breast cancer patient after lymph node dissection and radio-chemotherapy

## Stretch marks as ICD's

Stretch marks are common during pregnancy

and periods of a rapid increase of body weight or muscle mass. They are characterised by disturbances in the connective tissue and increased TEWL. Inflammatory dermatoses like psoriasis and lichen planus but also pigmentary disorders like vitiligo have been observed in stretch marks [31], [32].

The autoimmune disease herpes gestationis develops during the last trimester of pregnancy. It is characterised by vesico-bullous eruptions in striae distensae associated with pruritus [33].

## Injection sites, stings and bites as an ICD

Intralesional injections of corticosteroids may lead to an ICD. Verma (2007) observed the development of a verrucous carcinoma on the foot of an Indian female patient at the injection site [34].

Wilmer et al., (1998) reported on benign lymphangioendothelioma (acquired progressive lymphangioma) at the site of a tick bite [35]. This uncommon benign lesion should be distinguished from well-differentiated angiosarcoma and patch-stage Kaposi's sarcoma [36].

Chronic osteomyelitis after limb trauma can lead to malignant transformation known as Marjolin's ulcer [37].

## Previous sites of radiotherapy as ICD's

Chronic radiodermatitis occurs from 6 months up to 30 years after radiotherapy treatment. The skin develops telangiectasia, pigmentary changes, skin atrophy, dermal fibrosis, and keratoses. There is an ongoing activation of myofibroblasts in the connective tissue induced by transforming growth factor-beta 1 [38]. Sites of chronic radiodermatitis may be prone to delay non-melanoma skin cancer development. Wollina (2016) reported three patients with basal cell carcinomas in such ICD's more than 40 years after irradiation [39].

A 78-year-old female patient presented with a 3 cm large soft tissue defect on the frontotemporal left side with exposed bone and inflammatory soft tissue on the edges of the defect. About 35 years ago, she had undergone combined neurosurgery with skull trepanation and radiotherapy for an oligodendroglioma. Three years ago, sandwich transplantation with the dermal template and meshed skin graft failed. Recently she presented with a chronic ulcer, and a complex defect repair was performed after exclusion of a second malignancy. This is another example of an ICD [40].

Anastrozole is a non-selective aromatase inhibitor for adjuvant breast cancer therapy in postmenopausal women. Cutaneous adverse events have been reported. A 64-year-old female patient with a medical history of locally advanced breast cancer of her right breast that was treated with radiotherapy and adjuvant drug therapy with anastrozole, a non-selective aromatase inhibitor. She developed a segmental bullous eruption limited to the cancer-affected breast. Cessation of the aromatase inhibitor and systemic therapy with prednisolone cleared the lesions completely. This segmental erythema multiforme-like eruption by anastrozole represents another example of the concept of ICD [41].

### Tattoos as ICD's

Tattoos are pigmented areas of traumatised skin. Tattoo inks bear health risk. They may contain hexavalent chromium (Cr [VI]), which is carcinogenic to humans and a dermal sensitiser, benzene or naphthalene, known as carcinogens, and acrylates, known as sensitisers, among others [42], [43]. While contact dermatitis or infections are seen in tattoos, cancer development is a rare event and probably coincidental [44], [45].

The pigment particles are foreign bodies and can induce a chronic inflammatory response such as sarcoidal granulomas [46], [47], [48]. These granulomas are not identical with cutaneous sarcoidosis. However, true cutaneous sarcoidosis has also been observed in tattoos but less common [49], [50].

### Surgical scars as ICD's

Surgery may possess several risks including bleeding, infection, hypertrophic scars or keloid formation. Surgical scars may also be the site of manifestation of other disorders since they represent an IDC.

Koebnerization by scars has been reported for psoriasis [51], lichen sclerosis et atrophicus [52], necrobiosis lipoidica [53], and vitiligo [54]. Scar sarcoidosis is another representative of such dermatoses [55].

In women after open abdominal surgery, cutaneous endometriosis may develop. This uncommon condition is characterised by the presence of an abdominal mass, period and non-period pain. Diagnosis needs to be confirmed by histopathology

[56].

A greatly feared complication after surgery represents pyoderma gangrenosum – a primary sterile neutrophilic dermatosis (Figure 3) [57], [58].

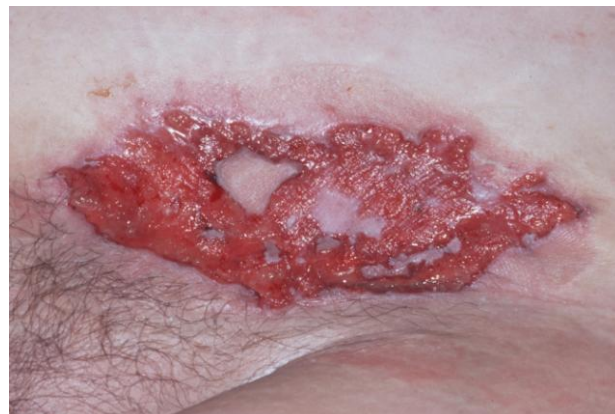

Figure 3: Pyoderma gangrenosum in in a scar from section caesarea

We observed a 63-year old man, who developed a verrucous carcinoma of skin in the scar of knee total endoprosthesis (Figure 4).

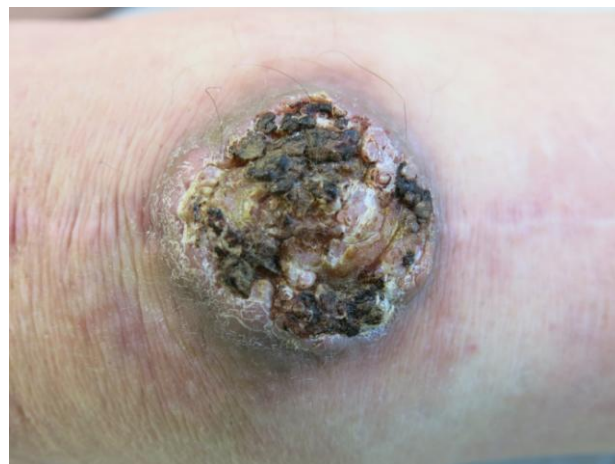

Figure 4: Verrucous carcinoma in the scar after knee total endoprosthesis

### Burn scars as ICD's

The burn wound is characterized by alterations of immune cell composition. Even in the early stage they contain significantly greater numbers of T-cells, primarily  $\alpha\beta$  T-cells with a suppressor phenotype. In contrast, the  $\gamma\delta$  T-cells are diminished, and the expression of the early activator CD69 is decreased 9-fold in the burn wound. This causes and ICD [59].

Deep burn scars seem to facilitate secondary

malignancies. With a delay of a year to decades squamous cell carcinoma, basal cell carcinoma and, to a lesser extent, melanoma has been reported [60]. Rarely, burn-induced tumours of histiocytic origin have been observed in a few cases. Vanhooteghem and Theate (2018) reported a 66-year-old male patient suffering from severe large stage 3 burn on the leg. Fifty-five years later, this patient developed large extraosseous osteosarcoma on the scar [61].

## Chronic friction as an ICD

Chronic friction is a threat to the epidermal barrier. Typical clinical findings of chronic friction are callus, corn, black heel and post-inflammatory hyperpigmentation – in particular in the skin of colour [62].

Friction can cause koebnerization of different, mostly inflammatory dermatoses such as atopic or occupational dermatitis [63], [64], lichen planus, vitiligo [65], frictional hypermelanosis [66], frictional keratosis of the nipple during breastfeeding or the hyperkeratosis of buccal mucosa seen in morsicatio buccorum [67]. Friction plays an obvious role in the manifestation of hidradenitis suppurativa (*syn*: acne inversa) [68]. In obese patients, boils often develop at the site of friction (Figure 5). Sitting with closed-legs on hard ground can cause callosities above the ankles, also known as Yoga sign [69]. Another example of a frictional dermatosis is pretibial alopecia [70].

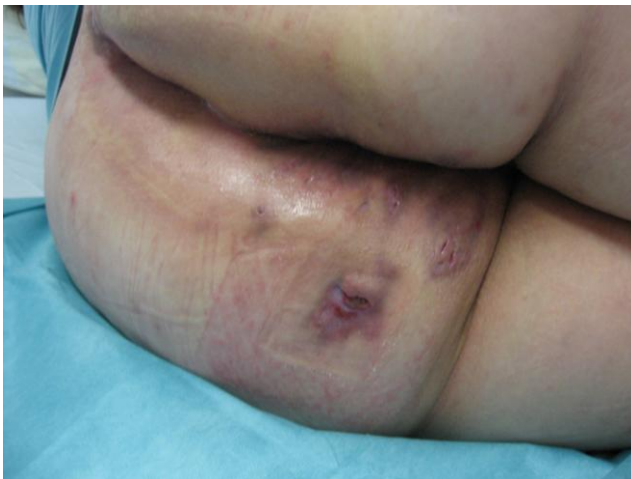

Figure 5: Acne inversa/hidradenitis suppurativa boils gluteal in an area of friction

## Epilation sites as an ICD

Eye-brow threatening is a popular procedure in India. There is several complications that have been reported including the appearance of verrucae,

folliculitis, pseudofolliculitis, hyperpigmentation, and depigmentation, including the koebnerization of vitiligo [71], [72].

Laser hair removal also can induce koebnerization. There are reports on reactive perforating collagenosis and vitiligo induced by laser hair removal [73], [74].

Table 1: Immunocompromised districts of skin

Major alteration(s)	Underlying disorders
Connective tissue disturbances	scars, stretch marks, chronic radiodermatitis, burns
Lymphatic impairment	lymphedema
Disturbed neural function	herpes zoster, spinal or neuromuscular complaints with disturbed autonomic vascular nerve function
Impaired epidermal barrier	skin graft recipient and donor sites, burns
Local immunosuppression	steroid injections, chronic radiodermatitis, burns
Chronic exposure to foreign bodies	tattoos

## Conclusions

The concept of ICD has broadened our view on localised immune dysfunction in the skin. These areas are prone to develop secondary skin disorders, both benign and sometimes malignant. The pathogenesis is not completely understood and does not seem to be uniform. Loss of barrier function, loss of skin glands important for innate immunity, disturbed vascular function, connective tissue alterations, disturbed innervation or chronic exposure to foreign bodies are possible mechanisms (Table 1). Future research is necessary to develop strategies to reconstitute ICD's to gain full immunologic competence again.

## References

- Kanitakis J. Anatomy, histology and immunohistochemistry of normal human skin. *Eur J Dermatol.* 2002; 12:390-9.
- Elias PM. Stratum corneum defensive functions: an integrated view. *J Invest Dermatol.* 2005; 125:183-200. <https://doi.org/10.1111/j.0022-202X.2005.23668.x> PMID:16098026
- Salimi M, Ogg G. Innate lymphoid cells and the skin. *BMC Dermatol.* 2014; 14:18. <https://doi.org/10.1186/1471-5945-14-18> PMID:25427661 PMCid:PMC4289267
- Inamadhar AC, Palit A. Acute skin failure: Concepts, causes, consequences and care. *Indian J Dermatol Venereol Leprol.* 2005; 71:379-85. <https://doi.org/10.4103/0378-6323.18007>
- Wollina U, Nowak A. Dermatology in the intensive care unit. *Our Dermatology.* 2012; 3:298-303. <https://doi.org/10.7241/ourd.20124.65>
- Irvine C. 'Skin failure' a real entity: discussion paper. *J R Soc Med.* 1991; 84:412-3. <https://doi.org/10.1177/014107689108400711> PMID:1865448 PMCid:PMC1293332
- Ruocco V, Ruocco E, Piccolo V, Brunetti G, Guerrera LP, Wolf R. The immunocompromised district in dermatology: A unifying pathogenic view of the regional immune dysregulation. *Clin Dermatol.* 2014; 32:569-76. <https://doi.org/10.1016/j.clindermatol.2014.04.004> PMID:25160098

8. Ruocco E, Puca RV, Brunetti G, Schwartz RA, Ruocco V. Lymphedematous areas: privileged sites for tumors, infections, and immune disorders. *Int J Dermatol*. 2007; 46:662. <https://doi.org/10.1111/j.1365-4632.2007.03244.x> PMID:17550576
9. Ruocco V, Brunetti G, Puca RV, Ruocco E. The immunocompromised district: a unifying concept for lymphoedematous, herpes-infected and otherwise damaged sites. *J Eur Acad Dermatol Venereol*. 2009; 23:1364-73. <https://doi.org/10.1111/j.1468-3083.2009.03345.x> PMID:19548975
10. Maarof M, Law JX, Chowdhury SR, Khairoji KA, Saim AB, Idrus RB. Secretion of wound healing mediators by single and bi-layer skin substitutes. *Cytotechnology*. 2016; 68:1873-84. <https://doi.org/10.1007/s10616-015-9940-3> PMID:26768914 PMID:PMC5023561
11. Chen L, Xing Q, Zhai Q, Tahtinen M, Zhou F, Chen L, et al. Pre-vascularization enhances therapeutic effects of human mesenchymal stem cell sheets in full thickness skin wound repair. *Theranostics*. 2017; 7:117-31. <https://doi.org/10.7150/thno.17031> PMID:28042321 PMID:PMC5196890
12. Lu C, Fuchs E. Sweat gland progenitors in development, homeostasis, and wound repair. *Cold Spring Harb Perspect Med*. 2014; 4:a015222. <https://doi.org/10.1101/cshperspect.a015222> PMID:24492848 PMID:PMC3904096
13. Ghura HS, Johnston GA, Milligan A. Development of a bullous pemphigoid after split-skin grafting. *Br J Surg*. 2001; 54:447-9. <https://doi.org/10.1054/bjps.2001.3601> PMID:11428779
14. Kim YJ, Kim MY, Lee PK, Kim HO, Park YM. Evaluation of natural change of skin function in split-thickness skin grafts by noninvasive bioengineering methods. *Dermatol Surg*. 2006; 32:1358-63. <https://doi.org/10.1111/j.1524-4725.2006.32306.x> PMID:17083588
15. Sahin C, Noyan N, Ergun O, Sever C, Kulahci Y. Eczema in full-thickness skin graft. *J Burn Care Res*. 2013; 34:e58. <https://doi.org/10.1097/BCR.0b013e31825adb43> PMID:22929528
16. Harnack K, Miemiec E, Waldau W. Endogenous eczema in a split-thickness skin graft. *Dermatol Monatsschr*. 1972; 158:28-32.
17. Constantini N. Eczema of Thiersch's graft following radical surgery. *Arcisp S Anna Ferrara*. 1954; 7:169-79.
18. Elias PM, Steinhoff M. "Outside-to-inside" (and now back to "outside") pathogenic mechanisms in atopic dermatitis. *J Invest Dermatol*. 2008; 128:1067-70. <https://doi.org/10.1038/jid.2008.88> PMID:18408746 PMID:PMC2675555
19. Weidinger S, Novak N. Atopic dermatitis. *Lancet*. 2016; 387:1109-22. [https://doi.org/10.1016/S0140-6736\(15\)00149-X](https://doi.org/10.1016/S0140-6736(15)00149-X)
20. Wollina U. Microbiome in atopic dermatitis. *Clin Cosmet Investig Dermatol*. 2017; 10:51-6. <https://doi.org/10.2147/CCID.S130013> PMID:28260936 PMID:PMC5327846
21. Pavlov VA, Chavan SS, Tracey KJ. Molecular and functional neuroscience in immunity. *Annu Rev Immunol*. 2018; 36:783-812. <https://doi.org/10.1146/annurev-immunol-042617-053158> PMID:29677475 PMID:PMC6057146
22. Verma SB, Mody BS. Explaining a hitherto nameless condition: 'SKINTED'. *Clin Exp Dermatol*. 2009; 34:e465-6. <https://doi.org/10.1111/j.1365-2230.2009.03522.x> PMID:19747315
23. Wollina U, Barta U, Uhlemann C, Oelzner P. Acquired nevoid telangiectasia. *Dermatology*. 2001; 203:24-6. <https://doi.org/10.1159/000051698> PMID:11549795
24. Wollina U. Variations in herpes zoster manifestation. *Indian J Med Res*. 2017; 145:294-298.
25. Wolf R, Wolf D. Tinea in a site of healed herpes zoster (isoloci response?). *Int J Dermatol*. 1985; 24:539. <https://doi.org/10.1111/j.1365-4362.1985.tb05561.x> PMID:4066096
26. Wolf R, Wolf D, Ruocco V, Ruocco E. Wolf's isotopic response: The first attempt to introduce the concept of vulnerable areas in dermatology. *Clin Dermatol*. 2014; 32:557-60. <https://doi.org/10.1016/j.clindermatol.2014.04.002> PMID:25160096
27. Verma SB, Wollina U. Herpes zoster in pregnancy leading to keloids and post herpetic neuralgia: A double whammy? *Indian Dermatol Online J*. 2013; 4:158-9. <https://doi.org/10.4103/2229-5178.110646> PMID:23741683 PMID:PMC3673390
28. Wollina U, Schönlebe J. Disseminated specific cutaneous infiltrates of B-cell chronic lymphocytic leukemia - Wolf's isotopic response following herpes zoster infection. *J Dtsch Dermatol Ges*. 2016; 14:179-81. <https://doi.org/10.1111/ddg.12670> PMID:26283648
29. Darling MD, Akin R, Tarbox MB, Stetson CL, Patterson JW, Tchernev G, et al. Intralymphatic histiocytosis overlying hip implantation treated with pentoxifylline. *J Biol Regul Homeost Agents*. 2015; 29(1 Suppl):117-21.
30. Bennewitz A, Langner D, Schönlebe J, Heinig B, Koch A, Wollina U. Stewart-Treves-Syndrom beim sekundären Arm-Lymphödem neun Jahre nach invasiv-duktalem Mammakarzinom. *Lymph Forsch Praxis*. 2013; 17:16-8.
31. Verma SB. Vitiligo precipitated by striae: a little known entity. *J Eur Acad Dermatol Venereol*. 2009; 23:357-8. <https://doi.org/10.1111/j.1468-3083.2008.02844.x> PMID:18554226
32. Verma SB. Striae: stretching the long list of precipitating factors for 'true koebnerization' of vitiligo, lichen planus and psoriasis. *Clin Exp Dermatol*. 2009; 34:880-3. <https://doi.org/10.1111/j.1365-2230.2009.03312.x> PMID:19489859
33. Wollina U, Degen KW, Konrad H, Schönlebe J. Itching stretch marks and bullous lesions in a pregnant woman. *Int J Dermatol*. 2004; 43:752-4. <https://doi.org/10.1111/j.1365-4632.2004.02356.x> PMID:15485535
34. Verma SB. Verrucous lesion on dorsum of the foot. *Indian J Dermatol Venereol Leprol*. 2007; 73:281. <https://doi.org/10.4103/0378-6323.33654> PMID:17682297
35. Wilmer A, Kaatz M, Mentzel T, Wollina U. Lymphangioendothelioma after a tick bite. *J Am Acad Dermatol*. 1998; 39:126-8. [https://doi.org/10.1016/S0190-9622\(98\)70416-5](https://doi.org/10.1016/S0190-9622(98)70416-5)
36. Guillou L, Fletcher CD. Benign lymphangioendothelioma (acquired progressive lymphangioma): a lesion not to be confused with well-differentiated angiosarcoma and patch stage Kaposi's sarcoma: clinicopathologic analysis of a series. *Am J Surg Pathol*. 2000; 24:1047-57. <https://doi.org/10.1097/0000478-200008000-00002> PMID:10935645
37. Bula P, Bula-Sternberg J, Wollina U, Haroske G, Bonnaire F. [Marjolin's ulcer: malignant transformation of a crural ulcer due to posttraumatic chronic osteomyelitis]. *Unfallchirurg*. 2010; 113:149-54. <https://doi.org/10.1007/s00113-009-1671-5> PMID:19859679
38. Martin M, Lefaix J, Delanian S. TGF-beta1 and radiation fibrosis: a master switch and a specific therapeutic target? *Int J Radiat Oncol Biol Phys*. 2000; 47:277-90. [https://doi.org/10.1016/S0360-3016\(00\)00435-1](https://doi.org/10.1016/S0360-3016(00)00435-1)
39. Wollina U. Basal cell carcinoma in the area of chronic radiodermatitis - 3 case reports with long-term follow-up. *Georgian Med News*. 2016; (254):7-10.
40. Wollina U, Nowak A, Tchernev G, Lotti T. Chronic scalp ulcer 35 years after skull trepanation surgery and radiotherapy for oligodendroglioma: A further example of immunocompromised cutaneous districts. *Open Access Maced J Med Sci*. 2017; 6:55-7. <https://doi.org/10.3889/oamjms.2018.019> PMID:29483982 PMID:PMC5816315
41. Wollina U, Schönlebe J, Heinig B, Tchernev G, França K, Lotti T. Segmental erythema multiforme-like drug eruption by aromatase inhibitor anastrozole - first case report and another example of an immunocompromised district. *Open Access Maced J Med Sci*. 2018; 6:79-81. <https://doi.org/10.3889/oamjms.2018.026> PMID:29483990 PMID:PMC5816324
42. Bocca B, Senofonte O, Petrucci F. Hexavalent chromium in tattoo inks: Dermal exposure and systemic risk. *Contact Dermatitis*. 2018; 79:218-25. <https://doi.org/10.1111/cod.13051> PMID:29998510
43. Schreiver I, Hutzler C, Andree S, Laux P, Luch A. Identification and hazard prediction of tattoo pigments by means of pyrolysis-

- gas chromatography/mass spectrometry. Arch Toxicol. 2016; 90:1639-50. <https://doi.org/10.1007/s00204-016-1739-2> PMID:27209489 PMCID:PMC4894928
44. Kluger N, Koljonen V. Tattoos, inks, and cancer. Lancet Oncol. 2012; 13:e161-8. [https://doi.org/10.1016/S1470-2045\(11\)70340-0](https://doi.org/10.1016/S1470-2045(11)70340-0)
45. Wollina U. Severe adverse events related to tattooing: a retrospective analysis of 11 years. Indian J Dermatol. 2012; 57:439-43. <https://doi.org/10.4103/0019-5154.103062> PMID:23248361 PMCID:PMC3519250
46. Wollina U, Gruner M, Schönlebe J. Granulomatous tattoo reaction and erythema nodosum in a young woman: common cause or coincidence? J Cosmet Dermatol. 2008; 7:84-8. <https://doi.org/10.1111/j.1473-2165.2008.00368.x> PMID:18482009
47. Leverenz DL, Henderson C, Shah A. Atypical cutaneous presentations of sarcoidosis: two case reports and review of the literature. Curr Allergy Asthma Rep. 2018; 18:40. <https://doi.org/10.1007/s11882-018-0794-6> PMID:29904803
48. Tchernev G, Lotti T, Wollina U, Cardoso JC, Popova LV, Maximov GK, et al. Sarcoidosis in A. C. Milan (1899)? Open Access Maced J Med Sci. 2018; 6:99-102. <https://doi.org/10.3889/oamjms.2018.049> PMID:29483997 PMCID:PMC5816331
49. Kluger N. Cutaneous complications related to tattoos: 31 cases from Finland. Dermatology. 2017; 233:100-9. <https://doi.org/10.1159/000468536> PMID:28441655
50. Grosse J, Menhart K, Schmidbauer B, Helliwig D. Cutaneous manifestation of sarcoidosis in lower-back tattoo with increased uptake of 18F-FDG. Clin Nucl Med. 2018; 43:454-5. <https://doi.org/10.1097/RLU.0000000000002061> PMID:29538031
51. Alolabi N, White CP, Cin AD. The Koebner phenomenon and breast reconstruction: Psoriasis eruption along the surgical incision. Can J Plast Surg. 2011; 19:143-4. <https://doi.org/10.1177/229255031101900411> PMID:23204886 PMCID:PMC3269195
52. Mendieta-Eckert M, Ocerin-Guerra I, Landa-Gundin N. Lichen sclerosus et atrophicus in a surgical scar treated with fractional laser. J Cosmet Laser Ther. 2017; 19:106-8. <https://doi.org/10.1080/14764172.2016.1262955> PMID:27911123
53. Prieto-Torres L, Bernárdez C, Hernández-Ostiz S, Pastushenko I, Ara-Martin M, Requena L. Necrobiosis lipoidica developing within a surgical scar in a non-diabetic patient: Type III Koebner phenomenon (isomorphic response), Wolf's isotopic response or Ruocco's immunocompromised cutaneous district? Indian J Dermatol Venereol Leprol. 2017; 83:233-6. <https://doi.org/10.4103/0378-6323.197389> PMID:28071608
54. Khurram H, AlGhamdi KM, Bedaiwi KM, AlBalal NM. Multivariate analysis of factors associated with the Koebner phenomenon in vitiligo: An observational study of 381 patients. Ann Dermatol. 2017; 29:302-6. <https://doi.org/10.5021/ad.2017.29.3.302> PMID:28566906 PMCID:PMC5438936
55. Tchernev G, Cardoso JC, Chokoeva AA, Verma SB, Tana C, Ananiev J, et al. The "mystery" of cutaneous sarcoidosis: facts and controversies. Int J Immunopathol Pharmacol. 2014; 27:321-30. <https://doi.org/10.1177/039463201402700302> PMID:25280023
56. Lopez-Soto A, Sanchez-Zapata MI, Martinez-Cendan JP, Ortiz Reina S, Bernal Mañas CM, Remezal Solano M. Cutaneous endometriosis: Presentation of 33 cases and literature review. Eur J Obstet Gynecol Reprod Biol. 2018; 221:58-63. <https://doi.org/10.1016/j.ejogrb.2017.11.024> PMID:29310043
57. Wollina U. Pyoderma gangrenosum--a review. Orphanet J Rare Dis. 2007; 2:19. <https://doi.org/10.1186/1750-1172-2-19> PMID:17433111 PMCID:PMC1857704
58. Verma SB. Atypical pyoderma gangrenosum following total knee replacement surgery: First report in dermatologic literature. An Bras Dermatol. 2009; 84:689-91. <https://doi.org/10.1590/S0365-05962009000600020> PMID:20191186
59. Rani M, Schwacha MG. The composition of T-cell subsets are altered in the burn wound early after injury. PLoS One. 2017; 12:e0179015. <https://doi.org/10.1371/journal.pone.0179015> PMID:28575063 PMCID:PMC5456360
60. Yoo JJ, Kim HS, Kim JH, Joo M, Kim KJ, Park S, Jet al. Clinical features and treatment outcomes of skin cancer arising from burn scar: a single-institution experience. Tumori. 2014; 100:26-30.
61. Vanhooteghem O, Theate I. A rare extraskeletal osteosarcoma appearing after 55 years on a large stage 3 burn scar. Case Rep Dermatol Med. 2018; 2018:5185604. <https://doi.org/10.1155/2018/5185604> PMID:29971170 PMCID:PMC6008689
62. Wollina U. Disorders Caused by Physical and Chemical Damage. In: Burgdorf WHC, Plewig G, Wolff HH, Landthaler M (Editors): Braun-Falco's Dermatology, 3rd edition. Berlin, Heidelberg: Springer-Verlag; 2009:598-616.
63. Bennike NH, Johansen JD, Menné T. Friction from paper and cardboard causing occupational dermatitis in non-atopic individuals. Contact Dermatitis. 2016; 74:307-8. <https://doi.org/10.1111/cod.12530> PMID:27040878
64. Wollina U, Heinig B, Tchernev G, França K, Lotti T. Unilateral palmar callus and irritant hand eczema - underreported signs of dependency on crutches. Open Access Maced J Med Sci. 2018; 6:103-4. <https://doi.org/10.3889/oamjms.2018.031> PMID:29483998 PMCID:PMC5816272
65. Verma SB. Dermatological signs in South Asian women induced by sari and petticoat drawstrings. Clin Exp Dermatol. 2010; 35:459-61. <https://doi.org/10.1111/j.1365-2230.2009.03587.x> PMID:19758377
66. Wollina U, Tchernev G, Lotti T. Frictional dermatosis in a courier driver. Open Access Maced J Med Sci. 2017; 5:541-2. <https://doi.org/10.3889/oamjms.2017.108> PMID:28785356 PMCID:PMC5535681
67. Wollina U. Krebsvorläufer an der Mundschleimhaut? MMW Fortschr Med. 2017; 159:7. <https://doi.org/10.1007/s15006-017-0144-y> PMID:29071646
68. Verma SB, Wollina U. Callosities of cross legged sitting: "yoga sign"--an under-recognized cultural cutaneous presentation. Int J Dermatol. 2008; 47:1212-4. <https://doi.org/10.1111/j.1365-4632.2008.03823.x> PMID:18986470
69. Boer J. Should hidradenitis suppurativa be included in dermatoses showing koebnerization? Is it friction or fiction? Dermatology. 2017; 233:47-52. <https://doi.org/10.1159/000472252> PMID:28505620
70. Zhao J, Cohen PR. Frictional alopecia of the distal legs: case series and review. Dermatol Online J. 2016; 22(8).
71. Verma SB. Vitiligo with koebnerisation due to eyebrow plucking by threading. J Cosmet Dermatol. 2002; 1:214-5. <https://doi.org/10.1111/j.1473-2165.2002.00069.x> PMID:17147543
72. Verma SB. Eyebrow threading: a popular hair-removal procedure and its seldom-discussed complications. Clin Exp Dermatol. 2009; 34:363-5. <https://doi.org/10.1111/j.1365-2230.2008.02920.x> PMID:19021633
73. Doshi SN, Levy ML, Markus R. Koebnerization of reactive perforating collagenosis induced by laser hair removal. Lasers Surg Med. 2003; 32:177-9. <https://doi.org/10.1002/lsm.10158> PMID:12605422
74. Zainab J. Koebnerization of reactive perforating collagenosis induced by laser hair removal. J Cosmet Dermatol. 2011; 10:72-3. <https://doi.org/10.1111/j.1473-2165.2010.00542.x> PMID:21332919

# Cutaneous Angiosarcoma of Head and Neck – A Single-Centre Analysis

Uwe Wollina<sup>1\*</sup>, André Koch<sup>1</sup>, Gesina Hansel<sup>1</sup>, Jacqueline Schönlebe<sup>2</sup>, Torello Lotti<sup>3</sup>, Aleksandra Vojvodic<sup>3,4</sup>

<sup>1</sup>Department of Dermatology and Allergology, Städtisches Klinikum Dresden, Academic Teaching Hospital, Dresden, Germany; <sup>2</sup>Institute of Pathology “Georg Schmorl”, Städtisches Klinikum Dresden, Academic Teaching Hospital, Dresden, Germany; <sup>3</sup>Department of Dermatology, University of Rome “G. Marconi”, Rome, Italy; <sup>4</sup>Military Medical Academy of Belgrade, Belgrade, Serbia

## Abstract

**Citation:** Wollina U, Koch A, Hansel G, Schönlebe J, Lotti T, Vojvodic A. Cutaneous Angiosarcoma of Head and Neck – A Single-Centre Analysis. Open Access Maced J Med Sci. 2019 Sep 30; 7(18):2976-2978. <https://doi.org/10.3889/oamjms.2019.763>

**Keywords:** Sarcoma; Cutaneous angiosarcoma; Head and neck region; Histology; Treatment; Outcome

**\*Correspondence:** Uwe Wollina, Department of Dermatology and Allergology, Städtisches Klinikum Dresden, Academic Teaching Hospital, Dresden, Germany. E-mail: uwollina@gmail.com

**Received:** 05-Apr-2019; **Revised:** 04-Jul-2019; **Accepted:** 05-Jul-2019; **Online first:** 30-Aug-2019

**Copyright:** © 2019 Uwe Wollina, André Koch, Gesina Hansel, Jacqueline Schönlebe, Torello Lotti, Aleksandra Vojvodic. This is an open-access article distributed under the terms of the Creative Commons Attribution-NonCommercial 4.0 International License (CC BY-NC 4.0)

**Funding:** This research did not receive any financial support

**Competing Interests:** The authors have declared that no competing interests exist

**BACKGROUND:** Cutaneous angiosarcoma of the head and neck region is a subtype of cutaneous angiosarcoma with an unfavourable prognosis. Diagnosis is often delayed.

**PATENTS AND METHODS:** The setting is an Academic Teaching Hospital Skin Cancer Center. Eight Caucasian patients could be identified, 5 men and 3 women. Delay to diagnosis was between 12 to 4 months (mean 7.8 ± 2.9 months). The diagnosis was confirmed in all cases by histopathology and immunohistochemistry. Hematoxylin-eosin, Giemsa, PAS, iron and reticulin stains were performed. Endothelial markers such as CD31, CD34, and Ki67 for proliferation assessment were used in all tumours. Other markers used included pan-cytokeratin (CK), CK7, CK20, ERG, CD 40 and c-MYC. Tumours were classified as localised versus multifocal or diffuse form. Tumour staging was performed according to the 8th edition of the AJCC. The mean age of patients was 79 years ± 26.4 years. The male to female ratio was 1.7. Tumour classification was diffuse in 2 patients, multilocular in one and localised in 5 patients. In 5 of 8 patients, a multimodal treatment was performed, one had radiotherapy alone, in another patient surgery was performed, and radiotherapy is planned. The mean OS was 26.4 months ± 24.5 months.

**CONCLUSION:** Cutaneous angiosarcoma of the head and neck is an aggressive tumour with a poor prognosis. Although surgery remains a cornerstone of treatment, the tumour size at first presentation may be too large, and the elderly patients maybe not suitable for extensive surgery. Therefore, multimodal treatment with adjuvant radiotherapy and/ or chemotherapy is necessary. Multimodal treatment offers a better outcome than radiotherapy or chemotherapy alone. Stealth liposomal encapsulated doxorubicin is a therapeutic option for elderly patients with improved safety compared to conventional doxorubicin.

## Introduction

Cutaneous angiosarcoma of the head and neck is a rare tumour entity of vascular origin. It comprises about half of all angiosarcomas and accounts for 1% of all soft tissue sarcomas. This tumour is notorious for its aggressive and relentless progression with frequent local recurrence and distant metastasis. It affects mainly older people with a mean age of 73 years. Due to its scarcity and innocuous appearance at an early stage diagnosis is often delayed for months. Bleeding is one of the leading

symptoms that is responsible for the first consultation. However, bleeding is not an early sign [1].

A study of the National Cancer Institute's Surveillance, Epidemiology, and End Results Program recorded 434 cases of cutaneous angiosarcoma from 1973 to 2007 with a comparable incidence in men and women. Caucasians represented the majority of patients compared to patients with Asian or African descent. Survival rates are dependent on age, anatomical site, and stage of the disease. In this study, patients < 50 years had a 10-year relative survival rate of 71.7%, whereas patients ≥ 50 years



had a 36.8% 10-year survival rate. Tumours of the scalp and neck had a poor survival rate (13.8% 10-year relative survival rate) compared to tumours on the trunk (75.3% 10-year survival rate). Tumours localised to the skin had a better prognosis (53.6% 10-year relative survival rate) than those with the regional or distant stage (19.0% and 6.2%) [2].

Scalp sarcoma tends to be larger at the time of diagnosis. That is responsible for a poorer prognosis than facial angiosarcoma. An analysis on 50 patients with cutaneous head and neck angiosarcomas from the Princess Margaret Cancer Centre, Toronto / Ontario, Canada, estimated a 5-year overall survival (OS) rate of 9% for scalp tumours and 26% for tumours of the face. In multivariate Cox proportional hazards analysis of their data, scalp location was independently prognostic for mortality (hazard ratio [HR], 2.10; 95% CI, 1.03-4.28; p = .04) [3].

**Patients and Methods**

Patients were seen and treated at the Department of Dermatology and Allergology, Skin Cancer Center. Delay to diagnosis was between 12 to 4 months (mean 7.8 ± 2.9 months). Differential diagnoses were lentigo, bruising, rosacea, squamous cell carcinoma and erysipelas.

The diagnosis was confirmed in all cases by histopathology and immunohistochemistry. Hematoxylin-eosin, Giemsa, PAS, iron and reticulin stains were performed. Endothelial markers such as CD31, CD34, and Ki67 for proliferation assessment were used in all tumours. Other markers used included pan-cytokeratin (CK), CK7, CK20, ERG, CD 40 and c-MYC.

Tumours were classified as localised versus multifocal or diffuse form. Tumour staging was performed according to the 8<sup>th</sup> edition of the AJCC [4]. The demographics are listed in Table 1.

**Table 1: Demographics of head and neck cutaneous angiosarcoma**

	Age	Sex	Localization	Size (cm)	Remarks	TNM
1	79 yrs	F	Scalp, temporoparietal	20	ulcerations, bleeding	pT4N0M0
2	74 yrs	M	Cheek	3.5	relapse after 6 yrs.	pT1N0M0
3	81 yrs	F	Scalp	30	ulceration, bleeding	pT4N1M0
4	85 yrs	M	Scalp	20	ulceration, bleeding	pT4N1M0
5	66 yrs	M	Cheek	4	Oedema	pT2N0M0
6	82 yrs	F	Scalp	2	multilocular, bleeding	pT2N0M0
7	66 yrs	M	Nose	6	oedema, redness	pT2N0M0
8	79 yrs	M	Scalp	12	Bleeding	pT3N0M0

The mean age was 79 years ± 26.4 years. The male to female ratio was 1.7. Tumour classification was diffuse in 2 patients, multilocular in one and localised in 5 patients (Figure 1).

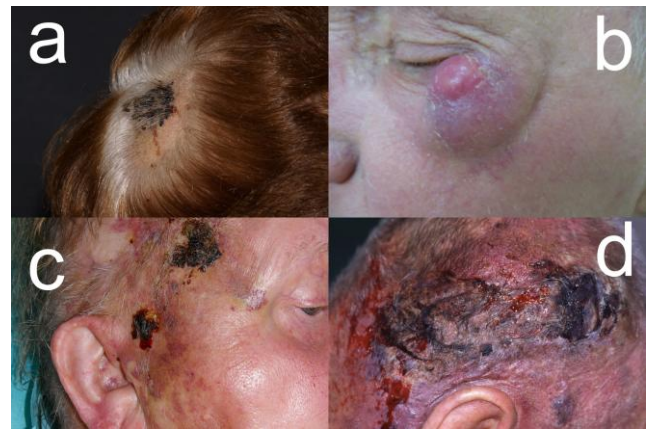

Figure 1: Cutaneous angiosarcoma of the head and neck region; A) Localized patch; B) Localized nodule; C) Multifocal tumour; D) Diffuse tumour

In 5 of 8 patients, a multimodal treatment was performed, one had radiotherapy alone, in another patient surgery was performed, and radiotherapy is planned (Figure 2). The mean OS was 26.4 months ± 24.5 months (Table 2).

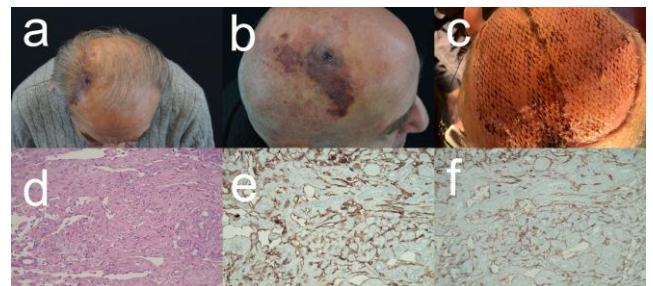


Figure 2: Cutaneous angiosarcoma, patient #8; A) Primary presentation – “bruising after local trauma”; B) Large localized scalp tumor after shaving; C) After surgery with curative intent (safety margin 2 cm), stable meshed graft transplant; D) and E) Histopathology and immunohistochemistry of the tumour; D) Irregular vascular proliferations interposed by the dermal collagen fibers. Endothelial cells with atypical nuclei, prominent toward the lumen, mitotic figures (Hematoxylin-eosin x 4); E) Immunoperoxidase staining for CD31, strongly expressed by the endothelial tumour cells (x 20); F) Immunoperoxidase staining with Ki67 demonstration a highly proliferative fraction of almost 100 % of tumour cells (x 20)

**Discussion**

The mainstay of treatment of cutaneous angiosarcoma of the head and neck is surgery. Surgery with curative intent as the initial treatment is significantly associated with improved overall survival [5].

However, complete excision is not always possible. In such a situation, multimodal regimens seem to improve the outcome [6]. A trial from the Mayo Clinic analysed 55 patients with angiosarcoma localised to the face or scalp. Multimodal treatment received 73% of patients (the combination of surgery,

radiation therapy, and/or chemotherapy), 15% were treated only surgically, 95 with chemotherapy, 2% with radiation alone and 2% had observation alone. The 5-year OS was 38%. On univariate analysis, the use of multimodality therapy (vs no multimodality therapy) was associated with higher 5-year OS (46% [26% vs 16%] [7]).

**Table 2: Treatment of head and neck cutaneous angiosarcoma and outcome**

Treatment	Safety	Overall Survival
1 Liposomal doxorubicin (20 mg/m <sup>2</sup> ) followed by electron beam (total 40 Gy)	Palmoplantar dysesthesia (CTC 0) radiation-induced erythema (CTC 2)	40 months
2 Surgery followed by electron beam (total 40 Gy)	Radiation-induced erythema (CTC 2)	80 months
3 Liposomal doxorubicin (20 mg/m <sup>2</sup> ) followed by electron beam (total 40 Gy)	Anemia & lymphopenia (CTC 2); radiation-induced erythema (CTC 2)	9 months
4 Electron beam (total 40 Gy)	Radiation-induced erythema (CTC 2)	3 months
5 Paclitaxel followed by electron beam (total 40 Gy)	Radiation-induced erythema (CTC 3)	6 months
6 Electron beam (total 40 Gy)	Radiation-induced erythema (CTC 2)	44 months
7 Surgery followed by electron beam (total 40 Gy)	Post-radiation-erythema (CTC 3)	80 months
8 Surgery, radiation is planned	-	> 4 months

Radiotherapy is most often used in combination with surgery. A meta-analysis from South Korea demonstrated that OS of the radiation therapy and chemotherapy group (37.0 ± 0.0 months) was significantly longer than that of the radiation therapy group alone (22.7 ± 7.6 months) or the chemotherapy group alone (15.1 ± 4.6 months) [8]. This is in one line with a trial from Osaka, Japan, that demonstrated patients treated with both surgery and radiotherapy (2-year OS: 45.8%) had a significantly better OS than patients treated with either surgery or radiotherapy alone (2-year OS: 11.1%) and patients treated with neither surgery nor radiotherapy (2-year OS: 0%) [9].

Considering chemotherapy in elderly patients, taxanes showed a response rate of 83.3% and a median progression-free survival of seven months, compared to non-liposomal doxorubicin with a response rate of 50% and median progression-free survival of 3 months [10]. Taxanes show anti-angiogenic activity. The conventional doxorubicin therapy bears a high risk of cardiotoxicity, that leads to the cessation of the treatments. This has not been observed with stealth liposomal doxorubicin [11].

In our series, advanced tumour stages and age > 70 years was characteristic. Initial differential diagnoses were bruising, lentigo-like hyperpigmentation and rosacea. Most patients presented to the doctor because of bleeding. None of the tumours was diagnosed at outpatient cancer screenings.

In conclusion, cutaneous angiosarcoma of the head and neck is a rare but aggressive vascular malignancy with a less favourable prognosis than the counterparts on trunk or extremities. Many patients are older than 70 years of age that needs to be considered for multimodal treatment. Surgery plus radiotherapy is the treatment of choice. When chemotherapy is necessary, stealth liposomal doxorubicin offers a better safety profile for this age group that conventional doxorubicin or taxanes [11], [12], [13].

## References

- Young RJ, Brown NJ, Reed MW, Hughes D, Woll PJ. Angiosarcoma. *Lancet Oncol.* 2010; 11(10):983-91. [https://doi.org/10.1016/S1470-2045\(10\)70023-1](https://doi.org/10.1016/S1470-2045(10)70023-1)
- Albores-Saavedra J, Schwartz AM, Henson DE, Kostun L, Hart A, Angeles-Albores D, Chablé-Montero F. Cutaneous angiosarcoma. Analysis of 434 cases from the Surveillance, Epidemiology, and End Results Program, 1973-2007. *Ann Diagn Pathol.* 2011; 15(2):93-7. <https://doi.org/10.1016/j.anndiagpath.2010.07.012> PMID:21190880
- Bernstein JM, Irish JC, Brown DH, Goldstein D, Chung P, Razak ARA, Catton C, Gilbert RW, Gullane PJ, O'Sullivan B. Survival outcomes for cutaneous angiosarcoma of the scalp versus face. *Head Neck.* 2017; 39(6):1205-1211. <https://doi.org/10.1002/hed.24747> PMID:28398688
- Amin MB, Greene FL, Edge S, Schilsky RL, Gaspar LE, Washington MK, Sullivan DC, Brookland RK. *AJCC Cancer Staging Manual*, 8th Edition. Springer International, New York, 2017.
- Oashi K, Namikawa K, Tsutsumida A, Takahashi A, Itami J, Igaki H, Inaba K, Yamazaki N. Surgery with curative intent is associated with prolonged survival in patients with cutaneous angiosarcoma of the scalp and face -a retrospective study of 38 untreated cases in the Japanese population. *Eur J Surg Oncol.* 2018; 44(6):823-829. <https://doi.org/10.1016/j.ejso.2018.02.246> PMID:29555155
- Wollina U, Hansel G, Schönlebe J, Averbek M, Paasch U, Uhl J, Hindemann W, Simon J-C. Cutaneous angiosarcoma is a rare aggressive malignant vascular tumour of the skin. *J Eur Acad Dermatol Venereol.* 2011; 25(8):964-8. <https://doi.org/10.1111/j.1468-3083.2010.03905.x> PMID:21108661
- Patel SH, Hayden RE, Hinni ML, Wong WW, Foote RL, Milani S, Wu Q, Ko SJ, Halyard MY. Angiosarcoma of the scalp and face: the Mayo Clinic experience. *JAMA Otolaryngol Head Neck Surg.* 2015; 141(4):335-40. <https://doi.org/10.1001/jamaoto.2014.3584> PMID:25634014
- Hwang K, Kim MY, Lee SH. Recommendations for therapeutic decisions of angiosarcoma of the scalp and face. *J Craniofac Surg.* 2015; 26(3):e253-6. <https://doi.org/10.1097/SCS.0000000000001495> PMID:25901670
- Ogawa K, Takahashi K, Asato Y, Yamamoto Y, Taira K, Matori S, Irahata S, Yagi N, Yogi A, Haranaga S, Fujita J, Uezato H, Murayama S. Treatment and prognosis of angiosarcoma of the scalp and face: a retrospective analysis of 48 patients. *Br J Radiol.* 2012; 85(1019):e1127-33. <https://doi.org/10.1259/bjr/31655219> PMID:22806620 PMID:PMC3500812
- Letsa I, Benson C, Al-Muderis O, Judson I. Angiosarcoma of the face and scalp: effective systemic treatment in the older patient. *J Geriatr Oncol.* 2014; 5(3):276-80. <https://doi.org/10.1016/j.jgo.2014.02.004> PMID:24685486
- Judson I, Radford JA, Harris M, Blay JY, van Hoesel Q, le Cesne A, van Oosterom AT, Clemons MJ, Kamby C, Hermans C, Whittaker J, Donato di Paola E, Verweij J, Nielsen S. Randomised phase II trial of pegylated liposomal doxorubicin (DOXIL/CAELYX) versus doxorubicin in the treatment of advanced or metastatic soft tissue sarcoma: a study by the EORTC Soft Tissue and Bone Sarcoma Group. *Eur J Cancer.* 2001; 37(7):870-7. [https://doi.org/10.1016/S0959-8049\(01\)00050-8](https://doi.org/10.1016/S0959-8049(01)00050-8)
- Toma S, Tucci A, Villani G, Carteni G, Spadini N, Palumbo R. Liposomal doxorubicin (Caelyx) in advanced pretreated soft tissue sarcomas: a phase II study of the Italian Sarcoma Group (ISG). *Anticancer Res.* 2000; 20(1B):485-91.
- Wollina U. Liposomal cancer chemotherapy in dermatology: current status and future prospects. *Indian J Dermatol.* 2004; 49(3):109-116.

## Botulin Toxin Use in Scars/Keloids Treatment

Jacopo Scala<sup>1</sup>, Aleksandra Vojvodic<sup>2</sup>, Petar Vojvodic<sup>3</sup>, Tatjana Vlaškovic-Jovicevic<sup>3</sup>, Zorica Peric-Hajzler<sup>4</sup>, Dusica Matovic<sup>4</sup>, Sanja Dimitrijevic<sup>5</sup>, Jovana Vojvodic<sup>3</sup>, Goran Sijan<sup>6</sup>, Nenad Stepic<sup>7</sup>, Uwe Wollina<sup>8</sup>, Michael Tirant<sup>1</sup>, Nguyen Van Thuong<sup>9</sup>, Massimo Fioranelli<sup>10</sup>, Torello Lotti<sup>11</sup>

<sup>1</sup>University G. Marconi, Rome, Italy; <sup>2</sup>Department of Dermatology and Venereology, Military Medical Academy, Belgrade, Serbia; <sup>3</sup>Clinic for Psychiatric Disorders "Dr. Laza Lazarevic", Belgrade, Serbia; <sup>4</sup>Military Medical Academy, Belgrade, Serbia; <sup>5</sup>Department of Gynecology, Military Medical Academy, Belgrade, Serbia; <sup>6</sup>Clinic for Plastic Surgery and Burns, Military Medical Academy, Belgrade, Serbia; <sup>7</sup>Chief of Clinic for Plastic Surgery and Burns, Military Medical Academy, Belgrade, Serbia; <sup>8</sup>Department of Dermatology and Allergology, Städtisches Klinikum Dresden, Dresden, Germany; <sup>9</sup>Vietnam National Hospital of Dermatology and Venereology, Hanoi, Vietnam; <sup>10</sup>Department of Nuclear Physics, Sub-nuclear and Radiation, G. Marconi University, Rome, Italy; <sup>11</sup>Department of Dermatology, University of G. Marconi, Rome, Italy

### Abstract

**Citation:** Scala J, Vojvodic A, Vojvodic P, Vlaškovic-Jovicevic T, Peric-Hajzler Z, Matovic D, Dimitrijevic S, Vojvodic J, Sijan G, Stepic N, Wollina U, Tirant M, Thuong NV, Fioranelli M, Lotti T. Botulin Toxin Use in Scars/Keloids Treatment. Open Access Maced J Med Sci. 2019 Sep 30; 7(18):2979-2981. <https://doi.org/10.3889/oamjms.2019.783>

**Keywords:** Botulin toxin; Scars; Keloids

**\*Correspondence:** Massimo Fioranelli, Department of Nuclear Physics, Sub-nuclear and Radiation, G. Marconi University, Rome, Italy. E-mail: [massimo.fioranelli@gmail.com](mailto:massimo.fioranelli@gmail.com)

**Received:** 12-Jun-2019; **Revised:** 06-Jul-2019; **Accepted:** 07-Jul-2019; **Online first:** 30-Aug-2019

**Copyright:** © 2019 Jacopo Scala, Aleksandra Vojvodic, Petar Vojvodic, Tatjana Vlaškovic-Jovicevic, Zorica Peric-Hajzler, Dusica Matovic, Sanja Dimitrijevic, Jovana Vojvodic, Goran Sijan, Nenad Stepic, Uwe Wollina, Michael Tirant, Nguyen Van Thuong, Massimo Fioranelli, Torello Lotti. This is an open-access article distributed under the terms of the Creative Commons Attribution-NonCommercial 4.0 International License (CC BY-NC 4.0)

**Funding:** This research did not receive any financial support

**Competing Interests:** The authors have declared that no competing interests exist

Botulinum toxin (BTX) is a neurotoxin protein derived from the *Clostridium botulinum* bacterium that inhibits the release of acetylcholine at the neuromuscular junction level whose effects has been used for many years to treat a variety of muscular/neuromuscular conditions and more recently also for cosmetic use.

BTX has experimented in some dermatological conditions which include scar prevention and treatment with good results. The complex mechanism underlying those results is not completely understood but several mechanisms were proposed: release inhibition of different substances like (TGF)- $\beta$ , substance P, calcitonin gene-related peptide (CGRP) and glutamate thus modulating cutaneous inflammation and wound healing.

We analysed the published data on BTX off label applications on scars and keloids retrieved from PubMed.

## Introduction

Botulinum toxin (BTX) is a neurotoxin protein derived from the *Clostridium botulinum* bacterium that inhibits the release of acetylcholine at the neuromuscular junction level causing temporary chemical denervation. At the synaptic level, BTX cleaves a docking protein (synaptosomal-associated protein of 25 kDa or SNAP-25) on the internal surface of neuronal membranes inhibiting vesicle fusion and thus the release of acetylcholine [1]. BTX effects are temporary and as SNAP-25 regenerates, contractility

is restored in the affected muscles after a variable time of a few months.

BTX effects have been used for many years to treat a variety of muscular/neuromuscular conditions and starting from 2002 also for cosmetic use [2].

More recently, BTX has experimented in some dermatological conditions which include scar prevention and treatment with good results [3], [4], [5]. The good results of those off label uses could be explained with the widely known interaction between skin and nervous system and is supposed that BTX

may inhibit the release of other substances like (TGF)- $\beta$ , substance P, calcitonin gene-related peptide (CGRP) and glutamate thus modulating cutaneous inflammation and wound healing [5], [6], [7].

## Material and Methods

We analysed the published data on BTX off label applications on scars and keloids retrieved from PubMed. We found 163 articles, from 2011 to April 2019 using the terms “botulin scar” and correlated MeSH terms. Of these articles, only 44 were included in this review. Exclusion criteria were: case reports, duplicated studies, papers focusing on topics not related to dermatology or plastic surgery and articles written in languages other than English.

## Results

BTX has been used to treat hypertrophic scars (HS) and keloids in a number of studies [8], [9], [10], [11], [12], [13], [14] and also was successfully used in scar prevention [14], [15], [16], [17], [18], [19], [20], [21]. Only a small number of available studies were made as randomized controlled trials with the efficacy of BTX compared to placebo (saline solution) or steroids, and those studies differ for the amount of BTX used ranging from 1.5 to 5 IU every cm<sup>2</sup> and for the frequency of treatment ranging from a single treatment to multiple treatments done every month or even with longer intervals, but all gave positive results.

Moreover, some animal studies demonstrated the usefulness of BTX in scar and keloid reduction [20], [21], [22]. Despite all differences in published studies a recent meta-analysis of randomised controlled trials evaluating BTX effect in the face/neck area has found that patients who received BTX had better outcomes than those who did not receive it [24]. According to this study the scars were significantly narrower ( $P = 0.006$ ) and visual analogue scale scores were significantly better, indicating that patients treated with BTX were more satisfied with the results than those who received saline. However, the number of studies eligible for the analysis was only 9, and only 3 of these were completely unbiased.

## Discussion

The molecular mechanism of BTX usefulness on hypertrophic scars and keloids is not yet perfectly explained but in vivo studies in animals and humans have demonstrated that, in addition to the known effects on acetylcholine release, BTX inhibits fibroblast proliferation (and hence collagen production). Also, it is reported to downregulate the expression of  $\alpha$ -smooth muscle actin and myosin II proteins, which are found in fibroblasts in a dose-dependent fashion [23]. It is important to note that these phenomena were not observed in fibroblasts isolated from normal skin [27]. Other studies indicated that, along with inhibition of fibroblast proliferation, production of transforming growth factor (TGF)- $\beta$ 1 and connective tissue growth factor were also diminished [25], [26], [27]. Unexpectedly collagen production and collagen organisation were found significantly improved with intralesional BTX than with saline in a rat model of burn healing and was associated with faster vascularisation and reepithelialisation of the wound [26].

To explain this phenomenon, it has been hypothesised that BTX may increase expression of Vascular endothelial growth factor (VEGF), and thus promote angiogenesis that hastens wound healing [29] and ultimately gave a better scar appearance, although the exact mechanism for this is not known. Results from studies investigating the effect of BTX on the expression of VEGF in scar healing are still inconsistent: some appear to demonstrate benefit, but others show no effect [28].

One particularly favourable aspect of BTX treatment is its ability to control the subjective symptoms of hypertrophic scars. We already know that BTX can immobilize the local muscles of a scar and reduce skin tension caused by the muscle pull which exacerbates inflammation and leads to overproduction of collagen and glycosaminoglycans, thus improving the cosmetic result of the scar, but also relieves trapped nerve fibers in keloids, neutralizing the itch and pain associated with small-fiber neuropathy [30], [31]. The last known effect reported of BTX treatment is related to the inhibition of inflammatory mediators release such as substance P and calcitonin gene-related peptide (CGRP) [32], [33]. The reduction and control of local skin inflammation mediated by those cytokines may allow better overall healing resulting in a less evident scar.

In conclusion, the innovative applications for BTX use in scar prevention or reduction, even if his complex mechanism is not completely understood, show very promising results. To better understand its therapeutic potential in dermatology, future studies should investigate the link between BTX and the cutaneous neuroimmune system and skin-nervous system interaction. Also, a consensus on the dose and regimen would be desirable to standardise the treatment.

## References

1. Blasi J, Chapman ER, Link E, et al. Botulinum neurotoxin A selectively cleaves the synaptic protein SNAP-25. *Nature*. 1993; 365(6442):160-163. <https://doi.org/10.1038/365160a0> PMID:8103915
2. França K, Kumar A, Fioranelli M, Lotti T, Tirant M, Rocchia MG. The history of Botulinum toxin: from poison to beauty. *Wien Med Wochenschr*. 2017; 167(1):46-48. <https://doi.org/10.1007/s10354-017-0553-7> PMID:28299552
3. França K, Castillo D, Lotti T. Non-cosmetic dermatological use of botulinum neurotoxin. *Dermatol Ther*. 2017; 30(4). <https://doi.org/10.1111/dth.12495> PMID:28425626
4. Guida S, Farnetani F, Nisticò SP, Giorgio Mariarosaria C, Babino G, Giovanni Pellacani G, Fulgione E. New trends in botulinum toxin use in dermatology. *Dermatol Pract Concept*. 2018; 8(4):277-282. <https://doi.org/10.5826/dpc.0804a05> PMID:30479855  
PMCID:PMC6246063
5. Schlessinger J, Gilbert E, Cohen JK, Kaufman J. New Uses of AbobotulinumtoxinA in Aesthetics. *Aesthet Surg J*. 2017; 37(1): S45-S58. <https://doi.org/10.1093/asi/sjx005> PMID:28388720  
PMCID:PMC5434494
6. Steinhoff M, Stander S, Seeliger S, Ansel JC, Schmeiz M, Luger T. Modern aspects of cutaneous neurogenic inflammation. *Arch. Dermatol*. 2003; 139:1479-1488. <https://doi.org/10.1001/archderm.139.11.1479>
7. Ansel JC, Kaynard AH, Armstrong CA, Olerud J, Bunnett N, Payan D. Skin-nervous system interactions. *J. Investig. Dermatol*. 1996; 106:198-204. <https://doi.org/10.1111/1523-1747.ep12330326> PMID:8592075
8. Elhefnawy AM. Assessment of intralesional injection of botulinum toxin type A injection for hypertrophic scars. *Indian J. Dermatol. Venereol. Leprol*. 2016; 82:279-283. <https://doi.org/10.4103/0378-6323.173586> PMID:27088929
9. Shaarawy E, Hegazy RA, Abdel Hay RM. Intralesional botulinum toxin type A equally effective and better tolerated than intralesional steroid in the treatment of keloids: A randomized controlled trial. *J. Cosmet. Dermatol*. 2015; 14:161-166. <https://doi.org/10.1111/jocd.12134> PMID:25810045
10. Xiao Z, Zhang F, Cui Z. Treatment of hypertrophic scars with intralesional botulinum toxin type A injections: A preliminary report. *Aesthet. Plast. Surg*. 2009; 33:409-412. <https://doi.org/10.1007/s00266-009-9334-z> PMID:19357910
11. Zhibo X, Miaobo Z. Intralesional botulinum toxin type A injection as a new treatment measure for keloids. *Plast. Reconstr. Surg*. 2009; 124:275e-277e. <https://doi.org/10.1097/PRS.0b013e3181b98ee7> PMID:20009818
12. Jablonka EM, Sherris DA, Gassner HG. Botulinum toxin to minimize facial scarring. *Facial Plast Surg*. 2012; 28(5):525-535. <https://doi.org/10.1055/s-0032-1325641> PMID:23027220
13. Gauglitz GG. Management of keloids and hypertrophic scars: current and emerging options. *Clin Cosmet Investig Dermatol*. 2013; 6:103-114. <https://doi.org/10.2147/CCID.S35252> PMID:23637546  
PMCID:PMC3639020
14. Gauglitz GG, Bureik D, Dombrowski Y, Pavicic T, Ruzicka T, Schaubert J. Botulinum toxin A for the treatment of keloids. *Skin Pharmacol Physiol*. 2012; 25(6):313-318. <https://doi.org/10.1159/000342125> PMID:22948093
15. Kim YS, Lee HJ, Cho SH, Lee JD, Kim HS. Early postoperative treatment of thyroidectomy scars using botulinum toxin: A split-scar, double-blind, randomized controlled trial. *Wound Repair Regen*. 2014; 22:605-612. <https://doi.org/10.1111/wrr.12204> PMID:24898579
16. Ziade M, Domergue S, Batifol D, Jreige R, Sebbane M, Goudot P, Yachouh J. Use of botulinum toxin type A to improve treatment of facial wounds: A prospective randomized study. *J. Plast. Reconstr. Aesthet. Surg*. 2013; 66:209-214. <https://doi.org/10.1016/j.bjps.2012.09.012> PMID:23102873
17. Gassner HG, Brissett AE, Otleigh CC, Boahene DK, Boggust AJ, Weaver AL, Sherris DA. Botulinum toxin to improve facial wound healing: A prospective, blinded, placebo-controlled study. *Mayo Clin Proc*. 2006; 81:1023-1028. <https://doi.org/10.4065/81.8.1023> PMID:16901024
18. Galárraga IM. Use of botulinum toxin in cheiloplasty: A new method to decrease tension. *Can J Plast Surg*. 2009; 17(3):e1-e2. <https://doi.org/10.1177/229255030901700313> PMID:20808741  
PMCID:PMC2740606
19. Chang CS, Wallace CG, Hsiao YC, Chang CJ, Chen PK. Botulinum toxin to improve results in cleft lip repair. *Plast Reconstr Surg*. 2014; 134(3):511-516. <https://doi.org/10.1097/PRS.0000000000000416> PMID:25158709
20. Wilson AM. Use of botulinum toxin type A to prevent widening of facial scars. *Plast. Reconstr. Surg*. 2006; 117:1758-1766. <https://doi.org/10.1097/01.prs.0000209944.45949.d1> PMID:16651948
21. Chen M, Yan T, Ma K, et al. Botulinum toxin type A inhibits  $\alpha$  smooth muscle actin and myosin II expression in fibroblasts derived from scar contracture. *Ann Plast Surg*. 2016; 77(3):e46-e49. <https://doi.org/10.1097/SAP.0000000000000268> PMID:25144422
22. Xiao Z, Qu G. Effects of botulinum toxin type a on collagen deposition in hypertrophic scars. *Molecules*. 2012; 17(2):2169-2177. <https://doi.org/10.3390/molecules17022169> PMID:22354193  
PMCID:PMC6268678
23. Jeong HS, Lee BH, Sung HM, et al. Effect of botulinum toxin type A on differentiation of fibroblasts derived from scar tissue. *Plast Reconstr Surg*. 2015; 136(2):171e-178e. <https://doi.org/10.1097/PRS.0000000000001438> PMID:26218391
24. Zhang DZ, Liu XY, Xiao WL, Xu YX. Botulinum toxin type A and the prevention of hypertrophic scars on the maxillofacial area and neck: a meta-analysis of randomized controlled trials. *PLoS One*. 2016; 11(3):e0151627. <https://doi.org/10.1371/journal.pone.0151627> PMID:26985661  
PMCID:PMC4795777
25. Xiao Z, Zhang M, Liu Y, Ren L. Botulinum toxin type a inhibits connective tissue growth factor expression in fibroblasts derived from hypertrophic scar. *Aesthetic Plast Surg*. 2011; 35(5):802-807. <https://doi.org/10.1007/s00266-011-9690-3> PMID:21455826
26. Xiao Z, Zhang F, Lin W, Zhang M, Liu Y. Effect of botulinum toxin type A on transforming growth factor beta1 in fibroblasts derived from hypertrophic scar: a preliminary report. *Aesthetic Plast Surg*. 2010; 34(4):424-427. <https://doi.org/10.1007/s00266-009-9423-z> PMID:19802513
27. Huang C, Akaishi S, Hyakusoku H, Ogawa R. Are keloid and hypertrophic scar different forms of the same disorder? A fibroproliferative skin disorder hypothesis based on keloid findings. *Int Wound J*. 2014; 11(5):517-522. <https://doi.org/10.1111/i.1742-481X.2012.01118.x> PMID:23173565
28. Haubner F, Leyh M, Ohmann E, Sadick H, Gassner HG. Effects of botulinum toxin A on patient-specific keloid fibroblasts in vitro. *Laryngoscope*. 2014; 124(6):1344-1351. <https://doi.org/10.1002/lary.24456> PMID:24122729
29. Wilgus TA, Ferreira AM, Oberyszyn TM, Bergdall VK, Dipietro LA. Regulation of scar formation by vascular endothelial growth factor. *Lab Invest*. 2008; 88(6):579-590. <https://doi.org/10.1038/labinvest.2008.36> PMID:18427552  
PMCID:PMC2810253
30. Viera, M.H.; Amini, S.; Valins, W.; Berman, B. Innovative therapies in the treatment of keloids and hypertrophic scars. *J. Clin. Aesthet. Dermatol*. 2010; 3:20-26.
31. Uyesugi B, Lippincott B, Dave S. Treatment of painful keloid with botulinum toxin type A. *Am. J. Phys. Med. Rehabil*. 2010; 89:153-155. <https://doi.org/10.1097/PHM.0b013e3181c1ec11> PMID:19884811
32. Kellogg Jr DL, Pérgola PE, Piest KL, Kosiba WA, Crandall CG, Grossmann M, Johnson JM. Cutaneous active vasodilation in humans is mediated by cholinergic nerve cotransmission. *Circ. Res*. 1995; 77:1222-1228. <https://doi.org/10.1161/01.RES.77.6.1222> PMID:7586235
33. Carmichael MM, Dostrovsky JO, Charlton MP. Peptide-mediated transdermal delivery of botulinum neurotoxin type A reduces neurogenic inflammation in the skin. *Pain*. 2010; 149:316-324. <https://doi.org/10.1016/j.pain.2010.02.024> PMID:20223589

# Dermal Pleomorphic Sarcoma of the Scalp – Report of Two Cases

Uwe Wollina<sup>1</sup>, Jacqueline Schönlebe<sup>2</sup>, Violetta Bujok<sup>1</sup>, Torello Lotti<sup>3</sup>, Georgi Tchernev<sup>4</sup>, Ivanka Temelkova<sup>4</sup>, Aleksandra Vojvodic<sup>5</sup>

<sup>1</sup>Department of Dermatology and Allergology, Städtisches Klinikum Dresden, Academic Teaching Hospital, Dresden, Germany; <sup>2</sup>Institute of Pathology “Georg Schmorl”, Städtisches Klinikum Dresden, Academic Teaching Hospital, Dresden, Germany; <sup>3</sup>Department of Dermatology, University of Rome “G. Marconi”, Rome, Italy; <sup>4</sup>Onkoderma Policlinic for Dermatology and Dermatologic Surgery, Sofia, Bulgaria; <sup>5</sup>Military Medical Academy of Belgrade, Serbia, and University of Rome Guglielmo Marconi Rome, Italy

## Abstract

**Citation:** Wollina U, Schönlebe J, Bujok V, Lotti T, Tchernev G, Temelkova I, Vojvodic A. Dermal Pleomorphic Sarcoma of the Scalp – Report of Two Cases. Open Access Maced J Med Sci. 2019 Sep 30; 7(18):2982-2984.  
<https://doi.org/10.3889/oamjms.2019.274>

**Keywords:** Cutaneous sarcomas; Atypical fibroxanthoma; Dermal pleomorphic sarcoma; Surgery

**\*Correspondence:** Uwe Wollina, Department of Dermatology and Allergology, Städtisches Klinikum Dresden, Academic Teaching Hospital, Dresden, Germany. E-mail: [Uwe.Wollina@klinikum-dresden.de](mailto:Uwe.Wollina@klinikum-dresden.de)

**Received:** 04-Apr-2019; **Revised:** 18-May-2019; **Accepted:** 19-May-2019; **Online first:** 30-May-2019

**Copyright:** © 2019 Uwe Wollina, Jacqueline Schönlebe, Violetta Bujok, Torello Lotti, Georgi Tchernev, Ivanka Temelkova, Aleksandra Vojvodic. This is an open-access article distributed under the terms of the Creative Commons Attribution-NonCommercial 4.0 International License (CC BY-NC 4.0)

**Funding:** This research did not receive any financial support

**Competing Interests:** The authors have declared that no competing interests exist

**BACKGROUND:** Neoplasias of the UV-exposed head-and-neck area of the elderly include non-melanoma skin cancers of various origin.

**CASE REPORT:** We report two cases of rapid growing exophytic scalp tumors on chronic sun-damaged skin, in one case with a tendency of bleeding. The tumours were removed by wide surgical excision with 3D margin control, and the resulting defect was covered by a meshed split skin graft. Histopathologic examination disclosed a dermal pleomorphic sarcoma in both cases. The staging was unremarkable in both patients.

**CONCLUSIONS:** Sarcomatous tumours of the scalp should be completely excised with a 3D margin control. Dermal pleomorphic sarcoma is a more aggressive variant compared to atypical fibroxanthoma despite some similarities.

## Introduction

Chronic sun-exposed skin predisposed to non-melanoma skin cancer. In the head-and-neck region, basal cell carcinoma, squamous cell carcinoma, Merkel cell carcinoma, and sarcomas have to be considered in elderly patients.

Dermal pleomorphic sarcoma (DPS) is an important differential diagnosis to atypical fibroxanthoma (AFX) [1]. Both tumour entities are predominantly seen on ultraviolet (UV)-radiation

exposed head-and-neck skin in elderly patients. They represent rapidly growing pleomorphic spindle-cellular tumours with numerous mitoses, including atypical ones. These tumours are non-encapsulated. Some authors consider AFX as a superficial variant of DPS [2], [3].

While both tumours are part of a disease spectrum, their differentiation is important in risk stratification. In contrast to AFX, which shows the metastatic spread in up to 5%, DSP develops metastasis in about 10 to 20% with up to 28% local recurrences [4], [5], [6].

## Case Report

**Case 1:** A 71-year old male patient presented with a field cancerization of his bald head. In the occipital area, there was an irregular nodular plaque. A diagnostic biopsy from elsewhere suggested a cutaneous leiomyosarcoma. He was referred for complete tumour excision. His medical records were remarkable for metabolic syndrome with diabetes mellitus type II, hyperlipidemia, hyperuricemia and arterial hypertension. A being prostate hypertrophy was known.

On examination, we observed numerous actinic keratoses on his baldness, cutis rhomboidalis nuchae and elastosis. In the centre of the occipital region, a nodular firm, a painless, skin-coloured, ill-defined plaque was observed with a diameter of approximately 1.5 cm (Figure 1).

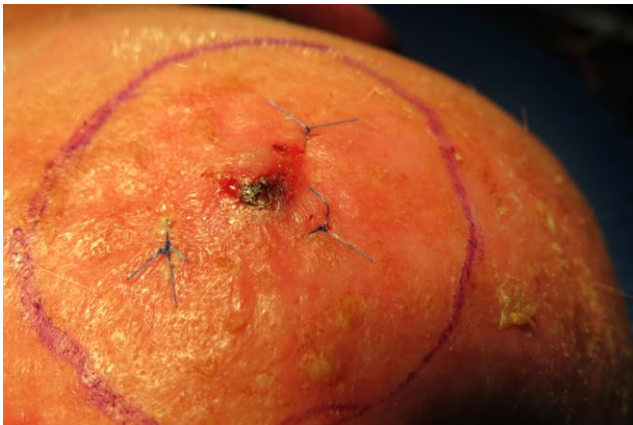

Figure 1: Dermal pleomorphic sarcoma (Case 1)

Due to the previous histological findings, we recommended a wide excision with a lateral safety margin of at least 2 cm and down to the galea in general anaesthesia and three-dimensional histologic margin control. The surgical defect measured 5 cm in diameter, which was closed by meshed graft transplantation. Wound healing was unremarkable.

Histologic examination revealed a spindle cell tumour with well-defined borders but no capsule infiltrating dermis and partially subcutaneous adipose tissue. Tumour cell was arranged in a fascicular or storiform pattern and demonstrated pronounced cellular and nuclear atypia. Locally, numerous mitoses, many atypical, could be identified. Neither lymphovascular or perineural invasion nor necrosis was evident. Tumour cells expressed CD10 and p53 strongly. Ki67 was positive in about 15% of tumour cells; smooth-muscle actin was only weakly expressed. Single cells were positive for CD68. The tumour was completely negative for pan-cytokeratin (CK), desmin and S100. Resection was R0.

The diagnosis of a DPS of the scalp was confirmed.

Tumour staging by lymph node and abdominal sonography and dual-energy X-ray of the thorax remained unremarkable. Healing was uneventful. There was no relapse within a 2-year follow-up.

**Case 2:** An 84-year-old male patient presented with a rapidly growing, exophytic and painless scalp tumour that was easily bleeding. His medical history was remarkable for hypertensive coronary heart disease with stent implantation, diabetes mellitus type II, lower leg varicosis, gonarthrosis, nodular goitre, and presbycusis.

His facial and neck skin demonstrated signs of extrinsic ageing with cutis rhomboidalis nuchae, facial telangiectasias, multiple actinic keratoses and elastosis. On examination, we observed a partially ulcerated skin tumour in the left parieto-occipital region, measuring 4 x 4 cm (Figure 2).

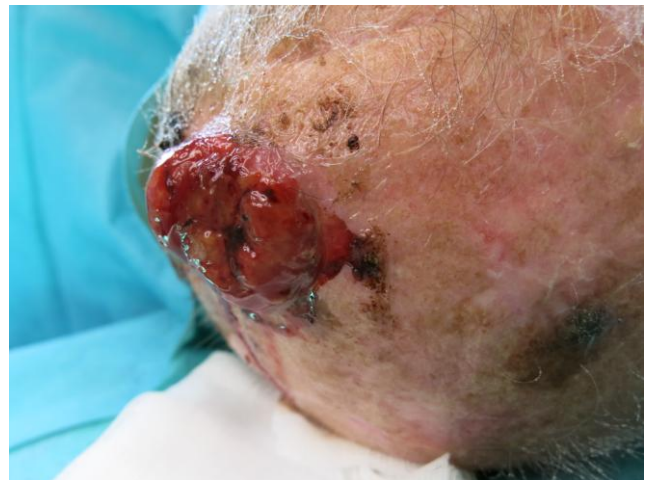

Figure 2: Dermal pleomorphic sarcoma (Case 2)

Our suspicion was either a cutaneous squamous cell carcinoma (SCC) or a Merkel cell carcinoma (MCC). We recommended wide excision with a lateral safety margin of at least 2 cm and down to the galea in general anaesthesia and three-dimensional histologic margin control. The surgical defect measured 9 x 7 cm. It was closed by meshed graft transplantation. Wound healing was unremarkable.

Histologic examination revealed an exophytic spindle cell tumour with well-defined borders but no capsule. Tumour cell was arranged in a storiform pattern and demonstrated moderate cellular and nuclear atypia. Locally, numerous mitoses, some atypical, could be identified. The tumour infiltrated the subcutaneous adipose tissue resulting in a honeycomb-like pattern. Lymphovascular and perineural invasion and tumour necrosis were absent. Tumour stroma was sparse but well vascularized with partially myxoid appearance. Tumour cells strongly expressed vimentin and CD10; a weaker expression of smooth-muscle actin was observed (Figure 3). Some cells were positive for CD68 but negative for

pan-cytokeratin (CK), CK5 and 6, CD34, and S100. Resection was R0.

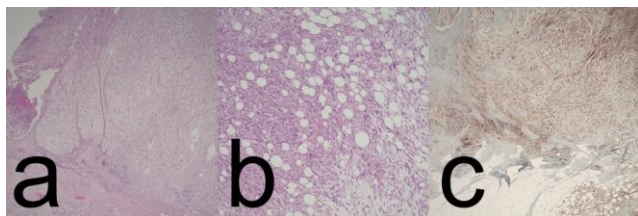


Figure 3: Histopathology of the dermal pleomorphic sarcoma (Case 2); a) Overview (hematoxylin-eosin x 2); b) Deep infiltration in the subcutaneous adipose tissue (hematoxylin-eosin x 4); c) Expression of CD10 (x 2)

The diagnosis of a DPS of the scalp was confirmed. Tumour staging by computerised tomography of the trunk and lymph node sonography did not provide any hints for a metastatic spread. The patient is in a regular follow-up.

## Discussion

AFX and DPS are sarcomatous neoplasias of the head-and-neck region of elderly patients. UV-exposure seems to be an additional risk factor for its development. Despite some similarities in clinical presentation and cell type, growth pattern, mitotic activity, they differ in depth of infiltration, invasiveness in lymphovascular and perineural structures, and prognosis [2], [3].

Comparative genomic hybridisation demonstrated similar mutation profiles in genes like *FAT1*, *NOTCH1* and 2, *CDKN2A*, *TP53* and *TERT* promoter, but activating *RAS* and *PIK3CA* mutations only in a small number of DPS [7], [8].

Risk factors for tumour recurrence are clinical tumour size larger than 5 cm and invasion beyond subcutaneous adipose tissue. Risk factors for mortality include tumour size > 2 cm, age, immunosuppression, and lymphovascular invasion [9]. Our second patient had a tumour larger than 2 cm, an age of 84 years but neither immunosuppression nor lymphovascular or perineural invasion. Treatment was surgical in both cases resulting in an R0-resection status. The staging did not demonstrate any signs of possible metastasis.

Complete excision is the treatment of choice. Whether Mohs surgery is better than wide excision is debatable, the same is true of sentinel lymph node biopsy. Nevertheless, a complete 3D-histologic margin control will reduce the risk of local recurrence. A regular follow-up of these patients is recommended [10].

In conclusion, DPS is a malignant

sarcomatous tumour of elderly patients. It represents an important differential diagnosis to other head-and-neck malignancies such as squamous cell carcinoma, basal cell carcinoma, Merkel cell carcinoma and AFX. Complete surgical excision is the treatment of choice. Tumour staging is necessary, since DPS have a risk of metastatic spread.

## References

- Mentzel T, Requena L, Brenn T. Atypical Fibroxanthoma Revisited. *Surg Pathol Clin*. 2017; 10(2):319-335. <https://doi.org/10.1016/j.path.2017.01.007> PMID:28477883
- Nonaka D, Bishop PW. Sarcoma-like tumor of head and neck skin. *Am J Surg Pathol*. 2014; 38(7):956-65. <https://doi.org/10.1097/PAS.0000000000000210> PMID:24705313
- Brenn T. Pleomorphic dermal neoplasms: a review. *Adv Anat Pathol*. 2014; 21(2):108-30. <https://doi.org/10.1097/PAP.0000000000000009> PMID:24508694
- Miller K, Goodlad JR, Brenn T. Pleomorphic dermal sarcoma: adverse histologic features predict aggressive behavior and allow distinction from atypical fibroxanthoma. *Am J Surg Pathol*. 2012; 36(9):1317-26. <https://doi.org/10.1097/PAS.0b013e31825359e1> PMID:22510760
- Wollina U, Schönlebe J, Ziemer M, Friedling F, Koch A, Haroske G, Kaatz M, Simon JC. Atypical fibroxanthoma: a series of 56 tumors and an unexplained uneven distribution of cases in southeast Germany. *Head Neck*. 2015; 37(6):829-34. <https://doi.org/10.1002/hed.23673> PMID:24946737
- Tardío JC, Pinedo F, Aramburu JA, Suárez-Massa D, Pampín A, Requena L, Santonja C. Pleomorphic dermal sarcoma: a more aggressive neoplasm than previously estimated. *J Cutan Pathol*. 2016; 43(2):101-12. <https://doi.org/10.1111/cup.12603> PMID:26264237
- Helbig D, Quaas A, Mauch C, Merkelbach-Bruse S, Büttner R, Emberger M, Wobser M, Rüsseler V, Pütz K, Binot E, Rehker J, Budczies J, Ihle MA. Copy number variations in atypical fibroxanthomas and pleomorphic dermal sarcomas. *Oncotarget*. 2017; 8(65):109457-109467. <https://doi.org/10.18632/oncotarget.22691> PMID:29312620 PMID:PMC5752533
- Koelsche C, Stichel D, Griewank KG, Schimpf D, Reuss DE, Bewerunge-Hudler M, Vokuhl C, Dinjens WNM, Petersen I, Mittelbronn M, Cuevas-Bourdier A, Buslei R, Pfister SM, Flucke U, Mechttersheimer G, Mentzel T, von Deimling A. Genome-wide methylation profiling and copy number analysis in atypical fibroxanthomas and pleomorphic dermal sarcomas indicate a similar molecular phenotype. *Clin Sarcoma Res*. 2019; 9:2. <https://doi.org/10.1186/s13569-019-0113-6> PMID:30809375 PMID:PMC6375211
- Winchester D, Lehman J, Tello T, Chimato N, Hocker T, Kim S, Chang J, Markey J, Yom SS, Ryan W, Mully T, Hodge D, Otley C, Arron ST. Undifferentiated pleomorphic sarcoma: Factors predictive of adverse outcomes. *J Am Acad Dermatol*. 2018; 79(5):853-859. <https://doi.org/10.1016/j.jaad.2018.05.022> PMID:29787841
- Soleymani T, Tyler Hollmig S. Conception and Management of a Poorly Understood Spectrum of Dermatologic Neoplasms: Atypical Fibroxanthoma, Pleomorphic Dermal Sarcoma, and Undifferentiated Pleomorphic Sarcoma. *Curr Treat Options Oncol*. 2017; 18(8):50. <https://doi.org/10.1007/s11864-017-0489-6> PMID:28762020



# Botulin Toxin Use in Rosacea and Facial Flushing Treatment

Jacopo Scala<sup>1</sup>, Aleksandra Vojvodic<sup>2</sup>, Petar Vojvodic<sup>3</sup>, Tatjana Vlaškovic-Jovicevic<sup>3</sup>, Zorica Peric-Hajzler<sup>4</sup>, Dusica Matovic<sup>4</sup>, Sanja Dimitrijevic<sup>5</sup>, Jovana Vojvodic<sup>3</sup>, Goran Sijan<sup>6</sup>, Nenad Stepic<sup>7</sup>, Uwe Wollina<sup>8</sup>, Michael Tirant<sup>1</sup>, Nguyen Van Thuong<sup>9</sup>, Massimo Fioranelli<sup>10</sup>, Torello Lotti<sup>11</sup>

<sup>1</sup>University G. Marconi, Rome, Italy; <sup>2</sup>Department of Dermatology and Venereology, Military Medical Academy, Belgrade, Serbia; <sup>3</sup>Clinic for Psychiatric Disorders "Dr. Laza Lazarevic", Belgrade, Serbia; <sup>4</sup>Military Medical Academy, Belgrade, Serbia; <sup>5</sup>Department of Gynecology, Military Medical Academy, Belgrade, Serbia; <sup>6</sup>Clinic for Plastic Surgery and Burns, Military Medical Academy, Belgrade, Serbia; <sup>7</sup>Chief of Clinic for Plastic Surgery and Burns, Military Medical Academy, Belgrade, Serbia; <sup>8</sup>Department of Dermatology and Allergology, Städtisches Klinikum Dresden, Dresden, Germany; <sup>9</sup>Vietnam National Hospital of Dermatology and Venereology, Hanoi, Vietnam; <sup>10</sup>Department of Nuclear Physics, Sub-nuclear and Radiation, G. Marconi University, Rome, Italy; <sup>11</sup>Department of Dermatology, University of G. Marconi, Rome, Italy

## Abstract

**Citation:** Scala J, Vojvodic A, Vojvodic P, Vlaškovic-Jovicevic T, Peric-Hajzler Z, Matovic D, Dimitrijevic S, Vojvodic J, Sijan O, Stepic N, Wollina U, Tirant M, Thuong NV, Fioranelli M, Lotti T. Botulin Toxin Use in Rosacea and Facial Flushing Treatment. Open Access Maced J Med Sci. 2019 Sep 30; 7(18):2985-2987. https://doi.org/10.3889/oamjms.2019.784

**Keywords:** Botulin toxin; Rosacea

**\*Correspondence:** Massimo Fioranelli, Department of Nuclear Physics, sub-nuclear and radiation, G. Marconi University, Rome, Italy. E-mail: massimo.fioranelli@gmail.com

**Received:** 12-Jun-2019; **Revised:** 06-Jul-2019; **Accepted:** 07-Jul-2019; **Online first:** 30-Aug-2019

**Copyright:** © 2019 Jacopo Scala, Aleksandra Vojvodic, Petar Vojvodic, Tatjana Vlaškovic-Jovicevic, Zorica Peric-Hajzler, Dusica Matovic, Sanja Dimitrijevic, Jovana Vojvodic, Goran Sijan, Nenad Stepic, Uwe Wollina, Michael Tirant, Nguyen Van Thuong, Massimo Fioranelli, Torello Lotti. This is an open-access article distributed under the terms of the Creative Commons Attribution-NonCommercial 4.0 International License (CC BY-NC 4.0)

**Funding:** This research did not receive any financial support

**Competing Interests:** The authors have declared that no competing interests exist

Botulinum toxin (BTX) is a neurotoxin derived from the Clostridium botulinum bacterium that inhibits the release of acetylcholine at the neuromuscular junction level whose effects has been used for many years to treat a variety of muscular/neuromuscular conditions and more recently also for cosmetic use.

BTX has experimented in some dermatological conditions, which include Rosacea and facial flushing treatment with good results. The complex mechanism underlying those results is not completely understood but was proposed a release inhibition of acetylcholine from peripheral autonomic nerves of the cutaneous vasodilatory system combined with the blockade substance P and calcitonin gene-related peptide (CGRP) thus modulating blood vessel dilatation.

We analysed the published data on BTX off label applications rosacea and flushing retrieved from PubMed.

## Introduction

Botulinum toxin (BTX) is a neurotoxin derived from the *Clostridium botulinum* bacterium that exerts its effect at the neuromuscular junction cleaving a docking protein (synaptosomal-associated protein of 25 kDa [SNAP-25]) on the internal surface of neuronal membranes, thereby inhibiting vesicle fusion and release of acetylcholine thus causing a temporary chemical denervation [1]. BTX effects in the targeted muscles diminish over time as SNAP-25 regenerates, and contractility is restored in a variable time of a few

months.

Those effects, used for many years to treat a variety of muscular/neuromuscular conditions in 2002 was also approved for cosmetic use to treat complex glabellar muscles that form frown lines first and to treat lateral orbicularis oculi muscles that form crow's feet later [2].

More recently, BTX has experimented in some dermatological conditions which include Rosacea and facial flushing treatment with good results [3], [4], [5], [6]. The good results of those off label uses could be explained with the widely known

interaction between skin and nervous system and is supposed that BTX may inhibit the release of substance P, calcitonin gene-related peptide (CGRP) and glutamate modulating cutaneous inflammation and wound healing.

## Material and Methods

We analysed the published data on BTX off label applications on rosacea and facial flushing retrieved from PubMed. We found 39 articles, from 2005 to April 2017 using the terms “botulin rosacea” and “botulin flushing” plus all correlated MeSH terms. Of these articles, only 30 were included in this review. Exclusion criteria were: duplicated studies, papers focusing on topics not related to dermatology or plastic surgery (like many papers on flushing related to Frey syndrome) and articles written in languages other than English.

## Results

BTX has been used to treat rosacea or facial flushing in a small number of studies [7], [8], [9], [10], [11], [12], [13], [14] and only one was made as randomized controlled trials with the efficacy of BTX compared to placebo (saline solution). All works, randomised and not, while all using intradermal injections, differ for the amount of BTX used ranging from 1 to 6 IU every cm<sup>2</sup> of affected skin and for the frequency of treatment ranging from a single treatment to three treatments done with different intervals, but all gave positive results.

Single-arm pilot studies involving patients with facial flushing were done and showed an improvement within a variable time ranging from 2 weeks to 3 months after a single treatment of a variable dose of BTX (from 1 to 2 IU/cm<sup>2</sup>) [9], [10], [12], [13], [14], while the only randomized controlled trial followed for 6 months 60 patients with menopausal hot flushes treated with a single injection of 6,2 IU of BTX per cm<sup>2</sup> versus 0,9% saline solution and showed a significant reduction in the mean number of menopausal hot flashes after 2 months. The effect of BTX was also investigated in 15 patients with rosacea. Treated with a single dose of 15–45 IU of BTX to face which resulted in a statistically significant of erythema grade, as compared to baseline, at 1, 2, and 3 months after treatment ( $P < 0.05$ ,  $P < 0.001$ , and  $P < 0.05$ , respectively) [9].

## Discussion

Facial flushing consists of an episode of redness often associated with a burning sensation. It can be primary or idiopathic and secondary to rosacea or hormonal stimuli like menopause; rosacea is a common inflammatory dermatosis also characterised by persistent erythema, telangiectasia, papules and pustules [15]. A possible mechanism by which BTX improves flushing and rosacea is the blockade of acetylcholine release from peripheral autonomic nerves of the cutaneous vasodilatory system [16], [17]. It is also known that BTX inhibits the release of inflammatory mediators such as substance P and calcitonin gene-related peptide (CGRP) [18] that have a relevant effect in vasodilation. The reduction of all those mediators can lead to a reduction of local skin inflammation and allow erythema to fade out relieving at the same time from pain. Reported adverse effect to BTX treatment is rare and limited to a mild headache.

In conclusion, the innovative applications for BTX use in rosacea and facial flushing treatment, even if his complex mechanism is not completely understood, suggest that intradermal BTX injections are safe and efficacious for reducing erythema and flushing in rosacea. Larger, controlled, randomised studies are warranted to determine optimal dosing and duration of the activity. Moreover, to better understand its therapeutic potential in dermatology future studies should investigate the link between BTX and the cutaneous neuroimmune system and skin-nervous system interaction. Also, a consensus on the dose and regimen would be desirable to standardise the treatment.

## References

1. Blasi J, Chapman ER, Link E, et al. Botulinum neurotoxin A selectively cleaves the synaptic protein SNAP-25. *Nature*. 1993; 365(6442):160-163. <https://doi.org/10.1038/365160a0> PMID:8103915
2. França K, Kumar A, Fioranelli M, Lotti T, Tirant M, Rocca MG. The history of Botulinum toxin: from poison to beauty. *Wien Med Wochenschr*. 2017; 167(1):46-48. <https://doi.org/10.1007/s10354-017-0553-7> PMID:28299552
3. França K, Castillo D, Lotti T. Non-cosmetic dermatological use of botulinum neurotoxin. *Dermatol Ther*. 2017; 30(4). <https://doi.org/10.1111/dth.12495> PMID:28425626
4. Guida S, Farnetani F, Nisticò SP, Giorgio Mariarosaria C, Babino G, Giovanni Pellacani G, Fulgione E. New trends in botulinum toxin use in dermatology. *Dermatol Pract Concept*. 2018; 8(4):277-282. <https://doi.org/10.5826/dpc.0804a05> PMID:30479855 PMID:PMC6246063
5. Kim YS, Hong ES, Kim HS. Botulinum Toxin in the Field of Dermatology: Novel Indications. *Toxins (Basel)*. 2017; 9(12):E403. <https://doi.org/10.3390/toxins9120403> PMID:29258169 PMID:PMC5744123

6. Schlessinger J, Gilbert E, Cohen JL, Kaufman J. New Uses of AbobotulinumtoxinA in Aesthetics. *Aesthet Surg J*. 2017; 37(1):S45-S58. <https://doi.org/10.1093/asi/sjx005> PMID:28388720  
PMCID:PMC5434494
7. Abokwidir M, Feldman SR. Rosacea management. *Skin Append- age Disord*. 2016; 2(1-2):26-34. <https://doi.org/10.1159/000446215> PMID:27843919  
PMCID:PMC5096126
8. Weinkle AP, Doktor V, Emer J. Update on the management of rosacea. *Clin Cosmet Investig Dermatol*. 2015; 8:159-177. <https://doi.org/10.1097/PSN.0000000000000111>  
PMCID:PMC4396587
9. Bloom BS, Payongayong L, Mourin A, Goldberg DJ. Impact of intradermal abobotulinumtoxinA on facial erythema of rosacea. *Dermatol Surg*. 2015; 41(1):S9-16. <https://doi.org/10.1097/DSS.0000000000000277> PMID:25548852
10. Geddoa, E.; Matar, H.E.; Paes, T.R. The use of botulinum toxin-a in the management of neck and anterior chest wall flushing: Pilot study. *Int. J. Dermatol*. 2013; 52:1547-1550. <https://doi.org/10.1111/ijd.12200> PMID:23968244
11. Odo ME, Odo LM, Farias RV, Primavera RA, Leao L, Cuce LC, Juliano Y. Botulinum toxin for the treatment of menopausal hot flushes: A pilot study. *Dermatol. Surg*. 2011; 37:1579-1583. <https://doi.org/10.1111/j.1524-4725.2011.02109.x> PMID:21790852
12. Eshghi G, Khezrian L, Alirezaei P. Botulinumtoxin A in treatment of facial flushing. *Acta Med Iran*. 2016; 54(7):454-457.
13. Dayan SH, Pritzker RN, Arkins JP. A new treatment regimen for rosacea: onabotulinumtoxinA. *J Drugs Dermatol*. 2012; 11(12):e76-e79.
14. Park KY, Hyun MY, Jeong SY, Kim BJ, Kim MN, Hong CK. Botulinum toxin for the treatment of refractory erythema and flushing of rosacea. *Dermatology*. 2015; 230(4):299-301. <https://doi.org/10.1159/000368773> PMID:25765295
15. Clatici VG, Satolli F, Tatu AL, Voicu C, Draganita AMV, Lotti T. Butterfly Effect - the Concept and the Implications in Dermatology, Acne, and Rosacea. *Maedica (Buchar)*. 2018; 13(2):89-94.
16. Kellogg Jr DL. In vivo mechanisms of cutaneous vasodilation and vasoconstriction in humans during thermoregulatory challenges. *J. Appl. Phys*. 2006; 100:1709-1718. <https://doi.org/10.1152/jappphysiol.01071.2005> PMID:16614368
17. Kellogg Jr DL, Pergola PE, Piest KL, Kosiba WA, Crandall M, Johnson JM. Cutaneous active vasodilation in humans is mediated by cholinergic nerve cotransmission. *Circ. Res*. 1995; 77:1222-1228. <https://doi.org/10.1161/01.RES.77.6.1222> PMID:7586235
18. Carmichael NM, Dostrovsky JO, Charlton MP. Peptide-mediated transdermal delivery of botulinum neurotoxin type A reduces neurogenic inflammation in the skin. *PAIN®*. 2010; 149(2):316-24. <https://doi.org/10.1016/j.pain.2010.02.024> PMID:20223589
19. Steinhoff M, Ständer S, Seeliger S, Ansel JC, Schmelz M, Luger T. Modern aspects of cutaneous neurogenic inflammation. *Archives of dermatology*. 2003; 139(11):1479-88. <https://doi.org/10.1001/archderm.139.11.1479> PMID:14623709
20. Ansel JC, Kaynard AH, Armstrong CA, Olerud J, Bunnett N, Payan D. Skin-nervous system interactions. *J. Investig. Dermatol*. 1996; 106:198-204. <https://doi.org/10.1111/1523-1747.ep12330326> PMID:8592075

## A Painful Step - Pendulating Plantar Eccrine Poroma

Uwe Wollina<sup>1\*</sup>, Gesina Hansel<sup>1</sup>, Jacqueline Schönlebe<sup>2</sup>, Ivanka Temelkova<sup>3</sup>, Georgi Tchernev<sup>3</sup>, Aleksandra Vojvodic<sup>4,5</sup>, Torello Lotti<sup>5</sup>, Michael Tirant<sup>5</sup>

<sup>1</sup>Department of Dermatology and Allergology, Städtisches Klinikum Dresden, Academic Teaching Hospital, Dresden, Germany; <sup>2</sup>Institute of Pathology "Georg Schmorl", Städtisches Klinikum Dresden, Academic Teaching Hospital, Dresden, Germany; <sup>3</sup>Onkoderma, Policlinic for Dermatology and Dermatologic Surgery, Sofia, Bulgaria; <sup>4</sup>Military Medical Academy of Belgrade, Belgrade, Serbia; <sup>5</sup>Department of Dermatology, University of Rome "G. Marconi", Rome, Italy

### Abstract

**Citation:** Wollina U, Hansel G, Schönlebe J, Temelkova I, Tchernev G, Vojvodic A, Lotti T, Tirant M. A Painful Step - Pendulating Plantar Eccrine Poroma. Open Access Maced J Med Sci. 2019 Sep 30; 7(18):2988-2990. <https://doi.org/10.3889/oamjms.2019.464>

**Keywords:** Eccrine poroma; Adnexal skin tumours; Porocarcinoma; Histology; Surgery; Foot

**\*Correspondence:** Uwe Wollina, Department of Dermatology and Allergology, Städtisches Klinikum Dresden, Academic Teaching Hospital, Dresden, Germany. E-mail: [Uwe.Wollina@klinikum-dresden.de](mailto:Uwe.Wollina@klinikum-dresden.de)

**Received:** 05-Apr-2019; **Revised:** 18-May-2019; **Accepted:** 19-May-2019; **Online first:** 31-May-2019

**Copyright:** © 2019 Uwe Wollina, Gesina Hansel, Jacqueline Schönlebe, Ivanka Temelkova, Georgi Tchernev, Aleksandra Vojvodic, Torello Lotti, Michael Tirant. This is an open-access article distributed under the terms of the Creative Commons Attribution-NonCommercial 4.0 International License (CC BY-NC 4.0)

**Funding:** This research did not receive any financial support

**Competing Interests:** The authors have declared that no competing interests exist

**BACKGROUND:** Eccrine poroma is a benign tumour of eccrine duct epithelium. The usual clinical presentation is nodular.

**CASE REPORT:** We present a 78-year-old man with a painful pendulating flesh-coloured malodorous plantar tumour. Differential diagnoses included telangiectatic granuloma, acrochordon, basal cell or squamous cell carcinoma, cylindroma, amelanotic melanoma, and verruca. Microbiological investigations identified numerous bacteria including *Corynebacterium striatum*, *Streptococcus dysgalactiae*, *Staphylococcus aureus*, *Citrobacter koseri*. We performed surgery since the tumour hampered his mobility. Histopathology revealed a well-circumscribed tumour composed of cuboidal cells with eosinophilic cytoplasm. Healing was unremarkable.

**CONCLUSIONS:** Pendulating plantar eccrine poroma is a rare clinical presentation of this benign adnexal tumour. Often asymptomatic, in some cases the tumour may become painful. Because of the bacterial colonisation, it could lead to deep soft tissue infections. Malignant transformation is possible. Surgical removal is the treatment of choice.

### Introduction

Eccrine poroma is a benign adnexal tumour of the skin. It originated from the sweat duct epithelium. The first description came from Hermann Pinkus et al., in 1956 [1]. The typical clinical presentation is a dome-shaped nodule or plaque, often flesh-coloured by sometimes pigmented. It occurs most commonly on hand and feet. The typical poroma is a slow-growing, asymptomatic lesion [2].

Histologically, it is composed of poroid or cuboidal cells and is well circumscribed. The solid tumour masses correspond to each other by anastomoses creating an epithelial network. In contrast to basal cell carcinoma, no palisading occurs

in the periphery. Tumours may be intraepidermal or dermal. Their cytoplasm is periodic acid-Schiff-positive. Mitoses may occur. Ductal differentiation occurs to a variable degree. The tumour stroma is highly vascularized.

There are several subtypes like poromatosis, linear eccrine poroma or porokeratotic eccrine ostial and dermal duct nevus, among others [3]. About 18% of poromas may transform into malignant porocarcinoma [4]. This is accompanied by harbouring ultraviolet light-induced mutations in TP53 and other tumour suppressor genes [5].

Eccrine poromas are uncommon tumours. Exophytic, pendulating poroma is very unusual.

## Case Report

A 78-year-old man presented with a plantar tumour because of painful steps. He was otherwise healthy.

On examination, we observed a malodorous pendulating, flesh-coloured tumour on the right foot. The plantar lesion measured 2.5 x 2 cm with a basis of 5 mm (Figure 1).

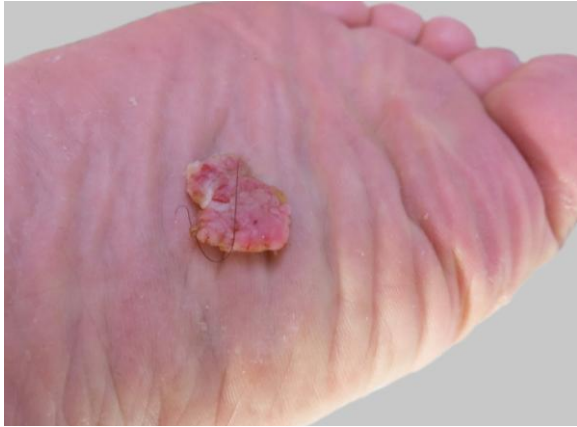

Figure 1: Pendulating tumour on the sole – eccrine poroma

Laboratory: Erythrocytes 4.42 (4.6-6.2 Tpt/l), MCV 104.8 (80-96 fl), MCH 2.13 (1.75-2.05 mmol/l), myelocytes 1%, lymphocytes 19% (25-45%), lactate dehydrogenase 3.84 (2.35-3.75  $\mu$ kat/l).

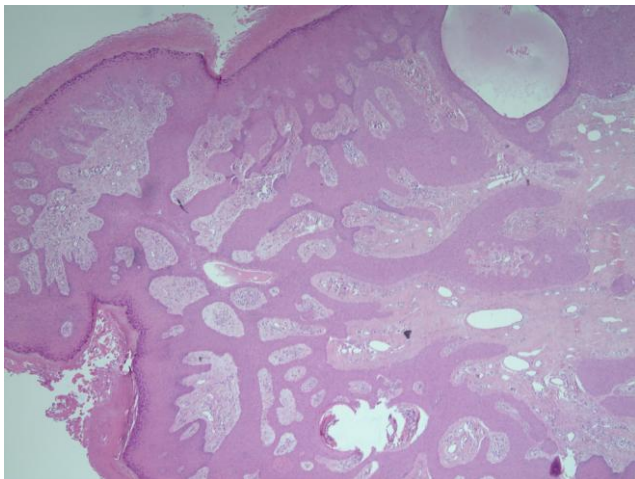


Figure 2: Histopathology of eccrine poroma with solid tumor formations composed of monomorphic cells, well circumscribed (HE x2)

Microbiology from the tumour: *Corynebacterium striatum*, *Streptococcus dysgalactiae*, *Staphylococcus aureus*, *Citrobacter koseri*.

Imaging: Diagnostic ultrasound from abdomen and groins revealed a 16 mm large lymph node with the preserved structure in his right groin.

Histology: A well-circumscribed polypoid exophytic tumour was seen, which was composed of monomorphic cuboidal cells with ductal differentiation and well vascularized fibrous stroma: no cellular atypia, no atypical mitoses (Figure 2).

The diagnosis of an eccrine poroma was made.

The tumour was removed surgically in local anaesthesia. Healing was unremarkable, and the patient became pain-free (Figure 3). The malodor was completely eradicated.

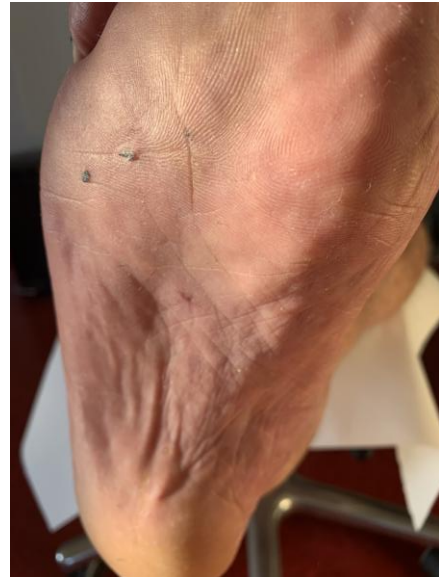

Figure 3: Complete healing after R0 surgery

## Discussion

Eccrine poroma is a benign adnexal tumour commonly but exclusively seen on hand and feet [6]. The clinical presentation as a pendulating polypoid lesion is very unusual. This raised a variety of potential differential diagnoses such as teleangiectatic granuloma, achrochordon, basal cell or squamous cell carcinoma, cylindroma, amelanotic melanoma, and verruca [2]. Histology provided the clue and confirmed an eccrine poroma.

On immunohistochemistry, we could demonstrate earlier that poromas disclosed some scattered S100-positive dendritic cells, red-stained cells in Lapham's method, and several silver-impregnated dendritic cells. The labelling with wide spectrum keratin antiserum was low compared to epidermal keratinocytes. Calmodulin known from eccrine sweat gland ducts could be found in poromas. In contrast, malignant porocarcinomas expressed a greater variety of cellular markers than benign poromas but failed to stain for calmodulin. The differentiation of both tumours, however, was directed toward inner duct cells and myoepithelium. Since

myoepithelial cells are missing in normal acrosyringium, poromas and porocarcinomas are thought to be sweat gland tumours related to the distal portion of the dermal duct [7], [8].

The malodor was related to bacterial contamination of the lesion by *Corynebacterium striatum*, *Streptococcus dysgalactiae*, *Staphylococcus aureus*, *Citrobacter koseri*. This is not only unpleasant but bears the risk of deep soft tissue infection [9]. Complete excision is the treatment of choice for poroma to prevent malignant transformation and deep soft tissue infections.

In conclusion, eccrine poroma of the sole is not uncommon, but pendulating tumours are extremely rare. They can be painful and possess a risk for deep soft tissue infections. Complete excision is the treatment of choice.

## References

1. Pinkus H, Rogin J, Goldman P. Eccrine poroma. Arch Derm. 1956; 74(5):511-21. <https://doi.org/10.1001/archderm.1956.01550110055013>
2. Sawaya JL, Khachemoune A. Poroma: a review of eccrine, apocrine, and malignant forms. Int J Dermatol. 2014; 53(9):1053-61. <https://doi.org/10.1111/ijd.12448> PMID:24697501
3. Hashimoto K, Mehregan AH, Kumakiri M. Tumors of skin appendages. Oxford Univ Pr; 1987.
4. Robson A, Greene J, Ansari N, Kim B, Seed PT, McKee PH, Calonje E. Eccrine porocarcinoma (malignant eccrine poroma): a clinicopathologic study of 69 cases. Am J Surg Pathol. 2001; 25(6):710-20. <https://doi.org/10.1097/0000478-200106000-00002> PMID:11395548
5. Botic M, Kirchner M, Brasanac D, Leichsenring J, Lier A, Volckmar AL, Oliveira C, Buchhalter I, Stögbauer F, Zivkovic-Perisic S, Goepfert B, Schirmacher P, Penzel R, Endris V, Stenzinger A. Targeted molecular profiling reveals genetic heterogeneity of poromas and porocarcinomas. Pathology. 2018; 50(3):327-332. <https://doi.org/10.1016/j.pathol.2017.10.011> PMID:29269125
6. Wong MW, Tse GM. Eccrine poroma: a differential diagnosis in chronic foot lesions. Foot Ankle Int. 2003; 24(10):789-92. <https://doi.org/10.1177/107110070302401010> PMID:14587995
7. Wollina U, Castelli E, Rülke D. Immunohistochemistry of eccrine poroma and porocarcinoma--more than acrosyringial tumors? Recent Results Cancer Res. 1995; 139:303-16. [https://doi.org/10.1007/978-3-642-78771-3\\_23](https://doi.org/10.1007/978-3-642-78771-3_23) PMID:7541147
8. Schaarschmidt H, Wollina U. Immunohistochemical detection of calmodulin. A contribution to the histogenetic classification of eccrine poroma and clear cell acanthoma. Dermatol Monatsschr. 1990; 176(5-6):363-70.
9. Wollina U, Langner D, Heinig B, Schönlebe J, Nowak A. Complicated Skin and Skin Structure Infection After Erysipelas: Urgent Need for Antibiosis and Surgery. Int J Low Extrem Wounds. 2016; 15(1):68-70. <https://doi.org/10.1177/1534734616628372> PMID:26933116

# New System Delivering Microwaves Energy for Inducing Subcutaneous Fat Reduction: In - Vivo Histological and Ultrastructural Evidence

Nicola Zerbinati<sup>1</sup>, Edoardo d'Este<sup>2</sup>, Antonia Icaro Cornaglia<sup>3</sup>, Federica Riva<sup>3</sup>, Aurora Farina<sup>3</sup>, Alberto Calligaro<sup>3</sup>, Giovanni Gallo<sup>4</sup>, Emanuele Rosario Perrotta<sup>5</sup>, Marina Protasoni<sup>1</sup>, Paolo Bonan<sup>6</sup>, Aleksandra Vojvodic<sup>7</sup>, Massimo Fioranelli<sup>8\*</sup>, Nguyen Van Thuong<sup>9</sup>, Torello Lotti<sup>10</sup>, Michael Tirant<sup>11</sup>, Petar Vojvodic<sup>12</sup>

<sup>1</sup>Department of Medicine and Surgery School of Medicine, University of Insubria (Varese), Italy; <sup>2</sup>Centro Medico Polispecialistico, Pavia, Italy; <sup>3</sup>Department of Public Health, Experimental and Forensic Medicine, Unit of Histology and Embryology, University of Pavia, Pavia, Italy; <sup>4</sup>Laser Unit of Medi-Este-Laser Center, Canicatti, Italy; <sup>5</sup>Department of General Surgery and Surgical Medical Specialties, Hospital Cannizzaro, Catania, Italy; <sup>6</sup>Laser Cutaneous Cosmetic & Plastic Surgery Unit, Villa Donatello Clinic, Florence, Italy; <sup>7</sup>Department of Dermatology and Venereology, Military Medical Academy, Belgrade, Serbia; <sup>8</sup>Department of Nuclear Physics, Sub-nuclear and Radiation, G. Marconi University, Rome, Italy; <sup>9</sup>Director of National Hospital of Dermatology and Venereology Vietnam, Head of Dermatology and Venereology Faculty, Hanoi Medical University, Hanoi, Vietnam; <sup>10</sup>Department of Dermatology, University Guglielmo Marconi, Rome, Italy; <sup>11</sup>University Guglielmo Marconi, Rome, Italy; <sup>12</sup>Clinic for Psychiatric Disorders "Dr. Laza Lazarevic", Belgrade, Serbia

## Abstract

**Citation:** Zerbinati N, d'Este E, Cornaglia AI, Riva F, Farina A, Calligaro A, Gallo G, Perrotta ER, Protasoni M, Bonan P, Vojvodic A, Fioranelli M, Van Thuong N, Lotti T, Tirant M, Vojvodic P. New System Delivering Microwaves Energy for Inducing Subcutaneous Fat Reduction: In - Vivo Histological and Ultrastructural Evidence. Open Access Maced J Med Sci. 2019 Sep 30; 7(18):2991-2997. <https://doi.org/10.3889/oamjms.2019.778>

**Keywords:** Microwaves; Subcutaneous; Fat; Fat reduction

**\*Correspondence:** Massimo Fioranelli, Department of Nuclear Physics, Sub-nuclear and Radiation, G. Marconi University, Rome, Italy. E-mail: [massimo.fioranelli@gmail.com](mailto:massimo.fioranelli@gmail.com)

**Received:** 12-Jun-2019; **Revised:** 04-Jul-2019; **Accepted:** 05-Jul-2019; **Online first:** 30-Aug-2019

**Copyright:** © 2019 Nicola Zerbinati, Edoardo d'Este, Antonia Icaro Cornaglia, Federica Riva, Aurora Farina, Alberto Calligaro, Giovanni Gallo, Emanuele Rosario Perrotta, Marina Protasoni, Paolo Bonan, Aleksandra Vojvodic, Massimo Fioranelli, Nguyen Van Thuong, Torello Lotti, Michael Tirant, Petar Vojvodic. This is an open-access article distributed under the terms of the Creative Commons Attribution-NonCommercial 4.0 International License (CC BY-NC 4.0)

**Funding:** This research did not receive any financial support

**Competing Interests:** The authors have declared that no competing interests exist

**BACKGROUND:** Recently, it has been developed a new technology for the reduction of subcutaneous adipose tissue through a non-invasive treatment by microwaves. The main objective of the present study is to demonstrate the feasibility of utilising a non-invasive, localised microwaves (MW) device to induce thermal modifications into subcutaneous adipose tissue only by a controlled electromagnetic field that heats up fat preferentially. This device is provided with a special handpiece appropriately cooled, directly contacting the cutaneous surface of the body, which provides a calibrated energy transfer by microwaves.

**AIM:** In this paper, microscopic and ultrastructural modifications of subcutaneous adipose tissue induced by microwaves irradiation are evaluated.

**METHODS:** Our experimental plan was designed for collecting biopsy samples, for each skin region treated with a single irradiation session, 1) before treatment (control), 2) immediately after treatment, 3) after 6 hrs, 4) after 1 month, 5) after 2 months. Bioptic samples from each step were processed for light microscopy and transmission electron microscopy. At the same time, each region where biopsies were collected was subjected to ultrasound examination. Recorded images permitted to evaluate the thickness of different layers as epidermis, dermis, hypodermis, connective fasciae, until to muscle layer, and related modifications induced by treatment.

**RESULTS:** In every biopsy collected at different time-steps, epidermis and superficial dermis appeared not modified compared to control. Differently, already in the short-term biopsies, in the deep dermis and superficial hypodermis, fibrillar connective tissue appeared modified, showing reduction and fragmentation of interlobular collagen septa. The most important adipose tissue modifications were detectable following 1 month from treatment, with a significant reduction of subcutaneous fat, participating both the lysis of many adipocytes and the related phagocytic action of monocytes/macrophages on residuals of compromised structures of adipocytes. In the samples collected two months following treatment, the remnants of adipose tissue appeared normal, and macrophages were completely absent.

**CONCLUSIONS:** Ultrasound, microscopic and ultrastructural evidence are supporting significant effectiveness of the new device treatment in the reduction of subcutaneous fat. In this paper, the possible mechanisms involved in the activation of the monocytes/macrophages system responsible for the removal of adipocytes residuals have also been discussed.

## Introduction

The trafficking of fatty acids into and out of adipocytes is a physiological mechanism regulated by

a complex series of proteins and enzymes and is under control by a variety of hormonal and metabolic factors (Thompson 2011) [1]. Many Authors have presented theoretical and experimental papers using methods and devices with as objective the reduction of adipose tissue. Particular interesting a recent paper

(Asan 2017) [2] in which it has been considered the properties of some tissues related to the absorption of microwaves energy in different models using equivalent phantom and ex-vivo measurements. The most of experimental evaluations available in the literature, related to fat reduction, have been performed *in vitro* conditions, which only in few cases could represent what and how happens *in vivo*, in the complex dynamics inside tissues and organs in the individuals. In this paper, we present morphological observations on the subcutaneous adipose tissue following microwaves irradiation of the skin.

A controlled electromagnetic field @2,45 GHz, perpendicularly applied to the skin, is selectively absorbed by the subdermal fat layer thanks to the dielectric properties of the different tissues (epidermis, dermis, fat) crossed by the applied EMF. The high-controlled emission of the EMF can establish a perfect coupling only in the presence of a fat layer, due to the absorption characteristics of this tissue at the established frequency.

In the present *in-vivo* study on an animal model, 7 minutes thermal exposure to 50°C, histological and ultrastructural evidences show conservation without damage to the epidermis and dermis layers, while the subdermal fat is modified through a series of molecular processes stimulating a massive delivery of fat droplets and the beginning of “auto-adipolysis”.

## Material and Methods

A mathematical model was used to correlate the frequency of the electromagnetic field and the dielectric properties of the tissues to induce localised hyperthermia only in the subcutaneous fat layer. The non-invasive pseudo-transcutaneous electromagnetic field (Coolwaves™ by Onda, DEKA, Florence, Italy) was applied to thermally induce adipocytes' damage. During the treatment, applying a transmitting handpiece on the surface of the skin, the electromagnetic field energy was delivered into the subcutaneous adipose tissue (SAT) of a Vietnamese pig (this study on the animal model was carried out in full compliance with international guidelines for safety and compliance with their use) with a 50.000 J total dose delivered in 7 minutes over a cutaneous area 15 x 15 cm<sup>2</sup>. The handpiece used was maintained at a temperature of 5°C through a specific cooling system.

The experimental plan was designed on the basis of a single irradiation session, and for each skin region treated, biopsy samples were collected and processed for light and electron microscopy, owing to the following steps: T0 (before treatment, as control), T1 (immediately after treatment), T2 (6h following treatment), T3 (1 month following treatment) and T4 (2

months following treatment).

Temperature monitoring was performed superficially by the thermometric infrared camera vision system and internally, in the subdermal fat layer (at 7mm depth), by sterile thermometric glass fibre. The epidermal temperature in the treated area was always observed in a safety-range of 15-25°C, while at 4 to 7 mm in depth was of 50°C (Figure 1A and 1B).

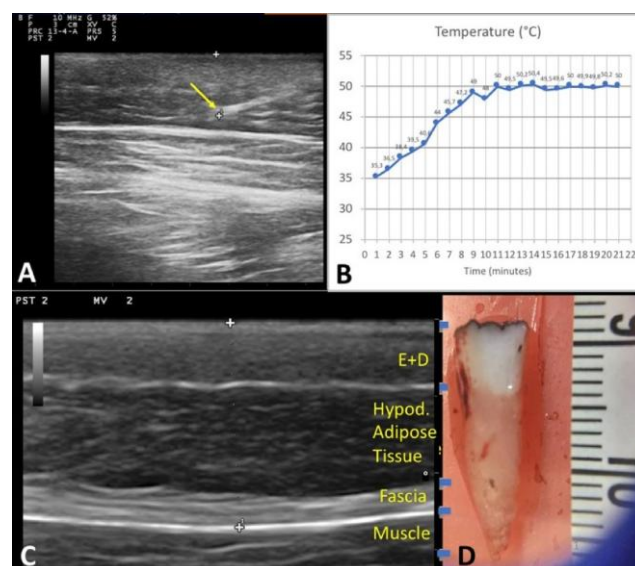


Figure 1: A and B are showing the tip of the temperature probe (arrow) by ultrasound A) and the temperature measured inside the hypodermal layer B) respectively; C) and D) correlation of ultrasound image C) and biopsy sample D) tissue layers; The different layers are clearly identifiable: Epidermis and Dermis (E + D), Subcutis (Hypodermal Adipose Tissue), Fascia, Muscle

In each time step, biopsy samples were collected, immediately immersed in the fixative solutions and processed both for light microscopy and transmission electron microscopy.

### Light microscopy

Biopsy samples were immediately immersed in a 4% paraformaldehyde/sodium phosphate buffer solution for 24 hrs and then processed (dehydration, paraffin embedding and sectioning) for light microscopy. Sections were stained with Haematoxylin and Eosin, and other sections were stained with Picrosirius Red for collagen staining.

### Electron microscopy

Fixation was performed by immersion of biopsy samples in a 2.5% glutaraldehyde (EM grade)-2% paraformaldehyde in 0.1M sodium cacodylate buffer solution (pH 7.3) for 6 hours at 4°C. After washing in the same buffer, samples were post-fixed for 2 h in osmium tetroxide 1.33% in 0.1 M s-collidine buffer, dehydrated in a graded series of ethanol (30%, 50%, 70%, 80%, 95%, 100%), propylene oxide and finally embedded in epoxy resin Epon 812. Semithin



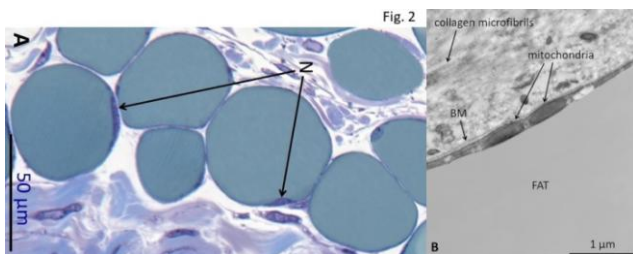
(0.2  $\mu\text{m}$ ) and ultrathin (40-60 nm) sections were obtained at the ultramicrotome Reichert Ultracut S provided with a diamond knife. Semithin sections were stained with Toluidine blue and ultrathin sections, previously collected on 200  $\mu\text{m}$  mesh copper grids, were counterstained with lead citrate and uranyl acetate. A Zeiss EM 902 transmission electron microscope, operating at 80 kV with an objective aperture of 30 / 60  $\mu\text{m}$ , was used for direct observation. Electron micrographs were recorded on Kodak 4489 Electron Image film and finally digitised with an Epson Perfection V750 Pro scanner at 1200 dpi.

## Results

The description of our observations will follow the time sequence of samples collection, using the most suitable presentation of our findings to better understand the functional dynamics.

Before sample collection, it has been used ultrasound imaging to define the thickness of the different structural layers, particularly the depth and extension of the subcutaneous tissue as the target of the microwave energy transfer (Figure 1C) and compare it with biopsy sample (Figure 1D).

At time T0, defining the control samples collected before the treatment, microscopic morphology of adipocytes appeared normal, spherical in shape, with the whole volume of cells appearing filled with a homogeneous content, surrounded by a very thin layer of peripheral cytoplasm, where an elongated and flattened nucleus was well identifiable (Figure 2A). All around adipocytes and between them, a loose connective tissue was appreciable, with some cells (fibroblasts) and an extracellular matrix constituted by collagen fibrils relatively dispersed inside a faint ground substance (Figure 2A).

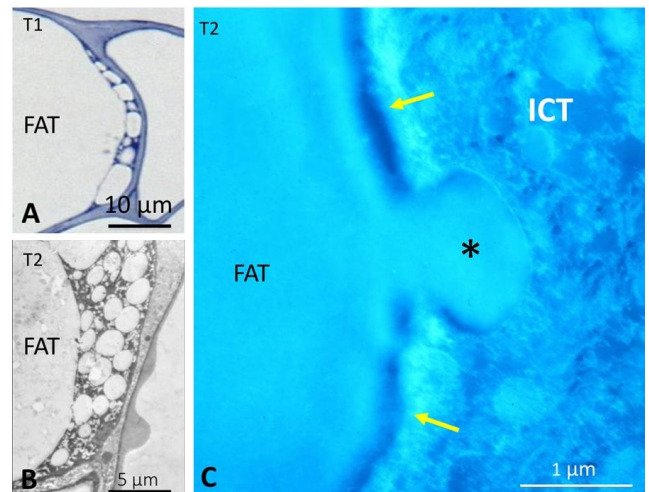


**Figure 2:** T0 (Control); A) Semithin section at the light microscope from epoxy resin embedding, stained with toluidine blue. Adipocytes show peripheral nucleus (N) with dispersed chromatin, a very thin peripheral layer of cytoplasm, and a homogeneous lipidic content. Around them, elongated fibroblasts and bundles of collagen fibres are also observable; B) Ultrastructure of the very thin peripheral cytoplasmic of an adipocyte and inside it two elongated mitochondria were observable. A continuous basal lamina close to the plasma membrane and collagen microfibrils in the surrounding connective tissue is also visible. The homogeneous fat is constituting the inner content of the adipocyte

Small blood vessels were also identifiable. At the electron microscope (Figure 2B), the very thin peripheral cytoplasm appeared to contain dispersed organelles, as mitochondria, rare profiles of the endoplasmic reticulum and small vesicles involved realistically in the physiological transport of materials (lipids included), responsible of the correct homeostatic processes across the cytoplasm to and from the interstitial connective tissue.

At time T1 (immediately the following treatment), small single or multiple vesicles were visible at the light microscope in the peripheral cytoplasm of adipocytes (Figure 3A).

At time T2 (6 hrs after treatment), many vesicles containing material very similar to the big lipidic content of the adipocyte were detectable inside adipocyte peripheral cytoplasm. In ultrathin sections observed at the electron microscope, the whole peripheral cytoplasm was completely occupied by vesicles containing a relatively electron transparent material. This feature appears particularly evident in the oblique sections of the inner surface of the peripheral cytoplasm as a holey structure (Figure 3B). In a relatively thick section at the electron microscope, we observed blebbing structures at the surface of adipocytes (Figure 3C) projecting part of their lipidic content towards the interstitial connective tissue.



**Figure 3:** T1, T2, T3; A) T1 (immediately the following treatment): Semithin section at the light microscope from epoxy resin embedding, stained with toluidine blue. Inside the thin peripheral cytoplasm of adipocytes, some vesicles with the content similar to the big lipid content of cells are visible; B) T2 (6 hrs following treatment): at the electron microscope the peripheral cytoplasm of adipocytes shows numerous vesicles occupying the whole thickness of the cytoplasm. In the oblique sections, the internal cytoplasmic surface appears fully of vesicles; C) T3 (6 hrs following treatment): the high magnification at the electron microscope represents the superficial blebbing as a direct extrusion of a lipid droplet (asterisk) through peripheral cytoplasm from the inside of an adipocyte (left) to the outside, in the interstitial connective tissue (ICT). Arrows mark the thin peripheral cytoplasm of the adipocyte

Further, some cytological details of adipocytes involved in these mechanisms, have been observed at the electron microscope, as mitochondrial

swelling with few disorganised cristae and interruptions of the inner membrane, interruptions of the plasma membrane, dilations of the endoplasmic reticulum (data not shown). The whole of these features suggests adipolysis via necrotic processes.

At time T3 (1 month after treatment), observing transverse sections of the wall of adipocytes, numerous vesicles were evident inside an electron-dense cytoplasm. Some of them appeared as invaginations of the inner side of the peripheral cytoplasm with a content continuous with the big lipidic sphere of the adipocyte; others appeared as openings towards the interstitial connective tissue. These features are suggesting a mechanism of endo-exo-cytosis of lipids from the inside of the adipocyte to the outside towards the interstitial connective tissue. At time T3, in some areas of the biopsies an inflammatory infiltrate was detectable. This infiltrate appeared constituted by numerous cells penetrating the interstitial tissue, singularly or grouped encircling single adipocytes (Figure 4A).

The infiltrate is constituted mainly by monocytes distributing free in the interstitial connective tissue or close contact with adipocytes, covering their external surface. Single monocytes appeared provided with cytoplasmic processes projecting free in the interstitial connective tissue or directly contacting free vesicles released by adipocytes. The first contact of monocytes with lipids released by necrotic adipocytes is realistically suggested by a direct contact representing the result of the "find me" action of the extracellular lipid structures towards monocytes and the starting of the mechanism "eat me" stimulating the phagocytic action of macrophages. The following step in the mechanism of adipolysis observed at the same time T3 (after 1 month from treatment) is represented by the formation of Crown-Like-Structures as the most typical feature. CLS are constituted by single monocytes closely related one with the other forming a pluricellular structure directly encircling adipocytes (Figure 4A). Inside these cells, small droplets appear very similar to the adipocyte content, suggesting the starting of a phagocytosis mechanism. In a following step of the mechanism suggested by images, single monocytes forming the "crown" around adipocyte, fuse their cytoplasm forming a unique big cytoplasm with many nuclei inside (syncytium) all around adipocytes (Figure 4B), realistically for a more effective action of phagocytosis of the content of these cells and the cytoplasmic residuals of the same necrotic adipocytes. Remark in Figure 4B the small dimensions of the represented adipocyte, due to the action of fat removal by macrophages. At the electron microscope, a single monocyte of the crown appears closely contacting the surface of the adipocyte (Figure 4C).

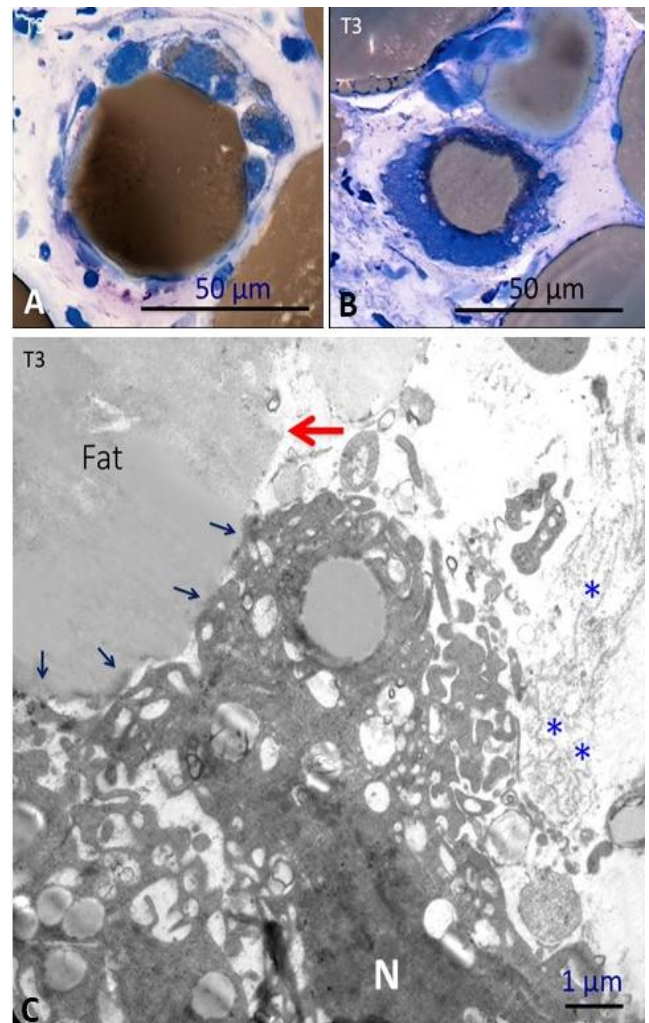


Figure 4: T3 (1 month following treatment); A) Light microscopy of a "Crown-Like-Structure", constituted by a crown of single monocytes, joined between them by thin cytoplasmic processes, distributed all around an adipocyte. These monocytes appear to contain in the cytoplasm small droplets similar to the content of the adipocyte. Realistically these droplets are the result of phagocytosis due to macrophage activity; B) The smaller adipocyte appears completely surrounded by a multinucleated structure originated by the fusion of single monocytes forming a single syncytial macrophage. The small dimensions of the adipocyte are realistically due to stimulated phagocytosis of the fat of necrotic adipocyte. Semithin sections from epoxy resin embedding, toluidine blue-stained; C) In the high left part of the electron micrographs (red arrow), a portion of the big lipidic content of the adipocyte is directly contacting the interstitial tissue. The remnant part of this content is directly contacting the plasma membrane of a macrophage (small black arrows), which has already internalised in his cytoplasm numerous lipid droplets. The lack of the peripheral cytoplasm of the adipocyte demonstrates that this adipocyte has completed the process of cellular death. Furtherly, the basal membrane, far from the adipocyte, appears highly disorganised inside interstitial tissue (asterisks); N: macrophage nucleus

The surface of this cell appears expanded in numerous and complex superficial projections towards both the interstitium and the surface of adipocyte, constituting a sort of labyrinth of spaces realistically ready to endocytosis. Inside this cell, some small droplets of phagocytosis are detectable (Figure 7C). Adipocyte peripheral cytoplasm appears highly fragmented or completely absent, permitting a direct

exposure of the adipocyte content to the interstitium and direct contact between the plasma membrane of macrophage and the big lipid droplet of the same adipocyte. Furtherly, remark the absence of the basal membrane at the surface of the necrotic adipocyte. Disorganised residuals of this structure are recognisable in the interstitium externally to the macrophage (Figure 4C).

The interstitium of the adipose tissue is constituted by a loose connective tissue containing finely distributed collagen fibres and a highly permeable ground substance formed by glycosaminoglycans, proteoglycans and multi adhesive glycoproteins. The interstitial connective tissue is also provided with cells, like fibroblasts, mesenchymal cells capable of differentiation, migrating cells, endothelial cells forming the inner lining of blood and lymphatic vessels. Highly extended lymphatic vessels have been detected even at the light microscope, as a delicate structure with a very fine endothelial wall expanded between adipocytes. Inside lymphatic vessels, free macrophages containing lipid droplets. Realistically, following phagocytosis, macrophages migrate inside connective tissue, then pass through the thin endothelial wall of lymphatics and finally they are transported with the lymph to lymph nodes where the terminal lysis of the phagocytised material is performed (data not shown).

At time T4 (two months after treatment) the normal structure of the adipose tissue appear restored, as shown in semithin sections from epoxy resin embedding (Figure 5A). Normal features of adipocytes morphology two months after treatment are also confirmed at the electron microscope (Figure 5B).

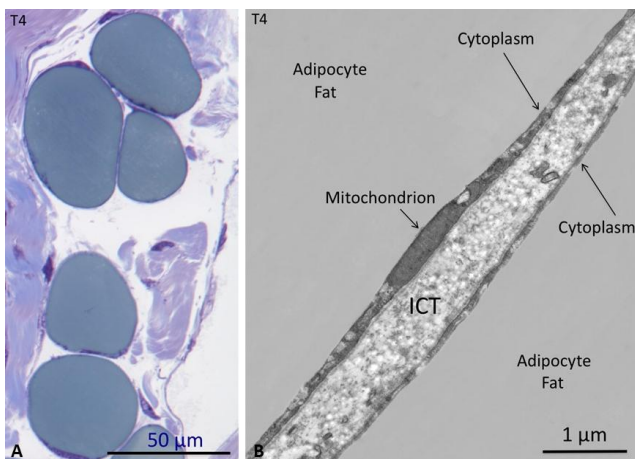


Figure 5: T4 (2 months following treatment); A) Semithin section at the light microscope from epoxy resin embedding, toluidine blue-stained. Adipocytes appear as TO (control), without any vesicle in the thin peripheral cytoplasm and a very thin interstitial tissue between them. No cell infiltrate detectable; B) At the electron microscope, the peripheral cytoplasm of two adjacent adipocytes, with the interstitial connective tissue (ICT) between them, shows normal features, as in the control samples. Abnormal modifications of the plasma membrane or cytoplasmic structures are never detectable. The very small vesicles observable in the peripheral cytoplasm, as in control, are related to physiological trafficking of molecules across peripheral cytoplasm of adipocytes

The effectiveness of the treatment in terms of fat reduction has been demonstrated by ultrasound measurements of thickness from the surface of epidermis to the muscle layer, significantly reduced due to the fat reduction (Table 1).

Table 1: Comparative Table of Thickness from the epidermal surface to the muscle (excluded)

Time Table	Thickness Abdomen A (right)	Thickness Abdomen B (left)
T0 Control	2.7 cm	3.1 cm
T1 Immediately post treatment	2.6 cm	3.0 cm
T2 6 hrs after treatment	2.38 cm	2.59 cm
T3 1 Month after treatment	1.38 cm	1.3 cm
T4 2 Months after treatment	1.31 cm	1.4 cm

## Discussion

Controlled hyperthermia-and maybe other effects not directly evaluable due to the treatment (among them the resonance of some molecular species-both structural and enzymatic-with the frequency of irradiation) determines in the adipose tissue (with particular effect on hypertrophic adipocytes), severe adipolysis with necrotic-like features which in turn stimulate an immune response with the active participation of monocytes and macrophages. Realistically, it could result in adipocytes a response of functional surcharge in the transporting mechanisms through membranes of the peripheral cytoplasm. In adipocytes, some key-structures for the life of cells appear involved, as the plasma membrane, the outer and inner membranes of mitochondria, and the membranes of the endoplasmic reticulum. The plasma membrane is essential for maintaining the intracellular microenvironment and for the whole of the finely controlled transmembrane transport processes which guarantee the correct ionic and molecular gradients and the related homeostatic equilibrium with the extracellular environment. Mitochondria are the cytoplasmic organelles responsible for oxidative phosphorylation, providing adenosine triphosphate (ATP) for most energetic cellular processes. Endoplasmic reticulum (particularly the rough e. r.) is the site of protein synthesis in the polyribosomes attached to the membranes of the organelle, controlling at the same time the 3D conformation of proteins form which specific biological functions depend. Concerning mitochondria, it is possible to consider that the increased catabolism induced by irradiation, in the mitochondria of hypertrophic adipocytes would start a condition of oxidative stress with production of Reactive Species of Oxygen and free radicals (Giordano 2013) [3], promoting an excess of delivery of fatty acids. The excess of transport of different molecular species through lipid droplets well identifiable morphologically at the electron microscope (Kranedonk 2014) [4]-fatty acids, adipokines and pro-inflammatory molecules –

to the outside of the cell towards the interstitial connective tissue (Giordano 2013) [3], overtake the normal physiologic homeostatic flow through the very thin peripheral cytoplasm of adipocytes (Gao 2017) [5].

As a consequence of these structural and functional events, “necrosis-like” modifications are initiated, similarly to what happens in experimental obesity demonstrated in mouse and humans (Cinti 2005) [6]. Through a chemotactic mechanism mediated by receptors specifically called “find me”, microparticles delivered by adipocytes stimulate the recruitment of cells, both resident and coming from the blood, specifically monocytes and macrophages (Eguchi 2015) [7]. To all that, it follows the starting of phagocytosis through molecular triggering signals (“eat me” signals) of phosphatidylserine (a glycerophospholipid) delivered by adipocytes (Krahling 1999, Engin 2017) [8], [9]. They are also released pro-inflammatory mediators, as (TNF) $\alpha$ , nitric oxide synthase, interleukin (IL)-6 and (IL)-1 $\beta$ . The most of macrophages arrange in close relationship with adipocytes which have started the necrotic process, constituting characteristic “Crown Like Structures” (Cinti 2005) [6]. In these structures, activated monocytes and macrophages, starting with single contacts, arrange constituting extended multinuclear syncytia, as demonstrated in our observations. The function of these structures is the removal of the excess of free fatty acids and lipid droplets free in the interstitial tissue, together with the residuals of necrotic adipocytes. The big amount of small insoluble lipid droplets released from adipocytes constitute an important cytotoxic source of cholesterol and free fatty acids, which can damage other adipocytes (Unger 2002) [10]. Because of that, the removal of these molecular species from the interstitial tissue by macrophages represents a defence mechanism to restore the physiological homeostatic equilibrium. To all that it is added the release of further other molecules chemoattractant for macrophages, also stimulating the recruitment of blood monocytes through diapedesis from vessels with synergistic action of resident macrophages (Curat 2004) [11].

The excess of free fatty acids, via “Toll-like receptors” (Nguyen 2007) [12], stimulate the immune-system of the interstitial tissue, represented by resident cells (subpopulation of macrophages also identified as “dendritic cells”). These cells, similarly to dendritic cells and Langerhans cells in the epidermis, perform patrolling functions in the interstitium and favour the recall of other monocytes from the blood. In these cells, phagocytic functions are stimulated and optimised through the aggregation of single monocytes forming multinucleated phagocytosing macrophages which arrange all around the most damaged adipocytes. In this process are also involved the lipases in the adipocytes (Fujimoto 2011) [13], as enzymes acting on constitutive triglycerides inside

adipocytes, with the delivery of glycerol and fatty acids. In this way, these molecules are delivered by adipocytes which already started a necrotic process, to which significantly contribute Reactive Oxygen Species (Ventura 2004, Green 2014) [14], [15]. These molecular species aggravate the cytotoxic stress, with rupture of cells membranes (plasma membrane, mitochondria and endoplasmic reticulum membranes), with free delivery of both cell fragments (or molecular components no more contained inside membranous compartments) and enzymes into the interstitial tissue. Here, through phagocytosis, macrophages remove these materials from interstitium and after that, migrate inside lymphatic vessels in order to complete terminal lysis of phagocytized material from involved adipocytes

## References

1. Thompson BR, Lobo S, Bernlohr DA. Fatty acid flux in adipocytes; the in's and out's of fat cell lipid trafficking. *Mol Cell Endocrinol.* 2010; 318(1-2): 24-33. <https://doi.org/10.1016/j.mce.2009.08.015> PMID:19720110 PMCID:PMC2826553
2. Asan NB, Noreland D, Hassan E, Redzwan Mohd Shah S, Rydberg A, Blokhuis TJ, Carlsson PO, Voigt T, Augustine R. Intra-body microwave communication through adipose tissue. *Healthc Technol Lett.* 2017; 4(4):115-121. <https://doi.org/10.1049/htl.2016.0104> PMID:28868147 PMCID:PMC5569712
3. Giordano A, Murano I, Mondini E, Perugini J, Smorlesi A, Severi I, Barazzoni R, Scherer PE, Cinti S. Obese adipocytes show ultrastructural features of stressed cells and die of pyroptosis. *J Lipid Res.* 2013; 54(9):2423-36. <https://doi.org/10.1194/jlr.M038638> PMID:23836106 PMCID:PMC3735940
4. Kranendonk ME, Visseren FL, van Balkom BW, Nolte-t Hoen EN, van Herwaarden JA, de Jager W, Schipper HS, Brenkman AB, Verhaar MC, Wauben MH, Kalkhoven E. Human adipocyte extracellular vesicles in reciprocal signaling between adipocytes and macrophages. *Obesity (Silver Spring).* 2014; 22(5):1296-308. <https://doi.org/10.1002/oby.20679> PMID:24339422
5. Gao X, Salomon C, Freeman DJ. Extracellular vesicles from Adipose tissue - A potential Role in Obesity and type 2 Diabetes? *Front. Endocrinol.* 2017. 8:202. <https://doi.org/10.3389/fendo.2017.00202> PMID:28868048 PMCID:PMC5563356
6. Cinti S, Mitchell G, Barbatelli G, Murano I, Ceresi E, Faloia E, Wang S, Fortier M, Greenberg AS, Obin MS. Adipocyte death defines macrophage localization and function in adipose tissue of obese mice and humans. *J Lipid Res.* 2005; 46(11):2347-2355. <https://doi.org/10.1194/jlr.M500294-JLR200> PMID:16150820
7. Eguchi A, Mulya A, Lazic M, Radhakrishnan D, Berk MP, Povero D, Gornicka A, Feldstein AE. Microparticles release by adipocytes act as “find-me” signals to promote macrophage migration. *PLoS One.* 2015; 10(4):e0123110. <https://doi.org/10.1371/journal.pone.0123110> PMID:25849214 PMCID:PMC4388837
8. Krahling S, Callahan MK, Williamson P, Schlegel RA. 1999. Exposure of phosphatidylserine is a general feature in the phagocytosis of apoptotic lymphocytes by macrophages. *Cell Death Differ.* 1999; 6(2):183-9. <https://doi.org/10.1038/sj.cdd.4400473> PMID:10200565
9. Engin AB. Adipocyte-Macrophage Cross-Talk in Obesity. *Adv*

- Exp Med Biol. 2017; 960:327-343. [https://doi.org/10.1007/978-3-319-48382-5\\_14](https://doi.org/10.1007/978-3-319-48382-5_14) PMID:28585206
10. Unger R. Lipotoxic diseases. *Annu Rev Med.* 2002; 53:319-336. <https://doi.org/10.1146/annurev.med.53.082901.104057> PMID:11818477
11. Curat C, Miranville A, Saengenes C, Diehl M, Tonus C, Busse R, Boulcumie A. From blood monocytes to adipose tissue-resident macrophages: induction of diapedesis by human mature adipocytes. *Diabetes.* 2004; 53:1285-1292. <https://doi.org/10.2337/diabetes.53.5.1285> PMID:15111498
12. Nguyen MA, Favelukis S, Nguyen AK, Reichart D, Scott PA, Jenn A, Liu-Bryan R, Glass CK, Neels JG, Olefsky JM. A subpopulation of macrophages infiltrates hypertrophic adipose tissue and is activated by free fatty acids via Toll-like receptors 2 and 4 and JNK-dependent pathways. *Journal of Biological Chemistry.* 2007; 282(48):35279-92. <https://doi.org/10.1074/jbc.M706762200> PMID:17916553
13. Fujimoto T1, Parton RG. Not just fat: the structure and function of the lipid droplet. *Cold Spring Harb Perspect Biol.* 2011; 3(3):a004838. <https://doi.org/10.1101/cshperspect.a004838> PMID:21421923 PMCID:PMC3039932
14. Ventura J, Cogswell P, Flavell R, Baldwin AJ, Davis R. JNK potentiates TNF-stimulated necrosis by increasing the production of cytotoxic reactive oxygen species. *Genes Dev.* 2004; 8:2905-2915. <https://doi.org/10.1101/gad.1223004> PMID:15545623 PMCID:PMC534651
15. Green DR, Galluzzi L, Kroemer G. Cell biology. Metabolic control of cell death. *Science* 2014; 345(6203):1250256. <https://doi.org/10.1126/science.1250256> PMID:25237106 PMCID:PMC4219413

# Rosacea Flare - Up after Photodynamic Therapy (PDT) for Field Cancerization and a Review on Adverse Events with PDT in General

Uwe Wollina<sup>1\*</sup>, Alena Bitel<sup>1</sup>, Aleksandra Vojvodic<sup>2</sup>, Torello Lotti<sup>3</sup>

<sup>1</sup>Department of Dermatology and Allergology, Städtisches Klinikum Dresden, Academic Teaching Hospital, Dresden, Germany; <sup>2</sup>Military Medical Academy of Belgrade, Belgrade, Serbia; <sup>3</sup>Department of Dermatology, University of Rome "G. Marconi", Rome, Italy

## Abstract

**Citation:** Wollina U, Bitel A, Vojvodic A, Lotti T. Rosacea Flare - Up after Photodynamic Therapy (PDT) for Field Cancerization and a Review on Adverse Events with PDT in General. Open Access Maced J Med Sci. 2019 Sep 30; 7(18):2998-3001.  
<https://doi.org/10.3889/oamjms.2019.536>

**Keywords:** Actinic keratosis; Field cancerization; Photodynamic therapy; Adverse events; Pain; Rosacea

**\*Correspondence:** Uwe Wollina, Department of Dermatology and Allergology, Städtisches Klinikum Dresden, Academic Teaching Hospital, Dresden, Germany. E-mail: [Uwe.Wollina@klinikum-dresden.de](mailto:Uwe.Wollina@klinikum-dresden.de)

**Received:** 07-Apr-2019; **Revised:** 29-May-2019; **Accepted:** 30-May-2019; **Online first:** 20-Aug-2019

**Copyright:** © 2019 Uwe Wollina, Alena Bitel, Aleksandra Vojvodic, Torello Lotti. This is an open-access article distributed under the terms of the Creative Commons Attribution-NonCommercial 4.0 International License (CC BY-NC 4.0)

**Funding:** This research did not receive any financial support

**Competing Interests:** The authors have declared that no competing interests exist

**BACKGROUND:** Actinic keratoses (AKs) are precancerous epidermal lesions induced by chronic exposure to ultraviolet light. Several topical and surgical treatments are available. For field cancerization, photodynamic therapy (PDT) is a very effective noninvasive treatment with excellent outcome and cosmesis. The management of treatment-associated adverse events, however, is crucial to achieve the treatment aims and to ensure patients adherence to PDT.

**CASE REPORT:** We report on adverse events and their management related to PDT. We conducted literature research on PUBMED (R). Also, we present a case of an uncommon adverse event-PDT-induced rosacea flare-up on scalp and eyes. The patient was treated successfully by submicrobial slow-release doxycycline orally.

**Conclusions:** PDT is an excellent treatment option for multiple AKs such as in bald scalp field cancerization. The management of adverse events during and after PDT is an essential part of a successful treatment plan.

## Introduction

Actinic keratoses (AKs) are common dysplastic intraepidermal lesions induced by chronic exposure to ultraviolet radiation (UVR). The prevalence of AKs in the United States has been estimated at nearly 40 million in 2004. AKs have the ability to progress to cutaneous squamous cell carcinoma (SCC) rate a yearly rate of 0.6% in the elderly population [1]. Multiple AKs often develop on the bald scalp in patients with an outdoor profession such as farmers, construction workers, or sailors. Such a situation has been described as field cancerization since the affected area is at higher risk

to develop cutaneous squamous cell carcinomas (SCC) [2]. Recently, the AK area and severity index (AKASI) has been developed as a new quantitative tool for assessing AK severity on the head and to monitor outcomes of different treatments [3].

For the treatment of AKs, various pharmacological, surgical and phototherapeutic approaches are available. One of the highly preferred methods to treat field cancerization is photodynamic therapy (PDT) [4], [5].

PDT is a non-invasive method that combines a photosensitizer that accumulated in preneoplastic and neoplastic epidermal keratinocytes with subsequent irradiation. Protoporphyrin IX (PpIX) is the

photosensitizer most commonly used in dermatological PDT. Soluble precursors to PpIX such as 5-aminolevulinic acid (ALA) or methylaminolevulinate (MAL) are used in topical ointments. These compounds are absorbed by the skin and enzymatically converted into PpIX within the keratinocytes. In contrast to normal keratinocytes, preneoplastic and neoplastic cells accumulate more PpIX more rapidly than normal cells because their heme biosynthesis is elevated. The most effective way to activate intracellular PpIX is an irradiation with 635 nm [6]. By irradiation, the photosensitizer becomes activated and leads to oxidative stress in mitochondria and membranes, resulting in cell death [7].

## Case Report

A 70-year-old Caucasian male patient present with a field cancerization with multiple actinic keratoses (AKs) on the forehead and scalp (Figure 1). His medical history was remarkable for facial and scalp rosacea, but the disease was in remission.

In the past, actinic keratoses were treated topically with diclofenac sodium 3% in hyaluronic acid 2.5% gel and 0.015% ingenol mebutate gel. However, this did not result in complete remissions but showed a rather rapid relapse. Therefore, photodynamic treatment (PDT) was suggested.

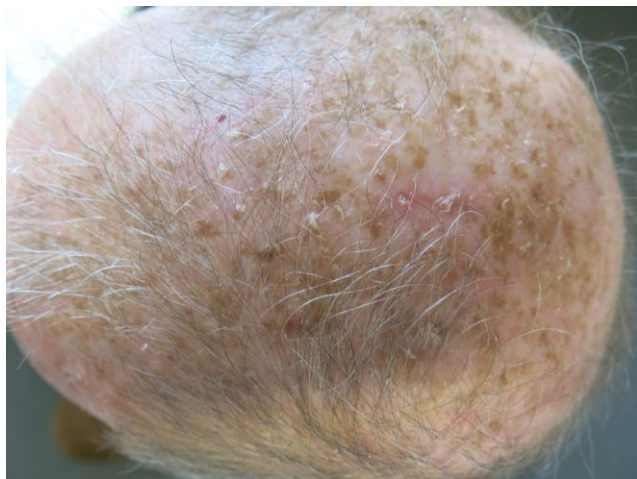

Figure 1: Field cancerization of the bald scalp

He underwent a single PDT. The session started with roughing of the actinically damaged skin with a mono-filamentous fibre pad (Debrisoft®, Lohmann & Rauscher GmbH & Co. KG, Neuwied, Germany). The area was disinfected with Octenisept® solution (SCHÜLKE & MAYR GmbH, Norderstedt, Germany). After that, a gel containing 78 mg 5-aminolaevulinic acid nanoemulsion (Ameluz®,

Biofrontera AG, Leverkusen, Germany) was applied. The area was covered by the aluminum foil for 3 hours. Before irradiation, the gel residues were removed with a wet gauze compress. Irradiation was performed with a narrow-band red light with a peak wavelength of 635 nm and a total light intensity of 37 J/cm<sup>2</sup> (BF-RHODO LED®, Biofrontera). During PDT, skin surface was treated by cooled air and an ice-spray. After PDT, skincare with a cream containing an extract of *Mahonia aquifolium* (Beliox® cream, Biofrontera AG) for at least two weeks was recommended.

Immediately after the procedure, moderate erythema was noted. The following days, he developed the usual inflammatory reaction in the treated area, which improved after topical treatment with moisturiser.

After 2 weeks, however, he presented with a severe flare-up of preexistent rosacea with multiple papulopustules on the scalp (red scalp syndrome) and ocular involvement with blepharitis-conjunctivitis (Figure 2). He received oral low-dose doxycycline (Oraycea 40 mg retard capsules 1 x d) with rapid improvement within 10 days.

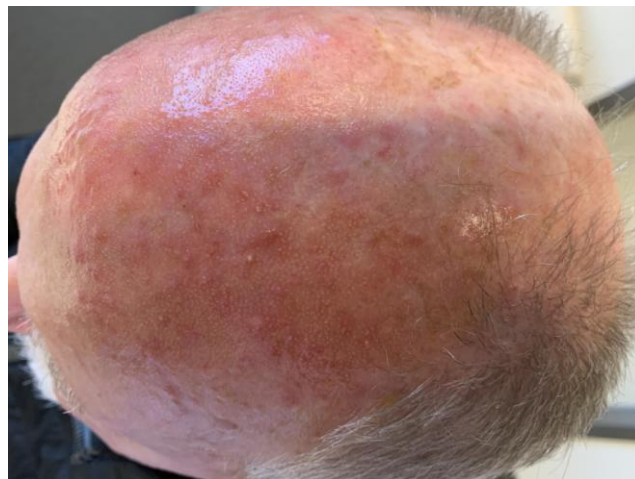

Figure 2: Rosacea eruption on the scalp after successful PDT. No actinic keratoses can be seen but erythematous papules

## Literature review on adverse events of dermatological PDT

The major drawback of PDT is the strong pain experienced during the irradiation with 635 nm light that can sometimes become even intolerable for patients, requiring interruption or termination of the process [4], [5]. Reactive oxygen species, transient receptor potential channels and inflammatory reactions are mediators in pain. This type of pain does not respond to oral pharmacological pain killers. Topical anaesthesia is of limited value. In a comparative trial, the scalp nerve block was more effective than intravenous (IV) analgesia with piritramide 7.5 mg IV plus oral metamizole in combination with cold-air analgesia, and cold-air analgesia alone [8].

An alternative to classical red-light irradiation is day-light PDT. The efficacy is slightly lower in particular in case of thicker AKs. On the other hand, low-irradiance light sources (such as variable pulsed light and daylight PDT) are currently the best analgesic option [9].

Other treatment-emergent adverse events are erythema, bullous reactions, transient oedema, and oozing. These cutaneous adverse events are experienced by 100% of treated patients in variable grades of severity. Sun-protection after PDT and moisturisers for skincare are highly recommended. Usually, these adverse events disappear within 2 weeks after PDT [10], [11].

## Discussion

PDT is a versatile treatment option in dermatology to improve symptoms of extrinsic ageing, including actinic keratoses but also acne and rosacea [12],[13],[14]. Adverse events are temporary and include pain sensations and localised inflammatory reactions. Here we report a rather uncommon adverse event after successful PDT – a rosacea flare-up.

During the treatment of field cancerization, rosacea is a possible adverse event. In a trial with topical ALA-PDT and red light, 70 J/cm<sup>2</sup> for mild and moderate AKs rosacea occurred in 6.6% of cases [15]. In a series of 30 patients with field cancerization treated by 5-aminolaevulinic acid nano-emulsion and narrow-band red light, no rosacea was noted [12].

Our patient presented with a combination of papulopustular eruptions on his scalp, suggesting a red scalp syndrome and ocular rosacea. Red scalp syndrome is part of the rosacea spectrum and responds very well to oral low-dose doxycycline [16], [17]. Systemic treatment is also warranted in the case of ocular rosacea involvement [18].

An alternative for the treatment of actinic keratoses and rosacea would be the use of combined Q-switched KTP 532 nm and Nd: YAG 1064 nm laser [19], combined intense pulse light and Q-switched KTP 532 nm, or Q-switched KTP 532 nm laser alone [20]. All of these methods work on precancerous lesions. They also target telangiectasia (KTP) and erythema (Nd: YAG and IPL). However, none of these is efficient for papulopustular rosacea.

Rosacea is known to be aggravated by several endogenous and exogenous factors. Heat activates both TRPV1 and TRPV2 (transient receptor potential vanilloid), which are involved in rosacea pathogenesis. Inflammasome (NALP3) and TLR-2 are induced by sun-light exposure in rosacea. Last not least, cosmetics have been shown to induce TRPA1 (transient receptor potential ankyrin 1) [19].

Although not studied in detail, various pathogenetic pathways might have been involved in this rare adverse effect of PDT – red scalp and blepharoneuroconjunctivitis.

In conclusion, PDT is a versatile noninvasive method in dermatology. The major medical indication is the treatment of multiple AKs and field cancerization. Adverse events are common but of a temporary nature. While pain and inflammatory reactions are noted in almost all patients, rosacea is a rather uncommon unwanted side effect. Treatment is as in idiopathic rosacea.

## References

1. Siegel JA, Korgavkar K, Weinstock MA. Current perspective on actinic keratosis: a review. *Br J Dermatol.* 2017; 177(2):350-358. <https://doi.org/10.1111/bjd.14852> PMID:27500794
2. Figueras Nart I, Cerio R, Dirschka T, Dréno B, Lear JT, Pellacani G, Peris K, Ruiz de Casas A; Progressing Evidence in AK (PEAK) Working Group. Defining the actinic keratosis field: a literature review and discussion. *J Eur Acad Dermatol Venereol.* 2018; 32(4):544-563. <https://doi.org/10.1111/jdv.14652> PMID:29055153
3. Dirschka T, Pellacani G, Micali G, Malvehy J, Stratigos AJ, Casari A, Schmitz L, Gupta G; Athens AK Study Group. A proposed scoring system for assessing the severity of actinic keratosis on the head: actinic keratosis area and severity index. *J Eur Acad Dermatol Venereol.* 2017; 31(8):1295-1302. <https://doi.org/10.1111/jdv.14267> PMID:28401585
4. Werner RN, Stockfleth E, Connolly SM, Correia O, Erdmann R, Foley P, Gupta AK, Jacobs A, Kerl H, Lim HW, Martin G, Paquet M, Pariser DM, Rosumeck S, Röwert-Huber HJ, Sahota A, Sanguenza OP, Shumack S, Sporbeck B, Swanson NA, Torezan L, Nast A; International League of Dermatological Societies; European Dermatology Forum. International League of Dermatological Societies in cooperation with the European Dermatology Forum. Evidence- and consensus-based (S3) Guidelines for the Treatment of Actinic Keratosis - Short version. *J Eur Acad Dermatol Venereol.* 2015; 29(11):2069-79. <https://doi.org/10.1111/jdv.13180> PMID:26370093
5. Morton CA, Szeimies RM, Sidoroff A, Braathen LR. European guidelines for topical photodynamic therapy part 1: treatment delivery and current indications - actinic keratoses, Bowen's disease, basal cell carcinoma. *J Eur Acad Dermatol Venereol.* 2013; 27(5):536-44. <https://doi.org/10.1111/jdv.12031> PMID:23181594
6. Taylor EL, Brown SB. The advantages of aminolevulinic acid photodynamic therapy in dermatology. *J Dermatolog Treat.* 2002; 13 Suppl 1:S3-11. <https://doi.org/10.1080/095466302317414645> PMID:12060511
7. Babilas P, Schreml S, Landthaler M, Szeimies RM. Photodynamic therapy in dermatology: state-of-the-art. *Photodermatol Photoimmunol Photomed.* 2010; 26(3):118-32. <https://doi.org/10.1111/j.1600-0781.2010.00507.x> PMID:20584250
8. Klein A, Karrer S, Horner C, Werner A, Heinlin J, Zeman F, Koller M, Landthaler M, Szeimies RM, Gruber M, Graf B, Hansen E, Kersch C. Comparing cold-air analgesia, systemically administered analgesia and scalp nerve blocks for pain management during photodynamic therapy for actinic keratosis of the scalp presenting as field cancerization: a randomized controlled trial. *Br J Dermatol.* 2015; 173(1):192-200. <https://doi.org/10.1111/bjd.13547> PMID:25413485
9. Wang B, Shi L, Zhang YF, Zhou Q, Zheng J, Szeimies RM,



- Wang XL. Gain with no pain? Pain management in dermatological photodynamic therapy. *Br J Dermatol.* 2017; 177(3):656-665. <https://doi.org/10.1111/bjd.15344> PMID:28122416
10. Reinhold U, Dirschka T, Ostendorf R, Aschoff R, Berking C, Philipp-Dormston WG, Hahn S, Lau K, Jäger A, Schmitz B, Lübbert H, Szeimies RM. A randomized, double-blind, phase III, multicentre study to evaluate the safety and efficacy of BF-200 ALA (Ameluz®) vs. placebo in the field-directed treatment of mild-to-moderate actinic keratosis with photodynamic therapy (PDT) when using the BF-RhodoLED(®) lamp. *Br J Dermatol.* 2016; 175(4):696-705. <https://doi.org/10.1111/bjd.14498> PMID:26921093
11. Dirschka T, Radny P, Dominicus R, Mensing H, Brüning H, Jenne L, Karl L, Sebastian M, Oster-Schmidt C, Klövekorn W, Reinhold U, Tanner M, Gröne D, Deichmann M, Simon M, Hübinger F, Hofbauer G, Krähn-Senftleben G, Borrosch F, Reich K, Berking C, Wolf P, Lehmann P, Moers-Carpi M, Hönigsmann H, Wernicke-Panten K, Helwig C, Foguet M, Schmitz B, Lübbert H, Szeimies RM; AK-CT002 Study Group. Photodynamic therapy with BF-200 ALA for the treatment of actinic keratosis: results of a multicentre, randomized, observer-blind phase III study in comparison with a registered methyl-5-aminolaevulinate cream and placebo. *Br J Dermatol.* 2012; 166(1):137-46. <https://doi.org/10.1111/j.1365-2133.2011.10613.x> PMID:21910711
12. Wollina U, Gaber B, Koch A. Photodynamic treatment with nanoemulsified 5-aminolevulinic acid and narrow band red light for field cancerization due to occupational exposure to ultraviolet light irradiation. *Georgian Med News.* 2018; (274):138-143.
13. Ozog DM, Rkein AM, Fabi SG, Gold MH, Goldman MP, Lowe NJ, Martin GM, Munavalli GS. Photodynamic Therapy: A Clinical Consensus Guide. *Dermatol Surg.* 2016; 42(7):804-27. <https://doi.org/10.1097/DSS.0000000000000800> PMID:27336945
14. Fan L, Yin R, Lan T, Hamblin MR. Photodynamic therapy for rosacea in Chinese patients. *Photodiagnosis Photodyn Ther.* 2018; 24:82-87. <https://doi.org/10.1016/j.pdpdt.2018.08.005> PMID:30118905
15. Buinauskaite E, Maciulaitis R, Buinauskiene J, Valiukeviciene S. Topical photodynamic therapy of actinic keratoses with 5-aminolevulinic acid: randomized controlled trial with six months follow-up. *J Dermatolog Treat.* 2014; 25(6):519-22. <https://doi.org/10.3109/09546634.2013.848257> PMID:24215475
16. Wollina U. Three orphans one should know: red scalp, red ear and red scrotum syndrome. *J Eur Acad Dermatol Venereol.* 2016; 30(11):e169-e170. <https://doi.org/10.1111/jdv.13474> PMID:26515581
17. Wollina U. Subantimicrobial-dose doxycycline monohydrate in dermatology. *Wien Med Wochenschr.* 2015; 165(23-24):499-503. <https://doi.org/10.1007/s10354-015-0399-9> PMID:26564206
18. Schaller M, Almeida LM, Bewley A, Cribier B, Dlova NC, Kautz G, Mannis M, Oon HH, Rajagopalan M, Steinhoff M, Thiboutot D, Troielli P, Webster G, Wu Y, van Zuuren E, Tan J. Rosacea treatment update: recommendations from the global ROSacea COnsensus (ROSCO) panel. *Br J Dermatol.* 2017; 176(2):465-471. <https://doi.org/10.1111/bjd.15173> PMID:27861741
19. Demetriou C. Reversing precancerous actinic damage by mixing wavelengths (1064 nm, 532 nm). *J Cosmet Laser Ther.* 2011; 13(3):113-9. <https://doi.org/10.3109/14764172.2011.581289> PMID:21609213
20. Hofmann MA, Lehmann P. Physical modalities for the treatment of rosacea. *J Dtsch Dermatol Ges.* 2016; 14 (Suppl 6):38-43. <https://doi.org/10.1111/ddg.13144>
21. Wollina U. Recent advances in the understanding and management of rosacea. *F1000Prime Rep.* 2014; 6:50. <https://doi.org/10.12703/P6-50> PMID:25184040 PMID:PMC4108952

# Wells Syndrome – An Odyssey

Birgit Heinig<sup>1</sup>, Aleksandra Vojvodic<sup>2</sup>, Torello Lotti<sup>3</sup>, Michael Tirant<sup>3</sup>, Uwe Wollina<sup>4\*</sup>

<sup>1</sup>Center of Physical and Rehabilitative Medicine, Städtisches Klinikum Dresden, Academic Teaching Hospital, Dresden, Germany; <sup>2</sup>Military Medical Academy of Belgrade, Belgrade, Serbia; <sup>3</sup>Department of Dermatology, University of Rome “G. Marconi”, Rome, Italy; <sup>4</sup>Department of Dermatology and Allergology, Städtisches Klinikum Dresden, Academic Teaching Hospital, Dresden, Germany

## Abstract

**Citation:** Heinig B, Vojvodic A, Lotti T, Tirant M, Wollina U. Wells Syndrome – An Odyssey. *Open Access Maced J Med Sci.* 2019 Sep 30; 7(18):3002-3005. <https://doi.org/10.3889/oamjms.2019.572>

**Keywords:** Eosinophilic skin diseases; Wells syndrome; Flame figure; Eosinophilia; Treatment; Interleukin-5

**\*Correspondence:** Uwe Wollina, Department of Dermatology and Allergology, Städtisches Klinikum Dresden, Academic Teaching Hospital, Dresden, Germany. E-mail: [uwollina@gmail.com](mailto:uwollina@gmail.com)

**Received:** 30-Apr-2019; **Revised:** 22-Jun-2019; **Accepted:** 23-Jun-2019; **Online first:** 30-Jun-2019

**Copyright:** © 2019 Birgit Heinig, Aleksandra Vojvodic, Torello Lotti, Michael Tirant, Uwe Wollina. This is an open-access article distributed under the terms of the Creative Commons Attribution-NonCommercial 4.0 International License (CC BY-NC 4.0)

**Funding:** This research did not receive any financial support

**Competing Interests:** The authors have declared that no competing interests exist

**BACKGROUND:** Wells syndrome is a rare idiopathic dermatosis of the eosinophilic spectrum. Diagnostic criteria include cutaneous eruptions of variable morphology with eosinophilic infiltrates, peripheral blood eosinophilia, a relapsing, remitting course, and exclusion of systemic disease. Diagnosis is often delayed.

**CASE PRESENTATION:** We present a 28-year older man with recently developed pruritic and sometimes painful erythema. His medical history was positive for coughing in the evening that started in November 2012. Later, a pansinusitis developed. Early diagnosis improves the outcome.

**CONCLUSION:** Standardized treatment has yet to be developed. In our case, systemic corticosteroids were of limited value only.

## Introduction

Eosinophilic skin diseases are characterised by eosinophil infiltration and/or degranulation in skin lesions, with or without blood eosinophilia. Eosinophils can defend against microbes, to regulate inflammation, cause tissue damage, promote remodelling and fibrosis, and initiate pruritus. Tissue eosinophilia can be caused by cytokine-mediated increased differentiation and survival of eosinophils (extrinsic eosinophilic disorders), and mutation-mediated clonal expansion of eosinophils (intrinsic eosinophilic disorders). Increased generation of interleukin (IL)-5 producing T-lymphocytes is often involved [1].

Eosinophilic skin diseases are heterogeneous. Pruritus is a common symptom. These disorders can be classified in:

- allergy-related (allergic drug eruption, urticaria, allergic contact dermatitis, atopic dermatitis),
- parasitic infestations and arthropod bites,
- infection-related (chronic pulmonary aspergillosis, HIV, *Toxocara canis*),
- autoimmune blistering (bullous pemphigoid, dermatitis herpetiformis), and
- those of unknown origin (idiopathic).

The latter group, which is extremely heterogeneous and rare, includes Wells syndrome

(eosinophilic cellulitis), granuloma faciale, eosinophilic pustular folliculitis, recurrent cutaneous eosinophilic vasculitis, Job syndrome, angiolymphoid hyperplasia with eosinophilia, and eosinophilic fasciitis [2]. Here we present a case of Wells syndrome with a remarkable delay of diagnosis.

## Case Report

A 28-year old man presented with recently developed pruritic and sometimes painful erythema (Figure 1). His medical history was positive for coughing in the evening that started in November 2012. In January 2018, he contacted his GP because of fever. He got a prescription for codeine and oral antibiotic.

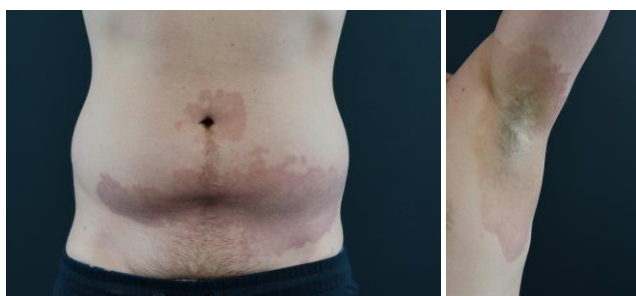


Figure 1: Clinical presentation of Wells syndrome (eosinophilic cellulitis) with large erythematous and brownish macules with slightly elevated borders: abdominal (left); axillary (right)

Because of a feeling of pressure and fullness of the paranasal sinuses, he went to an ENT specialist. The allergy tests remained negative, and he got a prescription for 200 mg-cineole capsules.

In April 2018 he experienced a short breath in addition to coughing and greenish sputum. The pulmonologist diagnosed infection-triggered asthma. A corticoid asthma spray improved coughing temporarily.

He presented himself again to the ENT specialist in July 2018 because of persistent coughing and nasal speech. He got a prescription for an oral antibiotic, prednisolone tablets and a corticoid-containing nasal-spray. In August 2018 he suffered an allergic shock after novaminsulfon intake. A respiratory insufficiency was treated in the intensive care unit. Oral prednisolone medication was continued. A computerised tomography (CT) of paranasal sinuses demonstrated a massive polypoid pansinusitis with congestion of the cavities. At this point, the erythematous skin lesions appeared.

On examination, we observed larger erythematous to brownish macules with a slightly elevated border of the armpits, peri- and infra-umbilical, on fingers and thighs. There was no scaling,

no blistering (Figure 1).

A diagnostic skin biopsy revealed eosinophilic and neutrophilic infiltrate with dominance of eosinophils of the whole corium with presence of so-called flame figures, i.e. degranulated eosinophils around collagen fibres.

Eosinophilia of the cutis is suggestive of the following three differential diagnoses: Wells syndrome (Eosinophilic cellulitis - EC), Churg-Strauss syndrome (Eosinophilic granulomatosis with polyangiitis - EGPA), and hyper-eosinophilic syndrome (HES).

Imaging: Echocardiography remained unremarkable. Dual X-ray energy of the chest was suggestive of atypical pneumonia treated with oral clindamycin (Figure 2).

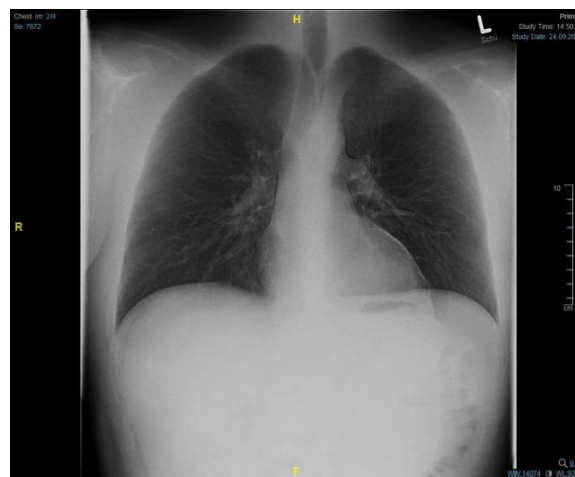

Figure 2: Chest X-ray with atypical pneumonia-like features

Body plethysmography excluded obstructive or restrictive ventilation conditions. There was no hint for a diffusion abnormality either.

Abdominal ultrasound demonstrated no pathological findings.

The ENT council confirmed a chronic pansinusitis with an indication for functional endoscopic sinus surgery. Histology of the surgical specimen did not show tissue eosinophilia. After surgery, prednisolone was omitted. The exanthema re-appeared but was less severe. Dyspnea continued.

Laboratory investigation: Eosinophil blood count 23.7 % (normal range: 0.8 – 7.0) or 2.03 G/L (0.04 – 0.54), total IgE 416.0 kU/L (< 100), lymphopenia of 20.0 % (25-45), creatine kinase 3.74  $\mu\text{mol/s} \cdot \text{L}$  (0.00-2.90), total protein 62.4 g/L (66-87), 25-OH-vitamine D 15.5 ng/L (20.0-80.0), C-reactive protein, ANA, c-ANCA, p-ANCA, myeloperoxidase, C3 and C4 complement, antibodies to SSA/Ro, SSB/La, Scl-70, Jo-1, Sm, and RNP70 were normal or negative.

In summary of our findings, we confirmed the diagnosis of Wells syndrome.

The medication at the end of hospital stay consisted of the following medical drugs: Cetirizine 10 mg/d, methyl-prednisolone 8 mg/d, cortisone nasal spray; tiotropium bromide pulmonary spray and salmeterol xinafoate/fluticasone spray, cholecalciferol 20.000 I.U. on day 1 and 15 of each month, and fluocinolone acetonide ointment for a maximum of 4 weeks.

## Discussion

Our patient underwent an odyssey to the final diagnosis of EC. Eventually, EGPA could be excluded by the normal finding of chest X-ray, body plethysmography, absence of tissue eosinophilia in surgical specimen from pansinusitis surgery, and absence of ANCA in peripheral blood. In skin histology there was no vasculitis, granulomas were missing [3].

HES has been recently redefined as: (1) Blood eosinophilia of greater than 1500/mm<sup>3</sup> on at least two occasions or evidence of prominent tissue eosinophilia associated with symptoms and marked blood eosinophilia. (2) Exclusion of secondary causes of eosinophilia, such as parasitic or viral infections, allergic diseases, drug-induced or chemical-induced eosinophilia, hypoadrenalism, and neoplasms [4].

EC or Wells syndrome was described in 1971 by G. C. Wells as recurrent granulomatous dermatitis with eosinophilia [5]. EC has a sudden onset. During the course of the disease, patients present with recurrent episodes of acute pruritic dermatitis and / or painful edematous swellings or persistent urticarial eruptions. This was a leading symptom in the present patient.

**Table 1: Diagnostic criteria for eosinophilic cellulitis (Wells syndrome)**

Major criteria (2 of 4 required)
Any of the previously reported clinical variants
Plaque-type
Annular-granuloma-like
Urticaria-like
Papulovesicular
Bullous
Papulonodular
Fixed-Drug Eruption-like
Relapsing, remitting course
No systemic evidence disease
Histology: eosinophilic infiltrates, no vasculitis
Minor (at least 1 required)
Histology: Flame figures
Histology: Granulomatous change
Laboratory: Peripheral eosinophilia not persistent and not greater than > 1500/ $\mu$ l
Triggering factor (e.g. drug)

Histopathology is useful in diagnostics. The findings vary with the disease stage, of course. Initially, oedema and a dermal infiltrate of eosinophils are seen. The sub-acute stage, as in our patient, is characterised by fibrinoid flame-figures of mid to deep dermis. Later on, eosinophils tend to disappear and are replaced by histiocytic granulomas. The absence

of vasculitis is an important negative sign [6].

Diagnostic criteria have been proposed by Heelan et al., in 2013 [7] (Table 1).

The cause of the disease is unknown, but other disorders may be associated with EC such as infections or hematologic disorders or medical drugs. Cases of EC arising in patients receiving biologics are increasingly reported [8], [9].

Systemic corticosteroids are usually helpful in EC, but the response may vary about associated pathologies. In our case, the previous corticosteroid treatments were too short, or the dosage was insufficient, leading to recurrences. Standard doses are 1 mg prednisolone per kg body weight. Sometimes higher dosages and repeated course are necessary. Cyclosporin A has been used at doses between 100 and 200 mg/d. Alternatives to systemic corticosteroids are dapsone with a dosage of up to 200 mg/d if there is no glucose-6-phosphate dehydrogenase deficiency, antihistamines (with limited success), colchicine, chloroquine, and azathioprine among others. The combination of prednisolone 50 to 10 mg/d with dapsone 50 mg/d seems to induce a more rapid response. Randomised controlled trials are missing [10].

New treatment modalities are on the horizon. Case reports on successful treatment of EC with monoclonal anti-IgE antibody omalizumab have been published [11]. Increased expression of IL-5 has been reported in several cases. Therefore, antibodies directed against IL-5 (e.g. mepolizumab), IL-5-receptor, and Siglec-8 could be a choice. Reduction of tissue eosinophilia can be achieved by dexpramipexole, tyrosine kinase inhibitors, Janus kinase inhibitors, or cytokine inhibitors to IL-13, IL-31, and others [12].

In conclusion, EC or Wells syndrome is a rare disorder of the spectrum of eosinophilic skin diseases. Diagnosis may be significantly delayed if this rare syndrome is not considered during a chronic relapsing course of variable complaints. Other eosinophilic disorders need to be excluded. Underlying or associated diseases of autoimmune, infectious or malignant nature need careful consideration. Treatment of choice is systemic corticosteroids, but more specific treatment options are on the horizon.

## References

1. Simon D, Wardlaw A, Rothenberg ME. Organ-specific eosinophilic disorders of the skin, lung, and gastrointestinal tract. *J Allergy Clin Immunol*. 2010; 126(1):3-13; quiz 14-5. <https://doi.org/10.1016/j.jaci.2010.01.055> PMID:20392477 PMCID:PMC2902687
2. Long H, Zhang G, Wang L, Lu Q. Eosinophilic Skin Diseases: A Comprehensive Review. *Clin Rev Allergy Immunol*. 2016;

- 50(2):189-213. <https://doi.org/10.1007/s12016-015-8485-8> PMID:25876839
3. Cottin V, Bel E, Bottero P, Dalhoff K, Humbert M, Lazor R, Sinico RA, Sivasothy P, Wechsler ME, Groh M, Marchand-Adam S, Khouatra C, Wallaert B, Taillé C, Delaval P, Cadranet J, Bonniaud P, Prévot G, Hirschi S, Gondouin A, Dunogué B, Chatté G, Briault C, Pagnoux C, Jayne D, Guillevin L, Cordier JF; Groupe d'Etudes et de Recherche sur les Maladies Orphelines Pulmonaires (GERM"O"P). Revisiting the systemic vasculitis in eosinophilic granulomatosis with polyangiitis (Churg-Strauss): A study of 157 patients by the Groupe d'Etudes et de Recherche sur les Maladies Orphelines Pulmonaires and the European Respiratory Society Taskforce on eosinophilic granulomatosis with polyangiitis (Churg-Strauss). *Autoimmun Rev*. 2017; 16(1):1-9. <https://doi.org/10.1016/j.autrev.2016.09.018> PMID:27671089
4. Simon HU, Rothenberg ME, Bochner BS, Weller PF, Wardlaw AJ, Wechsler ME, Rosenwasser LJ, Roufosse F, Gleich GJ, Klion AD. Refining the definition of hypereosinophilic syndrome. *J Allergy Clin Immunol*. 2010; 126(1):45-9. <https://doi.org/10.1016/j.jaci.2010.03.042> PMID:20639008 PMID:PMC3400024
5. Wells GC. Recurrent granulomatous dermatitis with eosinophilia. *Trans St Johns Hosp Dermatol Soc*. 1971; 57(1):46-56.
6. Peckruhn M, Tittelbach J, Schliemann S, Elsner P. Life of lesions in eosinophilic cellulitis (Wells' syndrome)-a condition that may be missed at first sight. *Am J Dermatopathol*. 2015; 37(2):e15-7. <https://doi.org/10.1097/DAD.0000000000000051> PMID:25238447
7. Heelan K, Ryan JF, Shear NH, Egan CA. Wells syndrome (eosinophilic cellulitis): Proposed diagnostic criteria and a literature review of the drug-induced variant. *J Dermatol Case Rep*. 2013; 7(4):113-20. <https://doi.org/10.3315/jdcr.2013.1157> PMID:24421864 PMID:PMC3888780
8. Rozenblat M, Cohen-Barak E, Dodiuk-Gad R, Ziv M. Wells' Syndrome Induced by Ustekinumab. *Isr Med Assoc J*. 2019; 21(1):65.
9. Dabas G, De D, Handa S, Chatterjee D, Radotra BD. Wells syndrome in a patient receiving adalimumab biosimilar: A case report and review of literature. *Indian J Dermatol Venereol Leprol*. 2018; 84(5):594-599. [https://doi.org/10.4103/ijdv.IJDVL\\_636\\_17](https://doi.org/10.4103/ijdv.IJDVL_636_17) PMID:30058563
10. Rășler F, Lukács J, Elsner P. Treatment of eosinophilic cellulitis (Wells syndrome) - a systematic review. *J Eur Acad Dermatol Venereol*. 2016; 30(9):1465-79. <https://doi.org/10.1111/jdv.13706> PMID:27357601
11. Egeland Ø, Balieva F, Undersrud E. Wells syndrome: a case of successful treatment with omalizumab. *Int J Dermatol*. 2018; 57(8):994-995. <https://doi.org/10.1111/ijd.14006> PMID:29707773
12. Simon D, Simon HU. Therapeutic strategies for eosinophilic dermatoses. *Curr Opin Pharmacol*. 2019; 46:29-33. <https://doi.org/10.1016/j.coph.2019.01.002> PMID:30743138

# Large B - Cell Lymphoma of the Leg – Unfavourable Course with Rituximab/Bendamustin

Uwe Wollina<sup>1\*</sup>, Nadine Schmidt<sup>1</sup>, Jacqueline Schönlebe<sup>2</sup>, Aleksandra Vojvodic<sup>3</sup>, Gesina Hansel<sup>1</sup>, André Koch<sup>1</sup>, Torello Lotti<sup>4</sup>

<sup>1</sup>Department of Dermatology and Allergology, Städtisches Klinikum Dresden, Academic Teaching Hospital, Dresden, Germany; <sup>2</sup>Institute of Pathology “Georg Schmorl”, Städtisches Klinikum Dresden, Academic Teaching Hospital; <sup>3</sup>Military Medical Academy of Belgrade, Belgrade, Serbia; <sup>4</sup>Department of Dermatology, University of Rome “G. Marconi”, Rome, Italy

## Abstract

**Citation:** Wollina U, Schmidt N, Schönlebe J, Vojvodic A, Hansel G, Koch A, Lotti T. Large B - Cell Lymphoma of the Leg – Unfavourable Course with Rituximab/Bendamustin. Open Access Maced J Med Sci. 2019 Sep 30; 7(18):3006-3008. <https://doi.org/10.3889/oamjms.2019.565>

**Keywords:** Cutaneous lymphomas; Peripheral diffuse large B-cell lymphoma of the leg-type; Immunotherapy; Rituximab; Bendamustine; Histopathology

**\*Correspondence:** Uwe Wollina, Department of Dermatology and Allergology, Städtisches Klinikum Dresden, Academic Teaching Hospital, Dresden, Germany. E-mail: [Uwe.Wollina@klinikum-dresden.de](mailto:Uwe.Wollina@klinikum-dresden.de)

**Received:** 11-Apr-2019; **Revised:** 22-Jun-2019; **Accepted:** 23-Jun-2019; **Online first:** 30-Jun-2019

**Copyright:** © 2019 Uwe Wollina, Nadine Schmidt, Jacqueline Schönlebe, Aleksandra Vojvodic, Gesina Hansel, André Koch, Torello Lotti. This is an open-access article distributed under the terms of the Creative Commons Attribution-NonCommercial 4.0 International License (CC BY-NC 4.0)

**Funding:** This research did not receive any financial support

**Competing Interests:** The authors have declared that no competing interests exist

**BACKGROUND:** Cutaneous B-cell lymphomas represent about 25% of all cutaneous lymphomas. Peripheral diffuse large B-cell lymphoma of the leg type is the most aggressive subtype seen mainly in elderly patients. Treatment is not standardised.

**CASE REPORT:** An 87-year-old female patient was presented in May 2018 because of the development of painless subcutaneous nodules on the legs since late 2017. On examination, we observed up to 5 cm large erythematous nodules on the legs and a smaller plaque in the left submammary fold. The histology of a skin demonstrated tumour infiltrate that was separated from the overlying epidermis by a grenz zone. It consisted of densely packed, blastoid lymphocytic cells with numerous, and some atypical mitoses. The cells were positive for CD20, CD79A and CD5. Almost 100% of the cells were labelled with Ki67. The diagnosis of a diffuse large B-cell lymphoma (PCLBCL-LT) of the leg was confirmed. Histologic analysis of a bone marrow biopsy demonstrated a hypercellular bone marrow without malignant lymphatic infiltrates. Diagnostic ultrasound of cervical nodes and computerised tomography (CT) scans (native and with contrast medium) of head, neck and trunk excluded an extracutaneous manifestation of the PCLBCL-LT. Treatment with rituximab plus bendamustine was initiated, but tumour progress was noted after the second course. Suggested palliative therapy with radiation and rituximab was refused. The patient died 7 months after diagnosis.

**CONCLUSIONS:** Although some trials suggested a beneficial effect of immuno-chemotherapy, the prognosis of (PCLBCL-LT) remains poor. Standardised treatment is missing due to the relative rarity of this malignancy.

## Introduction

Among all primary cutaneous lymphomas, B-cell lymphomas (CBCL) represent the minority with 25% of all cases. Their diagnosis is based on histopathology, immunohistochemistry, and staging evaluation. There are 3 types of primary (CBCL): primary cutaneous marginal zone lymphoma, primary cutaneous follicle centre lymphoma, and primary cutaneous diffuse large B-cell lymphoma, leg-type and NOS-type (not otherwise specified) [1]. Since these malignancies have the same morphology as their systemic counterparts, the diagnosis is one of exclusion of extracutaneous manifestation.

Cutaneous large B-cell lymphomas that contain a majority ( $\geq 80\%$ ) of large-cells and a proliferative rate  $\geq 40\%$  need further subtyping into diagnosis between leg type peripheral B-cell lymphoma (PCLBCL-LT) or primary cutaneous follicle centre lymphoma with large cell morphology (PCFCL-LC), and unclassified lymphomas (PCLBCL/NOS). Both CD10 and MUM1 are characteristic for the leg-type [2]. Patients with PCLBCLs-LT are on average older than those with (PCLBCL/NOS) and express more Bcl-2. Negative prognostic markers are Bcl-2, MYC rearrangements, and female gender, while proliferation rate (Ki67) is not of prognostic significance. Overall survival (OS) is poorer for PCLBCL-LT than PCFCL-LC or PCLBCL/NOS [2], [3], [4].

## Case Report

An 87-year-old female patient presented in May 2018 because of the development of painless subcutaneous nodules on the legs since late 2017. Past medical history was positive for a basal cell carcinoma of the nose which had been surgically removed in 2016, bilateral knee replacement and a large goitre.

On examination, we observed up to 5 cm large erythematous nodules on the legs and a smaller plaque in the left submammary fold (Figure 1).

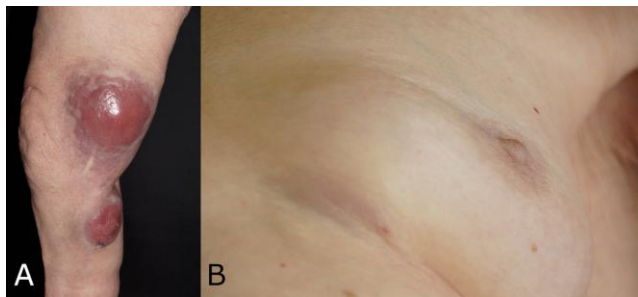


Figure 1: Primary cutaneous diffuse large B-cell lymphoma, leg-type; A) Large tumour nodules of the legs; B) Tumor plaque of the left submammary fold

A skin biopsy was performed. The tumour infiltrates separated from the overlying epidermis by a grenz zone. It consisted of densely packed, blastoid lymphocytic cells with numerous, and some atypical mitoses (Figure 2).

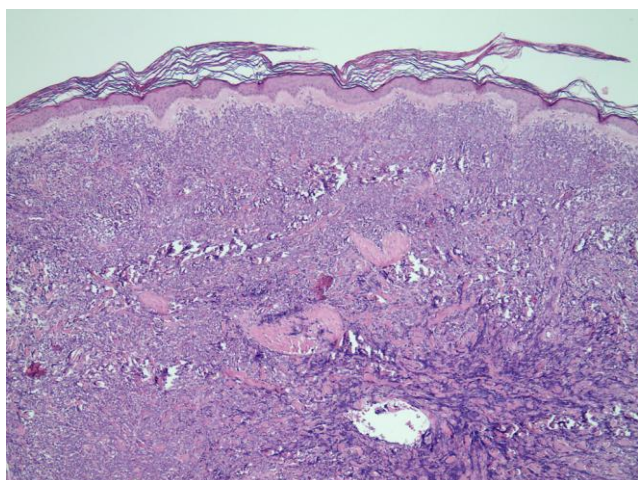


Figure 2: Histopathology of primary cutaneous diffuse large B-cell lymphoma, leg-type, with a grenz zone and blastoid lymphocytic cells of the dermis (Hematoxylin-eosin x 2)

The cells were positive for CD20, CD79A and CD5. Almost 100% of the cells were labelled with Ki67 (Figure 3). There was no reactivity with antibodies against CD10, CD30, Bcl-2, Bcl-6, cyclin D1 and SOX11. The diagnosis of a diffuse large B-cell lymphoma (PCLBCL-LT) of the leg was confirmed.

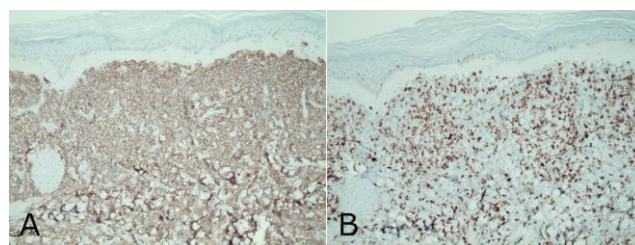


Figure 3: Immunohistology of primary cutaneous diffuse large B-cell lymphoma, leg-type, peroxidase stain; A) CD20 (x 10); B) Ki67 (x 10)

Histologic analysis of a bone marrow biopsy demonstrated a hypercellular bone marrow without malignant lymphatic infiltrates. Diagnostic ultrasound of cervical nodes and computerised tomography (CT) scans (native and with contrast medium) of head, neck and trunk demonstrated the giant goitre but no hints of an extracutaneous manifestation of the PCLBCL-LT were found. Laboratory investigations: Initially, we observed a leucopenia of 3.29 Gpt/L (Normal range: 3.8-11.0), increased lactate dehydrogenase of 5.33  $\mu$ kat/L (2.25-3.55), beta-2-microglobulin 3.3 mg/L (0.8-2.4), and strongly increased soluble interleukin-2 receptor of 1,188 U/mL (223-710). In the differential blood count, there was a lymphopenia of 8%.

She was presented to the interdisciplinary tumour board. Combination of rituximab / bendamustin therapy was initiated, and adjuvant neutropenia prophylaxis with granulocyte-colony stimulation factor (Neupogen®) was administered. Infection prophylaxis with trimethoprim – sulfamethoxazole, and substitution with folic acid and vitamin B12 completed the medical treatment. She has undergone two cycles but experienced progress of the disease after an initial partial response. Therefore, palliative radiotherapy, in combination with rituximab once a week was planned. Tumour nodules increased by size and by number, the larger ones exulcerated. The patients rejected the suggested palliative treatment. She died 7 months after confirmation of the diagnosis.

## Discussion

PCLBCL-LT is clinically more aggressive than other primary cutaneous B-cell lymphomas. This malignancy usually affects elderly females (mean age 76 years) and presents with rapidly progressive tumour nodules of the lower legs. The treatment is more challenging since PCLBCL-LT usually require multi-agent chemotherapy (cyclophosphamide, doxorubicin or epirubicin, vincristine, prednisone) and anti-CD20 monoclonal antibodies as their systemic counterparts [5], [6]. Most patients present with

disease confined to the leg(s). Although only a few reports are available, the use of R-CHOP (with anti-CD20 monoclonal antibody rituximab) in these patients is associated with disease-free survival rates comparing to those of patients with high-risk systemic diffuse large B-cell lymphomas. Field radiation therapy is another option. The overall 5-year disease-specific survival rate has been estimated as 41%-50%. Location on the leg and multiple skin lesions were predictive of death in multivariate analysis [7], [8]. In another trial, disease-specific survival at 5 years was 100% for those receiving rituximab versus 67% for no rituximab [9]. Rituximab plus bendamustine is effective in a variety of lymphomas, including relapsed or refractory diffuse large B cell lymphoma [10], [11], [12]. One study in aggressive diffuse B-cell lymphoma achieved an objective response rate of 45.8 % (complete response, 15.3%; partial response, 30.5%). The median duration of response was 17.3 months, and the median progression-free survival lasted 3.6 months [11].

PCLBCL-LT is an aggressive variant of primary cutaneous B-cell lymphomas. Our patient belonged to the typical age group. Negative prognostic markers are female gender, Bcl-2 expression, and MYC rearrangements [2], [3], [4]. We did not perform an MYC rearrangement analysis. Her lymphoma did not express Bcl-2. Weekly immuno-chemotherapy with rituximab and alkylating agent bendamustine was initiated. After an initial partial response, the situation worsened in our patient. Therefore, the combination was stopped after the second cycle. Recently, Bruton's tyrosine kinase inhibitor ibrutinib combined with chemotherapy-induced a durable remission in PCLBCL-LT with mutant *MYD88* and wild type *CD79* [13]. A single-arm phase II trial with the thalidomide derivate lenalidomide in relapsing or refractory PCLBCL-LT achieved a response rate of 26.3% with 4 complete responses. The median overall survival was 19.4 months [14].

Although another palliative approach had been suggested, the patient rejected any further therapy and died seven months after confirmation of the diagnosis. More effective treatment options that are tolerable in elderly patients are needed to improve prognosis.

## References

- Goyal A, LeBlanc RE, Carter JB. Cutaneous B-Cell Lymphoma. *Hematol Oncol Clin North Am.* 2019; 33(1):149-161. <https://doi.org/10.1016/j.hoc.2018.08.006> PMID:30497672
- Menguy S, Beylot-Barry M, Marie P, Pham Ledard A, Frison E, Como F, Battistella M, Szablewski V, Balme B, Croue A, Franck F, Ortonne N, Tournier E, Lamant L, Carlotti A, De Muret A, Le Gall F, Lorton MH, Merlio JP, Vergier B. Primary Cutaneous Large B-Cell Lymphomas: relevance of the 2017 WHO Classification. *Histopathology.* 2019;
- Felcht M, Klemke CD, Nicolay JP, Weiss C, Assaf C, Wobser M, Schlaak M, Hillen U, Moritz R, Tantcheva-Poor I, Nashan D, Beyer M, Dippel E, Müller CSL, Sachse MM, Meiss F, Géraud C, Marx A, Goerd S, Geissinger E, Kempf W. Primary cutaneous diffuse large B-cell lymphoma, NOS and leg type: Clinical, morphologic and prognostic differences. *J Dtsch Dermatol Ges.* 2019; 17(3):275-285. <https://doi.org/10.1111/ddg.13773>
- Schrader AMR, Jansen PM, Vermeer MH, Kleiverda JK, Vermaat JSP, Willemze R. High Incidence and Clinical Significance of MYC Rearrangements in Primary Cutaneous Diffuse Large B-Cell Lymphoma, Leg Type. *Am J Surg Pathol.* 2018; 42(11):1488-1494. <https://doi.org/10.1097/PAS.0000000000001132> PMID:30113335
- Paulli M, Lucioni M, Maffi A, Croci GA, Nicola M, Berti E. Primary cutaneous diffuse large B-cell lymphoma (PCDLBCL), leg-type and other: an update on morphology and treatment. *G Ital Dermatol Venereol.* 2012; 147(6):589-602.
- Wilcox RA. Cutaneous B-cell lymphomas: 2015 update on diagnosis, risk-stratification, and management. *Am J Hematol.* 2015; 90(1):73-6. <https://doi.org/10.1002/ajh.23863> PMID:25535037
- Grange F, Beylot-Barry M, Courville P, Maubec E, Bagot M, Vergier B, Souteyrand P, Machet L, Dalac S, Esteve E, Templier I, Delaporte E, Avril MF, Robert C, Dalle S, Laroche L, Delaunay M, Joly P, Wechsler J, Petrella T. Primary cutaneous diffuse large B-cell lymphoma, leg type: clinicopathologic features and prognostic analysis in 60 cases. *Arch Dermatol.* 2007; 143(9):1144-50. <https://doi.org/10.1001/archderm.143.9.1144> PMID:17875875
- Senff NJ, Hoefnagel JJ, Jansen PM, Vermeer MH, van Baarlen J, Blokx WA, Canninga-van Dijk MR, Geerts ML, Hebeda KM, Kluijn PM, Lam KH, Meijer CJ, Willemze R. Reclassification of 300 primary cutaneous B-Cell lymphomas according to the new WHO-EORTC classification for cutaneous lymphomas: comparison with previous classifications and identification of prognostic markers. *J Clin Oncol.* 2007; 25(12):1581-7. <https://doi.org/10.1200/JCO.2006.09.6396> PMID:17353548
- Hamilton SN, Wai ES, Tan K, Alexander C, Gascoyne RD, Connors JM. Treatment and outcomes in patients with primary cutaneous B-cell lymphoma: the BC Cancer Agency experience. *Int J Radiat Oncol Biol Phys.* 2013; 87(4):719-25. <https://doi.org/10.1016/j.ijrobp.2013.07.019> PMID:24001373
- Rummel MJ, Al-Batran SE, Kim SZ, Welslau M, Hecker R, Kofahl-Krause D, Josten KM, Dürk H, Rost A, Neise M, von Grünhagen U, Chow KU, Hansmann ML, Hoelzer D, Mitrou PS. Bendamustine plus rituximab is effective and has a favorable toxicity profile in the treatment of mantle cell and low-grade non-Hodgkin's lymphoma. *J Clin Oncol.* 2005; 23(15):3383-9. <https://doi.org/10.1200/JCO.2005.08.100> PMID:15908650
- Vacirca JL, Acs PI, Tabbara IA, Rosen PJ, Lee P, Lynam E. Bendamustine combined with rituximab for patients with relapsed or refractory diffuse large B cell lymphoma. *Ann Hematol.* 2014; 93(3):403-9. <https://doi.org/10.1007/s00277-013-1879-x> PMID:23955074 PMCID:PMC3918114
- Rigacci L, Puccini B, Cortelazzo S, Gaidano G, Piccin A, D'Arco A, Freilone R, Storti S, Orciuolo E, Zinzani PL, Zaja F, Bongarzone V, Balzarotti M, Rota-Scalabrini D, Patti C, Gobbi M, Carpaneto A, Liberati AM, Bosi A, Iannitto E. Bendamustine with or without rituximab for the treatment of heavily pretreated non-Hodgkin's lymphoma patients: A multicenter retrospective study on behalf of the Italian Lymphoma Foundation (FIL). *Ann Hematol.* 2012; 91(7):1013-22. <https://doi.org/10.1007/s00277-012-1422-5> PMID:22349722
- Deng AL, Kim YR, Lichtenstein EA, O'Connor OA, Deng C. Combination of ibrutinib and chemotherapy produced a durable remission in multiply relapsed diffuse large B-cell lymphoma leg type with mutant MYD88 and wildtype CD79. *Haematologica.* 2017; 102(7):e275-e277. <https://doi.org/10.3324/haematol.2016.161893> PMID:28341730 PMCID:PMC5566054
- Beylot-Barry M, Mermin D, Maillard A, Bouabdallah R, Bonnet N, Duval-Modeste AB, Mortier L, Ingen-Housz-Oro S, Ram-Wolff C, Barete S, Dalle S, Maubec E, Quereux G, Templier I, Bagot M, Grange F, Joly P, Vergier B, Vialy PJ, Gros A, Pham-Ledard A, Frison E, Merlio JP. A Single-Arm Phase II Trial of Lenalidomide in Relapsing or Refractory Primary Cutaneous Large B-Cell Lymphoma, Leg Type. *J Invest Dermatol.* 2018; 138(9):1982-1989. <https://doi.org/10.1016/j.jid.2018.03.1516> PMID:29596904



# Adult Measles – Case Reports of a Highly Contagious Disease

André Koch<sup>1</sup>, Claudia Krönert<sup>1</sup>, Torello Lotti<sup>2</sup>, Aleksandra Vojvodic<sup>3</sup>, Uwe Wollina<sup>1\*</sup>

<sup>1</sup>Department of Dermatology and Allergology, Städtisches Klinikum Dresden, Academic Teaching Hospital, Dresden, Germany; <sup>2</sup>Department of Dermatology, University of Rome “G. Marconi”, Rome, Italy; <sup>3</sup>Military Medical Academy of Belgrade, Belgrade, Serbia

## Abstract

**Citation:** Koch A, Krönert C, Lotti T, Vojvodic A, Wollina U. Adult Measles – Case Reports of a Highly Contagious Disease. Open Access Maced J Med Sci. 2019 Sep 30; 7(18):3009-3012.  
<https://doi.org/10.3889/oamjms.2019.540>

**Keywords:** Measles; Viral exanthema; Vaccination; Maculopapular rash; Encephalopathy; Thrombocytopenia; Pneumonia

**\*Correspondence:** Uwe Wollina, Department of Dermatology and Allergology, Städtisches Klinikum Dresden, Academic Teaching Hospital, Dresden, Germany. E-mail: [uwollina@gmail.com](mailto:uwollina@gmail.com)

**Received:** 07-Apr-2019; **Revised:** 04-May-2019; **Accepted:** 05-Jun-2019; **Online first:** 30-Jun-2019

**Copyright:** © 2019 André Koch, Claudia Krönert, Torello Lotti, Aleksandra Vojvodic, Uwe Wollina. This is an open-access article distributed under the terms of the Creative Commons Attribution-NonCommercial 4.0 International License (CC BY-NC 4.0)

**Funding:** This research did not receive any financial support

**Competing Interests:** The authors have declared that no competing interests exist

**BACKGROUND:** Measles is highly contagious and is caused by the RNA morbillivirus. The best protection is active immunisation in early childhood. Without immunisation morbidity and mortality of measles are high. In recent years, an increasing number of adult measles has been recognised in Europe.

**CASE REPORTS:** We report here on two adult patients – a 40-year-old male and a 55-year-old female – who presented with fever, fatigue, cough, coryza, conjunctivitis and maculopapular rash. The suspicion of adult measles infection was confirmed by positivity for IgM antibodies against measles virus and reverse-transcriptase polymerase chain reaction in blood and urine. Patients were isolated, and the treatment was symptomatic. In the younger patient, complete recovery was achieved within two weeks. In the older patient, an acute encephalopathy developed after initial improvement characterised by cognitive impairment.

**CONCLUSIONS:** In patients presenting with fever and maculopapular rash and fatigue, measles should be considered even in adult patients. Early diagnosis with subsequent isolation and registration of patients are important measures to prevent local outbreaks of the disease.

## Introduction

Measles is caused by infection with morbillivirus, which belongs to the *paramyxoviridae* family of single-stranded, negative-sense, non-segmented RNA viruses. The complete genome sequence of measles viruses has been discovered [1].

Measles belongs among the most contagious disorders of humankind with a basic reproduction number (R<sub>0</sub>) of 15 to 18, that translates into 15 to people who got infected by a single index patient. Almost everybody who is not immunised develops measles after two hours in the same room with an infected patient [2].

The incubation time is about 10 days. The disease is characterised by fever, followed by cough, coryza, and conjunctivitis. After 3 days of fever, the measles rash appears with small white Koplik's spots

on the buccal mucosa [3], [4] and maculopapular erythema, which starts on the face and spreads quickly to the trunk and the extremities [5]. Common complications include pneumonia, diarrhoea, middle ear infection, and central nervous system symptoms including seizures or encephalitis [6]. The risk of severe complication of measles is highest in children < 5 years of age and in adults > 20 years of age [7].

Immunisation provides protection [8]. The vaccine coverage in the general population should be as high as 95% to provide herd protection. Currently, this has not been realised in many European countries. In Germany, the Robert Koch Institute registered 727 cases of measles in 2017, translating into an incidence of 8.9 per 1 000 000 inhabitants. About 40% of registered cases were adults older than 20 years of age [9]. We report here two recent cases of adult measles in Dresden, Germany.

## Case reports

### Case 1

A 40-year-old male patient presented with high fever, fatigue, cough, sore throat, dysgeusia, conjunctivitis, and diarrhoea in the emergency department of the Municipal Hospital Dresden. About three days before, he had developed an erythematous rash. He had got a vaccination against measles as a child.

On examination, we observed a non-obese patient with severe fatigue. Koplik's spots were missing, but the oral mucosa was erythemic, vulnerable and bled easily. He had acute conjunctivitis and a generalised maculopapular rash including the palmar skin (Figure 1a).

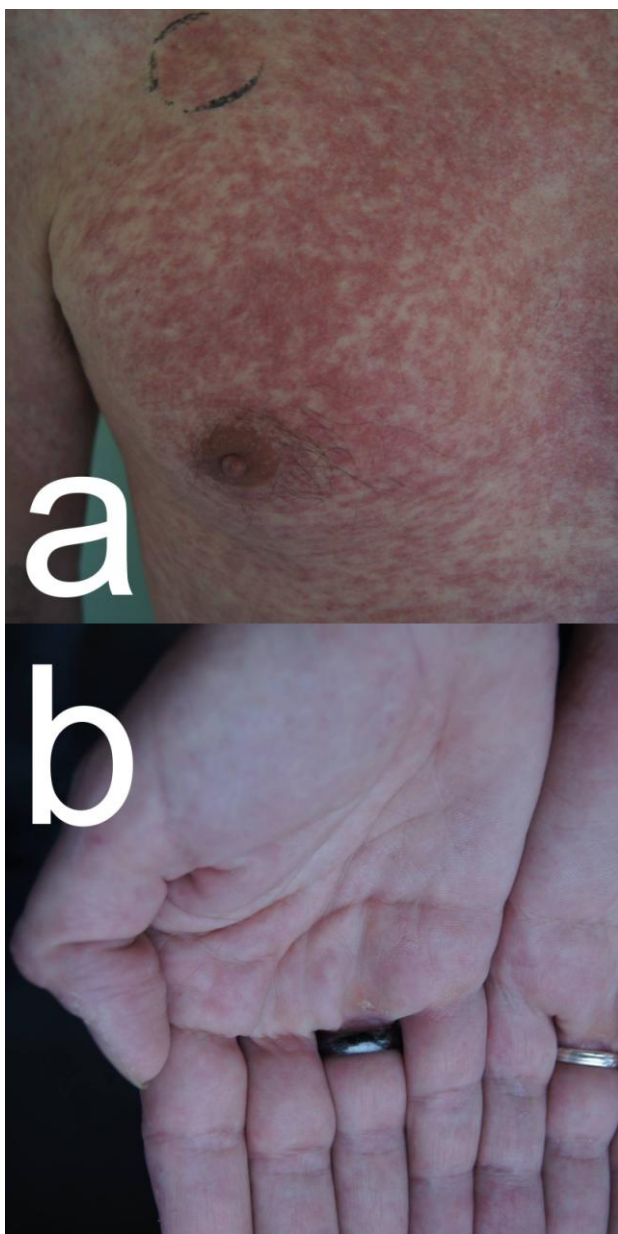


Figure 1: Measles: A) and B) Maculopapular rash. Involvement of the palms

Laboratory findings included thrombocytopenia, hyponatraemia, a moderate increase of C-reactive protein, and increased transaminases. Anti-measles IgM antibodies were positive in serum probes. Measles virus-RNA was detected from oral mucosa swabs and urine by polymerase chain reaction (PCR).

X-ray of the lungs suggested atypical pneumonia.

The patient was immediately isolated. Symptomatic therapy with intravenous infusions to correct hyponatraemia, antipyretic therapy with metamizole and clarithromycin for pneumonia was initialised. The patient achieved complete remission within 12 days.

### Case 2

A 55-year-old female patient presented with fever, fatigue, arthralgia, muscle pain, dyspnea, dysphonia, sore throat, cough in the emergency department. On the day before, she developed an erythematous rash.

On examination, we found a patient with a generalised maculopapular rash, Koplik's spots, conjunctivitis, and basal pulmonary crepitations (Fig. 1b).

Laboratory findings were leukopenia with 2.27 Gpt/L, lymphopenia (11%), increased plasma cell count (3%), thrombocytopenia (115 Gpt/L), 5-fold increased transaminases ASAT (2.85  $\mu$ kat/L) and ALAT (2.09  $\mu$ kat/L), gamma-glutamyl transferase 10.01  $\mu$ kat/L (15-fold increase), creatinine kinase 22  $\mu$ kat/L (8-fold increase), C-reactive protein 23.4 mg/L. Infection serology for influenza, hepatitis B, HIV 1/2, and legionella spp. was all negative. Measles IgM-antibodies were positive. PCR for measles from oral swabs and urine were positive. Computerised tomography of lungs and brain was unremarkable.

The patient was immediately isolated. Symptomatic treatment was initiated, and clinical improvement was rapid. After a couple of days, however, the patient developed cognitive dysfunction. She became unable to organise her daily activities. Eventually, she was unable to dress. She lost spontaneous communication but could answer simple direct questions. We suspected central nervous involvement. The cerebrospinal fluid analysis (CSF) revealed normal cell counts, protein concentration, and immunoglobulin levels. Measles virus PCR was negative. Multiplex PCR film array disclosed no meningitis or encephalitis pathogens. Magnetic resonance imaging (MRI) of the brain was normal. Both electrocardiogram and electroencephalogram were normal. The neurologic and psychiatric evaluation suggested a chronic encephalopathy. Improvement was significantly delayed. Therefore, neurological rehabilitation was organised.

## Discussion

Measles is a highly contagious viral disease affecting worldwide about 190 000 patients [6]. In the European Economic Area, 1818 measles infections were reported between July 2015 to June 2016, including 309 cases from Germany [10]. Local vaccination gaps caused several local epidemics in Berlin, Baden-Württemberg, and Bavaria. The most efficient and feasible intervention to limit measles outbreaks is the improvement of vaccination rate in the general population [11], [12], [13].

Clinical diagnosis of measles can be confirmed by laboratory methods such as a positive serological test for measles-specific immunoglobulin M antibody, isolation of measles virus in culture, or detection of measles virus RNA by ribonucleic acid reverse transcriptase-PCR [6].

There is an increasing number of adults affected by measles. Our patients disclosed a clinical peculiarity. In the typical case, measles exanthema spares palms and soles. Both patients, however, had involvement of the palms.

Patients older than 20 years of age are at risk of developing major complications such as subacute sclerosing panencephalitis (SSPE), a deadly disease due to persistence of measles virus in the central nervous system [9].

In both patients presented here, fatigue was associated with the 3 C's cough, coryza and conjunctivitis plus fever. The first patient was probably incompletely vaccinated during childhood. This is, however, questionable, since his course was not characteristic of modified measles. There were no vaccination documents available for both.

Both patients demonstrated thrombocytopenia, the most common haematological complication. They also suffered from pneumonia, a complication that is a major cause of mortality from measles in children [14].

The second patient developed, after clinical improvement, a severe neurologic disability. We do not expect SSPE since this disease usually develops with a delay of 4 to 10 years after acute infection and not within days or weeks. Children of less than 5 years of age represent the majority of cases [15].

Our second patient did not suffer from slow myoclonic jerks, visual symptoms, or periodic complexes on EEG. She had no raised titers of anti-measles antibodies in cerebrospinal fluid. Another possible complication is measles inclusion-body encephalitis. Again, we could not identify this particular disorder in our patient. Approximately one in 1000 patients with measles develop primary measles encephalitis, typically on day 5 of the rash (range: 1-14 days) [15]. In the present case, encephalitis was excluded by CSF analysis and MRI of the brain. We

suspect a yet not specified measles-induced acute encephalopathy [16].

In conclusion, measles is still an important viral infection worldwide. Due to vaccination gaps, adult-onset measles in industrialised Western countries such as Germany is increasing. Early recognition, isolation of patients and registration by the certified boards help to limit outbreaks. Symptomatic treatment is sufficient, but complications are common. Improved vaccination programs are necessary to protect citizens.

## References

1. Magaña LC, Espinosa A, Marine RL, Ng TFF, Castro CJ, Montmayeur AM, Hacker JK, Scott S, Whyte T, Bankamp B, Oberste MS, Rota PA. Complete Genome Sequences of Mumps and Measles Virus Isolates from Three States in the United States. *Genome Announc.* 2017; 5(33):e00748-17. <https://doi.org/10.1128/genomeA.00748-17> PMID:28818890 PMCID:PMC5604763
2. De Jong JG, Winkler KC. Survival of measles virus in air. *Nature.* 1964; 201:1054-5. <https://doi.org/10.1038/2011054a0> PMID:14191599
3. Koplik H. The diagnosis of the invasion of measles from a study of the exanthema as it appears on the buccal mucous membrane. *Arch Pediatr.* 1962; 79:162-5.
4. Aziz J. Rash Inside the Mouth. *Am Fam Physician.* 2017; 95(11):729-730.
5. Zhang Y, Yu YS, Zang GQ. Maculopapular rash and Koplik's spots in adult measles. *Rev Soc Bras Med Trop.* 2015; 48(2):231. <https://doi.org/10.1590/0037-8682-0236-2014> PMID:25992944
6. Moss WJ. Measles. *Lancet.* 2017; 390(10111):2490-2502. [https://doi.org/10.1016/S0140-6736\(17\)31463-0](https://doi.org/10.1016/S0140-6736(17)31463-0)
7. Rota PA, Moss WJ, Takeda M, de Swart RL, Thompson KM, Goodson JL. Measles. *NatRev Dis Primers.* 2016; 2:16049. <https://doi.org/10.1038/nrdp.2016.49> PMID:27411684
8. Robert-Koch-Institut. Impfpfehlungen der Ständigen Impfkommision (STIKO) am Robert Koch Institut. *Epid Bull* 2013; 34:313-343.
9. Matysiak-Klose D, Wicker S; für die Nationale Verifizierungskommission Masern Röteln (NAVKO) in Deutschland. Measles in Germany: An Epidemiological Analysis and First Measures for Containment. *Dtsch Med Wochenschr.* 2017; 142(23):1767-1772. <https://doi.org/10.1055/s-0043-117973> PMID:29145682
10. Eichner L, Wjst S, Brockmann SO, Wolfers K, Eichner M. Local measles vaccination gaps in Germany and the role of vaccination providers. *BMC Public Health.* 2017; 17(1):656. <https://doi.org/10.1186/s12889-017-4663-3> PMID:28807023 PMCID:PMC5557556
11. Palamara MA, Visalli G, Picerno I, Di Pietro A, Puglisi G, Marano F, D'Andrea G, Facciola A. Measles outbreak from February to August 2017 in Messina, Italy. *J Prev Med Hyg.* 2018; 59(1):E8-E13.
12. Béraud G, Abrams S, Beutels P, Dervaux B, Hens N. Resurgence risk for measles, mumps and rubella in France in 2018 and 2020. *Euro Surveill.* 2018; 23(25). <https://doi.org/10.2807/1560-7917.ES.2018.23.25.1700796> PMID:29945697 PMCID:PMC6152239
13. Wiese-Posselt M, Tertilt C, Zepp F. Vaccination recommendations for Germany. *Dtsch Arztebl Int.* 2011;

108(45):771-9; quiz 780. <https://doi.org/10.3238/arztebl.2011.0771>  
PMid:22163258 PMCID:PMC3230171

14. Ananiev J, Vassilev I, Arabadzhiev G, Ramdan V, Chokoeva AA, Tchernev G, Wollina U. Measles induced death in Eastern Europe. *Acta Med Bulg.* 2016; 41(2):67-74.  
<https://doi.org/10.1515/amb-2014-0025>

15. Watanabe S, Shirogane Y, Sato Y, Hashiguchi T, Yanagi Y.

New Insights into Measles Virus Brain Infections. *Trends Microbiol.* 2019; 27(2):164-175. <https://doi.org/10.1016/j.tim.2018.08.010>  
PMid:30220445

16. Kumar R, Kumar A, Dubey A, Misra PK. Acute encephalopathy associated with measles. *Indian J Pediatr.* 1989; 56(3):349-54.  
<https://doi.org/10.1007/BF02722298> PMid:2807470

# Unilateral Pseudo-Ainhum in Liver Cirrhosis

Uwe Wollina<sup>1\*</sup>, Michael Tirant<sup>2</sup>, Aleksandra Vojvodic<sup>3</sup>, Veronica di Nardo<sup>2</sup>, Torello Lotti<sup>2,4</sup>

<sup>1</sup>Department of Dermatology and Allergology, Städtisches Klinikum Dresden, Academic Teaching Hospital, Dresden, Germany; <sup>2</sup>Department of Dermatology, University of Rome "G. Marconi", Rome, Italy; <sup>3</sup>Military Medical Academy of Belgrade, Belgrade, Serbia; <sup>4</sup>Hanoi Medical University, Hanoi, Vietnam

## Abstract

**Citation:** Wollina U, Tirant M, Vojvodic A, di Nardo V, Lotti T. Unilateral Pseudo-Ainhum in Liver Cirrhosis. Open Access Maced J Med Sci. 2019 Sep 30; 7(18):3013-3014.  
<https://doi.org/10.3889/oamjms.2019.681>

**Keywords:** Pseudo-ainhum; Ainhum; Liver Cirrhosis; Fibrosis

**\*Correspondence:** Uwe Wollina, Department of Dermatology and Allergology, Städtisches Klinikum Dresden, Academic Teaching Hospital, Dresden, Germany. E-mail: uwollina@gmail.com

**Received:** 17-Aug-2019; **Revised:** 07-Sep-2019; **Accepted:** 08-Sep-2019; **Online first:** 10-Sep-2019

**Copyright:** © 2019 Uwe Wollina, Michael Tirant, Aleksandra Vojvodic, Veronica di Nardo, Torello Lotti. This is an open-access article distributed under the terms of the Creative Commons Attribution-NonCommercial 4.0 International License (CC BY-NC 4.0)

**Funding:** This research did not receive any financial support

**Competing Interests:** The authors have declared that no competing interests exist

**BACKGROUND:** Pseudo-ainhum is defined as any case of auto-amputation not associated with the classic spontaneous ainhum seen in Africans with unknown etiology.

**CASE PRESENTATION:** A severely ill 58-year-old male patient presented with a painless constricting circular band on his left second toe. His medical history was remarkable for severe alcoholic liver cirrhosis with ascites formation leading to dyspnea. He had a hypoalbuminemia and a pronounced peripheral sensory neuropathy.

**CONCLUSION:** Here we present the second case of pseudo-ainhum associated with liver cirrhosis.

## Introduction

Liver cirrhosis is considered as an end-stage of different types of liver injury. It is characterised by a chronic inflammatory and fibrotic process [1]. Cirrhosis has been associated to several skin diseases such as soft tissue infections [2], yellow urticaria [3], spider angiomas, paper money skin and xerosis [4], and Muehrcke lines of the nails [5].

In 2001, Wollina et al. described 64-year-old Caucasian woman with breast cancer, systemic scleroderma, and primary biliary cirrhosis due to Reynolds' syndrome, who presented with bilateral pseudo-ainhum [6]. Here, we report a second case of pseudo-ainhum in a patient with liver cirrhosis.

## Case Presentation

A severely ill 58-year-old male patient presented with a painless constricting circular band on his left second toe. His medical history was remarkable for severe alcoholic liver cirrhosis with ascites formation leading to dyspnea. He had a hypoalbuminemia and a pronounced peripheral sensory neuropathy. Other comorbidities were hypertension and hyperuricemia.

On examination we observed a constricting band of the second left toe (Figure 1). He had a generalized xerosis cutis with features of paper money skin and purpura, but no jaundice. He had palmar erythema and onychomycosis of toe nails.

We made the clinical diagnosis of pseudo-ainhum stage I. The primary treatment consisted of the management of the underlying liver disease.

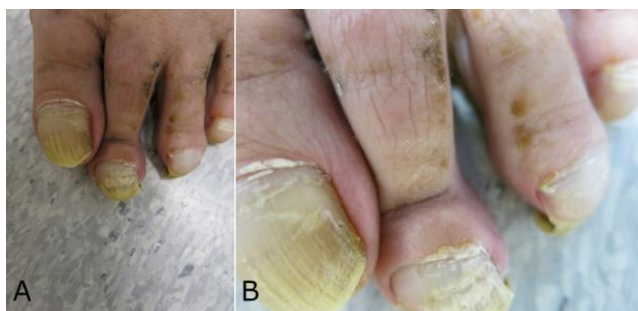

Figure 1: A) Constricting band of the 2<sup>nd</sup> toe on the left foot, onychomycosis; B) Detail demonstration the constricting circular fibrotic band, onychomycosis and hyperkeratosis of the cuticle

## Discussion

Ainhum (dactylosis spontanea) is a rare mutilating disorder of fingers and toes, most frequently seen in Africans. Ainhum develops in four stages. In the beginning, a clavus progresses to an annular fissure or band around the digit. While the soft tissue constriction gets more pronounced, the digit becomes globular distal to the groove. This is associated with bone resorption and arterial narrowing. Stage 3 describes a very painful bone separation at the joint with hypermobility of the distal part of the digit. In stage 4 a bloodless auto-amputation of the toe happens, which is associated with severe pain [7].

The major differential diagnosis of ainhum is pseudo-ainhum. Pseudo-ainhum is defined as any case of auto-amputation not associated with the classic spontaneous ainhum seen in Africans with unknown etiology. Grading is similar to ainhum [8]. Pseudo-ainhum has been described secondary to congenital amniotic bands known as Streeter's syndrome [9] or keratoderma hereditarium mutilans (Vohwinkel) [10]. Pseudo-ainhum can also occur as a very rare complication of infectious diseases (lues, leprosy or yaws), ichthyosis, scleroderma, or ischemia [11], [12], [13]. This is the second report about pseudo-ainhum and liver cirrhosis [6]. In liver cirrhosis, liver parenchyma is replaced by excess extra-cellular matrix leading to tissue fibrosis. The pro-fibrinogenic cytokines platelet-derived growth factor and transforming growth factor- $\beta$ 1 stimulate the production of collagen, noncollagenous glycoproteins, proteoglycans, and glycosaminoglycans while matrix-metalloproteinases are downregulated [1]. Tissue fibrosis is also involved in pseudo-ainhum, but the target cells are skin fibroblasts instead of hepatic stellate cells and hepatic myofibroblasts.

Treatment guidelines do not exist for pseudo-ainhum. Dependent on the underlying pathology and stage, systemic retinoids or surgery have been reported [14], [15], [16]. In the present case, retinoids were contraindicated. Surgery was not recommended due to the hepatic impairment of blood coagulation

and the general medical situation of the patient.

## References

- Romanelli RG, Stasi C. Recent advancements in diagnosis and therapy of liver cirrhosis. *Curr Drug Targets*. 2016; 17(15):1804-1817. <https://doi.org/10.2174/1389450117666160613101413> PMID:27296314
- Sanglodkar U, Jain M, Jothimoni D, Parida S, G B, Venkataraman J. Cellulitis in liver cirrhosis - a series of 25 cases from southern India. *Clin Exp Hepatol*. 2018; 4(3):201-204. <https://doi.org/10.5114/ceh.2018.78125> PMID:30324146 PMCid:PMC6185931
- Chiba T, Hayashi F, Shinmura M, Kiyomatsu M, Tatematsu S, Nakao M, Furue M. Yellow urticaria in a patient with hepatic cirrhosis. *G Ital Dermatol Venereol*. 2014; 149(3):381-2.
- Dogra S, Jindal R. Cutaneous manifestations of common liver diseases. *J Clin Exp Hepatol*. 2011; 1(3):177-84. [https://doi.org/10.1016/S0973-6883\(11\)60235-1](https://doi.org/10.1016/S0973-6883(11)60235-1)
- Muehrcke RC. The finger-nails in chronic hypoalbuminaemia; a new physical sign. *Br Med J*. 1956; 1(4979):1327-8. <https://doi.org/10.1136/bmj.1.4979.1327> PMID:13316143 PMCid:PMC1980060
- Wollina U, Graefe T, Oelzner P, Hein G, Schreiber G. Pseudoainhum of all fingers associated with Reynolds' syndrome and breast cancer: report of a case and review of the literature. *J Am Acad Dermatol*. 2001; 44(2 Suppl):381-4. <https://doi.org/10.1067/mjd.2001.104971> PMID:11174422
- Daccarett M, Espinosa G, Rahimi F, Eckerman CM, Wayne-Bruton S, Couture M, Rosenblum J. Ainhum (dactylosis spontanea): a radiological survey of 6000 patients. *J Foot Ankle Surg*. 2002; 41(6):372-8. [https://doi.org/10.1016/S1067-2516\(02\)80083-7](https://doi.org/10.1016/S1067-2516(02)80083-7)
- Rashid RM, Cowan E, Abbasi SA, Brieva J, Alam M. Destructive deformation of the digits with auto-amputation: a review of pseudo-ainhum. *J Eur Acad Dermatol Venereol*. 2007; 21(6):732-7. <https://doi.org/10.1111/j.1468-3083.2007.02224.x> PMID:17567298
- Piccolo V, Corneli P, Piccolo S, Zalaudek I, Argenziano G, Russo T. Pseudo ainhum and facial malformation secondary to Streeter's dysplasia. *J Eur Acad Dermatol Venereol*. 2019. <https://doi.org/10.1111/jdv.15757> PMID:31222806
- Bassetto F, Tiengo C, Sferrazza R, Belloni-Fortina A, Alaibac M. Vohwinkel syndrome: treatment of pseudo-ainhum. *Int J Dermatol*. 2010; 49(1):79-82. <https://doi.org/10.1111/j.1365-4632.2009.04267.x> PMID:20465619
- Behera B, Gochhait D, Thappa DM. Pseudoainhum and autoamputation associated with lamellar ichthyosis. *Indian J Dermatol Venereol Leprol*. 2017; 83(6):728-729. [https://doi.org/10.4103/ijdvl.IJDVL\\_56\\_17](https://doi.org/10.4103/ijdvl.IJDVL_56_17) PMID:28936990
- Silva M, Ribeiro R, Oliveira J. Pseudoainhum in systemic sclerosis. *J Rheumatol*. 2016; 43(11): 2076. <https://doi.org/10.3899/jrheum.160239> PMID:27803345
- Dasari BV, McBrearty A, Lau L, Lee B. Pseudoainhum of the toe with underlying chronic lower-limb ischemia. *Int J Low Extrem Wounds*. 2011; 10(2):96-7. <https://doi.org/10.1177/1534734611409369> PMID:21693445
- Richey PM, Stone MS. Resolution of pseudoainhum with acitretin therapy in a patient with palmoplantar keratoderma and congenital alopecia. *JAAD Case Rep*. 2019; 5(3):219-221. <https://doi.org/10.1016/j.jidcr.2018.12.004> PMID:30809564 PMCid:PMC6374960
- Pisoh T, Bhatia A, Oberlin C. Surgical correction of pseudo-ainhum in Vohwinkel syndrome. *J Hand Surg Br*. 1995; 20(3):338-41. [https://doi.org/10.1016/S0266-7681\(05\)80090-7](https://doi.org/10.1016/S0266-7681(05)80090-7)
- Zamiri M, Watson S. Loricrin palmoplantar keratoderma: full-thickness skin grafting for pseudoainhum. *Clin Exp Dermatol*. 2019; 44(4):444-446. <https://doi.org/10.1111/ced.13770> PMID:30264492

# A Sheep in Wolf's Clothing: Lobular Pyogenic Granuloma Masquerading Nodular Amelanotic Melanoma

Jacqueline Schönlebe<sup>1</sup>, Uwe Wollina<sup>2\*</sup>

<sup>1</sup>*Institute of Pathology "Georg Schmorl", Städtisches Klinikum Dresden, Academic Teaching Hospital, Dresden, Germany;*

<sup>2</sup>*Department of Dermatology and Allergology, Städtisches Klinikum Dresden, Academic Teaching Hospital, Dresden, Germany*

## Abstract

**Citation:** Schönlebe J, Wollina U. A Sheep in Wolf's Clothing: Lobular Pyogenic Granuloma Masquerading Nodular Amelanotic Melanoma. Open Access Maced J Med Sci. 2019 Sep 30; 7(18):3015-3017. <https://doi.org/10.3889/oamjms.2019.417>

**Keywords:** Amelanotic melanoma; Pyogenic granuloma; Histology; Treatment

**\*Correspondence:** Uwe Wollina, Department of Dermatology and Allergology, Städtisches Klinikum Dresden, Academic Teaching Hospital, Dresden, Germany. E-mail: [Uwe.Wollina@klinikum-dresden.de](mailto:Uwe.Wollina@klinikum-dresden.de)

**Received:** 30-Jul-2019; **Revised:** 04-Aug-2019; **Accepted:** 15-Aug-2019; **Online first:** 30-Aug-2019

**Copyright:** © 2019 Jacqueline Schönlebe, Uwe Wollina. This is an open-access article distributed under the terms of the Creative Commons Attribution-NonCommercial 4.0 International License (CC BY-NC 4.0)

**Funding:** This research did not receive any financial support

**Competing Interests:** The authors have declared that no competing interests exist

**BACKGROUND:** Tumor masquerading is a common phenomenon seen in clinical dermatology. While amelanotic melanoma is known to simulate pyogenic granuloma, a benign vascular tumour, the contrary has been reported exceptionally scarce.

**CASE PRESENTATION:** We present a 52-year-old woman with a slow-growing lesion on her right flank, which developed over 12 months. On examination, we observed a large exophytic, easily bleeding tumour on the right flank, that resembled amelanotic malignant melanoma. Histologic analysis after complete excision of the lesion confirmed a pyogenic granuloma of the lobular capillary hemangioma subtype. In the present case masquerading of the lesion went to the better site after histologic investigations despite the delay of diagnosis caused by the patients.

**CONCLUSION:** Nevertheless, the diagnosis of uncertain lesions needs a rapid histologic analysis to gain the best possible prognosis for the patient.

## Introduction

Pyogenic granuloma (syn. telangiectatic granuloma) is a common benign vascular tumour [1]. Genetic studies suggested that pyogenic granuloma is resulting from tissue injury, followed by an impaired wound healing response, during which vascular growth is driven by two major factors: (a) the ms-related tyrosine kinase 4, also known as FLT4, and (b) the nitric oxide pathway. The *FLT4* gene encodes a tyrosine kinase receptor for vascular endothelial growth factors C and D involved in angiogenesis [2]. Furthermore, BRAF mutations and probably herpes virus type 1, Orf virus and/or human papillomavirus type 2 may play a role in its pathogenesis [1].

Cawson et al., (1998) have described two subtypes depending on the rate of proliferation and vascularity: (a) lobular capillary hemangioma and (b) non-lobular capillary hemangioma. In the latter,

perivascular mesenchymal cells remain negative for alpha-smooth muscle actin but develop a vascular core that resembles granulation tissue [3]. They demonstrate a typical trajectory, starting with a cellular phase that transforms into capillary and eventually involution phase. Since malignancies such as melanoma and sarcoma can masquerade as pyogenic granuloma, early diagnosis and treatment may be life-saving [4].

## Case Report

A 52-year-old woman presented with an easy bleeding exophytic lesion on her right flank.

She reported that the nodule had been grown for about 12 months. During the last weeks, the lesion started bleeding. Therefore, she consulted her doctor.

On examination, we observed an exophytic nodular, auburn tumour, easily bleeding, with a size of 3 x 2.7 cm (Figure 1). Dermoscopy was hampered by bleeding. The patient had no current medications and was otherwise healthy. The working hypothesis was a possible amelanotic melanoma. Tumour staging with imaging techniques (diagnostic ultrasound and X-ray) did exclude any metastatic spread. The lesion was completely surgically removed. The defect was closed by a large skin advancement flap. Healing was uneventful.

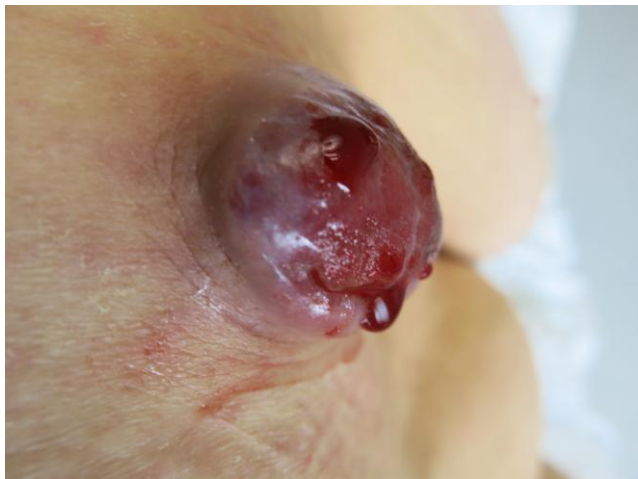

Figure 1: Clinical presentation of a large exophytic polypoid bleeding tumour

Histologic examination revealed a tumour thickness of 3.3 cm. The tumour was covered by a pseudo-capsule. We noticed a lobular vascular tumour with some larger vessels and numerous capillaries. There was a peripheral connective tissue septa formation. Numerous clumsy, partly epithelioid endothelial cells lined capillaries (Figure 2). Mitotic endothelial cells reactive with Ki67 were noticed. Several cavernous enlarged vascular spaces were located in the periphery. Thrombotic vascular obstructions could also be seen, some vessels with partial recanalisation.

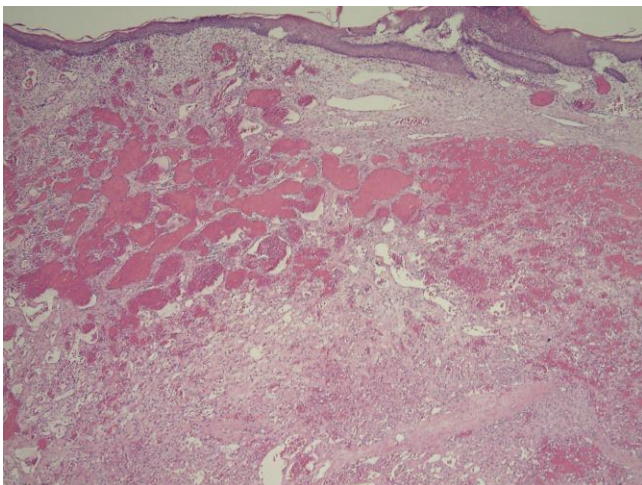


Figure 2: Histopathology of pyogenic granuloma demonstrating a lobular vascular structure (Hematoxylin-eosin x 2)

Endothelial cells were positive for CD31 and CD34, but completely negative for D2-40, human herpes virus-8 and c-Myc (Figure 3 and 4). The intra-tumoral vessels were surrounded by smooth muscle-actin positive pericytes. Tumour resection was complete (R0).

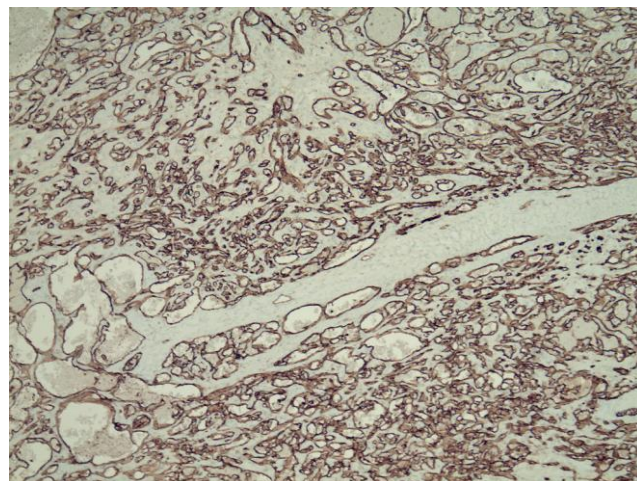


Figure 3: Immunohistology with a monoclonal antibody against CD31 staining the tumour vessels (Immunoperoxidase, x 4)

The diagnosis of a large lobular pyogenic granuloma was made.

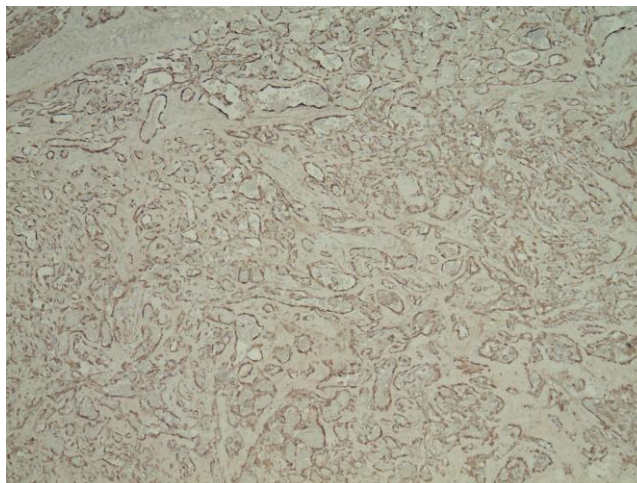


Figure 4: Immunohistology with a monoclonal antibody against smooth muscle actin staining the perivascular cells around tumour vessels (Immunoperoxidase, x 4)

## Discussion

We reported a pyogenic granuloma mimicking AMM. This is a very rare observation. Charles and Kahn (2017) observed an infarcted tarsal pyogenic granuloma simulating melanoma in a 34-year older adult [5]. Zaballos et al., (2009) reported about an 18-year old male with a crusted lesion on the thorax measuring about 1 cm, which could not be



distinguished from melanoma by dermoscopy [6].

This group tried to define typical dermoscopic patterns for pyogenic granuloma and its differential diagnosis. Vascular structures were observed in 45% of pyogenic granulomas but with low sensitivity and specificity. The pattern composed of 'reddish homogeneous area', 'white rail lines' and 'vascular structures' showed the highest sensitivity (22.1%) and specificity (100%) for pyogenic granuloma [7]. Other lesions that might masquerade melanoma include small atypical congenital melanocytic nevi [8] and hypercellular encapsulated neuroma [9].

In contrast, amelanotic melanoma (AMM) may simulate pyogenic granuloma. AMM account for a small proportion of all melanomas, i.e. between 1.8% to 8.1% [10]. Due to the lack of typical clinical features of melanoma, they pose a risk of delayed diagnosis and poor prognosis. In a large study of 2038 patients diagnosed with melanoma, about 0.5% had a pyogenic granuloma-like AMM. The mean age at diagnosis was 56 years, and the meantime from lesion appearance to diagnosis was  $91.5 \pm 117.1$  months. Nine tumours were located on the skin surface, and one on the oral mucosa. The mean Breslow's depth was  $6.47 \pm 3.1$  mm. At diagnosis, 70% of patients had lymph node involvement or distant metastasis; two patients died of AMM within 12 months of diagnosis [11].

In conclusion, masquerading of other lesions, may they be benign or malignant, is a phenomenon that is not uncommon in clinical dermatology. It is important to be aware of this. We recommend a histologic analysis in case of suspected AMM and pyogenic granuloma to avoid diagnostic delay and to prevent a poor prognosis. Our patient was lucky because the suspected malignant tumour could be eliminated from suspected tumours and the healing was complete after surgical excision.

## References

- Godfraind C, Calicchio ML, Kozakewich H. Pyogenic granuloma, an impaired wound healing process, linked to vascular growth driven by FLT4 and the nitric oxide pathway. *Mod Pathol*. 2013; 26:247-55. <https://doi.org/10.1038/modpathol.2012.148> PMID:22955520
- Wollina U, Langner D, França K, Gianfaldoni S, Lotti T, Tchernev G. Pyogenic granuloma - a common benign vascular tumor with variable clinical presentation: new findings and treatment options. *Open Access Maced J Med Sci*. 2017; 5:423-6. <https://doi.org/10.3889/oamjms.2017.111> PMID:28785323 PMID:PMC5535648
- Cawson RA, Binnie WH, Speight PM, Barrett AW, Wright JM. *Lucas Pathology of Tumors of Oral Tissues*. 5th. St. Louis, Mo, USA: Mosby, 1998.
- Marla V, Shrestha A, Goel K, Shrestha S. The histopathological spectrum of pyogenic granuloma: a case series. *Case Rep Dent*. 2016; 2016:1323798. <https://doi.org/10.1155/2016/1323798> PMID:27382492 PMID:PMC4921146
- Charles NC, Kahn JB. Infarcted tarsal pyogenic granuloma simulating malignant melanoma. *Ophthalmic Plast Reconstr Surg*. 2017; 33(3S Suppl 1):S33-4. <https://doi.org/10.1097/IOP.0000000000000525> PMID:26164159
- Zaballos P, Rodero J, Serrano P, Cuellar F, Guionnet N, Vives JM. Pyogenic granuloma clinically and dermoscopically mimicking pigmented melanoma. *Dermatol Online J*. 2009; 15:10.
- Zaballos P, Carulla M, Ozdemir F, Zalaudek I, Bafiuls J, Llambrich A, Puig S, Argenziano G, Malvey J. Dermoscopy of pyogenic granuloma: a morphological study. *Br J Dermatol*. 2010; 163:1229-37. <https://doi.org/10.1111/j.1365-2133.2010.10040.x> PMID:20846306
- Tchernev G, Chokoeva AA, Terziev I, Grigorov Y, Lotti T, Wollina U, Cardoso JC, Yungareva I, Lozev I, Maximov GK. Small dysplastic congenital melanocytic nevi in childhood as possible melanoma imitators. *Open Access Maced J Med Sci*. 2018; 6:149-51. <https://doi.org/10.3889/oamjms.2018.018> PMID:29484015 PMID:PMC5816289
- May C, LeBoit P, McCalmont T, Argenyi Z. Hypercellular encapsulated neuroma imitating desmoplastic melanoma. *Am J Dermatopathol*. 2019; 41:358-60. <https://doi.org/10.1097/DAD.0000000000001302> PMID:30531539
- Koch SE, Lange JR. Amelanotic melanoma: the great masquerader. *J Am Acad Dermatol*. 2000; 42:731-4. <https://doi.org/10.1067/mjd.2000.103981> PMID:10775846
- Moshe M, Levi A, Ad-El D, Ben-Amitai D, Mimouni D, Didkovsky E, Feinmesser M, Lapidot M. Malignant melanoma clinically mimicking pyogenic granuloma: comparison of clinical evaluation and histopathology. *Melanoma Res*. 2018; 28:363-7. <https://doi.org/10.1097/CMR.0000000000000451> PMID:29750750

# Treatment of Psoriasis: Novel Approaches to Topical Delivery

Uwe Wollina<sup>1\*</sup>, Michael Tirant<sup>2</sup>, Aleksandra Vojvodic<sup>3</sup>, Torello Lotti<sup>2</sup>

<sup>1</sup>Department of Dermatology and Allergology, Städtisches Klinikum Dresden, Academic Teaching Hospital, Dresden, Germany; <sup>2</sup>Department of Dermatology, University of Rome "G. Marconi", Rome, Italy; <sup>3</sup>Military Medical Academy of Belgrade, Belgrade, Serbia

## Abstract

**Citation:** Wollina U, Tirant M, Vojvodic A, Lotti T. Treatment of Psoriasis: Novel Approaches to Topical Delivery. Open Access Maced J Med Sci. 2019 Sep 30; 7(18):3018-3025.  
<https://doi.org/10.3889/oamjms.2019.414>

**Keywords:** Topical drug therapy; Psoriasis; Nanoparticles; Laser-assisted drug delivery; Foams; Niosomes; Ethosomes

**\*Correspondence:** Uwe Wollina, Department of Dermatology and Allergology, Städtisches Klinikum Dresden, Academic Teaching Hospital, Dresden, Germany. E-mail: [uwollina@gmail.com](mailto:uwollina@gmail.com)

**Received:** 12-Jul-2019; **Revised:** 04-Jul-2019; **Accepted:** 15-Jul-2019; **Online first:** 30-Aug-2019

**Copyright:** © 2019 Uwe Wollina, Michael Tirant, Aleksandra Vojvodic, Torello Lotti. This is an open-access article distributed under the terms of the Creative Commons Attribution-NonCommercial 4.0 International License (CC BY-NC 4.0)

**Funding:** This research did not receive any financial support

**Competing Interests:** The authors have declared that no competing interests exist

Topical treatment is the cornerstone for the management of mild to moderate psoriasis. Despite efforts in drug development, patient's satisfaction with the available topical treatments is limited. A strategy to improve safety, efficacy and comfort of topical treatment provides the development of new drug delivery and drug carrier systems. This review provides an overview of recent advances in this field with a focus on psoriasis. Laser-assisted drug delivery, foam formulations, nanoparticles, ethosomes, and niomes are considered. Hopefully, these new developments will improve topical drug therapy and patient satisfaction.

## Introduction

Easy accessibility of skin is a major factor for topical treatment. Topical drug delivery is depended on skin barrier properties, physicochemical properties of drug and vehicle, and interaction between drug and its vehicle with the skin layers. Penetration into intact skin is usually limited to hydrophilic substances smaller than 500 Da. This explains why highly hydrophilic or highly lipophilic compounds or such compounds with a higher molecular weight are much less suitable for conventional topical drug therapy [1].

Psoriasis is a chronic inflammatory skin disease affecting about 2% of the world population that harms various dimensions of quality of life of patients [2]. Topical drug therapy is the cornerstone in the treatment of mild to moderate psoriasis. It offers a direct targeting of affected skin by avoiding systemic adverse events. However, patient satisfaction with

available treatments remains modest [3].

There are three major pathways by which drug release into the skin and into the systemic circulation by topical application have to be considered: (a) percutaneous absorption - the passage of topically applied materials into the skin, (b) percutaneous penetration - the passage of material from the stratum corneum surface through the skin to the systemic circulation, and (c) permeation - the passage of material through a skin by diffusion or by pores.

Percutaneous penetration is measured by in vitro skin models such as skin disks, human or animal tissue samples in special skin chambers. Percutaneous penetration measurements are performed in vivo in animal models or humans since they are dependent on blood circulation. Drug concentrations are usually measured by high-performance liquid chromatography (HPLC) or mass

spectrometry [4]. Proton nuclear magnetic resonance ( $^1\text{H}$  NMR) spectroscopy allows the characterisation of the most represented proton-containing low-molecular-mass compounds in a biological sample and their representation in a spectrum [5].

In recent years, several technologies have been developed to enhance the efficacy and safety of topical drug therapy. Furthermore, new drug carriers offer the opportunity to introduce new molecules into topical psoriasis therapy. For these purposes, vesicular drug delivery systems including niosomes, proniosomes, liposomes and transferosomes, nonvesicular drug delivery systems such as foams, gels, and nanoparticles have been developed [6]. Hopefully, by using these new technologies, better patient satisfaction with topical treatment could be achieved.

## Ablative Fractional Lasers

Fractional ablative lasers can enhance the permeation of topical drugs into the skin through microscopic ablation zones (MAZs) of precise dimensions. At this moment, the skin barrier can be negotiated, and drug delivery markedly improved [7].

Several studies investigated topical methotrexate. Methotrexate is a folic acid analogue. The mechanism of action is the inhibition of 5-aminimidazole-4-carboxamide ribonucleotide transformylase, thus increasing intracellular and extracellular adenosine which has anti-inflammatory activity. Methotrexate has been used for a long time in the systemic treatment of both psoriasis and psoriasis arthritis. In contrast to its use in oncology, methotrexate is used just once a week in low dosages (usually 7.5-25 mg) orally, subcutaneously or intravenously in both indications [8]. Systemic treatment, however, is limited by possible methotrexate toxicities [9].

A systematic in vitro study with a low-power 2,940 nm ablative fractional erbium YAG laser investigated the correlation between laser parameters and tissue. Deeper MAZ depth increased the concentration of methotrexate in the deeper tissue layer. The biodistribution of the drug was surprisingly not compromised by coagulation zones of various thickness around MAZ. The ratio of skin deposition versus transdermal permeation was constant, not depending on the MAZ depth. Methotrexate distributed radially from the MAZ. Saturation of the skin occurred after 7 hours at a ten-fold concentration compared to intact skin [10].

The same technique can be applied to the treatment of nail psoriasis [11].

In a clinical trial using nanoparticulated

methotrexate in jojoba oil-based microemulsion, fractional erbium YAG laser resulted in a faster clinical response compared to intact skin, i.e. 3 weeks vs 8 weeks [12].

## Foams

Foams are colloids composed of two or three distinct phases: hydrophilic liquid continuous phase with a foaming agent, throughout which a gaseous dispersion phase is distributed, and sometimes a third hydrophobic dispersed phase. Pharmaceutical aerosol foams commonly exhibit three transition states: liquid in the can, propellant/aerosol as it leaves the can and foam on the skin of the patient [13].

A fixed combination of calcipotriol and betametasone dipropionate is on the market and found to superior to betamethasone ointment [14]. Betamethasone dipropionate in micronised particles can be easily suspended homogeneously. Calcipotriol, on the other hand, is a greater challenge and needs to be dissolved in a carefully selected vehicle component to ensure even distribution. The product contains an emollient vehicle base, with calcipotriol and betamethasone dissolved in a mixture of volatile propellants, butane and dimethyl ether. Dimethyl ether also acts as a solvent that enhances the solubility of the active ingredients allowing them to dissolve completely. It has been demonstrated that this anti-psoriatic foam formulation is more effective at week 12 than systemic methotrexate or acitretin, and it is more effective at week 16 as systemic apremilast measured by the PASI75 response [15].

## Nanofibres

Curcumin is a herbal substance with anti-inflammatory activities, that is of interest also in topical psoriasis therapy [16]. Cellulose nanofiber (CNF) is a biocompatible biomaterial with film-forming properties and excellent mechanical properties. Fibres of a diameter of approximately 500 nm were embedded in a composition containing shea butter and Capmul MCM EP and loaded with curcumin (liquid@CNF). They employed a variety of analytical methods including scanning and transmission electron microscopy, Fourier transform infrared spectroscopy, also known as FTIR analysis. The FTIR analysis method uses infrared light to scan test samples and observe chemical properties. X-ray photoelectron spectroscopy was used to analyse the surface chemistry of the curcumin preparation. Besides, atomic force microscopy was used to measure the

local properties of curcumin-CSF. In a mouse model with imiquimod-induced psoriasis-like dermatitis, deposition of curcumin was increased 2-fold compared with films missing the lipid component. Curcumin-CNF improved dermatitis *in vivo* including a reduction of pro-inflammatory cytokines in a range close to commercially available topical corticosteroids. Furthermore, the films had a skin hydration effect [17].

## Nanoparticles and Nano Emulsions

Another option to overcome skin barrier is the use of nanoparticles, especially for hydrophilic compounds. The most commonly used nanoparticles for topical drug delivery are polymeric nanoparticles, nano-emulsions, liposomes and solid lipid nanoparticles, metal nanoparticles, and dendrimers. Nanoparticles are used to enhance the solubility of highly hydrophobic drugs. They provide a sustained and controlled release of drugs while increasing their stability. Nanoparticles are capable of delivering higher concentrations of drugs to target areas. Nanoparticles can accumulate in hair follicles and thereby overcome the skin barrier [18].

Curcumin-loaded nanoparticles (NPs) made of poly (lactic-co-glycolic acid) with a mean particle size of 50 nm and 150 nm. *In vitro*, these NPs exerted a stronger anti-proliferative activity of human HaCaT keratinocytes than curcumin alone. Psoriatic skin samples were used for *in vitro* penetration studies. Curcumin-loaded NPs delivered more curcumin into the skin than curcumin hydrogel. Curcumin-loaded NPs was investigated *in vivo* in the imiquimod-induced mouse model versus tacrolimus cream. Clinical symptoms, histology and inflammatory cytokines improved most with curcumin-loaded NPs with 50 nm NPs reaching the most pronounced effects [19].

An amphiphilic polymer, RRR- $\alpha$ -tocopheryl succinate-grafted- $\epsilon$ -polylysine conjugate (VES-g- $\epsilon$ -PLL), was synthesised and self-assembled into skin penetrating polymeric NPs with a hydrodynamic diameter of only 24.4 nm. In these NPs curcumin could effectively be encapsulated with a drug loading capacity of 3.49% and an encapsulating efficiency of 78.45%. Silk fibroin was used as a hydrogel-based matrix to enhance further topical delivery of curcumin-NPs, which resulted in a slower release. *In vivo* studies on imiquimod-induced psoriasis-like dermatitis in mice, curcumin-NPs-silk fibroin gel demonstrated a high skin-permeating capability and a stronger anti-inflammatory activity. This was investigated by inhibitory effects on the expression of pro-inflammatory cytokines such as tumour necrosis factor- $\alpha$  (TNF $\alpha$ ), nuclear factor- $\kappa$ B and interleukin-6) [20].

Bacterial cellulose (BC) represents an

interesting biocompatible nanomaterial. BC can be easily manipulated to improve its properties and/or functionalities resulting in several BC-based nanocomposites such as BC/collagen, BC/gelatin, BC/fibroin, BC/chitosan. Bacterial cellulose/carboxymethylcellulose (BC / CMC) biocomposite nanofibers can also serve as drug carriers. This was investigated using methotrexate, a conventional systemic antipsoriatic drug with antifolate activity. Biocomposites loaded with methotrexate may be used as an alternative for the topical treatment of psoriasis. There was a decrease in the elastic modulus as the degree of substitution of CMC increased. Intermediate substitute CMC grade led to a slightly decreased MTX release rate, suggesting that the degree of substitution of CMC is a key factor to modulate the biocomposite properties [21].

Spherical methotrexate-loaded chitin nanogel (MCNG) with a particle size of 196 nm was formulated for topical use in psoriasis. Exposure of HaCaT keratinocytes and THP-1 cells to MCNG showed a significant level of cellular toxicity. MCNGs inhibited COX-2 and LOX-5 enzymes expressed in THP-1 cells. Skin permeation studies revealed an increased transdermal flux of methotrexate from MCNG in comparison with methotrexate solution treated samples. Furthermore, it could be shown that MCNG exerted anti-psoriatic efficacy on an imiquimod-induced mouse model of psoriasis. No dermal and systemic toxicities were reported [22].

Pentoxifylline (PTX) is an anti-inflammatory activity compound and exerts inhibitory activity against TNF $\alpha$ , one of the major proinflammatory cytokines involved in psoriasis. Therefore, it is of potential interest in topical psoriasis therapy — colloidal nanostructured lipid carriers (NLCs) with a size of less than 200 nm. PTX was loaded and encapsulated to the extent of 10% and 90% in the NLCs. *In vitro* studies suggested high retention of PTX in the skin (84%). *In vivo*, imiquimod-induced psoriasis in the mouse model was employed. PTX-loaded NLCs demonstrated a significant improvement of histological changes in the affected epidermis [23].

In contrast to PTX, topical corticosteroids are established drugs in psoriasis therapy. They are the cornerstone of topical outpatient treatment worldwide. Mometasone furoate-loaded NLCs with a droplet size of approximately 160 nm, a zeta potential-0.086 mV and entrapment efficiency of 60.0 % were transformed into a hydrogel using Carbopol 940 to optimise viscosity for topical use. Drug permeation studies showed prolonged drug release as compared to commercial mometasone formulation. The mometasone skin concentration was 2.5-fold higher than commercial corticosteroids. *In vivo* studies in imiquimod induced skin inflammation in Wistar rats demonstrated the absence of parakeratosis in mometasone-loaded NLC treated lesions [24].

Nanogels are water-soluble cross-linked polymer networks with nanometer-size dimensions. They can be designed to incorporate different types of anti-psoriatic compounds and are promising carrier systems for topical drug delivery. Gels produced with macromolecules and fibres can be classified as polymers with molecules attached to the fibres throughout the gel resulting in a polymer (chemical gel) or supramolecular gels (physical gels), in which smaller molecules are attached via van der Waals interactions, hydrogen bonds or coulombic forces [25]. While chemical gels are robust materials, physical gels are more suitable for drug delivery. These gels are also softer. While most physical gels are made by polymeric subunits, low-molecular-weight gelators (LMWGs) are smaller molecules that self-assemble to form fibres. Such gels have qualities that made them interesting for drug delivery, such as thermoreversibility and degradability [26].

Bis-imidazolium (1:2 Br) salts are cationic surfactants that could form micelles and deliver anionic drugs. The electrostatic attraction between the positively charged surfactant and the negatively charged drug is responsible for a slow but sustained release of the drug [27]. Triamcinolone acetonide and betamethasone 17-valerate are commonly used topical corticosteroid for inflammatory skin disorders such as psoriasis. The 1:2 Br carrier material permitted a high level of drug release and did not limit permeation of the drug into human skin as measured by Franz cells. Gels derived from 1:2 Br released up to three times more triamcinolone or betamethasone than two commercial products, which served as controls. Also, the speed of drug release was ten times faster if they were incorporated in gel 1:2 Br. Permeation studies using Franz cells show that gel 1:2 Br promotes the entry of the drug through the skin four times more rapidly than the commercial formulations. The gel also promotes retention of the drug in the skin two times (betamethasone) and 20-fold (triamcinolone) more than the commercial formulations. In conclusion, 1:2 Br carrier material ensures a faster action and higher bioavailability to the pharmacological target [28].

Further investigations demonstrated that several other possible compounds for topical psoriasis therapy could also be included and stabilised in nanostructures supramolecular gels such as methotrexate or tacrolimus [29].

PUVA-therapy – 8-methoxy psoralen (8MOP) plus ultraviolet A irradiation – is an established treatment for psoriasis, vitiligo and cutaneous T-cell lymphoma amongst other dermatoses [30].

8MOP has been incorporated into a nanoemulsion (NE) that showed a mean droplet diameter of  $24.98 \pm 0.49$  nm, polydispersity index of  $0.091 \pm 0.23$ , pH values of  $6.54 \pm 0.06$ , the refractive index of  $1.3525 \pm 0.0001$ , and apparent viscosity of  $51.15 \pm 3.66$  mPa at  $20^\circ\text{C}$ . The formulation was

characterised by *ex vivo* permeation study using porcine skin with fluorescence HPLC and transmission electron microscopy, to determine the amount of drug retained in stratum corneum, viable epidermis, and dermis. *Ex vivo* permeation revealed that 8.5% of the applied 8MOP dose permeated through the biological membranes, with a flux of  $1.35 \mu\text{g cm}^{-2} \text{h}^{-1}$ . The drug retention in viable epidermis and dermis was twice as high as normal cream with  $10.15 \pm 1.36 \mu\text{g cm}^{-2}$  compared to stratum corneum with  $1.95 \pm 0.71 \mu\text{g cm}^{-2}$ , respectively [31].

Since NE may have a relatively low viscosity, hydrogel-thickened NEs using chitosan have been prepared to improve topical applicability. The size of chitosan molecules influences drug release [32].

Cignolin (syn. dithranol or anthralin) is the most potent topical drug in psoriasis therapy with the longest remission times [33]. However, skin irritation and staining hamper its broader use. Microsponges as delivery systems for cignolin may overcome these problems. In one study, microsponges were composed of poly (amido) amine dendrimers, ethylcellulose, polyvinyl alcohol, dichloromethane, sodium metabisulphate, and distilled water. *In vitro* studies demonstrated that such a formulation could prevent autooxidation of cignolin. Microsponge gel of dithranol may provide further advantages of reduced side effects, increased elegance, enhanced formulation flexibility, and modified drug release [34].

Cignolin has also been used with NLCs for better application and efficacy. Cignolin-loaded NLCs were prepared by hot-melt homogenization with particle size  $< 300$  nm, polydispersity index (PDI)  $< 0.3$  and percentage entrapment efficiency of  $\sim 100\%$ . The NLCs were loaded into a gel and evaluated for drug release, spreadability, rheological behaviour, and staining. Anti-psoriatic efficacy was evaluated in the imiquimod-induced psoriatic plaque model in comparison with conventional 1.15% w/w cignolin ointment. Topical application of cignolin-loaded NLC gel reduced the PASI score. There was a significant reduction in IL-17, 22, 23 and TNF $\alpha$  as measured by enzyme-linked immunosorbent assays [35].

Cyclosporine A (CsA) is a calcineurin inhibitor which acts on T-cells and is an effective systemic treatment for psoriasis. However, systemic administration of CsA can cause dose-dependent toxic effects, which may be circumvented by topical drug delivery. Topical use, however, is hindered by its high molecular weight of 1,202 Da [36].

Recently a topical liposomal gel containing CsA loaded cationic liposomal nanocarriers has been developed. Optimised liposomal carriers prepared by the ethanol injection method were loaded with CsA and applied in a gel formulation on imiquimod-induced plaque model. Thereby, clinical symptoms could be improved, and key pro-inflammatory cytokines for psoriasis such as tumour necrosis factor- $\alpha$ , IL-17, and IL-22 were reduced [37].

A CsA-loaded microemulsions using oleic acid as oil phase, either Tween®80 or a soluble derivative of vitamin E (TPGS) as surfactants and either Transcutol®, propylene glycol or 1,3 propanediol as co-surfactants. Several Tween®80-based and 4 TPGS-based formulations were tested *ex vivo*, loaded with 6 mg/g CsA and applied *ex-vivo* on porcine skin for 22 h. A 3- or 6-fold higher cutaneous accumulation compared with CsA in propylene glycol could be obtained by a low-viscosity Tween®80-based microemulsion ( $9.78 \pm 3.86 \mu\text{g cm}^{-2}$ ) and with a high viscosity TPGS-based microemulsion ( $18.3 \pm 5.69 \mu\text{g cm}^{-2}$ ), respectively. The uptake of CsA by porcine skin was noted as early as two hours after application [38].

Another study investigated CsA-loaded polymeric micelles using the biodegradable and biocompatible MPEG-dihexPLA diblock copolymer. These polymeric micelles deliver CsA without penetrating the skin. They increased the aqueous solubility of CsA by 518-fold. Supra-therapeutic amounts of CsA were delivered to human skin ( $1.4 \pm 0.6 \mu\text{g cm}^{-2}$ ) after application of the formulation with 1.67 mg/ml CsA and 5 mg/ml copolymer for the only 1h without transdermal permeation. The micelles were preferentially deposited between corneocytes and in between the clusters of corneocytes [39].

Tacrolimus is a specific calcineurin inhibitor approved for atopic dermatitis and with moderate antipsoriatic activity for intertriginous psoriasis [40]. It suffers from poor cutaneous bioavailability when administered topically as protopic ointment. Therefore, polymeric micelles using methoxy-poly (ethylene glycol)-dihexyl substituted polylactide (MPEG-dihexPLA) diblock copolymer loaded with 0.1% tacrolimus was investigated *in vitro*. Delivery experiments using human skin resulted in significantly greater tacrolimus deposition compared to protopic 0.1% ointment, i.e.  $1.50 \pm 0.59$  versus  $0.47 \pm 0.20 \mu\text{g cm}^{-2}$ ). The increase in cutaneous drug concentrations was due to improved drug load of stratum corneum, viable epidermis, and upper dermis, while the copolymer was unable to penetrate the stratum corneum. Preferential deposition of tacrolimus-loaded micelles into the hair follicle was also documented [41].

Another study investigated a hybrid system based on nicotinamide (NIC) and nanoparticles (NPs) encapsulating tacrolimus to improve percutaneous drug delivery. NIC increased both the solubility and permeability of tacrolimus. NIC demonstrated self-assembly with amphiphilic hyaluronic acid-cholesterol conjugates. These NPs showed a higher encapsulation efficiency of  $79.2\% \pm 4.2\%$ , and the combination of NPs with NIC exhibited a significant synergistic effect on tacrolimus absorption within the skin ( $2.39 \pm 0.53 \mu\text{g cm}^{-2}$ ) and penetration through the skin ( $13.38 \pm 2.26 \mu\text{g cm}^{-2}$ ) as measured by confocal laser scanning microscopy. The cellular uptake of tacrolimus in HaCaT cells was also improved by NPs [42].

One trial investigated the applicability of NIC-based hybrid systems with chitosan instead of hyaluronic acid on tacrolimus efficacy in an animal model of atopic dermatitis (AD). AD-like skin lesions were induced by 1-chloro-2, 4-dinitrobenzene (DNCB) in BALB/c mice. *In vitro* and *in vivo* skin permeation studies demonstrated that this NIC-chitosan-NPs system significantly enhanced tacrolimus cutaneous permeation and penetration compared to commercial tacrolimus ointment. The treatment efficacy on clinical symptoms, histological analysis, and molecular biology of the AD-mice demonstrated that NIC-chitosan-NPs were more potent than the commercial ointment while using only one-third of their dosage [43]. The anti-TNF $\alpha$  fusion protein etanercept (molecular weight 150 kDa) is an effective drug in the systemic treatment of moderate to severe psoriasis. Due to the high molecular weight, the compound cannot penetrate human skin [44].

Recently, etanercept was successfully and stable encapsulated in thermoresponsive nanogels (tNG). Topical application of etanercept-loaded tNGs to human skin equivalents, prepared from primary human keratinocytes and fibroblasts and treated with TNF $\alpha$ , or tape striped human skin resulted in inefficient drug delivery throughout the stratum corneum and into the viable epidermis. Effective etanercept delivery was depended on temperature triggered release following topical application. Anti-inflammatory activity on TNF $\alpha$ , intercellular adhesion molecule 1, and thymic stromal lymphopoietin was measured by immunochemistry, enzyme-linked immunoassays, and Western blots. It was shown that the formulation was non-toxic for monocyte-derived Langerhans cells [45].

In another study, two different tNGs were synthesized, i.e. tNG\_dPG\_tPG-a combination of dendritic polyglycerol with poly (glycidyl methyl ether-co-ethyl glycidyl ether) (p(GME-co-EGE)) and tNG\_dPG\_pNIPAM with poly(N-isopropylacrylamide). These tNGs were capable of incorporating high amounts of the corticosteroid dexamethasone and tacrolimus. Cellular uptake and intracellular localisation were investigated in cell cultures of normal human keratinocytes and HaCaT cells. Neither cytotoxic nor genotoxic effects were noted. There was no induction of reactive oxygen species in keratinocytes. tNGs with a thermally triggered release at 35°C seem to be optimal for topical application on human skin [46].

## Ethosomes

Ethosomes are flexible nanovesicles composed of multiple, concentric layers of flexible phospholipid bilayers, with 20 to 45% of ethanol, glycol and water. They are used for dermal and

transdermal delivery of molecules since they can penetrate the stratum corneum [47].

However, percutaneous absorption and penetration of lipophilic 8MOP in intact skin are poor. After the development of microemulsions about 20 years ago, more recently nanocarriers were investigated for improved drug supply of 8MOP. In vitro skin permeation demonstrated a permeability of psoralen-loaded ethosomes superior to that of liposomes. With psoralen-loaded ethosomes, transdermal flux and skin deposition could be increased 3.50 and 2.15 times compared to psoralen-loaded liposomes [48].

One trial used spherical and multilamellar ethosomes incorporated into Carbopol® 934 gel. They were characterized for drug content, rheological behaviour, texture profile, in vitro release, ex vivo skin permeation and retention, skin photosensitization and histopathological examination. Ethosomal formulations showed significant skin permeation and accumulation in the epidermal and dermal layers as demonstrated by fluorescence microscopy study using <sup>123</sup>I-rhodamine while phototoxicity was not enhanced [49].

## Niosomes

Niosomes represent non-ionic surfactant-based vesicles formed mostly by non-ionic surfactant and cholesterol. They can entrap lipophilic drugs into vesicular bilayer membranes and hydrophilic drugs. Niosomes are osmotically active [50].

Acitretin is a vitamin-A analogue with antipsoriatic and anti-inflammatory activities. Systemic acitretin therapy warrants a close laboratory monitoring to prevent severe adverse events. Niosomes of approximately 370 nm were loaded with acitretin. Acitretin nanosized niosomal gel offered an enhanced ex vivo permeation profile drug deposition in the viable skin layers compared with acitretin gel. Acitretin-loaded nano-niosomes demonstrated an increased antiproliferative activity in HaCaT cell culture. Topical application of acitretin nano-niosomal gel to a mouse tail model achieved a significantly higher amount of orthokeratosis, drug activity, and reduction in epidermal thickness compared with controls. The formulation was characterised by improved tolerability and much less skin irritation [51].

Niosome technology has also been investigated for PUVA therapy with 8MOP. 8MOP niosomes were prepared by the thin-film hydration method along with cholesterol demonstrated a high entrapment efficiency (83-90%) with vesicle diameters between 111.1 and 198.8 nm. Physical stability over 6 months at different temperatures was good. Niosome formulations were incorporated in 5% sodium carboxy

methylcellulose-hydrogel matrix which showed a more retarded 8MOP release compared to niosomal vesicles. The skin penetration of the niosomes was studied in vivo by confocal laser scanning microscopy using <sup>123</sup>I-rhodamine-loaded niosomal hydrogels compared to plain <sup>123</sup>I-rhodamine hydrogel. In vitro drug permeation and deposition studies with rat skin demonstrated improved penetration and accumulation of 8MOP after 8h [52].

Proniosomes are liquid crystalline compact niosome hybrids which upon hydration form niosomes. They support physical stability such as leaking, fusion, aggregation and provide convenience in dosing, distribution, transportation and storage. Therefore, proniosomes seem to be superior to conventional niosomes [53].

A non-ionic surfactant based proniosomal gel (PNG) was developed to improve topical delivery of tazarotene – a retinoid for psoriasis. The PNG was had a vesicle size of 3.26 µm. Different formulations were investigated for drug release through cellulose membrane and rat skin, which showed a prolonged release of entrapped tazarotene. The formulations varied in drug permeation and retention in vitro. The male Albino NMRI mice tail model was used for in vivo studies. Span 60 based PNG formulations were able to increase drug accumulation in skin and reduce parakeratosis in the horny layer [54].

## Conclusions

Topical drug delivery is a field of recent research with great clinical implications. In contrast to the development of targeted systemic treatments and biologics, improved topical drug delivery is focused on the great majority of psoriasis patients with mild to moderate disease. Various anti-inflammatory drugs and herbal compounds are under investigation. Hopefully, a number these topical treatments become available for the dermatologic practice.

## References

1. Choy YB, Prausnitz MR. The rule of five for non-oral routes of drug delivery: ophthalmic, inhalation and transdermal. *Pharm Res*. 2011; 28(5):943-8. <https://doi.org/10.1007/s11095-010-0292-6> PMID:20967491 PMCID:PMC3074025
2. Wollina U. Psoriasis. In: França K, Lotti T (eds) *Advances in Integrative Dermatology*. 1st Edition. Chichester, UK: John Wiley & Sons, Ltd, 2019:131-144. <https://doi.org/10.1002/9781119476009.ch10>
3. Florek AG, Wang CJ, Armstrong AW. Treatment preferences and treatment satisfaction among psoriasis patients: a systematic review. *Arch Dermatol Res*. 2018; 310(4):271-319.

<https://doi.org/10.1007/s00403-018-1808-x> PMID:29442137

4. Telekes A, Hegedűs M, Kiss I. Therapeutic drug monitoring and measurement of drug concentrations using mass spectrometry. In: Vékey K, Telekes A, Vertes A (eds) *Medical Applications of Mass Spectrometry*. Elsevier, 2008:263-89. <https://doi.org/10.1016/B978-044451980-1.50015-X>
5. Lurie DJ, Mäder K. Monitoring drug delivery processes by EPR and related techniques--principles and applications. *Adv Drug Deliv Rev*. 2005; 57(8):1171-90. <https://doi.org/10.1016/j.addr.2005.01.023> PMID:15935868
6. Hamishehkar H, Rahimpour Y, Kouhsoltani M. Niosomes as a propitious carrier for topical drug delivery. *Expert Opin Drug Deliv*. 2013; 10(2):261-72. <https://doi.org/10.1517/17425247.2013.746310> PMID:23252629
7. Hsiao CY, Yang SC, Alalawi A, Fang JY. Laser ablation and topical drug delivery: a review of recent advances. *Expert Opin Drug Deliv*. 2019:1-16. <https://doi.org/10.1080/17425247.2019.1649655> PMID:31389261
8. Bangert CA, Costner MI. Methotrexate in dermatology. *Dermatol Ther*. 2007; 20(4):216-28. <https://doi.org/10.1111/j.1529-8019.2007.00135.x> PMID:17970887
9. Wollina U, Ständer K, Barta U. Toxicity of methotrexate treatment in psoriasis and psoriatic arthritis--short- and long-term toxicity in 104 patients. *Clin Rheumatol*. 2001; 20(6):406-10. <https://doi.org/10.1007/s100670170004> PMID:11771523
10. Taudorf EH. Laser-assisted delivery of topical methotrexate - in vitro investigations. *Dan Med J*. 2016; 63(6).
11. Nguyen HX, Banga AK. Effect of ablative laser on in vitro transungual delivery. *Int J Pharm*. 2018; 544(2):402-414. <https://doi.org/10.1016/j.ijpharm.2017.09.048> PMID:28951347
12. Ramez SA, Soliman MM, Fadel M, Nour El-Deen F, Nasr M, Youness ER, Aboel-Fadi DM. Novel methotrexate soft nanocarrier/fractional erbium YAG laser combination for clinical treatment of plaque psoriasis. *Artif Cells Nanomed Biotechnol*. 2018; 46(sup1):996-1002. <https://doi.org/10.1080/21691401.2018.1440236> PMID:29448838
13. Tamarkin D. Chapter 9. Foam: a unique delivery vehicle for topically applied formulations. In: Dayan N (editor). *Handbook of formulating dermal applications: a definitive practical guide*. Beverly, MA: Scrivener Publishing, 2017:233-60. <https://doi.org/10.1002/9781119364221.ch9>
14. Gold LS, Lebwohl M, Menter A, Villumsen J, Rosen M, Koo J. Aerosol Foam Formulation of Fixed Combination Calcipotriene Plus Betamethasone Dipropionate is Highly Efficacious in Patients With Psoriasis Vulgaris: Pooled Data From Three Randomized Controlled Studies. *J Drugs Dermatol*. 2016; 15(8):951-7.
15. Bewley AP, Shear NH, Calzavara-Pinton PG, Hansen JB, Nyeland ME, Signorovitch J. Calcipotriol plus betamethasone dipropionate aerosol foam vs. apremilast, methotrexate, acitretin or fumaric acid esters for the treatment of plaque psoriasis: a matching-adjusted indirect comparison. *J Eur Acad Dermatol Venereol*. 2019; 33(6):1107-15. <https://doi.org/10.1111/jdv.15369> PMID:30472749 PMID:PMC6766948
16. Nardo VD, Gianfaldoni S, Tchernev G, Wollina U, Barygina V, Lotti J, Daaboul F, Lotti T. Use of Curcumin in Psoriasis. *Open Access Maced J Med Sci*. 2018; 6(1):218-20. <https://doi.org/10.3889/oamjms.2018.055> PMID:29484027 PMID:PMC5816303
17. Kang NW, Kim MH, Sohn SY, Kim KT, Park JH, Lee SY, Lee JY, Kim DD. Curcumin-loaded lipid-hybridized cellulose nanofiber film ameliorates imiquimod-induced psoriasis-like dermatitis in mice. *Biomaterials*. 2018; 182:245-58. <https://doi.org/10.1016/j.biomaterials.2018.08.030> PMID:30142524
18. Goyal R, Macri LK, Kaplan HM, Kohn J. Nanoparticles and nanofibers for topical drug delivery. *J Control Release*. 2016; 240:77-92. <https://doi.org/10.1016/j.jconrel.2015.10.049> PMID:26518723 PMID:PMC4896846
19. Sangeetha NM, Maitra U. Supramolecular gels: functions and uses. *Chem Soc Rev*. 2005; 34(10):821-36. <https://doi.org/10.1039/b417081b> PMID:16172672
20. Sun L, Liu Z, Wang L, Cun D, Tong HHY, Yan R, Chen X, Wang R, Zheng Y. Enhanced topical penetration, system exposure and anti-psoriasis activity of two particle-sized, curcumin-loaded PLGA nanoparticles in hydrogel. *J Control Release*. 2017; 254:44-54. <https://doi.org/10.1016/j.jconrel.2017.03.385> PMID:28344018
21. Mao KL, Fan ZL, Yuan JD, Chen PP, Yang JJ, Xu J, ZhuGe DL, Jin BH, Zhu QY, Shen BX, Sohawon Y, Zhao YZ, Xu HL. Skin-penetrating polymeric nanoparticles incorporated in silk fibroin hydrogel for topical delivery of curcumin to improve its therapeutic effect on psoriasis mouse model. *Colloids Surf B Biointerfaces*. 2017; 160:704-14. <https://doi.org/10.1016/j.colsurfb.2017.10.029> PMID:29035818
22. de Lima Fontes M, Meneguín AB, Tercjak A, Gutierrez J, Cury BSF, Dos Santos AM, Ribeiro SJL, Barud HS. Effect of in situ modification of bacterial cellulose with carboxymethylcellulose on its nano/microstructure and methotrexate release properties. *Carbohydr Polym*. 2018; 179:126-34. <https://doi.org/10.1016/j.carbpol.2017.09.061> PMID:29111035
23. Panonnummal R, Sabitha M. Anti-psoriatic and toxicity evaluation of methotrexate loaded chitin nanogel in imiquimod induced mice model. *Int J Biol Macromol*. 2018; 110:245-58. <https://doi.org/10.1016/j.ijbiomac.2017.10.112> PMID:29054520
24. Ghatge VM, Kodoth AK, Shah A, Vishalakshi B, Lewis SA. Colloidal nanostructured lipid carriers of pentoxifylline produced by microwave irradiation ameliorates imiquimod-induced psoriasis in mice. *Colloids Surf B Biointerfaces*. 2019; 181:389-99. <https://doi.org/10.1016/j.colsurfb.2019.05.074> PMID:31170645
25. Kaur N, Sharma K, Bedi N. Topical Nanostructured Lipid Carrier Based Hydrogel of Mometasone Furoate for the Treatment of Psoriasis. *Pharm Nanotechnol*. 2018; 6(2):133-43. <https://doi.org/10.2174/2211738506666180523112513> PMID:29788899
26. Meazza L, Foster JA, Fucke K, Metrangolo P, Resnati G, Steed JW. Halogen-bonding-triggered supramolecular gel formation. *Nat Chem*. 2013; 5(1):42-7. <https://doi.org/10.1038/nchem.1496> PMID:23247176
27. Casal-Dujat L, Griffiths PC, Rodríguez-Abreu C, Solans C, Rogerse S, Pérez-García L. Nanocarriers from dicationic bis-imidazolium amphiphiles and their interaction with anionic drugs. *J Mater Chem B* 2013; 38(1):4963-71. <https://doi.org/10.1039/c3tb20289e>
28. Limón D, Jiménez-Newman C, Rodrigues M, González-Campo A, Amabilino DB, Calpena AC, Pérez-García L. Cationic Supramolecular Hydrogels for Overcoming the Skin Barrier in Drug Delivery. *ChemistryOpen*. 2017; 6(4):585-98. <https://doi.org/10.1002/open.201700040> PMID:28794954 PMID:PMC5542755
29. Limón D, Talló Domínguez K, Garduño-Ramírez ML, Andrade B, Calpena AC, Pérez-García L. Nanostructured supramolecular hydrogels: Towards the topical treatment of Psoriasis and other skin diseases. *Colloids Surf B Biointerfaces*. 2019; 181:657-70. <https://doi.org/10.1016/j.colsurfb.2019.06.018> PMID:31212138
30. Capezzeri R, Sala R, Venturini M, Zane C, Calzavara-Pinton P. PUVA photochemotherapy: update 2003. *G Ital Dermatol Venereol*. 2004; 139(2):111-30.
31. Oliveira CA, Gouvêa MM, Antunes GR, Freitas ZMF, Marques FFC, Ricci-Junior E. Nanoemulsion containing 8-methoxypsoralen for topical treatment of dermatoses: Development, characterization and ex vivo permeation in porcine skin. *Int J Pharm*. 2018; 547(1-2):1-9. <https://doi.org/10.1016/j.ijpharm.2018.05.053> PMID:29800737
32. Barradas TN, Senna JP, Cardoso SA, de Holanda E Silva KG, Elias Mansur CR. Formulation characterization and in vitro drug release of hydrogel-thickened nanoemulsions for topical delivery of 8-methoxypsoralen. *Mater Sci Eng C Mater Biol Appl*. 2018; 92:245-253. <https://doi.org/10.1016/j.msec.2018.06.049> PMID:30184748
33. Torsekar R, Gautam MM. Topical Therapies in Psoriasis. *Indian Dermatol Online J*. 2017; 8(4):235-245.



- <https://doi.org/10.4103/2229-5178.209622> PMID:28761838  
PMCID:PMC5518573
34. Tripathi PK, Gorain B, Choudhury H, Srivastava A, Kesharwani P. Dendrimer entrapped microsponge gel of dithranol for effective topical treatment. *Heliyon*. 2019; 5(3):e01343. <https://doi.org/10.1016/j.heliyon.2019.e01343> PMID:30957038  
PMCID:PMC6431737
35. Sathe P, Saka R, Kommineni N, Raza K, Khan W. Dithranol-loaded nanostructured lipid carrier-based gel ameliorate psoriasis in imiquimod-induced mice psoriatic plaque model. *Drug Dev Ind Pharm*. 2019; 45(5):826-838. <https://doi.org/10.1080/03639045.2019.1576722> PMID:30764674
36. Colombo MD, Cassano N, Bellia G, Vena GA. Cyclosporine regimens in plaque psoriasis: an overview with special emphasis on dose, duration, and old and new treatment approaches. *ScientificWorldJournal*. 2013; 2013:805705. <https://doi.org/10.1155/2013/805705> PMID:23983647  
PMCID:PMC3745987
37. Walunj M, Doppalapudi S, Bulbake U, Khan W. Preparation, characterization, and in vivo evaluation of cyclosporine cationic liposomes for the treatment of psoriasis. *J Liposome Res*. 2019;1-12. <https://doi.org/10.1080/08982104.2019.1593449>  
PMID:30897993
38. Benigni M, Pescina S, Grimaudo MA, Padula C, Santi P, Nicoli S. Development of microemulsions of suitable viscosity for cyclosporine skin delivery. *Int J Pharm*. 2018; 545(1-2):197-205. <https://doi.org/10.1016/j.ijpharm.2018.04.049> PMID:29698819
39. Lapteva M, Santer V, Mondon K, Patmanidis I, Chiriano G, Scapozza L, Gurny R, Möller M, Kalia YN. Targeted cutaneous delivery of ciclosporin A using micellar nanocarriers and the possible role of inter-cluster regions as molecular transport pathways. *J Control Release*. 2014; 196:9-18. <https://doi.org/10.1016/j.jconrel.2014.09.021> PMID:25278258
40. Wollina U. The role of topical calcineurin inhibitors for skin diseases other than atopic dermatitis. *Am J Clin Dermatol*. 2007; 8(3):157-73. <https://doi.org/10.2165/00128071-200708030-00003>  
PMID:17492844
41. Lapteva M, Mondon K, Möller M, Gurny R, Kalia YN. Polymeric micelle nanocarriers for the cutaneous delivery of tacrolimus: a targeted approach for the treatment of psoriasis. *Mol Pharm*. 2014; 11(9):2989-3001. <https://doi.org/10.1021/mp400639e>  
PMID:25057896
42. Wan T, Pan W, Long Y, Yu K, Liu S, Ruan W, Pan J, Qin M, Wu C, Xu Y. Effects of nanoparticles with hydrotropic nicotinamide on tacrolimus: permeability through psoriatic skin and antipsoriatic and antiproliferative activities. *Int J Nanomedicine*. 2017; 12:1485-1497. <https://doi.org/10.2147/IJN.S126210> PMID:28260894  
PMCID:PMC5328661
43. Yu K, Wang Y, Wan T, Zhai Y, Cao S, Ruan W, Wu C, Xu Y. Tacrolimus nanoparticles based on chitosan combined with nicotinamide: enhancing percutaneous delivery and treatment efficacy for atopic dermatitis and reducing dose. *Int J Nanomedicine*. 2017; 13:129-142. <https://doi.org/10.2147/IJN.S150319> PMID:29317821  
PMCID:PMC5743175
44. Woolacott N, Hawkins N, Mason A, Kainth A, Khadjesari Z, Vergel YB, Misso K, Light K, Chalmers R, Sculpher M, Riemsma R. Etanercept and efalizumab for the treatment of psoriasis: a systematic review. *Health Technol Assess*. 2006; 10(46):1-233, i-iv. <https://doi.org/10.3310/hta10460>
45. Giubudagian M, Yealland G, Hönzke S, Edlich A, Geisendörfer B, Kleuser B, Hedtrich S, Calderón M. Breaking the Barrier - Potent Anti-Inflammatory Activity following Efficient Topical Delivery of Etanercept using Thermoresponsive Nanogels. *Theranostics*. 2018; 8(2):450-63. <https://doi.org/10.7150/thno.21668>  
PMID:29290820 PMCID:PMC5743560
46. Gerecke C, Edlich A, Giubudagian M, Schumacher F, Zhang N, Said A, Yealland G, Lohan SB, Neumann F, Meinke MC, Ma N, Calderón M, Hedtrich S, Schäfer-Korting M, Kleuser B. Biocompatibility and characterization of polyglycerol-based thermoresponsive nanogels designed as novel drug-delivery systems and their intracellular localization in keratinocytes. *Nanotoxicology*. 2017; 11(2):267-77. <https://doi.org/10.1080/17435390.2017.1292371> PMID:28165853
47. Ainbinder D, Godin B, Touitou E. Ethosomes: Enhanced delivery of drugs to and across the skin. In: Dragicevic N, Maibach HI (eds) *Percutaneous Penetration Enhancers*. Chemical Methods in Penetration Enhancement: Nanocarriers. Berlin Heidelberg: Springer, 2016:61-75. [https://doi.org/10.1007/978-3-662-47862-2\\_4](https://doi.org/10.1007/978-3-662-47862-2_4)
48. Zhang YT, Shen LN, Wu ZH, Zhao JH, Feng NP. Comparison of ethosomes and liposomes for skin delivery of psoralen for psoriasis therapy. *Int J Pharm*. 2014; 471(1-2):449-52. <https://doi.org/10.1016/j.ijpharm.2014.06.001> PMID:24907596
49. Garg BJ, Garg NK, Beg S, Singh B, Katara OP. Nanosized ethosomes-based hydrogel formulations of methoxsalen for enhanced topical delivery against vitiligo: formulation optimization, in vitro evaluation and preclinical assessment. *J Drug Target*. 2016; 24(3):233-246. <https://doi.org/10.3109/1061186X.2015.1070855>  
PMID:26267289
50. Bartelds R, Nematollahi MH, Pols T, Stuart MCA, Pardakhty A, Asadikaram G, Poolman B. Niosomes, an alternative for liposomal delivery. *PLoS One*. 2018; 13(4):e0194179. <https://doi.org/10.1371/journal.pone.0194179> PMID:29649223  
PMCID:PMC5896898
51. Abu Hashim II, Abo El-Magd NF, El-Sheakh AR, Hamed MF, Abd El-Gawad AEH. Pivotal role of Acitretin nanovesicular gel for effective treatment of psoriasis: ex vivo-in vivo evaluation study. *Int J Nanomedicine*. 2018; 13:1059-79. <https://doi.org/10.2147/IJN.S156412> PMID:29503541  
PMCID:PMC5824759
52. Kassem AA, Abd El-Alim SH, Asfour MH. Enhancement of 8-methoxypsoralen topical delivery via nanosized niosomal vesicles: Formulation development, in vitro and in vivo evaluation of skin deposition. *Int J Pharm*. 2017; 517(1-2):256-268. <https://doi.org/10.1016/j.ijpharm.2016.12.018> PMID:27956194
53. Ahmad MZ, Mohammed AA, Mokhtar Ibrahim M. Technology overview and drug delivery application of proniosome. *Pharm Dev Technol*. 2017; 22(3):302-11. <https://doi.org/10.3109/10837450.2015.1135344> PMID:26794727
54. Prasad V, Chaurasia S. Performance evaluation of non-ionic surfactant based tazarotene encapsulated proniosomal gel for the treatment of psoriasis. *Mater Sci Eng C Mater Biol Appl*. 2017; 79:168-176. <https://doi.org/10.1016/j.msec.2017.05.036>  
PMID:28629004

# Multiple Cutaneous Leiomyomas with Uterus Myomatosis (MCUL) – Two Case Reports and One New Mutation of FH Gene

André Koch<sup>1</sup>, Jacqueline Schönlebe<sup>2</sup>, Aleksandra Vojvodic<sup>3</sup>, Torello Lotti<sup>4</sup>, Uwe Wollina<sup>1\*</sup>

<sup>1</sup>Department of Dermatology and Allergology, Städtisches Klinikum Dresden, Academic Teaching Hospital, Dresden, Germany; <sup>2</sup>Städtisches Klinikum Dresden, Institute of Pathology "Georg Schmorr", Dresden, Germany; <sup>3</sup>Military Medical Academy of Belgrade, Belgrade, Serbia; <sup>4</sup>Department of Dermatology, University of Rome "G. Marconi", Rome, Italy

## Abstract

**Citation:** Koch A, Schönlebe J, Vojvodic A, Lotti T, Wollina U. Multiple Cutaneous Leiomyomas with Uterus Myomatosis (MCUL) – Two Case Reports and One New Mutation of FH Gene. Open Access Maced J Med Sci. 2019 Sep 30; 7(18):3026-3029. <https://doi.org/10.3889/oamjms.2019.625>

**Keywords:** Fumarate dehydrogenase; Reed syndrome; Leiomyomatosis

**\*Correspondence:** Uwe Wollina, Department of Dermatology and Allergology, Städtisches Klinikum Dresden, Academic Teaching Hospital, Dresden, Germany. E-mail: [uwollina@gmail.com](mailto:uwollina@gmail.com)

**Received:** 12-May-2019; **Revised:** 16-Jul-2019; **Accepted:** 17-Jul-2019; **Online first:** 30-Jul-2019

**Copyright:** © 2019 André Koch, Jacqueline Schönlebe, Aleksandra Vojvodic, Torello Lotti, Uwe Wollina. This is an open-access article distributed under the terms of the Creative Commons Attribution-NonCommercial 4.0 International License (CC BY-NC 4.0)

**Funding:** This research did not receive any financial support

**Competing Interests:** The authors have declared that no competing interests exist

**BACKGROUND:** Reed syndrome or multiple cutaneous leiomyomas with uterine leiomyomas are part of the spectrum of heterozygous hereditary disorders with cutaneous, genital and renal manifestations.

**CASE REPORTS:** We report two female cases of multiple cutaneous leiomyomas with uterine leiomyomas (MCUL) without renal disease, in particular without cysts or papillary renal carcinoma, aged 52 and 55 years, respectively. The diagnosis of pilar leiomyomas was confirmed by histology and immunostaining for smooth muscle actin and desmin. Both females had a hysterectomy in the past because of uterus myomatosis. In one patient, a new mutation of the FH gene was detected, i.e. a heterozygote c1300\_1301del (p.Cys434Argfs17) mutation in the exon 9 of the FH gene.

**CONCLUSION:** Since MCUL shares features with the genetic cancer syndrome hereditary leiomyomatosis and renal cell carcinoma (HLRCC), these patients need a regular follow-up to prevent the late diagnosis of renal cancer.

## Introduction

The fumarate dehydrogenase (FH) gene is located on chromosome 1. In normal cells, FH is localised in both mitochondria and cytosol and catalyses fumarate to malate [1].

Fumarate is a covalent oncometabolite whose accumulation is characteristic for the genetic cancer syndrome hereditary leiomyomatosis and renal cell carcinoma (HLRCC). HLRCC is characterized by germline mutation of the fumarate hydratase (FH) gene, which leads to a shift to aerobic glycolysis in the affected cells (Warburg effect) [2]. The disease is autosomal dominant inherited. In homozygotes, FH deficiency is lethal in early childhood [3].

In the medical literature, only about 300 cases

of HLRCC are described with > 150 different mutations [4]. We report on two female patients with the milder type of the disease known as Reed syndrome or multiple cutaneous leiomyomas with uterine leiomyomas (MCUL; MIM 150800) and one new mutation.

## Case Reports

### Case One

A 52-year-old Caucasian woman presented with multiple flat painful tumours concentrated on her left shoulder (Figure 1).

Her medical history was positive for a uterus

myomatosis that was surgically removed by hysterectomy. She was otherwise healthy.

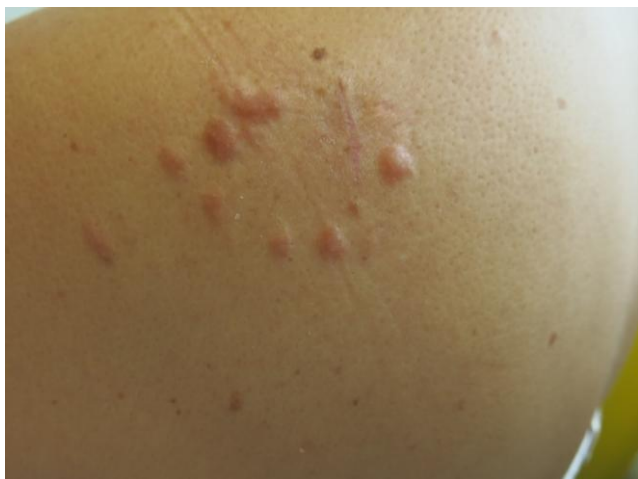

Figure 1: Multiple pilar leiomyomas on the left shoulder (case #1)

In her family, her mother had renal cancer at the age of 58 years, her son has multiple cutaneous leiomyomas (Fig. 2).

On examination, we observed multiple flat, livid nodules that were painful on pressure. Their size varied between 1 and 2 cm. The lesions were concentrated above her left shoulder blade, but single lesions were spread all over the body except palmoplantar skin and head and neck.

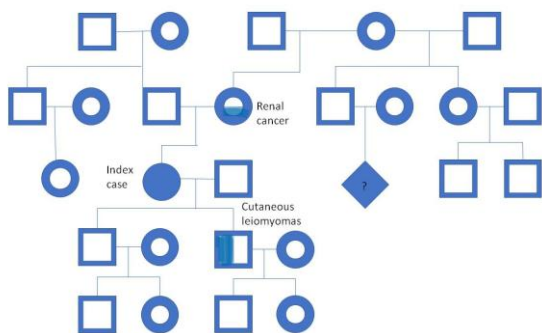


Figure 2: Family tree of the Case #1

We performed an excision of the most painful lesions. Histopathology disclosed dermal spindle cell tumours without cellular atypias or mitotic activity.

The lesions were well demarcated. Tumour cells were positive for smooth muscle actin and desmin (Figure 3) but Ki67 negative. The diagnosis of pilar leiomyomas was confirmed.

We performed molecular biology analysis of the fumarate hydrogenase (*FH*) gene. Extracted DNA was enriched by Nextera Rapid Capture on Illumina NextSequ 500 followed by Sanger sequencing, multiplex ligation-dependent probe analysis (MPLA) to detect possible duplications or deletions of exons, and biometric analysis by MutationSurveyor version 3.10,

GeneMarker V2 4.0 and Alamut Visual version 2.6.1 (MVZ Mitteldeutscher Praxisverbund Humangenetik GmbH, Dresden).

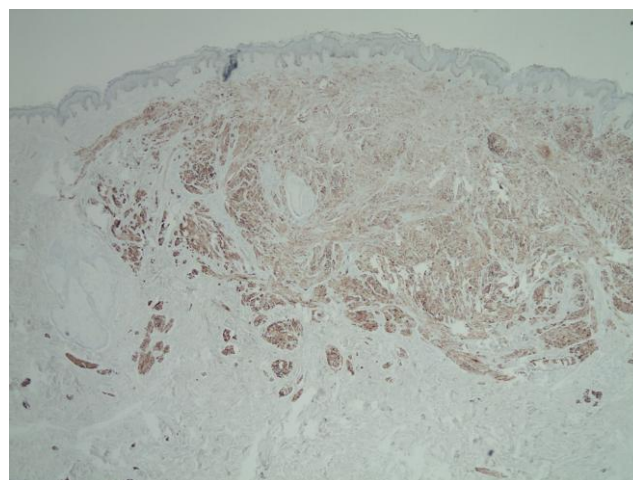


Figure 3: Desmin immunostaining of pilar leiomyoma (case #1, x 2)

A heterozygote c1300\_1301del (p.Cys434Argfs17) mutation in the exon 9 of the *FH* gene could be detected, leading to a loss of function for the reading frame. This mutation has not been described before.

Routine laboratory investigations remained unremarkable. Tumour markers ICA 125 and ICEA were detected by chemiluminescence assays (Roche Diagnostics) and were within the normal range.

She was screened by diagnostic ultrasound, abdominal magnetic resonance imaging, and X-ray of the chest. There was no hint for renal cancer or any other renal disorder.

The diagnosis of MCUL (MIM 150800) was confirmed.

### Case Two

A 55-year-old Caucasian woman presented with segmental painful tiny brownish nodules and plaques of the left supra- and infraclavicular region (Figure 4). She had a hysterectomy due to a uterus five years ago but no other disorders. Her family history was unremarkable.

A skin biopsy was taken, which disclosed circumscribed dermal tumours composed of interlacing and whorled bundles of smooth muscle cells expressing actin. The tumours appeared yellow-orange in van Giessen stain. The diagnosis of pilar leiomyomas was confirmed.

Screening for renal cancer by diagnostic ultrasound and contrast-enhanced computerised tomography (CT) was negative. No molecular analysis was available. Nevertheless, the diagnosis of MCUL (MIN 150800) was confirmed. This case had been reported earlier elsewhere [5]. Until now, no renal

cancer was detected in this patient.

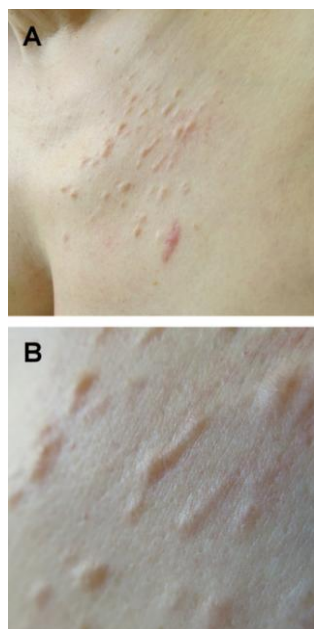


Figure 4: Pilar leiomyomas around the left clavicle (case # 2): a) Overview, b) detail (From Wollina U, Schönlebe J. Reed's syndrome: segmental piloleiomyomas type 1 and uterus myomatosis. *J Dermatol Case Rep.* 2014; 8(3):67-69) [5]

## Discussion

We reported two cases of MCUL, a rare heterozygote FH deficiency, without renal cancer. In the case of heterozygote FH deficiency, fumarate suppresses the homologous recombination DNA repair pathway which is necessary for the repair of DNA double-strand breaks and genomic integrity by succination of proteins. the increases intracellular ferritin concentrations which drives tumour cell proliferation [6].

Hallmark of the disease is hereditary leiomyomatosis seen in > 75% of the affected patients. However, only 46% of affected individuals show cutaneous leiomyomas, benign smooth muscle tumours of the skin of the tumour. These tumours are sensitive to touch and cold and can be painful [7], [8]. Cutaneous pilar leiomyomas are benign tumours with an incidence of 0.04% in pathology files. Other cutaneous leiomyomas are angioleiomyoma and dartoic myoma, but the pilar type if the predominant one responsible for 88.5% of all cases [9]. A rare subtype of pilar leiomyoma is represented by symplastic pilar leiomyoma with focal cellular pleomorphism [10]. This particular subtype has been reported to be potentially developing in leiomyosarcoma in rare cases [11].

Women with HLRCC are prone to develop multiple leiomyomas of the uterus as well, which leads to uterus myomatosis. Hysterectomy is performed in

about 50% in patients younger than 35 years. The disease can cause dysmenorrhea, menorrhagias, and menstrual irregularities [12], [13].

Both of our patients had a hysterectomy due to uterine leiomyomas. Both presented with multiple cutaneous pilar leiomyomas. The lesions were segmental in case # 2 and segmental concentrated with single lesions on other body parts in case # 1. Painful lesions were removed by surgery.

The most dangerous feature of HLRCC, however, is the early onset of papillary kidney cancer in the affected families. This tumour has two subtypes. Type 1 is an indolent growing tumour associated with germline mutations of *MET*. It is found in hereditary papillary kidney cancer. Type 2, in contrast, is an aggressive tumour with early metastatic spread. This type is associated with HLRCC. It occurs in about 25% of patients with an average onset at 46 years. It may be without specific symptoms but can cause lumbar back pain or hematuria. Renal cysts are also more common in HLRCC than in the general population [14].

In case # 1, the mother of our index patient had an unspecified renal cancer but no leiomyomatosis. This could be an incidental coincidence. In case 2, there was no family history of other members affected by either MCUL or HLRCC. Nevertheless, these patients need a regular live-long follow-up for early detection of renal cell cancer.

In conclusion, MCUL may be considered a *forme fruste* of HLRCC or a more benign subtype. More investigations are needed.

## Acknowledgements

We are grateful for the support of the staff of the MVZ Mitteldeutscher Praxisverbund Humangenetik GmbH, Dresden, in molecular diagnostics.

## References

- Jardim-Messeder D, Cabreira-Cagliari C, Rauber R, Turchetto-Zolet AC, Margis R, Margis-Pinheiro M. Fumarate reductase superfamily: A diverse group of enzymes whose evolution heterozygotes to the establishment of different metabolic pathways. *Mitochondrion.* 2017; 34:56-66. <https://doi.org/10.1016/j.mito.2017.01.002> PMID:28088649
- King A, Selak MA, Gottlieb E. Succinate dehydrogenase and fumarate hydratase: linking mitochondrial dysfunction and cancer. *Oncogene.* 2006; 25(34):4675-4682. <https://doi.org/10.1038/sj.onc.1209594> PMID:16892081
- Eng C, Kiuru M, Fernandez MJ, Aaltonen LA. A role for mitochondrial enzymes in inherited neoplasia and beyond. *Nat Rev*

- Cancer. 2003; 3(3):193-202. <https://doi.org/10.1038/nrc1013> PMID:12612654
4. Bayley JP, Launonen V, Tomlinson IP. The FH mutation database: an online database of fumarate hydratase mutations involved in the MCUL (HLRCC) tumor syndrome and congenital fumarase deficiency. BMC Med Genet. 2008; 9:20. <https://doi.org/10.1186/1471-2350-9-20> PMID:18366737 PMCid:PMC2322961
5. Wollina U, Schönlebe J. Reed's syndrome: segmental piloleiomyomas type 1 and uterus myomatosis. J Dermatol Case Rep. 2014; 8(3):67-69. <https://doi.org/10.3315/jdcr.2014.1178> PMID:25324907 PMCid:PMC4195502
6. Kerins MJ, Milligan J, Wohlschlegel JA, Ooi A. Fumarate hydratase inactivation in hereditary leiomyomatosis and renal cell cancer is synthetic lethal with ferroptosis induction. Cancer Sci. 2018; 109(9):2757-2766. <https://doi.org/10.1111/cas.13701> PMID:29917289 PMCid:PMC6125459
7. Bholra PT, Gilpin C, Smith A, Graham GE. A retrospective review of 48 individuals, including 12 families, molecularly diagnosed with hereditary leiomyomatosis and renal cell cancer (HLRCC). Fam Cancer. 2018; 17(4):615-620. <https://doi.org/10.1007/s10689-018-0076-4> PMID:29423582
8. Naversen DN, Trask DM, Watson FH, Burket JM. Painful tumors of the skin: "LEND AN EGG". J Am Acad Dermatol. 1993; 28(2 Pt 2):298-300. [https://doi.org/10.1016/0190-9622\(93\)70039-V](https://doi.org/10.1016/0190-9622(93)70039-V)
9. Orellana-Díaz O, Hernández-Pérez E. Leiomyoma cutis and leiomyosarcoma: a 10-year study and a short review. J Dermatol Surg Oncol. 1983; 9(4):283-7. <https://doi.org/10.1111/j.1524-4725.1983.tb00803.x> PMID:6833615
10. Usmani N, Merchant W, Yung A. A case of cutaneous symplastic leiomyoma - a rare variant of cutaneous pilar leiomyoma. J Cutan Pathol. 2008; 35(3):329-31. <https://doi.org/10.1111/j.1600-0560.2007.00803.x> PMID:18251750
11. Fons ME, Bachhuber T, Plaza JA. Cutaneous leiomyosarcoma originating in a symplastic pilar leiomyoma: a rare occurrence and potential diagnostic pitfall. J Cutan Pathol. 2011; 38(1):49-53. <https://doi.org/10.1111/j.1600-0560.2009.01420.x> PMID:19780873
12. Tomlinson IP, Alam NA, Rowan AJ, Barclay E, Jaeger EE, Kelsell D, Leigh I, Gorman P, Lamlum H, Rahman S, Roylance RR, Olpin S, Bevan S, Barker K, Hearle N, Houlston RS, Kiuru M, Lehtonen R, Karhu A, Vilkki S, Laiho P, Eklund C, Vierimaa O, Aittomäki K, Hietala M, Sistonen P, Paetau A, Salovaara R, Herva R, Launonen V, Aaltonen LA; Multiple Leiomyoma Consortium. Germline mutations in FH predispose to dominantly inherited uterine fibroids, skin leiomyomata and papillary renal cell cancer. Nat Genet. 2002; 30(4):406-410. <https://doi.org/10.1038/ng849> PMID:11865300
13. Gunnala V, Pereira N, Irani M, Lilienthal D, Pirog EC, Soslow R, Caputo TA, Elias R, Kligman I, Rosenwaks Z. Novel fumarate hydratase mutation in siblings with early onset uterine leiomyomas and hereditary leiomyomatosis and renal cell cancer syndrome. Int J Gynecol Pathol. 2018; 37(3):256-261. <https://doi.org/10.1097/PGP.0000000000000423> PMID:28700432 PMCid:PMC5908258
14. Menko FH, Maher ER, Schmidt LS, Middleton LA, Aittomäki K, Tomlinson I, Richard S, Linehan WM. Hereditary leiomyomatosis and renal cell cancer (HLRCC): renal cancer risk, surveillance and treatment. Fam Cancer. 2014; 13(4):637-644. <https://doi.org/10.1007/s10689-014-9735-2> PMID:25012257 PMCid:PMC4574691

# Nonmelanoma Skin Cancer with Skull Infiltration and Cranial Involvement

Uwe Wollina<sup>1\*</sup>, Thomas Kittner<sup>2</sup>, Andreas Nowak<sup>3</sup>

<sup>1</sup>*Department of Dermatology and Allergology, Städtisches Klinikum Dresden, Academic Teaching Hospital, Dresden, Germany;* <sup>2</sup>*Department of Radiology, Städtisches Klinikum Dresden, Academic Teaching Hospital, Dresden, Germany;* <sup>3</sup>*Department of Anesthesiology and Intensive Care Medicine, Emergency Medicine and Pain Management, Städtisches Klinikum Dresden, Academic Teaching Hospital, Dresden, Germany*

## Abstract

**Citation:** Wollina U, Kittner T, Nowak A. Nonmelanoma Skin Cancer with Skull Infiltration and Cranial Involvement. *Open Access Maced J Med Sci.* 2019 Sep 30; 7(18):3030-3033. <https://doi.org/10.3889/oamjms.2019.416>

**Keywords:** Skin cancer; Skull invasion; Squamous cell carcinoma; Treatment

**\*Correspondence:** Uwe Wollina, Department of Dermatology and Allergology, Städtisches Klinikum Dresden, Academic Teaching Hospital, Dresden, Germany. E-mail: [uwollina@gmail.com](mailto:uwollina@gmail.com)

**Received:** 12-Aug-2019; **Revised:** 14-Sep-2019; **Accepted:** 15-Sep-2019; **Online first:** 30-Sep-2019

**Copyright:** © 2019 Uwe Wollina, Thomas Kittner, Andreas Nowak. This is an open-access article distributed under the terms of the Creative Commons Attribution-NonCommercial 4.0 International License (CC BY-NC 4.0)

**Funding:** This research did not receive any financial support

**Competing Interests:** The authors have declared that no competing interests exist

**BACKGROUND:** Skin cancer is an uncommon cause of skull invasion, dural infiltration and brain parenchyma involvement.

**CASE REPORT:** We report on a series of three elderly patients who presented with squamous cell carcinoma of the scalp with skull bone and cerebral invasion and discuss the diagnostic and therapeutic challenges.

**CONCLUSION:** A major factor of delayed diagnosis of this potentially life-threatening skin cancer feature is patients' neglecting.

## Introduction

Malignant skin tumours of the scalp with skull invasion, dural infiltration and brain involvement are uncommon. However, in advanced cases, skin cancer may be associated with infiltration of the skull bone and even the brain. In a 10-year retrospective analysis, Brunner et al. (2017) analysed 62 patients with malignant craniofacial skin tumours. Brain invasion, surgical margin involvement, and dural margin involvement were the factors that significantly reduce survival. They concluded that the resection of bone is a reasonable surgical option in the treatment of patients with advanced skin cancer of the face and scalp [1]. In a retrospective study of 25 patients with aggressive squamous cell carcinoma (SCC) of the scalp from Catania (Italy) a multidisciplinary approach achieved a complete response in 22 patients with a

follow-up of seven years. Three patients died from other causes not related to the cutaneous malignancy [2].

## Case Reports

### Case 1

An 80-year-old male patient presented a fast-growing exophytic tumour parietal right, measuring 8 x 7 cm. A keratoacanthoma or keratoacanthoma-like SCC was suspected (Figure 1, A and B). He had several comorbidities including dementia, arterial hypertension, glaucoma and atrial fibrillation. Five years ago, another SCC had been removed surgically.

He was treated with rivaroxaban and anti-hypertensive drugs.

Lymph node sonography and chest-X-ray were unremarkable. Computerised tomography (CT) and magnetic resonance imaging (MRI) of the head demonstrated an osteolytic defect of the skull measuring 2.6 cm in diameter with the involvement of the tabula interna. The MRI suggested a tumour infiltration of the sinus sagittalis and the dura mater (Figure 1, C and D). The surgical situs demonstrated an exophytic, the skull infiltrating tumour with a pulsation at the bottom of the skull defect (Figure 1C). In association with the neurosurgeon, it was decided to perform a temporary closure with a meshed graft. Histopathology confirmed the diagnosis of an SCC, pT3, G2. Imaging techniques excluded a metastatic spread leading to the final tumour stage of pT3 cN0 cM0, G2, stage III.

Because of the R1-resection status, the patient was presented to the interdisciplinary tumour board. Adjuvant radiotherapy and complete neurosurgical excision of the tumour were discussed. Both methods bear a mortality risk. After consultation with the family, and because of dementia, palliative treatment was initiated.

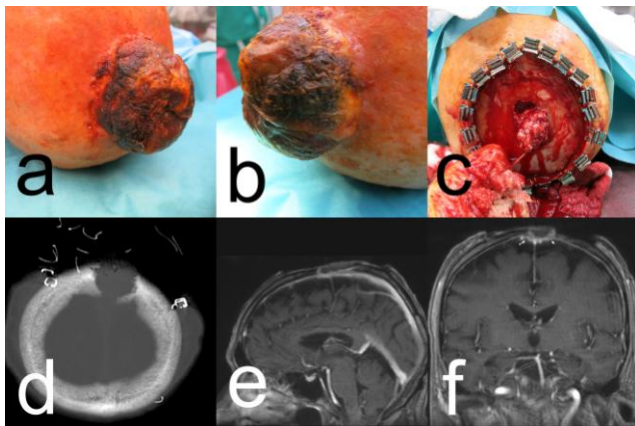


Figure 1: Patient #1 with SCC; A) and B) clinical presentation of the tumour; C) Surgical situs with infiltration of the skull; D) MRI scan with osteolytic skull lesion; E) and F) CT scan with skull penetrating the tumour

### Case 2

An 83-year old female patient presented with a long-standing occipital scalp tumour, that was hidden by hair and crusts. The lesion developed over several years. Due to recent bleeding, the patient had been referred to our department (Figure 2A).

She was living in a nursing home. Her medical history was positive for arterial hypertension, depression and diabetes type II, which were pharmacologically treated. A diagnostic skin biopsy revealed an SCC, G2. On CT, a 42 x 53 mm large full-thickness skull defect was noted (Figure 2, B and D). By imaging techniques, there was no evidence of a metastatic spread. In association with the

neurosurgeon, complete surgical removal had been discussed but was denied by the patient and her family. Palliative care was initiated. The patient was lost to follow-up.

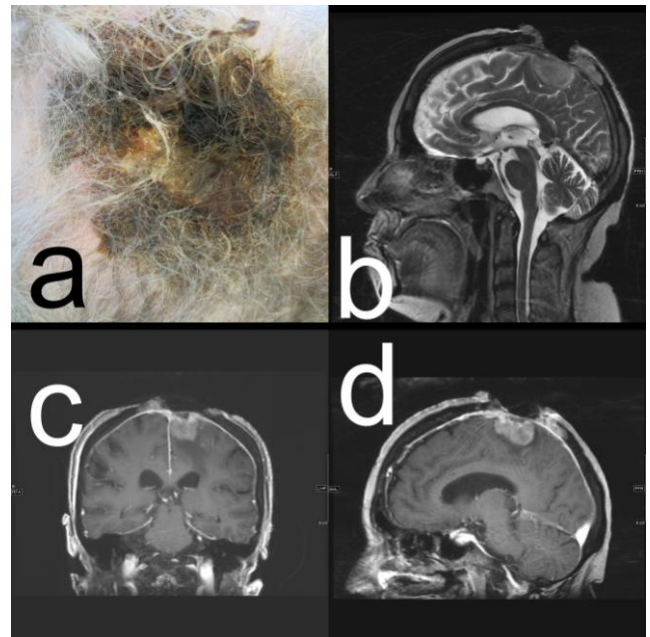


Figure 2: Patient # 2; A) Clinical presentation of the SCC; C) to D) CT scan with a large osteolytic skull lesion due to tumour infiltration

### Case 3

A 67-year-old man presented to the emergency room with very large bleeding, the ulcerated, malodorous, exophytic tumour of the scalp, infested by maggots, that was slowly growing over more than two years. His medical history was remarkable for chronic alcohol abuse. He had no medical drug therapy.

We observed cauliflower-like exophytic growth with partial necrosis and discharged measuring 23 cm x 12 cm x 2.4 cm localised in the midline of the frontal skull (Figure 3A). There were neither clinical signs of tumour spread to regional lymph nodes nor any neurological impairment. A diagnostic biopsy was taken that confirmed the diagnosis of a tricholemmal SCC (Broders grade 3) (Figure 3D). Routine laboratory demonstrated anaemia and hypoproteinemia: erythrocyte count 3.1 Tpt/L (normal range 4.6-6.2), haemoglobin 6.4 mmol/L (normal range 8.6-12.1), and serum protein 43.3 g/L (normal range 60-85).

Microbial swabs from the tumour surface revealed *Proteus mirabilis*, *Alcaligenes faecalis*, and beta-hemolytic streptococci that were sensitive to levofloxacin.

Staging with thoracic X-ray, lymph node sonography, and cranial CT did not show any metastases. Cranial CT, MRI, and gadolinium-enhanced vascular MRI disclosed parietal parasagittal cranial tumor invasion with a continuous extension to

the meninges on the left side with infiltration (3.5 cm x 3.7 cm) and partial closure of the medial part of the superior sinus sagittalis (remaining open lumen 2.4 cm) (Figure 3, B and C).

After good ulcer care and initiation of intravenous levofloxacin therapy (2 x 250 mg/day), we performed a debulking surgery in association with the neurosurgeon with lateral safety margins of 2 cm down to the skull bone. During surgery, a large full-thickness skull bone defect in the neighbourhood of the sinus sagittalis was visible.

The defect was covered by oxygenised regenerated cellulosis (Tabotamp, Johnson & Johnson—Ethicon) and split-thickness skin meshes graft transplant (Figure 3, E and F).

There was an uneventful postoperative course, and the patient could leave the intensive care unit after 24 hours, but the transplant was lost after seven days. A second surgery with complete debridement of the defect and thinning of the outer tabula of the skull bone by a larger rose drill was performed. After that, a smaller rose drill was used to make penetrations into the spongiosa to reach diploe veins for transplant nutrition. The whole area was covered with a dermal template of porcine collagen (mediCipio, V-CARE Biomedical, Leipzig). Split skin was obtained from the abdomen, meshed 1:1.5, and transplanted onto the dermal template. A light protective helmet was provided to support mobilisation. The patient was re-staged after two months when a collateral circulation around the thrombosed sagittal sinus was evident. We planned a neuro-vascular surgery for complete removal of the remaining tumour. One week before the scheduled operation, he died in a traffic accident.

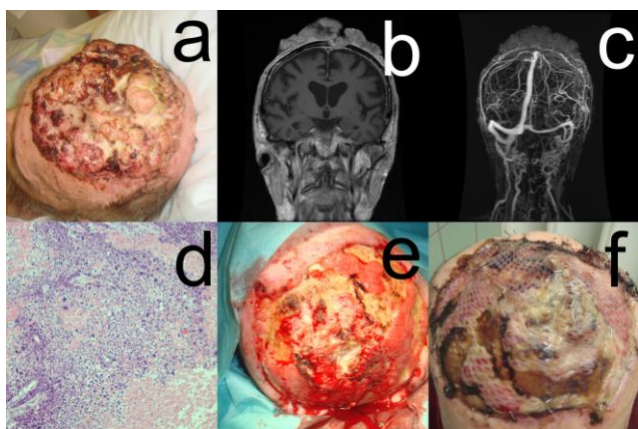


Figure 3: Patient #3: a, cauliflower-like exophytic growth with partial necrosis and discharged measuring 23 cm x 12 cm x 2.4 cm localised in the midline of the frontal skull; b, c, Cranial CT, MRI, and gadolinium-enhanced vascular MRI disclosed parietal parasagittal cranial tumor invasion with a continuous extension to the meninges on the left side with infiltration (3.5 cm x 3.7 cm) and partial closure of the medial part of the superior sinus sagittalis (remaining open lumen 2.4 cm); d, A diagnostic biopsy was taken that confirmed the diagnosis of a tricholemmal SCC (Broders grade 3); e, f, The defect was covered by oxygenised regenerated cellulosis (Tabotamp, Johnson & Johnson—Ethicon) and split-thickness skin meshes graft transplant

## Discussion

Skull and cranial invasion are rare among cutaneous malignancies. Cancer that has been most often reported to cause this rare but potentially life-threatening complication is SCC [2], [3], [4].

Other tumours with a potential of cranial infiltration are adenoid carcinoma, basal cell carcinoma, and cutaneous melanoma [5], [6], [7].

We presented three patients (one female and three males) with full-thickness skull bone penetration by SCC and intracranial extension. The main cause for the late diagnosis and treatment was the neglect of the tumours by the patients. But GP's, nurses and family members were unable to overcome this disadvantage. Interestingly, none of these patients presented with neurological symptoms. This argues for a slow process of intracranial tumour invasion.

The differential diagnosis includes metastases. The most common site of metastases is the bony skull, while dural metastasis occurs less frequently and may mimic subdural hematoma [8].

The treatment of these advanced SSC's should be multidisciplinary with dermatology, neurosurgery, radiotherapy, and rehabilitative medicine. In the case of dura and brain invasion, the mortality is increased [1], [2]. Newer pharmaceutical treatment options include epidermal growth factor receptor inhibitors such as cetuximab-alone or in combination with radiotherapy-and immune checkpoint inhibitors like cemiplimab (anti-programmed death-1) [9], [10], [11]. The response rate in real life, however, is less than 50% and short-lived. Surgery remains the cornerstone of treatment [1], [2], [10].

In conclusion, in addition to metastases into the brain and the meninges, nonmelanoma skin cancer can cause other types of cancer involvement by local bone infiltration and perineural invasion. Often, a multidisciplinary approach for diagnosis and treatment of these cancers will be needed.

## References

1. Brunner M, Ch'ng S, Shannon K, Clifford A, Ashford B, Elliott M, Clark JR. Bone resection for facial cutaneous malignancies. *J Surg Oncol*. 2017; 116(4):545-549. <https://doi.org/10.1002/jso.24693> PMID:28628727
2. Soma PF, Chibbaro S, Makiese O, Marsella M, Diemidio P, Fricia M, Passanisi M, Catania V, Siragò P, Ventura F. Aggressive scalp carcinoma with intracranial extension: a multidisciplinary experience of 25 patients with long-term follow-up. *J Clin Neurosci*. 2008; 15(9):988-92. <https://doi.org/10.1016/j.jocn.2007.09.014> PMID:18653348



3. Wollina U, Helm C, Schreiber A, Brandl HG. Extensive cranial infiltration by basal cell carcinoma. *J Cutan Med Surg.* 2006; 10(5):257-8. <https://doi.org/10.2310/7750.2006.00050> PMID:17234111
4. Schwarze HP, Loche F, Gorguet MC, Kuchta J, Bazex J. Invasive cutaneous squamous cell carcinoma associated with actinic keratosis: a case with orbital invasion and meningeal infiltration. *Dermatol Surg.* 1999; 25(7):587-9. <https://doi.org/10.1046/j.1524-4725.1999.99009.x> PMID:10469120
5. Keck M, Ueberreiter K, Tanzella U, Doll D, Krapohl BD. Primary cutaneous adenoid carcinoma of the scalp. *GMS Interdiscip Plast Reconstr Surg DGPW.* 2012; 1:Doc04.
6. Sicinska J, Rakowska A, Czuwara-Ladykowska J, Mroz A, Lipinski M, Nasierowska-Guttmejer A, Sikorska J, Sklinda K, Slowinska M, Kowalska-Oledzka E, Walecka I, Walecki J, Rudnicka L. Cylindroma transforming into basal cell carcinoma in a patient with Brooke-Spiegler syndrome. *J Dermatol Case Rep.* 2007; 1(1):4-9. <https://doi.org/10.3315/jdcr.2007.1.1002> PMID:21886698 PMCid:PMC3157764
7. Wollina U, Hansel G, Schmidt N, Schönlebe J, Kittner T, Nowak A. Very rare amelanotic lentigo maligna melanoma with skull roof invasion. *Open Access Maced J Med Sci.* 2017; 5(4):458-461. <https://doi.org/10.3889/oamjms.2017.113> PMID:28785332 PMCid:PMC5535657
8. Grisold W, Grisold A. Cancer around the brain. *Neurooncol Pract.* 2014; 1(1):13-21. <https://doi.org/10.1093/nop/npt002> PMID:26034610 PMCid:PMC4369702
9. Wollina U. Update of cetuximab for non-melanoma skin cancer. *Expert Opin Biol Ther.* 2014; 14(2):271-6. <https://doi.org/10.1517/14712598.2013.876406> PMID:24387664
10. Hillen U, Leiter U, Haase S, Kaufmann R, Becker J, Gutzmer R, Terheyden P, Krause-Bergmann A, Schulze HJ, Hassel J, Lahner N, Wollina U, Ziller F, Utikal J, Hafner C, Ulrich J, Machens HG, Weishaupt C, Hauschild A, Mohr P, Pöhler C, Maurer J, Wolff P, Windemuth-Kieselbach C, Schadendorf D, Livingstone E; Dermatologic Cooperative Oncology Group (DeCOG). Advanced cutaneous squamous cell carcinoma: A retrospective analysis of patient profiles and treatment patterns- Results of a non-interventional study of the DeCOG. *Eur J Cancer.* 2018; 96:34-43. <https://doi.org/10.1016/j.ejca.2018.01.075> PMID:29665511
11. Migden MR, Rischin D, Schmults CD, Guminski A, Hauschild A, Lewis KD, Chung CH, Hernandez-Aya L, Lim AM, Chang ALS, Rabinowits G, Thai AA, Dunn LA, Hughes BGM, Khushalani NI, Modi B, Schadendorf D, Gao B, Seebach F, Li S, Li J, Mathias M, Booth J, Mohan K, Stankevich E, Babiker HM, Brana I, Gil-Martin M, Homsí J, Johnson ML, Moreno V, Niu J, Owonikoko TK, Papadopoulos KP, Yancopoulos GD, Lowy I, Fury MG. PD-1 Blockade with Cemiplimab in Advanced Cutaneous Squamous-Cell Carcinoma. *N Engl J Med.* 2018; 379(4):341-351. <https://doi.org/10.1056/NEJMoa1805131> PMID:29863979

# Gut Microbiota and the Alteration of Immune Balance in Skin Diseases: From Nutraceuticals to Fecal Transplantation

Aleksandra Vojvodic<sup>1</sup>, Zorica Peric-Hajzler<sup>2</sup>, Dusica Matovic<sup>2</sup>, Petar Vojvodic<sup>3</sup>, Tatjana Vlaskovic-Jovicevic<sup>3</sup>, Goran Sijan<sup>4</sup>, Sanja Dimitrijevic<sup>5</sup>, Nenad Stepic<sup>6</sup>, Uwe Wollina<sup>7</sup>, Badr Abdulwahab E. Badr<sup>8</sup>, Ashraf Badawi<sup>9</sup>, Mohamad Goldust<sup>10</sup>, Michael Tirant<sup>10</sup>, Van Thuong Nguyen<sup>11</sup>, Massimo Fioranelli<sup>12\*</sup>, Torello Lotti<sup>13</sup>

<sup>1</sup>Department of Dermatology and Venereology, Military Medical Academy, Belgrade, Serbia; <sup>2</sup>Military Medical Academy, Belgrade, Serbia; <sup>3</sup>Clinic for Psychiatric Disorders "Dr. Laza Lazarevic", Belgrade, Serbia; <sup>4</sup>Clinic for Plastic Surgery and Burns, Military Medical Academy, Belgrade, Serbia; <sup>5</sup>Department of Gynecology, Military Medical Academy, Belgrade, Serbia; <sup>6</sup>Chief of Clinic for Plastic Surgery and Burns, Military Medical Academy, Belgrade, Serbia; <sup>7</sup>Department of Dermatology and Allergology, Städtisches Klinikum Dresden, Dresden, Germany; <sup>8</sup>Faculty of Medicine – King Abdulaziz University, Jeddah, Saudi Arabia; <sup>9</sup>Laser Institute, Cairo University, Cairo, Egypt; <sup>10</sup>G. Marconi University, Rome, Italy; <sup>11</sup>National Hospital of Dermatology and Venereology, Hanoi, Vietnam; <sup>12</sup>Department of Nuclear Physics, Sub-nuclear and Radiation, G. Marconi University, Rome, Italy; <sup>13</sup>Department of Dermatology, G. Marconi University, Rome, Italy

## Abstract

**Citation:** Vojvodic A, Peric-Hajzler Z, Matovic D, Vojvodic P, Vlaskovic-Jovicevic T, Sijan G, Dimitrijevic S, Stepic N, Wollina U, Badr BAE, Badawi A, Goldust M, Tirant M, Nguyen VY, Fioranelli M, Lotti T. Gut Microbiota and the Alteration of Immune Balance in Skin Diseases: From Nutraceuticals to Fecal Transplantation. *Open Access Maced J Med Sci.* 2019 Sep 30; 7(18):3034-3038. <https://doi.org/10.3889/oamjms.2019.827>

**Keywords:** Microbiota; Cytokines; Treatment; Inflammatory; Skin diseases; Immunology

**\*Correspondence:** Massimo Fioranelli. Department of Nuclear Physics, Sub-nuclear and Radiation, G. Marconi University, Rome, Italy. E-mail: [massimo.fioranelli@gmail.com](mailto:massimo.fioranelli@gmail.com)

**Received:** 10-Jul-2019; **Revised:** 08-Aug-2019; **Accepted:** 09-Aug-2019; **Online first:** 12-Sep-2019

**Copyright:** © 2019 Aleksandra Vojvodic, Zorica Peric-Hajzler, Dusica Matovic, Petar Vojvodic, Tatjana Vlaskovic-Jovicevic, Goran Sijan, Sanja Dimitrijevic, Nenad Stepic, Uwe Wollina, Badr Abdulwahab E. Badr, Ashraf Badawi, Mohamad Goldust, Michael Tirant, Van Thuong Nguyen, Massimo Fioranelli, Torello Lotti. This is an open-access article distributed under the terms of the Creative Commons Attribution-NonCommercial 4.0 International License (CC BY-NC 4.0)

**Funding:** This research did not receive any financial support

**Competing Interests:** The authors have declared that no competing interests exist

The P.N.E.I. (Psycho-Neuro-Endocrine-Immunology) approach is represented by the interdisciplinary concept of bidirectional cross-talk between the psycho-neuro-endocrine and immune systems, which can influence the immune response. The well-known Gut-Brain Axis and the Gut-Skin Axis can be merged in a bigger network- the Gut-Brain-Skin Axis, with complex regulation by cytokines, neuro-peptides, neuro-hormones and another messenger (signalling) molecules and maybe the most important modulator of the Gut-Brain-Skin Axis/ the gut microbiota. The role of gut bacterial homeostasis is very important, and the homeostatic imbalance of the immune response may be a relevant etiologic/pathophysiologic factor for extra-intestinal and intestinal inflammatory, allergic and autoimmune diseases. The Low Dose Cytokines Medicine (LDM) is an innovative therapeutic approach. It is based on the most advanced knowledge in molecular biology and low dose pharmacology with the primary outcome. The SKA (Sequential Kinetic Activation) technology, codified and standardised by GUNA S.p.a. -Italy- makes the low doses of signalling molecules able to be active even below the minimum dose classically considered as effective and the significative efficacy of orally administered low-dose signalling molecules is the most representative aspect of LDM. The Physiologic Nutraceuticals and the Low Dose Medicine are two of the most promising approaches for the treatment of skin diseases based on the rebalance of the immune response and the recovery of gut dysbiosis.

## Introduction

The P.N.E.I. (Psycho-Neuro-Endocrine-Immunology) approach is represented by the interdisciplinary concept of bidirectional cross-talk between the psycho-neuro-endocrine and immune systems, which can influence the immune response. Also, the immune system can influence the neuroendocrine functions, and this very complex interplay is mediated by a network of a lot of different

hormones, neuropeptides, growth factors, cytokines and other signalling molecules [1], [2], [3].

Skin and gut roles and relations with other organs and tissues are examples of the P.N.E.I. functioning. They are complex immune and neuroendocrine organs integrated into the whole immune-endocrine systems and the most important contact organs of all animals with the environment, with a lot of common characteristics: colonized by specific microbial strains, with a large number of vascular and neural structures, constantly exposed to

a heavy antigenic charge, represented by bacterial flora, with the tolerance of the commensal microbiota. The well-known Gut-Brain Axis and the Gut-Skin Axis can be merged in a larger network-the Gut-Brain-Skin Axis, with complex regulation by cytokines, neuropeptides, neuro-hormones and other messenger (signaling) molecules and maybe the most important modulator of the Gut-Brain-Skin Axis/the gut microbiota [2], [3], [4], [5].

## Gut microbiota

It is well known that the gastrointestinal tract is colonised by about 100 trillion bacterial population (microbiota) composed of non-commensal (pathogenic) and commensal (nonpathogenic) species. Microbiota differs in composition and also in the function based on numerous factors such as the specific GI segment but also the diet of a subject, the gender, the age, etc. The nucleus of 57 species is common to all individuals, but each human being has a specific and unique microbiota. The dominant bacterial *fila*, constituting over 90% of the species present in the human intestine, are *Bacteroides* and *Firmicutes*, but also *Lactobacilli*, *Bacteroides*, *Proteobacteria*, *Bifidobacteria* and *Streptococci* are common [3], [4], [5], [6], [7].

The role of gut bacterial homeostasis is very important, and the homeostatic imbalance of the immune response may be a relevant etiologic factor for extra-intestinal and intestinal inflammatory, allergic and autoimmune diseases. This role is not limited to its systems but the whole organism [1], [4], [8].

Gram-negative bacteria, which contain lipopolysaccharide are considered as the main proinflammatory strains, responsible for the expression of pro-inflammatory cytokines such as Interleukin-1 (IL-1) and Interleukin-6 (IL-6) [2], [9].

Formation of biofilm is identified as one of the main forms of chronic intestinal, an adherent conglomerate to the intestinal epithelium having a composition like the extracellular matrix, in which bacteria and fungi proliferate and resid. The antibiotic treatment can affect mostly the bacterial infection caused by bacteria external to the biofilm, and an immune response is not able to be fully effective on biofilm. So, biofilm could be one of the most important etiologic agents of numerous chronic inflammatory diseases, promote the persistence of a Low-Grade Chronic Inflammation (LGCI) that can lead to the Leaky Gut Syndrome, connected with the onset of autoimmune and allergic diseases [1], [10], [11], [12], [13].

The physiological inflammation is supported by Th1-related cytokines-IL-1, TNF- $\alpha$  and IL-6 and these cytokines induce the production of other pro-

inflammatory agents-adhesive molecules, chemokines, growth factors and other mediators such as prostaglandins and nitric oxide (NO) with the stimulation of the leukocyte at the site of inflammation. IL-6 acts as the secondary mediator, responsible for maintaining the inflammatory response itself. Inflammation leads to the increasing level of Interleukin-10 (IL-10), which is the most important Th2 anti-inflammatory cytokine involved in the inflammation resolution phenomenon [3], [4], [12], [13], [14].

LGCI also has systemic effects, and it is often responsible for the disruption of skin immune homeostasis and systemic diseases such as obesity, Type II Diabetes, Vitiligo, Atopic Dermatitis, Psoriasis, BPCO (Broncho-Pulmonary-Chronic-Obstructive Pulmonary Disease) or the RRI (Recurrent Respiratory Infections), Rheumatoid Arthritis, etc.

The key risk factor for the development of allergic sensitisation is the perturbation of microbiota development during the first years of life (due to maternal consumption of antimicrobials during pregnancy, formula feeding or antimicrobial exposure or caesarean birth) [15], [16], [17].

The presence of a shift ("Th1/Th2 shift") of the immunological balance as a consequence of an imbalance between the cytokines expressed by Th1/Th17 and T<sub>reg</sub>/Th2 lymphocyte subpopulations is one of the most important etiologic factors for a large number of dermatologic diseases. Th1 cytokines hyper-production is strictly linked with inflammatory and autoimmune skin diseases such as Psoriasis and Vitiligo, with the central role of a class of memory T-cells characterised by the presence of the Cutaneous Lymphocyte Antigen (CLA) on their surface and responsible for skin-homing T cell.

The presence of systemic LGCI is a strong trigger for CLA<sup>+</sup> T-cells [17], [18], [19], [20].

As two of the most important etiologic factors for many of chronic dermatologic inflammatory, autoimmune and allergic diseases, gut dysbiosis (biofilm) and LGCI are currently considered therapeutic targets, but there are no standard therapeutic opportunities to treat LGCI. Also, and very important is that the chronic use of active anti-inflammatory molecules designed for the treatment of acute inflammatory phenomena shows an unfavourable efficacy/adverse effects ratio. Anti-cytokine therapy was proposed for the treatment of inflammatory and autoimmune diseases. The need of high doses of active molecules to reach the therapeutic goal and the low compliance of systemic administration performed by injective routes are the most important and limiting pitfalls connected with the use of high dosage cytokines and other signal molecules [21], [22], [23].

The Low Dose Cytokines Medicine (LDM) is an innovative therapeutic approach. It is based on the

most advanced knowledge in molecular biology and low dose pharmacology with the primary outcome.

The SKA (Sequential Kinetic Activation) technology, codified and standardised by GUNA S.p.a. -Italy- makes the low doses of signalling molecules able to be active even below the minimum dose classically considered as effective and the significative efficacy of orally administered low-dose signalling molecules is the most representative aspect of LDM [17], [22], [23], [24].

The SKA of low dose signalling molecules activates some units of cellular (or plasmatic) receptors by their low concentration.

The researchers performed a double-blind multicenter versus placebo clinical study was conducted on a dermatologic disease in 2014 for treating patients with Psoriasis Vulgaris in order to test the LDM approach with the oral administration of low dose SKA activated cytokines with the great effectiveness of the treatment assessing improvement of the psoriatic lesions and of quality of life (PASI (Psoriasis Area Severity Index) and ii) DLQI (Dermatology Life Quality Index). This study showed the effectiveness and the safety of the SKA low dose cytokines treatment and also that the SKA low dose cytokines treatment has a long action term, which extends over the months following the end of treatment [25], [26], [27], [28].

Lotti T. and colleagues, in 2015, were organised a retrospective clinical study and the effectiveness of adopted treatments for Vitiligo were compared and analysed the clinical data collected from patients who received different treatments for Vitiligo. Patients were treated with low-dose SKA IL-10, IL-4; b-FGF and anti-IL-1 antibodies, topical treatments with cortisone cream alone or in association with both groups of low dose molecules and nbUVB radiation alone or in association with both groups of molecules low dose. Other patients were treated with oral intake of extracts from Ginkgo biloba and with exposure to natural sunlight

The treatment with low dose SKA b-FGF registered an improvement in 74% of the patients. The combination of low doses SKA IL-4, IL-10 and anti-IL-1 antibodies registered an improvement in 77% of patients. The greatest improvement was registered with the association of treatments with low dose SKA molecules and UV-B treatment which has led to improvements in 92/93. No adverse effects have been reported, and the safety and efficacy of low dose SKA were verified [29], [30], [31]. The randomised, double-blinded, controlled clinical trial included children with mild to medium IgE-mediated and non-IgE mediated Atopic Dermatitis in an acute phase of the disease was conducted using low dose SKA (IL-12 and IFN- $\gamma$ ). The main outcome was the reduction of the AD quantified as a reduction of SCORAD index of at least 30%; in the same group, the decrease of SCORAD value continues during the follow-up period reaching

64%. The treated group showed a significant reduction of the intake of drugs for symptoms control (antihistamines and topical corticosteroids) with progressive improvement of the quality of life. No adverse effects have been reported [32], [33], [34].

## Conclusions

The disruption of gut and skin homeostatic equilibrium has not only local but also systemic negative outcomes. Gut dysbiosis and inflammatory phenomena are one of the most important etiological components of many dermatologic diseases.

A rebalance action of the gut microbiota and a rebalancing of the inflammatory immune response, for the treatment of many diseases, not adequately managed with currently available therapies, are needed.

The study of biofilm formation and consolidation dynamics and the search for substances, of both natural and synthetic origin, able to intervene effectively on them, could be extremely useful.

It is now possible to design an effective treatment protocol for dysbiosis using medical devices and food supplements, also useful to prevent both dysbiosis and biofilm formation. In selected cases, faecal transplantation is needed.

The availability of Low Dose SKA signalling molecule is the most important point of LDM. Oral administration of low dose SKA signalling molecules represents the innovative core of the entire strategy for the treatment of dermatological diseases characterised by an immune imbalance and LGCI such as in Psoriasis Vulgaris, Vitiligo and Atopic Dermatitis.

The Physiologic Nutraceuticals and the Low Dose Cytokines Medicine and faecal transplantation two of the most promising approaches for the treatment of skin diseases based on the rebalance of the immune response and the recovery of gut dysbiosis.

## References

1. Haroon E, Raison CL, Miller AH. Psychoneuroimmunology meets neuropsychopharmacology: translational implications of the impact of inflammation on behavior. *Neuropsychopharmacology*. 2012; 37(1):137-62. <https://doi.org/10.1038/npp.2011.205> PMID:21918508 PMCID:PMC3238082
2. Bacchus W, Aubel D, Fussenegger M. Biomedically relevant circuit-design strategies in mammalian synthetic biology. *Mol Syst*

- Biol. 2013; 9:691. <https://doi.org/10.1038/msb.2013.48> PMID:24061539 PMCID:PMC3792348
3. Tojo R, Suárez A, Clemente MG, de los Reyes-Gavilán CG, Margolles A, Gueimonde M, Ruas-Madiedo P. Intestinal microbiota in health and disease: role of bifidobacteria in gut homeostasis. *World J Gastroenterol.* 2014; 20(41):15163-76. <https://doi.org/10.3748/wjg.v20.i41.15163> PMID:25386066 PMCID:PMC4223251
4. Myles IA, Williams KW, Reckhow JD, Jammeh ML, Pincus NB, Sastalla I, Saleem D, et al. Transplantation of human skin microbiota in models of atopic dermatitis. *JCI Insight.* 2016; 1(10):e86955. <https://doi.org/10.1172/jci.insight.86955> PMID:27478874 PMCID:PMC4963067
5. Pickard JM, Zeng MY, Caruso R, Núñez G. Gut microbiota: Role in pathogen colonization, immune responses, and inflammatory disease. *Immunol Rev.* 2017; 279(1):70-89. <https://doi.org/10.1111/immr.12567> PMID:28856738 PMCID:PMC5657496
6. O'Neill CA, Monteleone G, McLaughlin JT, Paus R. The gut-skin axis in health and disease: A paradigm with therapeutic implications. *Bioessays.* 2016. <https://doi.org/10.1002/bies.201600008> PMID:27554239
7. Underhill DM, Iliev ID. The mycobiota: interactions between commensal fungi and the host immune system. *Nat Rev Immunol.* 2014; 14(6):405-16. <https://doi.org/10.1038/nri3684> PMID:24854590 PMCID:PMC4332855
8. Lynch SV. Gut Microbiota and Allergic Disease. *New Insights. Ann Am Thorac Soc.* 2016; 13(1):S51-4.
9. Chen L, Wen YM. The role of bacterial biofilm in persistent infections and control strategies. *Int J Oral Sci.* 2011; 3(2):66-73. <https://doi.org/10.4248/IJOS11022> PMID:21485310 PMCID:PMC3469879
10. Brauner A, Söderhäll M, Jacobson SH, Lundahl J, Andersson U, Andersson J. Escherichia coli-induced expression of IL-1 alpha, IL-1 beta, IL-6 and IL-8 in normal human renal tubular epithelial cells. *Clin Exp Immunol.* 2001; 124(3):423-8. <https://doi.org/10.1046/j.1365-2249.2001.01533.x> PMID:11472403 PMCID:PMC1906084
11. Huang YJ, Marsland BJ, Bunyavanich S, O'Mahony L, Leung DY, Muraro A, Fleisher TA. The microbiome in allergic disease: Current understanding and future opportunities-2017 PRACTALL document of the American Academy of Allergy, Asthma & Immunology and the European Academy of Allergy and Clinical Immunology. *J Allergy Clin Immunol.* 2017; 139(4):1099-1110. <https://doi.org/10.1016/j.jaci.2017.02.007> PMID:28257972 PMCID:PMC5899886
12. Lee SY, Lee E, Park YM, Hong SJ. Microbiome in the Gut-Skin Axis in Atopic Dermatitis. *Allergy Asthma Immunol Res.* 2018; 10(4):354-362. <https://doi.org/10.4168/aa.2018.10.4.354> PMID:29949831 PMCID:PMC6021588
13. Hueston CM, Deak T. The inflamed axis: the interaction between stress, hormones, and the expression of inflammatory-related genes within key structures comprising the hypothalamic-pituitary-adrenal axis. *Physiol Behav.* 2014; 124:77-91. <https://doi.org/10.1016/j.physbeh.2013.10.035> PMID:24184413
14. Opazo MC, Ortega-Rocha EM, Coronado-Arrázola I, Bonifaz LC, Boudin H, Neunlist M, Bueno SM, et al. Intestinal Microbiota Influences Non-intestinal Related Autoimmune Diseases. *Front Microbiol.* 2018; 9:432. <https://doi.org/10.3389/fmicb.2018.00432> PMID:29593681 PMCID:PMC5857604
15. Mancuso P. The role of adipokines in chronic inflammation. *Immunotargets Ther.* 2016; 5:47-56. <https://doi.org/10.2147/ITT.S73223> PMID:27529061 PMCID:PMC4970637
16. Kraljević Pavelić S, Simović Medica J, Gumbarević D, Filošević A, Pržulj N, Pavelić K. Critical Review on Zeolite Clinoptilolite Safety and Medical Applications in vivo. *Front Pharmacol.* 2018; 9:1350. <https://doi.org/10.3389/fphar.2018.01350> PMID:30538633 PMCID:PMC6277462
17. Van den Wijngaard R, Wankowicz-Kalinska A, Le Poole C, Tigges B, Westerhof W, Das P. Local immune response in skin of generalized vitiligo patients. Destruction of melanocytes is associated with the prominent presence of CLA+ T cells at the perilesional site. *Lab Invest.* 2000; 80(8):1299-309. <https://doi.org/10.1038/labinvest.3780138> PMID:10950121
18. Pallešchi G, Carbone A, Zanello PP, Mele R, Leto A, Fuschi A, Al Salhi Y, et al. Prospective study to compare antibiotics versus the association of N-acetylcysteine, D-mannose and Morinda citrifolia fruit extract in preventing urinary tract infections in patients submitted to urodynamic investigation. *Arch Ital Urol Androl.* 2017; 89(1):45-50. <https://doi.org/10.4081/aiua.2017.1.45> PMID:28403598
19. Prasai TP, Walsh KB, Bhattarai SP, Midmore DJ, Van TT, Moore RJ, Stanley D. Biochar, Bentonite and Zeolite Supplemented Feeding of Layer Chickens Alters Intestinal Microbiota and Reduces Campylobacter Load. *PLoS One.* 2016; 11(4):e0154061. <https://doi.org/10.1371/journal.pone.0154061> PMID:27116607 PMCID:PMC4845986
20. Yeo CK, Vikhe YS, Li P, Guo Z, Greenberg P, Duan H, Tan NS, et al. Hydrogel Effects Rapid Biofilm Debridement with ex situ Contact-Kill to Eliminate Multidrug Resistant Bacteria in vivo. *ACS Appl Mater Interfaces.* 2018; 10(24):20356-20367. <https://doi.org/10.1021/acsami.8b06262> PMID:29806938
21. Marcum ZA, Hanlon JT. Recognizing the Risks of Chronic Nonsteroidal Anti-Inflammatory Drug Use in Older Adults. *Ann Longterm Care.* 2010; 18(9):24-27.
22. Renukuntla J, Vadlapudi AD, Patel A, Boddu SH, Mitra AK. Approaches for enhancing oral bioavailability of peptides and proteins. *Int J Pharm.* 2013; 447(1-2):75-93. <https://doi.org/10.1016/j.ijpharm.2013.02.030> PMID:23428883 PMCID:PMC3680128
23. Biancotto A, Wank A, Perl S, Cook W, Olmes MJ, Dagur PH, et al. Baseline levels and temporal stability of 27 multiplexed serum cytokine concentrations in healthy subjects. *PLoS One.* 2013; 8(12):e76091. <https://doi.org/10.1371/journal.pone.0076091> PMID:24348989 PMCID:PMC3861126
24. Roberti ML, Ricottini L, Capponi A, Sciauzero E, Vicenti P, et al. Immunomodulating treatment with low dose Interleukin-4, Interleukin-10 and Interleukin-11 in psoriasis vulgaris. *J Biol Regul Homeost Agents.* 2014; 28(1):133-9.
25. Luchetti P. Increasing of visual function in patients with retinal atrophy treated with drugs of Low Dose Medicine. Monocentric retrospective observational study. *Minerva Medica Oftalmologica.* 2014; 56(3-4):53-61.
26. Cardani D, Dusio GF, Luchini P, Sciarabba M, Solimene U, Rumio C. Oral Administration of Interleukin-10 and Anti-IL-1 Antibody Ameliorates Experimental Intestinal Inflammation. *Gastroenterology Research.* 2013; 6:124-133. <https://doi.org/10.4021/gr556w> PMID:27785242 PMCID:PMC5074810
27. Barygina V, Becatti M, Lotti T, Taddei N, Fiorillo C. Low dose cytokines reduce oxidative stress in primary lesional fibroblasts obtained from psoriatic patients. *J Dermatol Sci.* 2016; 83(3):242-4. <https://doi.org/10.1016/j.jdermsci.2016.06.002> PMID:27317477
28. Lotti T, Hercogova J, Wollina U, et al. Vitiligo: successful combination treatment based on oral low dose cytokines and different topical treatments. *J Biol Regul Homeost Agents.* 2015; 29(1):53-8.
29. Radice E, Bellone G, Miranda V. Enhancement of the immunomodulatory functions of ex vivo-generated dendritic cells from early-stage colon cancer patients by consecutive exposure to low doses of sequential kinetic activated IL-4 and IL-12. A preliminary study. *Translational Oncology.* 2015; 8:327-38. <https://doi.org/10.1016/j.tranon.2015.06.005> PMID:26310379 PMCID:PMC4562983
30. Lotti T, et al. Successful combination treatment for Psoriasis with phototherapy and Low Dose Cytokines. A spontaneous observational retrospective clinical study. *Der Hautarzt* 2015; 66(11):849-54. <https://doi.org/10.1007/s00105-015-3698-6> PMID:26449546

31. Genazzani AD, Despini G, Chierchia E, Benedetti C, Prati A. Pharmacological and integrative treatment of stress-induced hypothalamic amenorrhea. In *Frontiers in Gynecological Endocrinology*. Springer, Cham, 2016:69-84. [https://doi.org/10.1007/978-3-319-23865-4\\_9](https://doi.org/10.1007/978-3-319-23865-4_9)
32. Kim JE, Kim HS. Microbiome of the Skin and Gut in Atopic Dermatitis (AD): Understanding the Pathophysiology and Finding Novel Management Strategies. *J Clin Med*. 2019; 8(4):E444. <https://doi.org/10.3390/jcm8040444> PMID:30987008 PMCid:PMC6518061
33. Barygina V, Becatti M, Lotti T, Moretti S, Taddei N, et al. Treatment with low-dose cytokines reduces oxidative-mediated injury in perilesional keratinocytes from vitiligo skin. *J Dermatol Sci*. 2015; 79(2): 163-70. <https://doi.org/10.1016/j.jdermsci.2015.05.003> PMID:26051876
34. Fiorito F, Cantiello A, Granato GE, Navas L, Diffidenti C, De Martino L, Maharajan V, et al. Clinical improvement in feline herpesvirus 1 infected cats by oral low dose of interleukin-12 plus interferon-gamma. *Comp Immunol Microbiol Infect Dis*. 2016; 48:41-7. <https://doi.org/10.1016/j.cimid.2016.07.006> PMID:27638118

# Erythema Elevatum Diutinum - Two Case Reports, Two Different Clinical Presentations, and a Short Literature Review

Uwe Wollina<sup>1\*</sup>, Claudia Krönert<sup>1</sup>, André Koch<sup>1</sup>, Jacqueline Schönlebe<sup>2</sup>, Aleksandra Vojvodic<sup>5</sup>, Torello Lotti<sup>6</sup>

<sup>1</sup>Department of Dermatology and Allergology, Städtisches Klinikum Dresden, Academic Teaching Hospital, Dresden, Germany; <sup>2</sup>Institute of Pathology "Georg Schmorl", Städtisches Klinikum Dresden, Academic Teaching Hospital, Dresden, Germany; <sup>3</sup>Military Medical Academy of Belgrade, Belgrade, Serbia; <sup>4</sup>Department of Dermatology, University of Rome "G. Marconi", Rome, Italy

## Abstract

**Citation:** Wollina U, Krönert C, Koch A, Schönlebe J, Vojvodic A, Lotti T. Elevatum Diutinum - Two Case Reports, Two Different Clinical Presentations, and a Short Literature Review. Open Access Maced J Med Sci. 2019 Sep 30; 7(18):3039-3042. <https://doi.org/10.3889/oamjms.2019.765>

**Keywords:** Leukocytoclastic vasculitis; Infections; Autoimmune disorders; Hematologic disorders; Dapsone; Erythema elevatum diutinum

**\*Correspondence:** Uwe Wollina, Department of Dermatology and Allergology, Städtisches Klinikum Dresden, Academic Teaching Hospital, Dresden, Germany. E-mail: uwollina@gmail.com

**Received:** 18-Apr-2019; **Revised:** 04-Jul-2019; **Accepted:** 05-Jul-2019; **Online first:** 30-Aug-2019

**Copyright:** © 2019 Uwe Wollina, Claudia Krönert, André Koch, Jacqueline Schönlebe, Aleksandra Vojvodic, Torello Lotti. This is an open-access article distributed under the terms of the Creative Commons Attribution-NonCommercial 4.0 International License (CC BY-NC 4.0)

**Funding:** This research did not receive any financial support

**Competing Interests:** The authors have declared that no competing interests exist

**BACKGROUND:** Erythema elevatum diutinum (EED) belongs to the spectrum of cutaneous leukocytoclastic vasculitides. EED is a very rare dermatosis presenting with reddish to brownish papules and plaques. EED may be associated with infections, hematologic and autoimmune disorders.

**CASE REPORTS:** We present two patients with EED, a 50-year-old woman and a 42-year-old man. While the woman shows an association with colitis ulcerosa, the man had an anti-thrombin deficiency. Treatment was started with oral corticosteroid and dapsone, respectively. In both cases, there was a partial and temporary response.

**CONCLUSIONS:** EED is a rare vasculitis with an unusual clinical presentation and a chronic course. Response to treatment is unsatisfactory and in the long-term run sometimes frustrating.

## Introduction

Erythema elevatum diutinum (EED) belongs to the heterogeneous group of cutaneous leukocytoclastic vasculitides. It is a rare disorder, with less than 150 cases reported worldwide. It runs a chronic course with a fluctuating severity [1].

The characteristic clinical features are often symptomless plaques and nodules with a preference of extensor areas. There is neither a racial nor gender preference. The peak incidence seems to be in the fourth to the sixth decade [2].

Histologically, the disease is a leuko-

cytotoxic vasculitis of the mid and upper dermis. Polymorphonuclear cells, macrophages, histiocytes dominate the infiltrate. Some eosinophils may be present. In the early stage, there is papillary oedema causing pseudo-vesiculation. In long-standing lesions, dermal vessels become dilated with hypertrophic and sometimes protruding endothelial cells. Sometimes nodular lesions may be present containing spindle cells which are expressing Mac-387. Immune complexes may become deposited, and granulomas can appear [3], [4].

Infections have been associated with EED such as human deficiency virus and AIDS, hepatitis B or syphilis [5], [6]. There are several reports on the

association of EED with haematological disorders such as clonal gammopathy, or autoimmune connective tissue diseases like lupus erythematosus, dermatomyositis, chronic inflammatory bowel disease, Wegener's granulomatosis or relapsing polychondritis [2]. Cocaine adulterated with levamisole can induce an EED-like vasculitis [7].

## Case Report

### Case 1

A 50-years-old woman presented with chronic plaques on the extensor surface of both hands for four years. Sometimes, she noted swelling of the hands or suggillations into the plaques. She suffered from colitis ulcerosa. More than 10 years ago a colectomy had been performed. She was treated with ispaghula (Psylla seeds), loperamide, tolterodine tartrate, and topical intra-anal corticosteroid foam.

On examination, we observed multiple erythematous-livid nodules and plaques of a relatively soft consistency on the back of her hands (Figure 1).

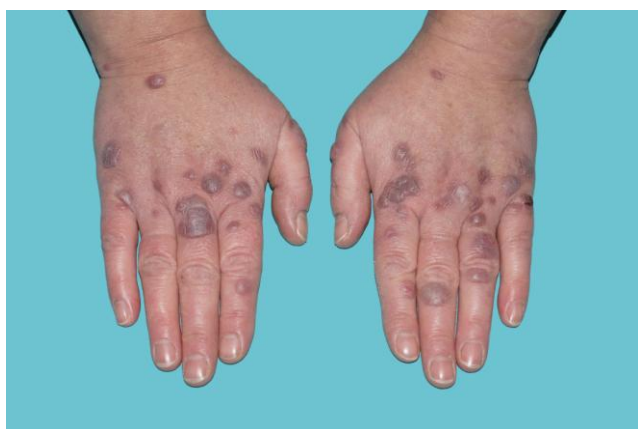

Figure 1: Erythema elevatum diutinum late-stage lesion on the hands (case 1)

Laboratory investigations: Anti-thrombin was reduced with 54% (normal range: 75-125), slightly increased were gamma globulins 13.5% (7.2-11.3) and lactate dehydrogenase 3.85  $\mu$ kat/L (2.25-3.55). Negative or in the normal range were an immune fixation, HIV-antibodies, cardiolipin antibodies, and rheumatoid factor.

Imaging (endo-sonography, sigmoidoscopy, abdominal magnetic resonance imaging (MRI)) was unremarkable, except for a pouchitis.

Histopathology from a skin biopsy revealed increased vascularity (mainly post-capillary venules) embedded in a slightly fibrotic connective tissue. Perivascular infiltrates consisted of lymphocytes, monocytes, and some neutrophils (Figure 2).

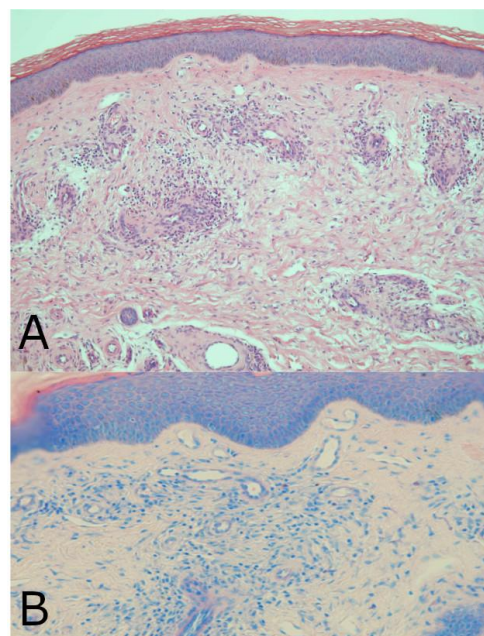


Figure 2: Histopathology of erythema elevatum diutinum (Case 1); A) Hematoxylin-eosin (x 10); B) Giemsa stain (x 20)

The findings were interpreted as a late stage of EED. We compared our findings with an external histopathology report 3 years ago, where the lesions demonstrated the characteristic leukocytoclastic vasculitis signs.

We initiated oral treatment with methylprednisolone 32 mg/day and topical treatment with clobetasol 0.05% ointment. The lesions became flatter, but the patient developed arterial hypertension and headaches. The internal corticosteroid therapy was stopped. Neither cyclosporine A nor methotrexate were effective. Dapsone 100 mg/day was not tolerated due to increased meth-haemoglobin levels.

### Case 2

Two years ago, a 42-years-old man developed some papules on the knees with minimal pruritus. Dark red and livid papules and plaques appeared on arms. The course was characterized by waxing and waning. His medical history was otherwise unremarkable. He had no medical drug treatment.

On examination, we observed multiple erythematous to brownish asymptomatic papules on the extremities (knees, forearms, elbows, and back of the hands). The maximum diameter was 2 cm. Some of the lesions disappeared, leaving atrophic scars (Figure 3).

A skin biopsy demonstrated upper dermal leukocytoclastic vasculitis and massive neutrophilic nuclear debris and discrete extravasates of erythrocytes.

Laboratory investigations were unremarkable. Antinuclear antibodies, paraproteins, and anti-



streptolysin titer were negative.

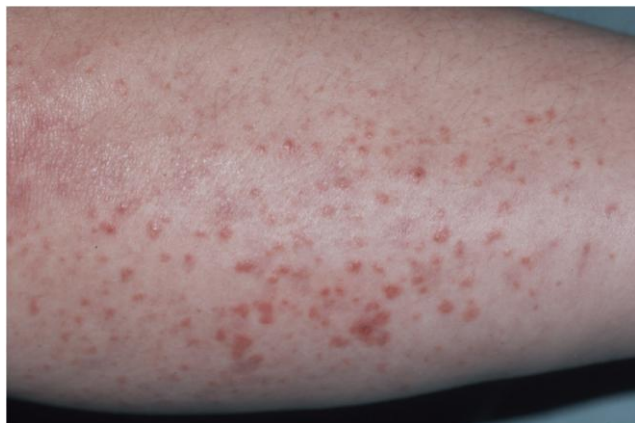

Figure 3: Erythema elevatum diutinum – earlier lesions (Case 2)

The diagnosis of EED was confirmed.

We initiated oral treatment with dapsons 100 mg/day. Lesions showed regression leaving hyperpigmented scars. After dose reduction, a partial relapse was observed, and the dose was increased to 100 mg per day.

## Discussion

EED is a rare leukocytoclastic vasculitis of the mid and upper dermis, that can be associated with underlying disorders like autoimmune diseases, haematological conditions or chronic infections [1], [2]. It has a good prognosis in contrast to systemic leukocytoclastic vasculitides although the course is chronic [8].

We report on EED with two different clinical patterns – A) the classical nodules and plaques overlying the joints of upper extremities and B) disseminated papules on legs and arms. Rarely, vesiculobullous lesions have been reported suggesting Sweet syndrome [9].

The course of the disease is characterized by chronicity with waxing and waning of lesions. We presented a late-stage and an earlier stage of EED. The characteristics of leukocytoclastic vasculitis are seen in earlier lesions with prominent endothelial cells, but they get lost, and the perivascular connective tissue becomes fibrotic [3], [4].

The most commonly used therapy is oral dapsons, with a response rate of up to 80%. The drug inhibits neutrophil chemotaxis and function. A complete resolution is not always possible. In nodular lesions, this drug has only limited efficacy. Many patients with nodules do not respond [2].

Dapsons is contraindicated in patients with a

glucose-6-phosphate deficiency where it can cause severe hemolytic anaemia. Dapsons hypersensitivity is another important adverse effect. Pancytopenia has occasionally been observed [10],

Second-line therapies are systemic corticosteroids, colchicine, methotrexate, chloroquine and anti-retroviral drugs in case of HIV-associated EED. Antimicrobials with suppressive effects on neutrophils such as tetracyclines, erythromycin or sulfonamides have been used in single cases with success. Nicotinamide may be used in combination with tetracyclines or as a single drug. Topical therapy with corticosteroids, retinoids or dapsons is of limited value [11].

In conclusion, EED is part of the spectrum of leukocytoclastic vasculitides of skin. Although the lesions are commonly asymptomatic, they are disfiguring, and treatment is demanded. Based on experience, dapsons is the most often used drug. In the long-term run, however, medical treatment of EED is unsatisfactory and sometimes frustrating.

## References

1. Doktor V, Hadi A, Hadi A, Phelps R, Goodheart H. Erythema elevatum diutinum: a case report and review of literature. *Int J Dermatol.* 2019; 58(4):408-415. <https://doi.org/10.1111/ijd.14169> PMID:30074624
2. Momen SE, Jorizzo J, Al-Niimi F. Erythema elevatum diutinum: a review of presentation and treatment. *J Eur Acad Dermatol Venereol.* 2014; 28(12):1594-602. <https://doi.org/10.1111/jdv.12566> PMID:25288365
3. Wilkinson SM, English JS, Smith NP, Wilson-Jones E, Winkelmann RK. Erythema elevatum diutinum: a clinicopathological study. *Clin Exp Dermatol.* 1992; 17(2):87-93. <https://doi.org/10.1111/j.1365-2230.1992.tb00171.x> PMID:1516248
4. LeBoit PE, Yen TS, Wintroub B. The evolution of lesions in erythema elevatum diutinum. *Am J Dermatopathol.* 1986; 8(5):392-402. <https://doi.org/10.1097/00000372-198610000-00005> PMID:3777377
5. Cardis MA, Sowash MG, Mosojane KI, Kovarik C, Williams V. HIV-associated erythema elevatum diutinum: a case report and review of a clinically distinct variant. *Dermatol Online J.* 2018; 24(5).
6. Hoy JV, Kikam A, Tyler K, Peters SB, Kaffenberger BH. Unusual presentation of erythema elevatum diutinum with underlying hepatitis B infection. *Cutis.* 2018; 101(6):462-5.
7. Dewan AK, Pinard J, Jadeja S, Granter S, Merola JF. Erythema elevatum diutinum-like vasculitis secondary to cocaine adulterated with levamisole. *Clin Exp Dermatol.* 2018; 43(4):494-6. <https://doi.org/10.1111/ced.13392> PMID:29423942
8. Bouiller K, Audia S, Devilliers H, Collet E, Aubriot MH, Leguy-Seguain V, Berthier S, Bonniaud P, Chavanet P, Besancenot JF, Vabres P, Martin L, Samson M, Bonnotte B. Etiologies and prognostic factors of leukocytoclastic vasculitis with skin involvement: A retrospective study in 112 patients. *Medicine (Baltimore).* 2016; 95(28):e4238. <https://doi.org/10.1097/MD.0000000000004238> PMID:27428231 PMID:27428231
9. Ossorio-García L, Jiménez-Gallo D, Arjona-Aguilera C, Salamanca-Sánchez M, Linares-Barrios M. Vesiculobullous variant

of erythema elevatum diutinum. Clin Exp Dermatol. 2017; 42(7):777-80. <https://doi.org/10.1111/ced.13166> PMID:28639709

10. Kocatürk E, Memet B, Topal IO, Yüksel T, Ülkümen PK, Kızıldağ U. A Case of Erythema Elevatum Diutinum With Pancytopenia: Focus on Dapsone-Induced Hematologic Side Effects and Colchicine as a Safe Treatment Option. J Drugs Dermatol. 2015; 14(10):1090-2.

11. Frieling GW, Williams NL, Lim SJ, Rosenthal SI. Novel use of topical dapsone 5% gel for erythema elevatum diutinum: safer and effective. J Drugs Dermatol. 2013; 12(4):481-4.

# Psychological Impact of Melanoma, How to Detect, Support and Help

Aleksandra Vojvodic<sup>1</sup>, Tatjana Vlaskovic-Jovicevic<sup>2</sup>, Petar Vojvodic<sup>2</sup>, Jovana Vojvodic<sup>2</sup>, Mohamad Goldust<sup>3</sup>, Zorica Peric-Hajzler<sup>4</sup>, Dusica Matovic<sup>4</sup>, Goran Sijan<sup>5</sup>, Nenad Stepic<sup>5</sup>, Van Thuong Nguyen<sup>6</sup>, Michael Tirant<sup>7</sup>, Uwe Wollina<sup>8</sup>, Torello Lotti<sup>9</sup>, Massimo Fioranelli<sup>10</sup>

<sup>1</sup>Department of Dermatology and Venereology, Military Medical Academy, Belgrade, Serbia; <sup>2</sup>Clinic for Psychiatric Disorders "Dr. Laza Lazarevic", Belgrade, Serbia; <sup>3</sup>Guglielmo Marconi University, Rome, Italy; <sup>4</sup>Military Medical Academy, Belgrade, Serbia; <sup>5</sup>Clinic for Plastic Surgery and Burns, Military Medical Academy, Belgrade, Serbia; <sup>6</sup>Vietnam National Hospital of Dermatology and Venereology, Hanoi, Vietnam; <sup>7</sup>Guglielmo Marconi University, Rome, Italy; <sup>8</sup>Department of Dermatology and Allergy, Städtisches Klinikum Dresden, Dresden, Germany; <sup>9</sup>Department of Dermatology, Guglielmo Marconi University, Rome, Italy; <sup>10</sup>Department of Nuclear Physics, Sub-nuclear and Radiation, G. Marconi University, Rome, Italy

## Abstract

**Citation:** Vojvodic A, Vlaskovic-Jovicevic T, Vojvodic P, Vojvodic J, Goldust M, Peric-Hajzler Z, Matovic D, Sijan G, Stepic N, Nguyen VT, Tirant M, Wollina U, Lotti T, Fioranelli M. Psychological Impact of Melanoma, How to Detect, Support and Help. *Open Access Maced J Med Sci.* 2019 Sep 30; 7(18):3043-3045. <https://doi.org/10.3889/oamjms.2019.770>

**Keywords:** Melanoma; Psychology; Depression; Anxiety

**\*Correspondence:** Massimo Fioranelli, Department of Nuclear Physics, Sub-nuclear and Radiation, G. Marconi University, Rome, Italy. E-mail: [massimo.fioranelli@gmail.com](mailto:massimo.fioranelli@gmail.com)

**Received:** 13-Jun-2019; **Revised:** 04-Jul-2019; **Accepted:** 05-Jul-2019; **Online first:** 30-Aug-2019

**Copyright:** © 2019 Aleksandra Vojvodic, Tatjana Vlaskovic-Jovicevic, Petar Vojvodic, Jovana Vojvodic, Mohamad Goldust, Zorica Peric-Hajzler, Dusica Matovic, Goran Sijan, Nenad Stepic, Van Thuong Nguyen, Michael Tirant, Uwe Wollina, Torello Lotti, Massimo Fioranelli. This is an open-access article distributed under the terms of the Creative Commons Attribution-NonCommercial 4.0 International License (CC BY-NC 4.0)

**Funding:** This research did not receive any financial support

**Competing Interests:** The authors have declared that no competing interests exist

Incidence of melanoma is increasing every year. A few years ago, we could not speak about long term survivors with melanoma. Chemotherapy did not give a good effect in the past. Metastasis occurred very rapidly, and the progression of melanoma was very fast. But now, with new forms of therapy, especially immunotherapy and target therapy, for the first time, we have long-time survivors. For the prognosis of melanoma, the most important is the stage in which melanoma is detected. For all dermatologists, it is very important to be aware of the psychological impact of melanoma on patients. Dermatologists should recognise psychological disorders. Several different scales can be used for the detection of depression and anxiety – some of them are completed by researchers, some of them are completed by patients, and also, we have combined scales. The need for adequate social and family support as well as psychological help to achieve better coping with illness is necessary. Learning techniques to overcome fear and stress would help in better functioning of all affected, regardless of the stage of the disease. The most severe cases of anxiety and depression, in addition to psychotherapeutic interventions, should also be considered medication therapy.

## Introduction

Incidence of melanoma is increasing every year. There are different sources with different data, very controversial, but it is evident increasing in incidence, especially in men over the age of 60. It is more frequent in young girls than in young men probably because of the use of the sunbeds. But, in Australia, New Zealand, the USA, North and Eastern Europe incidence is the highest. The fair-skinned, overexposed white population is in the greatest risk.

A few years ago, we could not speak about long term survivors with melanoma. Chemotherapy did not give a good effect in the past. Metastasis

occurred very rapidly, and the progression of melanoma was very fast. In young people, progression was even more aggressive. Living with melanoma was not considered and occurred very rarely. But now, with new forms of therapy, especially immunotherapy and target therapy, for the first time, we have long-time survivors. For the prognosis of melanoma, the most important is the stage in which melanoma is detected. If it is detected in the IA stage 5-years survival is 97%, but if it is detected in the IV stage 5-years survival is only 15%. Living with melanoma is not easy, even if it is detected in the first stage. Follow up procedures every 3 or 6 months, laboratory testing, different examinations, surgery interventions, skin checking and other follow up procedures are very hard for all patients. Fear of the

progression of the disease is always present, even if it is diagnosed in the IA stage. Sometimes, but not so frequently, depression is also detected. We can mostly detect depressive symptoms, or minor depressive disorder and very rarely major depressive disorder.

### The most frequent psychological disorders and scales

For all dermatologists, it is very important to be aware of the psychological impact of melanoma on patients. Dermatologists should recognise psychological disorders. Depressed mood, loss of interest/pleasure, significant weight loss or weight gain without trying to, insomnia or hypersomnia, psychomotor agitation/retardation, daily fatigue or loss of energy, feelings of worthlessness or excessive guilt, inability or difficulty with thinking, concentrating, and making decisions, suicidal thoughts, plans to commit suicide, or a suicide attempt. Sometimes, very rarely, we can detect symptoms of psychosis-delusions or hallucinations. For the diagnosis of major depressive disorders, it is necessary coexistence of 5-9 symptoms that last at least 2 weeks. For diagnosis of minor depressive disorder coexistence of 2 / 4 symptoms that last at least 2 weeks are necessary. Dysthymic disorder is different, and it is characterised by the depressive mood that lasts longer than 2 years, with mostly 2-6 symptoms.

Several different scales can be used for detection of depression – some of them are completed by researchers, some of them are completed by patients, and also, we have combined scales. Some of the scales completed by researchers are the Hamilton Depression Rating Scale, Montgomery-Åsberg Depression Rating Scale, Raskin Depression Rating Scale. But for dermatologists and screening programs, the most important are scales completed by patients. The Beck Depression Inventory is a scale that is in use very frequently. It consists of a 21-question, and it is self-report inventory that covers different symptoms that are present in depression such as fatigue, lack of interest in sex, weight loss, feelings of guilt, hopelessness, etc. The scale is completed by patients to identify the presence and severity of symptoms consistent with the DSM-IV diagnostic criteria. The next very frequently used self-reported questionnaire is The Patient Health Questionnaire (PHQ). The Patient Health Questionnaire-9 (PHQ-9) is a self-reported, 9-question version of the Primary Care Evaluation of Mental Disorders and it is very useful for quick screening. The Patient Health Questionnaire-2 (PHQ-2) is a shorter version of the PHQ-9 with only two questions to assess the presence of a depressed mood and a loss of interest or pleasure in routine

activities. If it is detected, further testing is needed. Other scales that can be used are The Geriatric Depression Scale (GDS), Zung Self-Rating Depression Scale, The Clinically Useful Depression Outcome Scale (CUDOS), The Inventory of Depressive Symptomatology (IDS), The Mood and Feelings Questionnaire (MFQ), The Quick Inventory of Depressive Symptoms (QIDS), The Jacobson Joy Inventory (JJI)-Research in process-Banner University Medical Center, The Positive Health Questionnaire (PHQ) Research in process-Banner University Medical Center, etc.

Anxiety is very frequent, and it can be detected in almost all patients with melanoma. It is a feeling of apprehension caused by anticipation of an ill-defined threat or danger that is not based. Components of anxiety are emotional, cognitive anticipation (memory), behavioural and somatic. There are different scales for measuring level of anxiety – Brief fear negative evaluation scale / BFNE, depression anxiety stress scales-DASS-21, Generalized anxiety disorder questionnaire IV – GADQ-IV, generalized anxiety disorder-GAD 7 (Table 1), Hamilton Anxiety rating scale – HARS, Leibowitz social anxiety scale – LSAS, overall anxiety severity and impairment scale (OASIS), hospital anxiety and depression scale – HADS, patient health questionnaire 4 – PHQ-4, Penn state worry questionnaire – PSWQ, etc.

**Table 1: Depression and symptoms**

Major depressive disorder	Minor depressive disorder	Dysthymia	Symptoms
2 weeks duration	2 weeks duration	2 years duration	1. depressed mood
Depressed mood or loss of interest	Depressed mood or loss of interest	Depressed mood	2. loss of interest/pleasure
			3. significant weight loss or weight gain without trying to
			4. insomnia or hypersomnia
			5. psychomotor agitation/retardation
			6. daily fatigue or loss of energy
			7. feelings of worthlessness or excessive guilty
			8. inability or difficulty with thinking, concentrating and making decisions
			9. suicidal thoughts, plans to commit suicide, or a suicide attempt
5 of 9 Symptoms	2-4 of 9 Symptoms	2-6 Symptoms	

For dermatologists, for fast screening, GAD-7 and BAI are very useful. They are self-reported questionnaires, and very fast, and with a high-quality dermatologist can detect the level of anxiety (Table 2).

**Table 2: Generalized anxiety disorder- GAD 7**

Over the last 2 weeks, how often have you been bothered by the following problems?	Not at all sure	Several days	Over half the days	Nearly every day
1. Feeling nervous, anxious, or on edge	0	1	2	3
2. Not being able to stop or control worrying	0	1	2	3
3. Worrying too much about different things	0	1	2	3
4. Trouble relaxing	0	1	2	3
5. Being so restless that it's hard to sit still	0	1	2	3
6. Becoming easily annoyed or irritable	0	1	2	3
7. Feeling afraid as if something awful might happen	0	1	2	3
Add the score for each column				
Total Score (add your column scores) =				

If dermatologist detects any level of anxiety or

some of depressive symptoms, it is necessary to advise patient to visit psychologist, psychotherapist or psychiatrist. How patient will accept the disease depends very much on their mechanisms of defence. Also, support and help are necessary, the first from the family members, friends, colleges, but also from doctors/ dermatologists, and at the and professional help from psychiatrists, psychologists and psychotherapists.

There are described mostly three general theoretical coping styles in the psycho-oncology literature: 1) Active-behavioral coping – this coping style refers to overt behavioural attempts to deal directly with cancer and its effects; 2) Active cognitive coping, this coping style includes one's attitudes, beliefs, and thoughts about cancer; 3) Avoidance coping, this coping style refers to attempts to actively avoid the problem or indirectly reduce emotional tension through the use of distraction. All these mechanisms of coping are useful but not equally.

In conclusion, the need for adequate social and family support as well as psychological help in order to achieve better coping with illness is necessary. Learning techniques to overcome fear and stress would help in better functioning of all affected, regardless of the stage of the disease. The most severe cases of anxiety and depression, in addition to psychotherapeutic interventions should also be considered medication therapy. The need for a multidisciplinary team that would be involved in monitoring the patient from the moment of the establishing the diagnosis of melanoma is of exceptional importance and include dermatologist, surgeon, radiotherapist, neurologist and psychiatrist, psychologist, psychotherapist.

## References

1. Vojvodic A, Dedic G. Depression, anxiety and quality of life in patients with melanoma. *VSP*, 2018. <https://doi.org/10.2298/VSP180414185V>
2. Vojvodic A, Dedic G. Quality of Life and Anxiety in Military Personnel. *SJECR*, 2017.
3. Lotti T, Bruscinò N, Hercogova J, de Giorgi V. Controversial issues on melanoma. *Dermatol Ther*. 2012; 25(5):458-62. <https://doi.org/10.1111/j.1529-8019.2012.01524.x> PMID:23046025
4. Campolmi E, et al. Melanoma diagnosis: traumatic impact of the event on the patient. *G Ital Dermatol Venereol*. 2019.
5. de Giorgi V, Gori A, Grazzini M, Rossari S, Scarfi F, Corciova S, Verdelli A, Lotti T, Massi D. Estrogens, estrogen receptors and melanoma. *Expert Rev Anticancer Ther*. 2011;11(5):739-47. <https://doi.org/10.1586/era.11.42> PMID:21554049
6. De Giorgi V, Grazzini M, Gandini S, Benemei S, Lotti T, Marchionni N, Geppetti P. Treatment with  $\beta$ -blockers and reduced disease progression in patients with thick melanoma. *Arch Intern Med*. 2011; 171(8):779-81. <https://doi.org/10.1001/archinternmed.2011.131> PMID:21518948
7. Rogiers A, Boekhout A, Schwarze JK, Awada G, Blank CU, Neyns B. Long-Term Survival, Quality of Life, and Psychosocial Outcomes in Advanced Melanoma Patients Treated with Immune Checkpoint Inhibitors. *J Oncol*. 2019. <https://doi.org/10.1155/2019/5269062> PMID:31182961 PMID:PMC6512024
8. Heino PJ, Mylläri PH, Jahkola TA, Sintonen H, Luoma ML, Räsänen P, Roine RP. Long-Term Quality of Life of Melanoma Survivors Is Comparable to that of the General Population. *Anticancer Res*. 2019; 39(5):2633-2640. <https://doi.org/10.21873/anticancer.13387> PMID:31092462
9. O'Reilly A, et al. An immunotherapy survivor population: health-related quality of life and toxicity in patients with metastatic melanoma treated with immune checkpoint inhibitors. *Support Care Cancer*. 2019. <https://doi.org/10.1007/s00520-019-04818-w>
10. Dieng M, et al. Psychoeducational Intervention to Reduce Fear of Cancer Recurrence in People at High Risk of Developing Another Primary Melanoma: Results of a Randomized Controlled Trial. *J Clin Oncol*. 2016; 34(36):4405-4414. <https://doi.org/10.1200/JCO.2016.68.2278> PMID:27998215
11. Fioranelli M, Rocchia MG, Pastore C, Aracena CJ, Lotti T. Completion dissection or observation for sentinel-node metastasis in melanoma. *Dermatol Ther*. 2017; 30(6). <https://doi.org/10.1111/dth.12544> PMID:28836714
12. Vaccaro M, Lentini M, Lotti J, Fioranelli M, Rocchia MG, Lotti T, Guarneri C. Hard to face: cutaneous malignant melanoma. *J Biol Regul Homeost Agents*. 2017; 31(2):53-55.
13. Chokoeva AA, Tchernev G, Wollina U, Lotti T. Cutaneous melanoma: how to improve the quality of diagnosis and treatment - a regional experience. *Dermatol Ther*. 2015; 28(6):344-5. <https://doi.org/10.1111/dth.12278> PMID:26279288
14. Vojvodic A, Dedic G, Djukic-Dejanovic S. Defense mechanisms and quality of life in military personnel with burnout syndrome. *VSP*. 2019. 76(3):298-306. <https://doi.org/10.2298/VSP170304114V>
15. Smith K. Mental health: a world of depression. *Nature*. 2014; 515(7526):181. <https://doi.org/10.1038/515180a> PMID:25391942
16. Tas F, Karabulut S, Guveli H, Kurul S, Erturk K, Guveli M, Kinik H. Assessment of Anxiety and Depression Status in Turkish Cutaneous Melanoma Patients. *Asian Pac J Cancer Prev*. 2017; 18(2):369-373.
17. Brown SL, Hope-Stone L, Heimann H, Damato B, Salmon P. Predictors of anxiety and depression 2 years following treatment in uveal melanoma survivors. *Psychooncology*. 2018; 27(7):1727-1734. <https://doi.org/10.1002/pon.4715> PMID:29601654
18. Miniati M, et al. Quality of Life, Depression, and Anxiety in Patients with Uveal Melanoma: A Review. *J Oncol*. 2018:5253109. <https://doi.org/10.1155/2018/5253109> PMID:29755525 PMID:PMC5883983

# Dermatoporosis – The Chronic Cutaneous Fragility Syndrome

Uwe Wollina<sup>1\*</sup>, Torello Lotti<sup>2</sup>, Aleksandra Vojvotic<sup>3</sup>, Andreas Nowak<sup>4</sup>

<sup>1</sup>*Department of Dermatology and Allergology, Städtisches Klinikum Dresden, Academic Teaching Hospital, Dresden, Germany;* <sup>2</sup>*Department of Dermatology, University of Rome “G. Marconi”, Rome, Italy;* <sup>3</sup>*Military Medical Academy of Belgrade, Belgrade, Serbia;* <sup>4</sup>*Department of Anesthesiology and Intensive Care Medicine, Emergency Medicine and Pain Management, Städtisches Klinikum Dresden, Dresden, Germany*

## Abstract

**Citation:** Wollina U, Lotti T, Vojvotic A, Nowak A. Dermatoporosis – The Chronic Cutaneous Fragility Syndrome. Open Access Maced J Med Sci. 2019 Sep 30; 7(18):3046-3049.  
<https://doi.org/10.3889/oamjms.2019.766>

**Keywords:** Skin ageing; Skin fragility; Wound healing; Bruises; Dermatoporosis; ICU

**\*Correspondence:** Uwe Wollina, Department of Dermatology and Allergology, Städtisches Klinikum Dresden, Academic Teaching Hospital, Dresden, Germany. E-mail: uwollina@gmail.com

**Received:** 18-Apr-2019; **Revised:** 04-Jul-2019;  
**Accepted:** 05-Jul-2019; **Online first:** 30-Aug-2019

**Copyright:** © 2019 Uwe Wollina, Torello Lotti, Aleksandra Vojvotic, Andreas Nowak. This is an open-access article distributed under the terms of the Creative Commons Attribution-NonCommercial 4.0 International License (CC BY-NC 4.0)

**Funding:** This research did not receive any financial support

**Competing Interests:** The authors have declared that no competing interests exist

Dermatoporosis is an important clinical condition leading to chronic skin fragility. It can be separated into primary and secondary subtypes, with the latter induced by medical drugs and environmental factors. Dermatoporosis can be classified into 4 major stages with increasing morbidity and mortality with the advanced stages. Its aetiology has been related to the epidermal hyalosome. Dermatoporosis is a cause of mortality in the intensive care unit and should be known not only by a dermatologist but another medical speciality as well. Prevention is of major importance. Therapeutic options are limited but available.

## Introduction

Cutaneous ageing has been divided into intrinsic and extrinsic ageing based upon the origin of changes leading to the ageing process. Cutaneous ageing is characterised by pigmentary, vascular, connective tissue and adipose tissue aspects that are contributing to the complex process. The ageing process is genetically determined but can be largely be influenced by environmental factors such as ultraviolet radiation, air pollution and smoking [1].

## Dermatoporosis

Dermatoporosis is the term coined by Saurat that covers all the aspects of the chronic cutaneous fragility syndrome [2]. Dermatoporosis describes a loss of function that eventually results in a breakdown

of the protective mechanisms of human skin. We differentiate primary forms due to increased age and extensive exposure to sunlight from secondary forms due to certain medications (see below).

The prevalence of dermatoporosis in 202 elderly French hospital in-patients aged between 60 to 80 years has been calculated as high as 32% [3]. A prospective trial of the department of dermatology of Helsinki University Central Hospital analysed 176 consecutive outpatients aged  $\geq 60$  years. Dermatoporosis was evident in 30.7% of patients, mainly on the upper limbs (94%). The authors performed multivariate analysis for possible risk factors. Dermatoporosis was significantly associated with ultrapotent topical corticosteroids (odds ratio (OR) 5.34), oral corticosteroids (OR 3.22), concomitant corticosteroid therapy, anticoagulant and chronic renal failure (OR 4.02) while age had only a marginal impact (OR 1.05). Patients with bullous pemphigoid were those with the highest prevalence of dermatoporosis in their cohort (64%) [4].

The prevalence is slightly higher in another

French study performed in a representative sample of the population ( $n = 533$ ): Here, the estimated overall prevalence of dermatoporosis was 37.5% in subjects aged older than 65 years with a predominance of women [5].

Dermatoporosis has been staged into 4 stages (Table 1).

**Table 1: Staging of dermatoporosis (according to [5])**

Stage I:	Skin atrophy, senile purpura and pseudo-cicatrices
Stage IIa:	Localised and small superficial lacerations (< 3 cm) due to skin fragility
Stage IIb:	Larger lacerations (> 3 cm)
Stage IIIa:	Superficial hematomas
Stage IIIb:	Deep dissecting hematomas without skin necrosis
Stage IV:	Large areas of skin necrosis with potentially lethal complications

## Aetiology

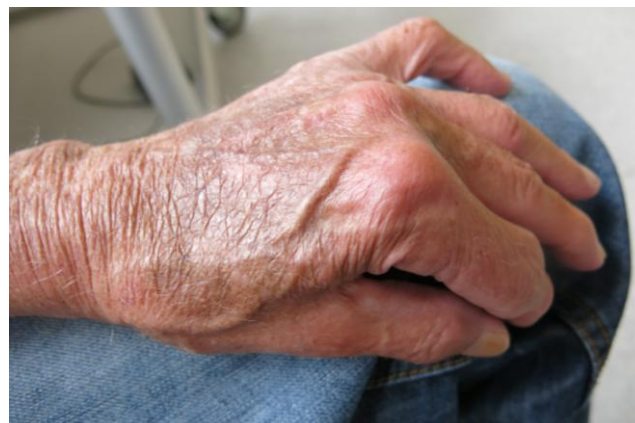In the case of corticosteroid-induced skin atrophy, the hyalurosomes of filopodia of epidermal keratinocytes becomes weakened [6]. This organelle is composed of hyaluronic acid receptor CD44, heparin-binding epidermal growth factor (HB-EGF), HB-EGF receptor erbB1 and hyaluronic acid synthase 3. The hyalurosomes are involved in different functions such as secretion of hyaluronic acid and epidermal growth factor-receptors signalling. It is anchored on F-actin fibres. Investigations in a mouse model suggested that the hyalurosomes are the target of corticosteroids and involved in corticosteroid-induced epidermal atrophy and dermatoporosis [7].

As a consequence of these molecular mechanisms, dermatoporosis skin demonstrated peculiarities in the viscoelastic properties of the affected skin. In the steep suction mode using the 4 mm aperture probe, the comparison with normal skin showed that residual deformation (RD) was significantly increased ( $P < 0.05$ ) in dermatoporosis. In the progressive suction mode using the same aperture probe, the comparison with normal skin revealed a significant increased RD in dermatoporosis ( $P < 0.05$ ). A combination of the 2 mm aperture probe with the outer guard ring yielded significant ( $P < 0.05$ ) hysteresis increase in dermatoporosis compared to normal skin [8].

## Bateman purpura

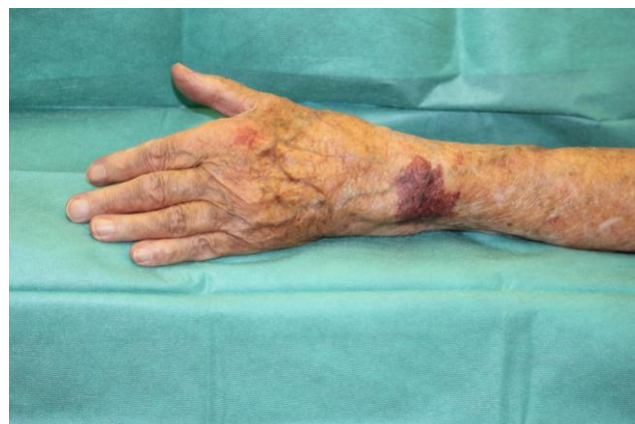Bateman purpura is a classical sign of photo-ageing, characterised by hemorrhagic areas with purpuric eruptions like petechial or confluent ecchymoses, by stellar scars, and a fragile skin due to thinness of the dermis [9].

These features are mainly localised and the back of the hands and the forearms (Figures 1 and 2).



*Figure 1: Dermatoporosis stage I with pronounced skin atrophy and pigmentary changes*

It has been demonstrated, that in the affected parts of the skin, there is a depletion of the photoprotective vitamin C due to chronic ultraviolet light (UV)-exposure [10].



*Figure 2: Dermatoporosis with advanced skin atrophy and Bateman purpura in a patient with bullous pemphigoid*

## Complications of dermatoporosis

### **Laceration and delayed wound healing (Fig. 3)**

From stage IIa onwards, laceration (skin tears) is a common feature of dermatoporosis. This symptom is caused by blunt trauma. Underlying mechanisms are age-related skin changes, but also dehydration, malnutrition, sensory changes, mobility impairment, pharmacological therapies and mechanical factors related to skincare practices [11]. Due to the delayed wound healing, it has a risk of soft tissue infections [12].

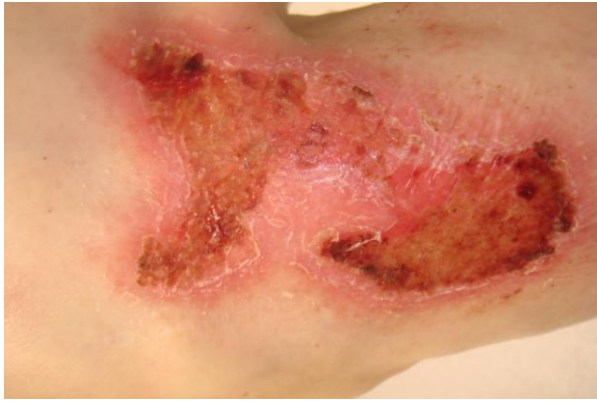

Figure 3: Delayed wound healing after laceration in a 76-year-old male patient with Parkinson's disease

## Deep dissecting hematoma

Deep dissecting hematoma (syn. chronic expanding hematoma) is an emergency [13]. A Swiss study reported a close connection to dermatoporosis. The legs were affected in all patients, most frequently in older women (mean age 81.7 years). Risk factors were long-term treatment with systemic corticosteroids and anticoagulation. Deep dissecting hematoma presents with pain and swelling, erythema and oedema without fever (Figure 4). Skin necrosis was a late symptom. Magnetic resonance imaging and histopathological analysis confirmed the deep anatomical location of the hematoma. Treatment consisted of deep incision and/ or debridement followed by direct closure, skin grafting, or wound healing by second intention [14].

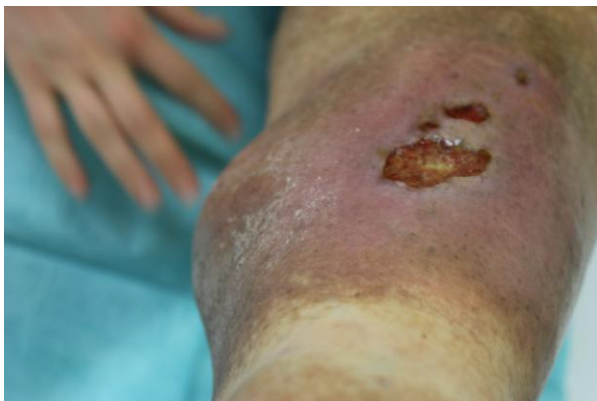

Figure 4: Chronic deep dissecting hematoma of the lower leg leading to secondary ulcerations of the skin

## Dermatoporosis in the Intensive Care Unit (ICU)

Skin failure is defined as loss of normal

temperature control combined with the inability to maintain the core body temperature, percutaneous loss of fluid, electrolytes and protein, and failure of the mechanical barrier to prevent penetration of germs [15]. In an analysis of 552 adult patients admitted to the ICU, a logistic model was developed to differentiate pressure sores from acute skin failure. The identified risk factors for acute skin failure were peripheral arterial disease (odds ratio [OR] 3.8), mechanical ventilation greater than 72 hours (OR 3.0), respiratory failure (OR 3.2), liver failure (OR 2.9), and severe sepsis and/or septic shock (OR 1.9) were independent predictors (Figure 5) [16].

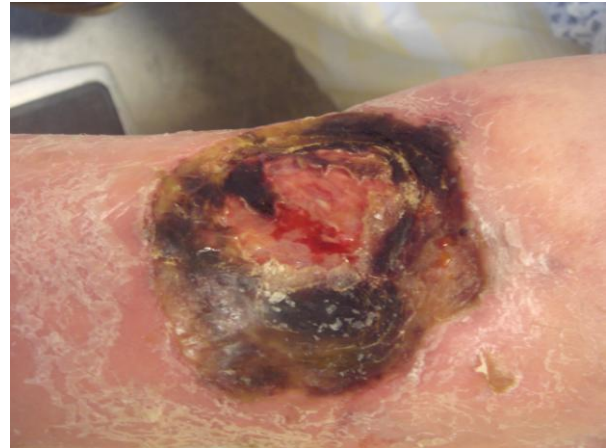

Figure 5: Ulceration and delayed wound healing after removal of a saphenous vein graft for coronary artery bypass graft surgery

Dermatoporosis is a condition that can lead to acute skin failure in the ICU. Dermatoporosis has a high prevalence in autoimmune bullous disorders such as pemphigoid, and bullous disorders are among the dermatological diagnoses that can lead to an ICU admission (Figure 4 and 5) [4], [17], [18].

## Prevention and treatment of dermatoporosis

Prevention of dermatoporosis is possible by limiting the exposure to known inducers of this skin condition such as extrinsic factors like ultraviolet radiation, pollution or smoking, and medical drugs like topical and systemic corticosteroids [19].

Treatment of dermatoporosis is principally possible, although best results are obtained in stage I. In a mouse model, intermediate size hyaluronic acid fragments (HAFi) inhibited the downregulation of filopodia and skin atrophy induced by clobetasol propionate. Topical treatment of atrophic forearm skin of dermatoporosis patients with HAFi 1% for 1 month resulted in a significant clinical improvement. Also, the expression of hyalurosomes molecules was induced. Topical retinaldehyde 0.05% and HAFi 1%



demonstrated synergy in hyaluronic acid production and heparin-binding epidermal growth factor in mouse skin and in dermatoporosis patients [6], [7], [20].

Other topical modalities to increase skin thickness include alpha-hydroxy acids twice daily for at least three months [21] or topical dehydroepiandrosterone 1% cream (in women) twice daily for four months [22].

In a single-centre, intra-individual randomised, double-blind and placebo-controlled clinical trial, topical vitamin C was used to improve Bateman purpura. The patients received either an active cream containing 5% of vitamin C (L-ascorbic acid) vs a neutral cream twice daily.

In this trial, topical vitamin C led to a clinically apparent improvement of purpura and measurable improvement of skin elasticity (Cutometer SM 575®; Courage and Khazaka, Köln, Germany) and thickness (Harpenden skin-fold calliper) [23].

## References

- Zouboulis CC, Ganceviciene R, Liakou AI, Theodoridis A, Elewa R, Makrantonaki E. Aesthetic aspects of skin aging, prevention, and local treatment. *Clin Dermatol*. 2019; 37(4):365-372. <https://doi.org/10.1016/j.clindermatol.2019.04.002> PMID:31345325
- Kaya G, Saurat JH. Dermatoporosis: a chronic cutaneous insufficiency/fragility syndrome. Clinicopathological features, mechanisms, prevention and potential treatments. *Dermatology*. 2007; 215(4):284-94. <https://doi.org/10.1159/000107621> PMID:17911985
- Mengeaud V, Dautzac-Vieu C, Josse G, Vellas B, Schmitt AM. Prevalence of dermatoporosis in elderly French hospital in-patients: a cross-sectional study. *Br J Dermatol*. 2012; 166(2):442-3. <https://doi.org/10.1111/j.1365-2133.2011.10534.x> PMID:21787367
- Kluger N, Impivaara S. Prevalence of and risk factors for dermatoporosis: a prospective observational study of dermatology outpatients in a Finnish tertiary care hospital. *J Eur Acad Dermatol Venereol*. 2019; 33(2):447-450. <https://doi.org/10.1111/jdv.15240> PMID:30198583
- Saurat JH, Mengeaud V, Georgescu V, Coutanceau C, Ezzedine K, Taieb C. A simple self-diagnosis tool to assess the prevalence of dermatoporosis in France. *J Eur Acad Dermatol Venereol*. 2017; 31(8):1380-1386. <https://doi.org/10.1111/jdv.14240> PMID:28342195
- Barnes L, Tran C, Sorg O, Hotz R, Grand D, Carraux P, Didierjean L, Stamenkovic I, Saurat JH, Kaya G. Synergistic effect of hyaluronate fragments in retinaldehyde-induced skin hyperplasia which is a Cd44-dependent phenomenon. *PLoS One*. 2010; 5(12):e14372. <https://doi.org/10.1371/journal.pone.0014372> PMID:21179550 PMCID:PMC3002934
- Barnes L, Ino F, Jaunin F, Saurat JH, Kaya G. Inhibition of putative hyalurosomes in keratinocytes as a mechanism for corticosteroid-induced epidermal atrophy. *J Invest Dermatol*. 2013; 133(4):1017-26. <https://doi.org/10.1038/jid.2012.439> PMID:23223147
- Piérard GE, Piérard S, Delvenne P, Piérard-Franchimont C. In vivo evaluation of the skin tensile strength by the suction method: pilot study coping with hysteresis and creep extension. *ISRN Dermatol*. 2013; 2013:841217. <https://doi.org/10.1155/2013/841217> PMID:23986871 PMCID:PMC3748421
- Bateman T. *Abbildungen von Hautkrankheiten, wodurch die charakteristischen Erscheinungen der Gattungen und Arten nach der Willan'schen Classification dargestellt werden*. Weimar: Verlag des Großherzoglichen Sächsischen Privilegirten Landes-Industrie-Comptoirs, 1830.
- Thiele JJ, Traber MG, Packer L. Depletion of human stratum corneum vitamin E: an early and sensitive in vivo marker of UV induced photo-oxidation. *J Invest Dermatol*. 1998; 110(5):756-61. <https://doi.org/10.1046/j.1523-1747.1998.00169.x> PMID:9579541
- Serra R, Ielapi N, Barbetta A, de Franciscis S. Skin tears and risk factors assessment: a systematic review on evidence-based medicine. *Int Wound J*. 2018; 15(1):38-42. <https://doi.org/10.1111/iwj.12815> PMID:29045078
- LeBlanc K, Baranoski S; Skin Tear Consensus Panel Members. Skin tears: state of the science: consensus statements for the prevention, prediction, assessment, and treatment of skin tears. *Adv Skin Wound Care*. 2011; 24(9):2-15. <https://doi.org/10.1097/01.ASW.0000405316.99011.95> PMID:21876389
- Wollina U, Heinig B, Langner D. Chronic Expanding Organized Hematoma of the Lower Leg: A Rare Cause for Nonhealing Leg Ulcers. *Int J Low Extrem Wounds*. 2015; 14(3):295-8. <https://doi.org/10.1177/1534734615571129> PMID:25691320
- Kaya G, Jacobs F, Prins C, Viero D, Kaya A, Saurat JH. Deep dissecting hematoma: an emerging severe complication of dermatoporosis. *Arch Dermatol*. 2008; 144(10):1303-8. <https://doi.org/10.1001/archderm.144.10.1303> PMID:18936393
- Irvine C. 'Skin failure'--a real entity: discussion paper. *J R Soc Med*. 1991; 84(7):412-3. <https://doi.org/10.1177/014107689108400711> PMID:1865448 PMCID:PMC1293332
- Delmore B, Cox J, Rolnitzky L, Chu A, Stolfi A. Differentiating a Pressure Ulcer from Acute Skin Failure in the Adult Critical Care Patient. *Adv Skin Wound Care*. 2015; 28(11):514-24; quiz 525-6. <https://doi.org/10.1097/01.ASW.0000471876.11836.dc> PMID:26479695
- Wollina U, Nowak A. *Dermatology in the Intensive Care Unit*. *Our Dermatol Online*. 2012; 3(4):298-303. <https://doi.org/10.7241/ourd.20124.65>
- Inamadar AC, Palit A. Acute skin failure: concept, causes, consequences and care. *Indian J Dermatol Venereol Leprol*. 2005; 71(6):379-85. <https://doi.org/10.4103/0378-6323.18007>
- Dyer JM, Miller RA. Chronic Skin Fragility of Aging: Current Concepts in the Pathogenesis, Recognition, and Management of Dermatoporosis. *J Clin Aesthet Dermatol*. 2018; 11(1):13-18.
- Nikolic DS, Ziori C, Kostaki M, Fontao L, Saurat JH, Kaya G. Hyalurosomes gene regulation and dose-dependent restoration of skin atrophy by retinaldehyde and defined-size hyaluronate fragments in dermatoporosis. *Dermatology*. 2014; 229(2):110-5. <https://doi.org/10.1159/000362594> PMID:25138066
- Van Scott EJ, Ditre CM, Yu RJ. Alpha-hydroxyacids in the treatment of signs of photoaging. *Clin Dermatol*. 1996; 14(2):217-26. [https://doi.org/10.1016/0738-081X\(95\)00157-B](https://doi.org/10.1016/0738-081X(95)00157-B)
- Nouveau S, Bastien P, Baldo F, de Lacharriere O. Effects of topical DHEA on aging skin: a pilot study. *Maturitas*. 2008; 59(2):174-81. <https://doi.org/10.1016/j.maturitas.2007.12.004> PMID:18242894
- Humbert P, Fanian F, Lihoreau T, Jeudy A, Pierard GE. Bateman purpura (dermatoporosis): a localized scurvy treated by topical vitamin C - double-blind randomized placebo-controlled clinical trial. *J Eur Acad Dermatol Venereol*. 2018; 32(2):323-328. <https://doi.org/10.1111/jdv.14525> PMID:28833652

# Melanoma and Mastocytosis

Aleksandra Vojvodic<sup>1</sup>, Tatjana Vlaskovic-Jovicevic<sup>2</sup>, Petar Vojvodic<sup>2</sup>, Jovana Vojvodic<sup>2</sup>, Mohamad Goldust<sup>3</sup>, Zorica Peric-Hajzler<sup>4</sup>, Dusica Matovic<sup>4</sup>, Goran Sijan<sup>5</sup>, Nenad Stepic<sup>5</sup>, Uwe Wollina<sup>6</sup>, Massimo Fioranelli<sup>7</sup>, Michael Tirant<sup>8</sup>, Van Thuong Nguyen<sup>9</sup>, Torello Lotti<sup>10</sup>

<sup>1</sup>Department of Dermatology and Venereology, Military Medical Academy, Belgrade, Serbia; <sup>2</sup>Clinic for Mental Disorders "Dr Laza Lazarevic" Belgrade, Serbia; <sup>3</sup>Guglielmo Marconi University, Rome, Italy; <sup>4</sup>Military Medical Academy, Belgrade, Serbia; <sup>5</sup>Clinic for Plastic Surgery and Burns, Military Medical Academy, Belgrade, Serbia; <sup>6</sup>Department of Dermatology and Allergology, Städtisches Klinikum Dresden, Dresden, Germany; <sup>7</sup>Department of Nuclear Physics, Sub-nuclear and Radiation, G. Marconi University, Rome, Italy; <sup>8</sup>University G. Marconi, Rome, Italy; <sup>9</sup>Vietnam National Hospital of Dermatology and Venereology, Hanoi, Vietnam; <sup>10</sup>Department of Dermatology, Guglielmo Marconi University, Rome, Italy

## Abstract

**Citation:** Vojvodic A, Vlaskovic Jovicevic T, Vojvodic P, Vojvodic J, Goldust M, Peñic Hajzler Z, Matovic D, Sijan G, Stepic N, Wollina U, Fioranelli M, Tirant M, Thuong Nguyen V, Lotti T. Melanoma and Mastocytosis. *Open Access Maced J Med Sci.* 2019 Sep 30; 7(18):3050-3052. <https://doi.org/10.3889/oamjms.2019.772>

**Keywords:** Melanoma; Mastocytosis; Growth factor; Mastocytoma

**\*Correspondence:** Massimo Fioranelli, Department of Nuclear Physics, Sub-nuclear and Radiation, G. Marconi University, Rome, Italy. E-mail: [massimo.fioranelli@gmail.com](mailto:massimo.fioranelli@gmail.com)

**Received:** 13-Jun-2019; **Revised:** 04-Jul-2019; **Accepted:** 05-Jul-2019; **Online first:** 30-Aug-2019

**Copyright:** © 2019 Aleksandra Vojvodic, Tatjana Vlaskovic Jovicevic, Petar Vojvodic, Jovana Vojvodic, Mohamad Goldust, Zorica Peric Hajzler, Dusica Matovic, Goran Sijan, Nenad Stepic, Uwe Wollina, Massimo Fioranelli, Michael Tirant, Van Thuong Nguyen, Torello Lotti. This is an open-access article distributed under the terms of the Creative Commons Attribution-NonCommercial 4.0 International License (CC BY-NC 4.0)

**Funding:** This research did not receive any financial support

**Competing Interests:** The authors have declared that no competing interests exist

There are numerous cases reports and studies confirming the enhanced incidence of melanoma among patients with mastocytosis, especially with systemic mastocytosis. These two diseases are arising from two different types of cells; melanoma arises from neural crest cells and mastocytosis from hematopoietic stem cells. But there are a lot of similarities between the two diseases. The most important and significant is the dependence of the growth factor receptor c-KIT and c-KIT ligand (stem cell factor) for their growth and development. Also, expression of the STAT3 (signal transducer and activator of transcription 3) and transcription factors MITF (microphthalmia-associated transcription factor) make the connection between melanoma and mastocytosis.

## Introduction

There are numerous cases reports and studies confirming the enhanced incidence of melanoma among patients with mastocytosis, especially with systemic mastocytosis. These two diseases are arising from two different types of cells; melanoma arises from neural crest cells and mastocytosis from hematopoietic stem cells. But there are a lot of similarities between the two diseases. The most important and significant is the dependence of the growth factor receptor c-KIT and c-KIT ligand (stem cell factor) for their growth and development. Also, expression of the STAT3 (signal transducer and activator of transcription 3) and transcription factors MITF (microphthalmia-associated transcription factor)

make the connection between melanoma and mastocytosis.

## Discussion

Mastocytosis is a group of rare disorders characterised by the proliferation and accumulation of mast cells in the skin and/or other organs, and occur in children and adults. Most of the patients, about 80%, are with cutaneous mastocytosis, and mostly the course is indolent (90%). Classification of cutaneous mastocytosis is into urticaria pigmentosa, the most common cutaneous variant, solitary mastocytoma and

diffuse cutaneous mastocytosis.

Melanoma is one of the most malignant cancers, with the incidence increasing all over the world, and it is one of the most frequent cancers in fair-skinned populations. There are biological explanations for an increased incidence of melanoma among patients with mastocytosis. Mast cells would interact with melanocytes through the release of cytokines. The high rate of mutations in melanoma makes it difficult to distinguish between driver mutations and bystander mutations. The most frequent driver mutations in melanoma are BRAF, NRAS, KIT, GNAQ, GNA11, NF1 and telomerase). BRAF and NRAS mutations are mostly found in cutaneous melanomas, and KIT mutations are detected in acral and mucosal melanomas. In systemic mastocytosis a KIT D816V mutation is present in almost all cases, in adult-, but not in childhood-onset mastocytosis. This mutation of KIT<sup>D816V</sup> has been found in melanoma, but its involvement is yet not well understood. In some studies, it is shown that KIT<sup>D816V</sup> induces tyrosine phosphorylation of microphthalmia-associated transcription factor (MITF). It forms a triple protein complex formation of KIT, MITF, and SRC family kinases. Activated microphthalmia-associated transcription factor activates genes involved in melanoma proliferation, cell-cycle progression, survival, and also an invasion. Both mast cells and melanocytes need for growth binding of the stem cell factor (SCF) to the KIT receptor. The SCF receptor is expressed in primitive hematopoietic cells and mast cells mostly, but it is also expressed in certain regions of the brain, germs cells, melanocytes and basal cells in the skin, interstitial cells of Cajal. The signalling pathways activated downstream from Kit receptor include MAP kinase pathways, Src kinases, PI3-kinase and phospholipase C and D. Mast cells are producing large subsets of mediators (e.g., EGF, NGF, PDGF, SCF, angiopoietin, heparin, IL-8, VEGF). They are involved in IgE-associated allergic reactions, mostly, but numerous studies have shown the connection between mast cells accumulation and tumour growth – melanoma, Merkel cell carcinoma adenocarcinoma, squamous cell carcinomas, prostate carcinoma, etc. In mastocytosis, RAF is the most frequently mutated kinases, where BRAF V600E mutation occurs in most hairy cell leukaemias (HCL) and half of the malignant melanomas. Thus, although BRAF is commonly mutated, it appears not to be present in SM. The risk-association to other hematologic neoplasms and the risk of cardiovascular disease in mastocytosis is well-established, but also for increased risk of solid cancer as well as thromboembolic morbidity. Mast cells are influencing tumour development and remodelling of tissue, tumour-induced angiogenesis, and shaping of adaptive immune responses to tumours. Mostly presence of mast cells in tumours is associated with poor prognosis, but for prostate cancer and colorectal cancer is a favorable prognostic factor. The use of

kinase inhibitors could improve cancer treatment, but the main problem with this treatment is the second mutation in c-Kit, which changes the binding region of kinase inhibitor, and the result is drug resistance [1], [2], [3], [4], [5], [6].

Melanoma inhibitory activity (MIA) is expressed on mast cells of cutaneous mastocytosis, neurofibroma cells in patients with neurofibromatosis type 1 (NF1) and it is used as a serum marker for malignant melanoma. The function of MIA is in inhibition of apoptosis in melanocytic cells, but the whole mechanisms of expression on mast cells are unknown. Inhibition of the transcription factor, SOX10 reduced MIA expression and promoter activity. This transcriptional factor is important for melanoma development and survival [7], [8].

After exposure to histamine, melanocytes undergo morphological variations and increased activity of tyrosinase. Also, one of the most potent mast cell growth factors- CD-117 binding mast cells growth factor (MFG) stimulates the proliferation of both mast cells and melanocytes.

One of the therapies mostly used for the cutaneous mastocytosis is phototherapy, 311 nm UVB and PUVA and it is well known that UV exposure favour the onset of skin cancers.

The role of estrogens on the development of melanoma and on the exacerbation of the mastocytosis is extremely unknown, but it has been shown in vitro that binding estradiol to estrogen receptor- $\alpha$  on the membrane of mast cells supports the synthesis and release of mast cell mediators [9].

In conclusion, there is an enhanced incidence of melanoma among patients with mastocytosis, especially with systemic mastocytosis, and connection between these two diseases is still not clear. Understanding the influence of mast cells on melanocytes could bring great benefit in threatening the melanoma. New studies are needed.

## References

1. Capo A, Goteri G, Mozzicafreddo G, Serresi S, Giacchetti A. Melanoma and mastocytosis: is really only a coincidence? *Clin Exp Dermatol*. 2019; 44(1):76-7. <https://doi.org/10.1111/ced.13717> PMID:30178486
2. Molderings GJ, Zienkiewicz T, Homann J, Menzen M, Afrin LB. Risk of solid cancer in patients with mast cell activation syndrome: Results from Germany and USA. *F1000Res*. 2017; 6:1889. <https://doi.org/10.12688/f1000research.12730.1> PMID:29225779 PMCID:PMC5710302
3. Broesby-Olsen S et al. Risk of solid cancer, cardiovascular disease, anaphylaxis, osteoporosis and fractures in patients with systemic mastocytosis: A nationwide population-based study. *Am J Hematol*. 2016; 91(11):1069-75. <https://doi.org/10.1002/ajh.24490> PMID:27428296
4. Phung B, et al. KITD816V Induces SRC-Mediated Tyrosine

Phosphorylation of MITF and Altered Transcription Program in Melanoma. *Mol Cancer Res.* 2017; 15(9):1265-1274.

<https://doi.org/10.1158/1541-7786.MCR-17-0149> PMID:28584020

5. Hägglund H, Sander B, Ahmadi A, Gülen T, Nilsson G. Analysis of V600E BRAF and D816V KIT mutations in systemic mastocytosis. *Med Oncol.* 2014; 31(8):123.

<https://doi.org/10.1007/s12032-014-0123-4> PMID:25034364

6. Abbaspour Babaei M, Kamalidehghan B, Saleem M, Huri HZ, Ahmadipour F Receptor tyrosine kinase (c-Kit) inhibitors: a potential therapeutic target in cancer cells. *Drug Des Devel Ther.* 2016; 10:2443-59.

<https://doi.org/10.2147/DDDT.S89114>

PMid:27536065 PMCid:PMC4975146

7. Ehara Y, Yoshida Y, Tahira M, Yamamoto O. The expression of melanoma inhibitory activity on mast cells in child patients with cutaneous mastocytosis. *Yonago Acta Med.* 2014; 57(3):99-101.

8. Heldin CH, Lennartsson J Structural and functional properties of platelet-derived growth factor and stem cell factor receptors. *Cold Spring Harb Perspect Biol.* 2013; 5(8):a009100.

<https://doi.org/10.1101/cshperspect.a009100> PMID:23906712

PMCid:PMC3721287

9. Donati P, Paolino G, Donati M, Panetta C. Cutaneous mastocytosis combined with eruptive melanocytic nevi and melanoma. Coincidence or a linkage in the pathogenesis? *J Dermatol Case Rep.* 2014; 8(3):70-4.

<https://doi.org/10.3315/jdcr.2014.1179> PMID:25324908

PMCid:PMC4195503

## Clinical Applications of System Regulation Medicine

Massimo Fioranelli<sup>1\*</sup>, Alireza Sepehri<sup>1</sup>, Maria Grazia Roccia<sup>1</sup>, Cota Linda<sup>1</sup>, Chiara Rossi<sup>1</sup>, Amos Dawodo<sup>1</sup>, Petar Vojvodic<sup>2</sup>, Jacopo Lotti<sup>1</sup>, Victoria Barygina<sup>3</sup>, Aleksandra Vojvodic<sup>4</sup>, Uwe Wollina<sup>5</sup>, Michael Tirant<sup>6</sup>, Thuong Nguyen Van<sup>7</sup>, Torello Lotti<sup>8</sup>

<sup>1</sup>Department of Nuclear Physics, Sub-nuclear and Radiation, G. Marconi University, Rome, Italy; <sup>2</sup>Clinic for Psychiatric Disorders "Dr. Laza Lazarevic", Belgrade, Serbia; <sup>3</sup>Department of Biomedical Experimental and Clinical Sciences, University of Florence, Florence, Italy; <sup>4</sup>Department of Dermatology and Venereology, Military Medical Academy, Belgrade, Serbia; <sup>5</sup>Department of Dermatology and Allergology, Städtisches Klinikum Dresden, Dresden, Germany; <sup>6</sup>G. Marconi University, Rome, Italy; <sup>7</sup>Vietnam National Hospital of Dermatology and Venereology, Hanoi, Vietnam; <sup>8</sup>Department of Dermatology, University of G. Marconi, Rome, Italy

### Abstract

**Citation:** Fioranelli M, Sepehri A, Roccia MG, Linda C, Rossi C, Dawodo A, Vojvodic P, Lotti J, Barygina V, Vojvodic A, Wollina U, Tirant M, Nguyen Van T, Lotti T. Clinical Applications of System Regulation Medicine. Open Access Maced J Med Sci. 2019 Sep 30; 7(18):3053-3060.  
<https://doi.org/10.3889/oamjms.2019.775>

**Keywords:** Bioregulatory Systems Medicine; Preclinical; Networks

**\*Correspondence:** Massimo Fioranelli, Department of Nuclear Physics, Sub-nuclear and Radiation, G. Marconi University, Rome, Italy. E-mail: [massimo.fioranelli@gmail.com](mailto:massimo.fioranelli@gmail.com)

**Received:** 16-Jul-2019; **Revised:** 04-Aug-2019; **Accepted:** 05-Aug-2019; **Online first:** 14-Sep-2019

**Copyright:** © 2019 Massimo Fioranelli, Alireza Sepehri, Maria Grazia Roccia, Cota Linda, Chiara Rossi, Amos Dawodo, Petar Vojvodic, Jacopo Lotti, Victoria Barygina, Aleksandra Vojvodic, Uwe Wollina, Michael Tirant, Thuong Nguyen Van, Torello Lotti. This is an open-access article distributed under the terms of the Creative Commons Attribution-NonCommercial 4.0 International License (CC BY-NC 4.0)

**Funding:** This research did not receive any financial support

**Competing Interests:** The authors have declared that no competing interests exist

Increasing incidence and poor outcome of chronic non-communicable diseases in western population would require a paradigm shift in the treatments. Guidelines-based medical approaches continue to be the standard rule in clinical practice, although only less than 15% of them are based on high-quality research. For each person who benefits from the 10 best-selling drugs in the USA, a number between 4 and 25 has no one beneficial effect.

The reductionist linear medicine method does not offer solutions in the non-manifest preclinical stage of the disease when it would still be possible to reverse the pathological progression and the axiom "a drug, a target, a symptom" are still inconclusive. Needs additional tools to address these challenges.

System Medicine considers the disease as a dysregulation of the biological networks that changes throughout the evolution of the pathological process and with the comorbidities development. The strength of the networks indicates their ability to withstand dysregulations during the perturbation phases, returning to the state of stability. The treatment of dysregulated networks before the symptomatological manifestation emerges offers the possibility of treating and preventing pathologies in the preclinical phase and potentially reversing the pathological process, stopping it or preventing comorbidities. Furthermore, treating shared networks instead of individual phenotypic symptoms can reduce drug use, offering a solution to the problem of ineffective drug use.

## Introduction

The reductionist linear medicine has undoubtedly contributed to the prolongation of the life expectancy of the western population, but, as far as chronic non-communicable diseases are concerned, it presents some problems that require a paradigm shift in the treatments currently in use.

The progressive ageing of the population and the increase in environmental pollution are conditions capable to profoundly influencing the health status of the population.

The management of non-communicable diseases, the ageing of the population and the progressive environmental pollution, pose new and

complex problems, difficult to be solved by the current health organisation, also due to the economic sustainability of the care [1], [2], [3].

The incidence of complex non-communicable diseases, such as type II diabetes, cardiovascular diseases (growing exponentially), atopic dermatitis and cancer, increases with age, but the most worrying fact is that it is also increasing in the pediatric population [4], [5], [6], [7], [8].

Also, regarding transmissible pathologies, there are new challenges related to the increasing resistance of microbes to antibiotics and to the limited number of new drugs being developed [9], [10], [11].

Guidelines-based medical approaches continue to be the rule in clinical practice, although only less than 15% of them are based on high-quality

research. Although this type of (statistical) approach can be profitable in the general population, it becomes unsuccessful when compared to the genetic, epigenetic and environmental characteristics of the individual subject [4]. The result is excessive healthcare spending compared to poor results. The annual cost of ineffective treatments in the US would be \$ 350 billion, while the development of new linear drugs costs \$ 1 billion for each formulation, with an additional impact on the cost of health care [12].

In research on the 10 best-selling drugs in the USA, it was found that, for each person who benefits from one of these treatments, a number between 4 and 25 has none [13].

Another study showed that the use of prescription drugs has drastically increased among the elderly population during an observation period of 12 years and, in particular, the number of patients taking more than 5 drugs has increased from 12.8% at 39.0% from 1988 to 2010, identifying a population considered particularly fragile [14].

Usually, in chronic conditions, Western Medicine treats the symptomatic manifestations of the disease (e.g. hypertension or hypercholesterolemia) and often can identify patients at risk in advance. However, this method does not offer solutions in the non-manifest preclinical stage of the disease, when it would still be possible to reverse the pathological progression, correcting underlying causes [12], [13], [14], [15].

It, therefore, appears clear that the need for additional tools to address these challenges. For this reason, more and more frequently, System Medicine is proposed as a useful tool [16], [17], [18], [19], in particular in terms of different view and approach to the disease, unfortunately even more in theory than in practice, because the alternatives to the axiom "a drug, a target, a symptom" are still struggling to get ahead.

The Bioregulatory System Medicine (BrSM), the subsequent evolution of Systems Medicine, aims to bridge this gap through the use of low dose medicines with precise, targeted and synergistic bioregulatory capacities. These are medicines composed of different therapeutic nuclei (multi-component) with an effect on as many different targets (multi-target) and a favourable safety profile [20], [82]. Based on a correct evaluation of the patient's clinical history, recognition of its characteristics specific and at the stage of progression of the pathology, the BrSM directs the choices of therapeutic strategy, allowing a more complete and systematic approach to the patient.

## Systems Medicine

Biological systems have some aspects in common, including self-organisation, intrinsic stability, robustness and resilience [12], [15], [21].

Self-organisation is one of the fundamental characteristics of Systems Medicine and takes up the so-called autopoiesis of the school of Santiago de Francisco Varela and Humberto Maturana [21], [22].

The complexity of the human body is considered as a set of interconnected networks, composed of genome, molecules, cells, organs, going beyond, up to the environment surrounding the organism and to the networks created by individuals in societies [4], [12].

The disease is considered a dysregulation of the networks, linked to different perturbations or disturbances that act by jeopardising stability and functionality [23], [24], [25].

The networks go through phases of dysregulation long before the recognisable pathology divides, and before any structural symptoms or alterations appear.

Stability is another intrinsic characteristic of complex systems, and in living organisms, it is ensured by self-regulation to maintain homeostasis.

The networks are organised in functional modules to protect the system from global collapse, and robustness (i.e. the ability of systems to resist, without modification, to perturbations) allows the system to defend itself against elements of disturbance and destabilisation [15], [26].

Finally, resilience indicates the ability of the system to withstand disturbances by adapting to it to guarantee the function of the system itself.

These characteristics can be exploited in the clinical approach and the BrSM aims at this goal, placing as the main goal of the therapy the support to the organism self-regulation system to re-establish a normal state of homeostasis or, if this is not possible, a state of optimal compensation, reducing the use of drugs as much as possible [20].

In practice, numerous distinctive aspects differentiate the Systems Medicine from the linear reductionist approach [4], [16], [81].

The use of targeted drug therapies that target only one point of the network, as happens in reductionist medicine, has been questioned. If the interrelations of the target are not taken into account, in fact, one risks unintentionally causing the opposite effect. For example, the use of statins could increase atherosclerosis due to the depletion of coenzyme Q10 and vitamin K2, 25 or the use of non-steroidal anti-inflammatory drugs in acute inflammation has an anti-inflammatory effect, but also tends to block the

production of prostaglandins (PG) E<sub>2</sub>, necessary for the activation of lipid mediators responsible for resolving inflammation and triggering the repair and restoration processes of tissue physiology [28], [29], [30].

The recognition of the role of the dysregulation of biological networks in the evolution of pathologies not only offers opportunities for their management but also questions the current diagnostic procedure, based on a fixed number of biomarkers that are interpreted only after the onset of clinical symptoms [31], [32]. This different approach to the patient, called Network Medicine, has many advantages [12].

According to this more current reference model, in the diagnosis phase we tend to recognize dynamic patterns in network dysregulations rather than resort to isolated and immutable biomarkers over time and, in particular, in the approach to the progressive evolution of the pathology, such patterns contribute to the definition of an individualized vision for each patient [17], [33], [34].

In 2008 Fuite et al., showed him that, through the analysis of a genomic network in patients with chronic fatigue syndrome, it was possible to identify an alteration in the interrelation of the immune system, adrenocorticotrophic hormone, and thyroid [35].

More recently, recognition of specific patterns in patients with systemic sclerosis has allowed physicians to predict prognosis and contributed to the definition of therapy [36].

To examine and visualise these complex networks to define their patterns, the so-called "-omics" technologies are used: genomics, epigenomics, proteomics, metabolomics and microbiomics, up to the most recent exposomics [10], [19], [37]. It appears very promising, in this panorama, also the alterations of the parameters of bio-impedance metre that involve the analysis of the systems [38].

The reductionist approach tends largely to ignore environmental influences, but starting from the revolutionary article by Christopher Wild, who introduced the term *esposoma* in 2005, this concept has taken on a prominent role in the systems approach [10], [39], [40], [41].

The concept of *exposome* indicates the list of all the chemical substances to which a subject has been and including environmental, food or work-related, endogenous biochemical substances formed by normal metabolic processes, and by inflammation, oxidative stress, lipid peroxidation and infections, as well as other natural metabolic processes, such as alteration of the intestinal microbiome [41]. These exhibits affect all networks and in particular the epigenetic one.

The omics technologies are also ideally useful

for investigating the effects of multicomponent / multitarget drugs with bioregulation properties, as they would allow clarifying the effects effects [42] better.

In summary, System Medicine considers the disease as a dysregulation of the biological networks that changes throughout the evolution of the pathological process and with the development of comorbidities. The strength of the networks indicates their ability to withstand dysregulations during the perturbation phases, returning to the state of stability or guaranteeing the best possible stability through compensation mechanisms [5], [24], [43], [44].

The treatment of dysregulated networks before the symptomatological manifestation emerges offers the possibility of treating and preventing pathologies in the preclinical phase and potentially reversing the pathological process, stopping it or preventing comorbidities [15].

Furthermore, treating shared networks instead of individual phenotypic symptoms can reduce drug use, offering a solution to the problem of ineffective drug use [4].

## Systems Bioregulation Medicine

The conceptual pillar of BrSM is a therapeutic approach that aims to treat the networks dysregulations of underlying pathology by supporting self-regulation networks, to promote the restoration of physiological homeostatic conditions of networks or the achievement of a state of equilibrium [20].

The dysregulation of the networks is the initial phase of the pathological evolution, preceding the symptomatological manifestation; it follows an advantageous overall therapeutic intervention and directed to the dysregulation as a whole, instead of on the single symptomatological manifestations of each disease.

Complex non-communicable diseases often share dysregulations of the inflammatory and metabolic networks. During evolution, these same networks have evolved to address a wide variety of circumstances. At the same time, however, it must be considered that this characteristic of flexibility also makes them more vulnerable to dysregulation. The regulation of these networks is based on relatively primitive self-regulation processes and is often overwhelmed by incongruous lifestyles and by increasingly unfavourable conditions of environmental pollution to which modern man is exposed [45], [46].

The Nervous and Endocrine Systems maintain a systemic homeostatic state, while the local homeostatic circuits regulate the state and integrity of cell and tissue networks. However, when homeostatic mechanisms are not sufficient, the inflammatory

process is triggered in order to maintain or restore balance. Several authors define this process as homeostatic inflammation (or physiological inflammation [47], [48]).

The inflammatory response of the organism and its effects on it in the acute phase play a fundamental role in the model of BrSM. The inflammations that persist can potentially cause alterations of the cellular microenvironment and progressively lead to structural tissue damage, up to their degeneration [45], [49]. In BrSM the inflammatory response is used as a substitute in clinical decision making.

The vision of inflammation as a static process that ends with the elimination of its mediators has changed a lot in recent years. Today inflammation is considered an active process. As is often observed in homeostatic mechanisms, it is the initial mechanism itself that also determines its end. Among the main protagonists is PGE<sub>2</sub>, which is not only responsible for most of the symptoms associated with acute inflammation, but also plays a fundamental role in the activation of the so-called mediators favouring the resolution of the inflammatory process [26], [27].

Drugs developed linearly, such as non-steroidal anti-inflammatory drugs, whose main target is cyclo-oxygenase 2, have an anti-inflammatory action, but can at the same time prevent the resolution of the problem by forcibly suppressing PGE<sub>2</sub> [28].

It has recently been shown that the multi-component drug *Traumeel* has a different mechanism of action in the context of the inflamed tissue and a modulation effect on PGE<sub>2</sub> and on specialised prorisolutive mediators that can favour a more physiological resolution of the process [50], [51].

## Individualised treatments

In their pioneering article, Ahn et al., they also outlined the future of System Medicine in clinical practice [52].

The applications-omics bode well for a revolution in the approach to the diagnosis and individualisation of patients based on risk, stage of the disease and possible response to treatment. However, the costs and degree of innovation currently prevent the use of these tools as a routine medical practice. This means that doctors must continue to rely on classical methods to selectively choose the therapy of their patients.

The path starts from the collection of the anamnesis, in which the aspects related to genetics and exposome deserve special attention. The patient's prenatal history has the same importance as

post-birth events, as many stress factors, such as maternal psychological stress and exposure to environmental xenobiotics, have a fundamental impact on the patient's responses in the later stages of life. This is often mediated by epigenetic alterations [53], [54], [55].

Work and leisure activities can be indicative of possible exposures and stress factors.

Genetic and genomic markers are often suggestive of possible risks; by way of example, single nucleotide polymorphisms may represent a risk factor, for example in the known association between homocysteine metabolism disorders and cardiovascular diseases [56]; another example is the risk assessment tests for breast cancer [57]. Genomics and metabolomics are also used in clinical practice to predict treatment responses [58].

This is also useful for the probabilistic forecasts cited by Ahn.

The biomarkers and algorithms currently used to diagnose pathologies in terms of phenotypic results (e.g. erythrocyte sedimentation rate, high-sensitivity C-reactive protein and complete blood count) should be used appropriately for clinical decisions.

The treatment based on the progression of the disease and in particular on the recognition of preclinical stages will remain difficult to apply until the sciences-omics and Networks Medicine become part of the common practice.

In BrSM, the effect of the inflammatory response on the microenvironment is used as a substitute / in addition to the sciences-omics available for the interpretation of clinical decisions. Unlike what was thought in the past, the microenvironment has the possibility to reverse the structural alterations, provided that the cell membrane has not been damaged.

In the BrSM there is, therefore, a dynamic attitude in the prescription, which will be based on the degree of progression of the patient's pathology.

To further individualize the treatment, the patient's exposure and microbiome are considered and, consequently, the use of appropriate draining and detoxifying medicines and the insertion of certain probiotic strains, often specific for each pathological process (eg *Bifidobacterium PBL1* in the metabolic syndrome or *Bifidobacterium lactis* CECT 8145, *Bifidobacterium longum* CECT 7347, and *Lactobacillus casei* CECT 9104 in atopic dermatitis) [59], [80].



## Change in therapy paradigm

In the "one drug, one target, one symptom" approach, pharmacological treatment is often symptomatic or aimed at treating phenotypic results secondary to dysregulation. These are static treatments, and patients often take the same therapies for long periods.

Supporting the self-regulation system, the BrSM aims to re-establish a state of health or compensation, and this means that often, once this result is achieved, the patient no longer needs drugs or needs only in limited quantities. This requires careful assessments of disease progression and good monitoring. In the case of advanced phenotypic alterations, drug treatment is frequently the only option available. Obviously, this also applies to diseases in which there is no possibility of regulation, for example in the case of ablation of an organ, and, in these cases, replacement therapy must be taken for life.

## Low dose drugs effects

This characteristic does not exclusively refer to the attempt to reduce the use of drugs to the minimum necessary, which can be the result of better individualisation of the patient or improvement of the state of health through the achievement of optimal self-regulation.

The hormetic effects of the substances are the subject of constant research [60]. The hormesis seems to have positive consequences on the resilience of the organism, in particular through the so-called mitormesis [slight mitochondrial damage can induce a hormetic response (mitormesis) that promotes compensatory adaptive processes] [61], [62], [63].

Some authors have specifically cited the hormetic effects that increase adaptive responses through the exposure of natural phytotherapeutic substances (xenormes) [64].

This is a concept that requires further research but could be a plausible hypothesis to explain how some substances in reduced concentrations exert bioregulation effects.

The low naltrexone dose, which has been discussed earlier, is a good example of how a drug to conventional doses, developed with a specific purpose, can also be used for other purposes. It is able, at this lower dosage, to generate bioregulatory effects. This also happens for other preparations with bioregulation properties: for example, the medicinal product *Lymphomyosot*, originally developed for

lymphatic pathology, has subsequently shown that it can also be usefully used for wound healing [65].

Since-omic technologies allow the analysis of large groups of data on multitarget actions; the identification of alternative applications of drugs is destined to grow over time.

## Synergistic treatments

To achieve bioregulation in dysregulations involving more than one network or different functional modules of a network, it may be necessary to resort to a combination of several drugs (treatments).

This is a common approach in the BrSM, in particular for chronic diseases, in which with the development of comorbidities we are witnessing the subsequent dysregulation of further networks.

Chronic diseases seem to have in common the main dysregulation of certain networks [66], [67], [83]. These include the network inflammatory, the network metabolic, the network energy-mobile, and network neuroendocrine.

The chronic dysregulation of the networks also puts a strain on the processes of self-regulation. It is, therefore, necessary to add cofactors to optimise the efficient operation of enzymes, for example, since they can run out if they are not reintegrated over time. The patient's nutritional status must be carefully considered and, about it, deficient cofactors will be established according to specific needs.

As mentioned above, some pharmacological therapies also lead to the depletion of cofactors that are fundamental for self-regulation (e.g. coenzyme Q 10 and vitamin K2 in statin-based therapies) [25]. Missing cofactors must be adequately replenished and, if bioregulation allows it, the patient must gradually reduce and then stop therapy.

Recently the efficacy of a combination of two drugs with bioregulatory properties and their synergistic effects in the treatment of knee osteoarthritis (Arnica comp. + Zeel T) has been demonstrated [68], [69], [70].

## "Space - sensitive" treatments: administration of drugs in specific locations

As can be seen from the bioregulation model, the microenvironment plays a fundamental role in the therapeutic approach of the BrSM. In numerous

publications, it is argued that connective tissue is an organ with interconnecting properties [71], [72]. A recent publication in *Nature* even speaks of interstitial spaces containing fluidly plastic structures previously not characterised, emphasising the fundamental function of this important tissue and introducing for it the most correct classification of the organ [73].

Drugs can be administered directly in this organ through infiltration techniques at specific points. In fact, injection into the acupuncture points is frequent in the BrSM approach [74], [75], [76], [77]. Intradermal injections are also used in Aesthetic Medicine, similarly to infiltration in the corresponding dermatomes to act on the internal organs [78], [79].

## Conclusions

In the current context, medical personnel are exposed to numerous challenges, which require new tools to respond to patients' needs.

The Systems Medicine approach is making headway in clinical practice as a solution for improving patient management; however, the reference paradigm of conventional therapies "a target, a drug" is proving not entirely suitable.

System Medicine applications, such as BrSM, aim to remedy the shortcomings of the conventional approach, using complex multicomponent drugs, to obtain regulatory effects on multiple targets.

The BrSM complies with the fundamental criteria that distinguish the Systems Medicine approach, but the clear therapeutic objective is the support of patient self-regulation networks. This approach can be associated with "linear drugs" based on the specific needs of patients. Applying these different approaches at the same time, we will witness the birth of a single Medicine: the one that responds to the specific patient's needs at a specific time.

## References

- Cesario A, Cazzola M, Lauro D, Frustaci A, Neri M. A systems medicine clinical platform for understanding and managing non-communicable diseases. *Curr Pharm Des.* 2014; 20(38):5945-5956. <https://doi.org/10.2174/1381612820666140314130449> PMID:24641232
- Bland JS, Minich DM, Eck BM. A Systems Medicine approach: translating emerging science into individualized wellness. *Adv Med.* 2017; 2017:1718957. <https://doi.org/10.1155/2017/1718957> PMID:29164177 PMCid:PMC5661085
- Kramer F, Just S, Zeller T. New perspectives: Systems Medicine in cardiovascular disease. *BMC Syst Biol.* 2018; 12(1):1-13. <https://doi.org/10.1186/s12918-018-0579-5> PMID:29699591 PMCid:PMC5921396
- Trachana K, Bargaje R, Glusman G, Price ND, Huang S, Hood LE. Taking Systems Medicine to heart. *Circ Res.* 2018; 122(9):1276-1289. <https://doi.org/10.1161/CIRCRESAHA.117.310999> PMID:29700072 PMCid:PMC5926821
- Peters U, Dixon AE, Forno E. Obesity and asthma. *J Allergy Clin Immunol.* 2018; 141(4):1169-1179. <https://doi.org/10.1016/j.jaci.2018.02.004> PMID:29627041 PMCid:PMC5973542
- Faienza MF, Wang DQH, Fruhbeck G, Garruti G, Portincasa P. The dangerous link between childhood and adulthood predictors of obesity and metabolic syndrome. *Intern Emerg Med.* 2016; 11(2):175-182. <https://doi.org/10.1007/s11739-015-1382-6> PMID:26758061
- Nutten S. Atopic dermatitis: global epidemiology and risk factors. *Ann Nutr Metab.* 2015; 66(1):8-16. <https://doi.org/10.1159/000370220> PMID:25925336
- Isaevska E, Manasievska M, Alessi D, et al. Cancer incidence rates and trends among children and adolescents in Piedmont, 1967-2011. *PLoS One.* 2017; 12(7):e0181805. <https://doi.org/10.1371/journal.pone.0181805> PMID:28742150 PMCid:PMC5524393
- Courvalin P. Why is antibiotic resistance a deadly emerging disease? *Clin Microbiol Infect.* 2016; 22(5):405-407. <https://doi.org/10.1016/j.cmi.2016.01.012> PMID:26806259
- Turner MC, Vineis P, Seleiro E, et al. EXPOsOMICS: final policy workshop and stakeholder consultation. *BMC Public Health.* 2018; 18(1):260. <https://doi.org/10.1186/s12889-018-5160-z> PMID:29448939 PMCid:PMC5815236
- Frieri M, Kumar K, Boutin A. Antibiotic resistance. *J Infect Public Health.* 2017; 10(4):369-378. <https://doi.org/10.1016/j.jiph.2016.08.007> PMID:27616769
- Gustafsson M, Nestor CE, Zhang H, et al. Modules, networks and systems medicine for understanding disease and aiding diagnosis. *Genome Med.* 2014; 6(10):82. <https://doi.org/10.1186/s13073-014-0082-6> PMID:25473422 PMCid:PMC4254417
- Schork NJ. Time for one-person trials. *Nature.* 2015; 520:609-610. <https://doi.org/10.1038/520609a> PMID:25925459
- Charlesworth CJ, Smit E, Lee DSH, Alramadhan F, Odden MC. Polypharmacy among adults aged 65 years and older in the United States: 1988-2010. *J Gerontol A Biol Sci Med Sci.* 2015; 70(8):989-995. <https://doi.org/10.1093/gerona/glv013> PMID:25733718 PMCid:PMC4573668
- Hu JX, Thomas CE, Brunak S. Network biology concepts in complex disease comorbidities. *Nat Rev Genet.* 2016; 17(10):615-629. <https://doi.org/10.1038/nrg.2016.87> PMID:27498692
- Ahn AC, Tewari M, Poon C-S, Phillips RS. The limits of reductionism in medicine: could systems biology offer an alternative? *PLoS Med.* 2006; 3(6):e208. <https://doi.org/10.1371/journal.pmed.0030208> PMID:16681415 PMCid:PMC1459480
- Cardinal-Fernández P, Nin N, Ruiz-Cabello J, Lorente JA. Systems Medicine: a new approach to clinical practice. *Arch Bronconeumol (English Ed).* 2014; 50(10):444-451. <https://doi.org/10.1016/j.arbr.2014.09.001>
- Apweiler R, Beissbarth T, Berthold MR, et al. Whither Systems Medicine? *Exp Mol Med.* 2018; 50(3):e453. <https://doi.org/10.1038/emmm.2017.290> PMID:29497170 PMCid:PMC5898894
- Fiandaca MS, Mapstone M, Connors E, et al. Systems healthcare: a holistic paradigm for tomorrow. *BMC Syst Biol.* 2017; 11(1):1-17. <https://doi.org/10.1186/s12918-017-0521-2> PMID:29258513 PMCid:PMC5738174
- Goldman AW, Burmeister Y, Cesnulevicius K, et al. Bioregulatory Systems Medicine: an innovative approach to integrating the science of molecular networks, inflammation, and

- systems biology with the patient's autoregulatory capacity? *Front Physiol.* 2015; 6:225. <https://doi.org/10.3389/fphys.2015.00225> PMID:26347656 PMCID:PMC4541032
- 21 Varela FJ, Maturana HR, Uribe RB. Autopoiesis: the organization of living systems, characterization and a model. *Biosystems.* 1974; 5:187-196. [https://doi.org/10.1016/0303-2647\(74\)90031-8](https://doi.org/10.1016/0303-2647(74)90031-8)
- 22 Varela FJ, Shear J. First-person methodologies: what, why, how? *Journal of Consciousness Studies.* 1999; 6(2-3):1-14.
- 23 Barabási A. Emergence of scaling in random networks. *Science.* 1999; 286(5439):509-512. <https://doi.org/10.1126/science.286.5439.509> PMID:10521342
- 24 Barabási A-L, Gulbahce N, Loscalzo J. Network medicine: a network-based approach to human disease. *Nat Rev Genet.* 2011; 12(1):56-68. <https://doi.org/10.1038/nrg2918> PMID:21164525 PMCID:PMC3140052
- 25 Uriarte SM, Rane MJ, Luerman GC, et al. Granule exocytosis contributes to priming and activation of the human neutrophil respiratory burst. *J Immunol.* 2011; 187(1):391-400. <https://doi.org/10.4049/jimmunol.1003112> PMID:21642540 PMCID:PMC3582343
- 26 Whitacre JM. Biological robustness: paradigms, mechanisms, and systems principles. *Front Genet.* 2012; 3:67. <https://doi.org/10.3389/fgene.2012.00067> PMID:22593762 PMCID:PMC3350086
- 27 Okuyama H, Langsjoen PH, Hamazaki T, et al. Statins stimulate atherosclerosis and heart failure: pharmacological mechanisms. *Expert Rev Clin Pharmacol.* 2015; 8(2):189-199. <https://doi.org/10.1586/17512433.2015.1011125> PMID:25655639
- 28 Serhan CN, Levy BD. Resolvins in inflammation: emergence of the pro-resolving superfamily of mediators. *J Clin Invest.* May 2018. <https://doi.org/10.1172/JCI97943> PMID:29757195 PMCID:PMC6025982
- 29 Ricciotti E, FitzGerald GA. Prostaglandins and inflammation. *Arterioscler Thromb Vase Biol.* 2011; 31 (5):986-1000. <https://doi.org/10.1161/ATVBAHA.110.207449> PMID:21508345 PMCID:PMC3081099
- 30 Dakin SG, Dudhia J, Smith RKW. Resolving an inflammatory concept: the importance of inflammation and resolution in tendinopathy. *Vet Immunol Immunopathol.* 2014; 158(3-4):121-127. <https://doi.org/10.1016/j.vetimm.2014.01.007> PMID:24556326 PMCID:PMC3991845
- 31 Cesario A, Auffray C, Russo P, Hood L. P4 medicine needs P4 education. *Curr Pharm Des.* 2014; 20(38):6071-6072. <https://doi.org/10.2174/1381612820666140314145445> PMID:24641231
- 32 van Bon L, Affandi AJ, Broen J, et al. Proteome-wide analysis and CXCL4 as a biomarker in systemic sclerosis. *N Engl J Med.* 2014; 370(5):433-443. <https://doi.org/10.1056/NEJMoa1114576> PMID:24350901 PMCID:PMC4040466
- 33 Buchman TG. The community of the self. *Nature.* 2002; 420(6912):246-251. <https://doi.org/10.1038/nature01260> PMID:12432410
- 34 Buchman TG. Cardiovascular variability as a measure of inflammation. *Crit Care Med.* 2014; 42(8):1964. <https://doi.org/10.1097/CCM.0000000000000460> PMID:25029145
- 35 Fuite J, Vernon SD, Broderick G. Neuroendocrine and immune network re-modeling in chronic fatigue syndrome: an exploratory analysis. *Genomics.* 2008; 92(6):393-399. <https://doi.org/10.1016/j.ygeno.2008.08.008> PMID:18775774
- 36 Dobrota R, Mihai C, Distler O. Personalized medicine in systemic sclerosis: facts and promises. *Curr Rheumatol Rep.* 2014; 16(6):425. <https://doi.org/10.1007/s11926-014-0425-8> PMID:24752884
- 37 Barko PC, McMichael MA, Swanson KS, Williams DA. The gastrointestinal microbiome: a review. *J Vet Intern Med.* 2018; 32(1):9-25. <https://doi.org/10.1111/jvim.14875> PMID:29171095 PMCID:PMC5787212
- 38 Chrousos GP. Stress and disorders of the stress system. *Nature reviews endocrinology.* 2009; 5(7):374-381. <https://doi.org/10.1038/nrendo.2009.106> PMID:19488073
- 39 Escher BI, Hackermuller J, Polte T, et al. From the exposome to mechanistic understanding of chemical-induced adverse effects. *Environ Int.* 2017; 99:97-106. <https://doi.org/10.1016/j.envint.2016.11.029> PMID:27939949 PMCID:PMC6116522
- 40 Miller GW, Jones DP. The nature of nurture: refining the definition of the exposome. *Toxicol Sci.* 2014; 137(1):1-2. <https://doi.org/10.1093/toxsci/kft251> PMID:24213143 PMCID:PMC3871934
- 41 Nakamura J, Mutlu E, Sharma V, et al. The endogenous exposome. *DNA Repair (Amst).* 2014; 19:3-13. <https://doi.org/10.1016/j.dnarep.2014.03.031> PMID:24767943 PMCID:PMC4097170
- 42 St Laurent G, Seilheimer B, Tackett M, et al. Deep sequencing transcriptome analysis of murine wound healing: effects of a multicomponent, multitarget natural product therapy-Tr14. *Front Mol Biosci.* 2017; 4(August):1-12. <https://doi.org/10.3389/fmolb.2017.00057> PMID:28879183 PMCID:PMC5572416
- 43 Kitano H. Violations of robustness trade-offs. *Mol Syst Biol.* 2010; 6:384. <https://doi.org/10.1038/msb.2010.40> PMID:20571533 PMCID:PMC2913402
- 44 Kitano H. Biological robustness in complex host-pathogen systems. *Prog Drug Res.* 2007; 64(239):239-263. [https://doi.org/10.1007/978-3-7643-7567-6\\_10](https://doi.org/10.1007/978-3-7643-7567-6_10) PMID:17195478
- 45 Kotas ME, Medzhitov R. Homeostasis, inflammation and disease susceptibility. *Cell.* 2015; 160(5):816-827. <https://doi.org/10.1016/j.cell.2015.02.010> PMID:25723161 PMCID:PMC4369762
- 46 Stearns SC, Medzhitov R. *Evolutionary Medicine.* Oxford, UK: Oxford University Press; 2016.
- 47 Cheng LE, Locksley RM. Allergic inflammation: innately homeostatic. *Cold Spring Harb Perspect Biol.* 2014; 7(3):a016352. <https://doi.org/10.1101/cshperspect.a016352> PMID:25414367 PMCID:PMC4355269
- 48 Miyake K, Kaisho T. Homeostatic inflammation in innate immunity. *Curr Opin Immunol.* 2014; 30(10):85-90. <https://doi.org/10.1016/j.coi.2014.08.003> PMID:25190609
- 49 Chovatiya R, Medzhitov R. Stress, inflammation, and defense of homeostasis. *Mol Cell.* 2014; 54(2):281-288. <https://doi.org/10.1016/j.molcel.2014.03.030> PMID:24766892 PMCID:PMC4048989
- 50 St Laurent G, Toma I, Seilheimer B, et al. Differential effects of Tr14 versus diclofenac on COX/LOX pathways revealed by RNASeq. *Ann Rheum Dis.* 2018; 77(2):238-239. <https://doi.org/10.1136/annrheumdis-2018-eular.3779>
- 51 St Laurent G, Toma I, Tackett M, et al. Differential effects of Tr14 versus diclofenac on pro-resolving lipid mediators revealed by RNASeq. *Ann Rheum Dis.* 2018; 77(2):1237-1238. <https://doi.org/10.1136/annrheumdis-2018-eular.3789>
- 52 Ahn AC, Tewari M, Poon C-S, Phillips RS. The clinical applications of a systems approach. *PLoS Med.* 2006; 3(7):e209. <https://doi.org/10.1371/journal.pmed.0030209> PMID:16683861 PMCID:PMC1459481
- 53 Marciniak A, Patro-Matysza J, Kimber-Trojnar Z, Marciniak B, Oleszczuk J, Leszczynska-Gorzela B. Fetal programming of the metabolic syndrome. *Taiwan J Obstet Gynecol.* 2017; 56(2): 133-138. <https://doi.org/10.1016/j.tjog.2017.01.001> PMID:28420495
- 54 Perera F, Herbstman J. Prenatal environmental exposures, epigenetics, and disease. *Reprod Toxicol.* 2011; 31(3):363-373. <https://doi.org/10.1016/j.reprotox.2010.12.055> PMID:21256208 PMCID:PMC3171169
- 55 Jiménez-Chillarón JC, Nijland MJ, Ascensão AA, et al. Back to the future: transgenerational transmission of xenobiotic-induced epigenetic remodeling. *Epigenetics.* 2015; 10(4):259-273. <https://doi.org/10.1080/15592294.2015.1020267> PMID:25774863

PMCID:PMC4622959

56. Sun K, Song J, Liu K, et al. Associations between homocysteine metabolism related SNPs and carotid intima-media thickness: a Chinese sib pair study. *J Thromb Thrombolysis*. 2017; 43(3):401-410. <https://doi.org/10.1007/s11239-016-1449-x> PMID:27822905 PMCID:PMC5337241
57. Thompson ER, Rowley SM, Li N, et al. Panel testing for familial breast cancer: calibrating the tension between research and clinical care. *J Clin Oncol*. 2016; 34(13):1455-1459. <https://doi.org/10.1200/JCO.2015.63.7454> PMID:26786923
58. Monte AA, Brocker C, Nebert DW, Gonzalez FJ, Thompson DC, Vasiliou V. Improved drug therapy: triangulating phenomics with genomics and metabolomics. *Hum Genomics*. 2014; 8(1):1-9. <https://doi.org/10.1186/s40246-014-0016-9> PMID:25181945 PMCID:PMC4445687
59. Navarro-López V, Ramirez-Boscà A, Ramón-Vidal D, et al. Effect of oral administration of a mixture of probiotic strains on SCORAD Index and use of topical steroids in young patients with moderate atopic dermatitis: a randomized clinical trial. *JAMA Dermatol*. 2018; 154(1):37-43. <https://doi.org/10.1001/jamadermatol.2017.3647> PMID:29117309 PMCID:PMC5833582
60. Calabrese EJ. Hormesis: from mainstream to therapy. *J Cell Commun Signal*. 2014; 8(4):289-291. <https://doi.org/10.1007/s12079-014-0255-5> PMID:25366126 PMCID:PMC4390802
61. Yun J, Finkel T. Mitohormesis. *Cell Metab*. 2014; 19(5):757-766. <https://doi.org/10.1016/j.cmet.2014.01.011> PMID:24561260 PMCID:PMC4016106
62. Srivastava S. The mitochondrial basis of aging and age-related disorders. *Genes (Basel)*. 2017; 8(12). <https://doi.org/10.3390/genes8120398> PMID:29257072 PMCID:PMC5748716
63. Barbour JA, Turner N. Mitochondrial stress signaling promotes cellular adaptations. *Int J Cell Biol*. 2014; 2014. <https://doi.org/10.1155/2014/156020> PMID:24587804 PMCID:PMC3920668
64. Kim S-A, Lee Y-M, Choi J-Y, Jacobs DR, Lee D-H. Evolutionarily adapted hormesis-inducing stressors can be a practical solution to mitigate harmful effects of chronic exposure to low dose chemical mixtures. *Environ Pollut*. 2018; 233:725-734. <https://doi.org/10.1016/j.envpol.2017.10.124> PMID:29126094
65. Keim AP, Slis JR, Mendez U, et al. The multicomponent medication Lymphomyosot improves the outcome of experimental lymphedema. *Lymphat Res Biol*. 2013; 11(2):81-92. <https://doi.org/10.1089/lrb.2012.0024> PMID:23725444 PMCID:PMC3696932
66. van Ommen B, Wopereis S, van Empelen P, et al. From diabetes care to diabetes cure: the integration of systems biology, eHealth, and behavioral change. *Front Endocrinol (Lausanne)*. 2018; 8:381. <https://doi.org/10.3389/fendo.2017.00381> PMID:29403436 PMCID:PMC5786854
67. Stroeve JHM, van Wietmarschen H, Kremer BHA, van Ommen B, Wopereis S. Phenotypic flexibility as a measure of health: the optimal nutritional stress response test. *Genes Nutr*. 2015; 10(3):459. <https://doi.org/10.1007/s12263-015-0459-1> PMID:25896408 PMCID:PMC4404421
68. Lozada C, del Rio E, Reitberg D, Smith R, Kahn C, Moskowitz RW. A multi-center double-blind, randomized, controlled trial (db-RCT) to evaluate the effectiveness and safety of co-administered Traumeel® (Tr14) and Zeel® (Ze14) intra-articular (IA) injections versus IA placebo in patients with moderate-to-severe pain ass. *Arthritis Rheum*. 2014; 66(Suppl):S1266. <https://doi.org/10.1136/annrheumdis-2015-eular.4268>
69. Lozada C, del Rio E, Reitberg DP, Smith R, Moskowitz RW. Risk-benefit of coadministered Traumeel® (Tr14) and Zeel® (Ze14) intra-articular (IA) injections in patients with moderate-to-severe pain associated with OA of the knee (OAK) (THU0441). *Ann Rheum Dis*. 2015; 74(2):4268. <https://doi.org/10.1136/annrheumdis-2015-eular.4268>
70. Lozada CJ, del Rio E, Reitberg DP, Smith RA, Kahn CB, Moskowitz RW. A doubleblind, randomized, saline-controlled study of the efficacy and safety of co-administered intra-articular injections of Tr14 and Ze14 for treatment of painful osteoarthritis of the knee: the MOZArT trial. *Eur J Integr Med*. 2017; 13:54-63. <https://doi.org/10.1016/j.eujim.2017.07.005> doi: 10.1016/j.eujim.2017.07.005.
71. Langevin HM. Connective tissue: a body-wide signaling network? *Med Hypotheses*. 2006; 66(6):1074-1077. <https://doi.org/10.1016/j.mehy.2005.12.032> PMID:16483726
72. Oschman JL. Charge transfer in the living matrix. *J Bodyw Mov Ther*. 2009; 13(3):215-228. <https://doi.org/10.1016/j.jbmt.2008.06.005> PMID:19524846
73. Benias PC, Wells RG, Sackey-Aboagy B, et al. Structure and distribution of an unrecognized interstitium in human tissues. *Sci Rep*. 2018; 8(1):1-8. <https://doi.org/10.1038/s41598-018-23062-6> PMID:29588511 PMCID:PMC5869738
74. Langevin HM, Yandow J a. Relationship of acupuncture points and meridians to connective tissue planes. *Anat Rec*. 2002; 269(6):257-265. <https://doi.org/10.1002/ar.10185> PMID:12467083
75. Kersschot J. Biopuncture: The Management of Common Orthopedic and Sports Disorders. Thieme; 2014 May 14.
76. Frase W, Bauer G. Moderne Homöopathie. Baden-Baden, Germany: Aurelia, 2002.
77. Ben-Yakir S. Primary evaluation of homeopathic remedies injected via acupuncture points to reduce chronic high somatic cell counts in modern dairy farms. *J Biomed Ther*. 2004; (Fall):13-15.
78. Bossy J. Morphological data concerning the acupuncture points and channel network. *Acupuncture & electro-therapeutics research*. 1984; 9(2):79-106. <https://doi.org/10.3727/036012984816714758> PMID:6148847
79. Bredikhin A V, Bredikhin KA, Chekha OA. New organ representation areas localized between front & back of the human neck and body their potential application to metameriac acupuncture. *Acupunct Electrother Res*. 2016; 41(3-4):199-205. <https://doi.org/10.3727/036012917X14831065080050>
80. Roccia MG, Fioranelli M, Lotti T. *Dermatol Ther*. Obesity, psoriasis, and microbiota: an unexplored dangerous connection? *J Biol Regul Homeost Agents*. 2015. <https://doi.org/10.1111/dth.12218> PMID:25731602
81. França K, Castillo DE, Roccia MG, Lotti T, Wollina U, Fioranelli M. Psychoneurocutaneous medicine: past, present and future. *Wien Med Wochenschr*. 2017. <https://doi.org/10.1007/s10354-017-0573-3> PMID:28616665
82. Fioranelli M, Del Prete M, Aracena JC, Roccia MG, Dal Lin C, Tomella C. *Integrative Cardiology*. Editor: Massimo Fioranelli. Low-Dose Therapy for the Treatment of Low-Grade Chronic Inflammation. Springer International Switzerland, 2017. [https://doi.org/10.1007/978-3-319-40010-5\\_3](https://doi.org/10.1007/978-3-319-40010-5_3) PMID:28801812
83. Fioranelli M, Roccia MG, Lotti T. Coronary blood flow and psoriasis. *Dermatol Ther*. 2017. <https://doi.org/10.1111/dth.12471> PMID:28211598

# Giant Squamous Cell Carcinoma on Chronic Lichen Planus on the Ankle - A Case Report and Short Literature Review

Uwe Wollina<sup>1\*</sup>, Claudia Krönert<sup>1</sup>, Jacqueline Schönlebe<sup>2</sup>, Aleksandra Vojvodic<sup>3,4</sup>, Torello Lotti<sup>4</sup>

<sup>1</sup>Department of Dermatology and Allergology, Städtisches Klinikum Dresden, Academic Teaching Hospital, Dresden, Germany; <sup>2</sup>Institute of Pathology "Georg Schmorl", Städtisches Klinikum Dresden, Academic Teaching Hospital, Dresden, Germany; <sup>3</sup>Military Medical Academy of Belgrade, Belgrade, Serbia; <sup>4</sup>Department of Dermatology, University of Rome "G. Marconi", Rome, Italy

## Abstract

**Citation:** Wollina U, Krönert C, Schönlebe J, Vojvodic A, Lotti T. Giant Squamous Cell Carcinoma on Chronic Lichen Planus on The Ankle - A Case Report and Short Literature Review. Open Access Maced J Med Sci. 2019 Sep 30; 7(18):3061-3063. <https://doi.org/10.3889/oamjms.2019.553>

**Keywords:** Squamous cell carcinoma; Lichen planus; Malignant transformation; Surgery; Sepsis

**\*Correspondence:** Uwe Wollina, Department of Dermatology and Allergology, Städtisches Klinikum Dresden, Academic Teaching Hospital, Dresden, Germany. E-mail: [Uwe.Wollina@klinikum-dresden.de](mailto:Uwe.Wollina@klinikum-dresden.de)

**Received:** 09-Apr-2019; **Revised:** 19-Jun-2019; **Accepted:** 20-Jun-2019; **Online first:** 19-Aug-2019

**Copyright:** © 2019 Uwe Wollina, Claudia Krönert, Jacqueline Schönlebe, Aleksandra Vojvodic, Torello Lotti. This is an open-access article distributed under the terms of the Creative Commons Attribution-NonCommercial 4.0 International License (CC BY-NC 4.0)

**Funding:** This research did not receive any financial support

**Competing Interests:** The authors have declared that no competing interests exist

**BACKGROUND:** Cutaneous squamous cell carcinoma (SCC) is the second most common malignancy of skin. Although a major risk factor is a chronic exposure to ultraviolet radiation, preexistent chronic inflammatory disorders may also possess an increased risk for SCC. That is not the case for cutaneous lichen planus in contrast to oral lichen planus and oral SCC.

**CASE REPORT:** We report the case of an 87-year-old Caucasian woman presenting with a giant verrucous tumour on the left ankle. She suffered from long-standing disseminated lichen planus. Histology confirmed the diagnosis of SCC on partly verrucous lichen planus. The course was complicated due to sepsis. An emergency transfemoral amputation became necessary. The patients survived and could be released into her nursery. A literature review underlined the rarity of SCC on lichen planus of the skin. Most of these rare cases were in patients in their second half of life on the lower legs. Hypertrophic lichen planus was overrepresented.

**CONCLUSIONS:** Although very rare by number, SCC can complicate lichen planus and lead to the life-threatening situation. Atypical verrucous lesions on lichen planus warrant a histologic analysis. Surgery is the treatment of choice for cutaneous SCC.

## Introduction

Cutaneous squamous cell carcinoma is the second most common malignancy of skin. Chronic exposure to ultraviolet radiation (UVR) is the most important environmental factor. Fair skin complexion, immunosuppression, exposure to arsenic compounds are also contributing factors [1].

Major risk factors for relapse and metastasis are a Breslow thickness > 6 mm (Relative risk-RR, 7.13) and perineural invasion (RR, 4.30), while a diameter > 20 mm (RR, 3.22) bears the highest risk for metastasis [2]. SCC can develop as a consequence of chronic inflammatory skin lesions such as in chronic discoid lupus erythematosus [3], hidradenitis suppurativa/ acne inversa [4], chronic leg ulcers [5], erythema ab igne [6], or recessive dystrophic epidermolysis bullosa [7], and lichen planus [8].

Lichen planus is a chronic inflammatory T-cell disorder of the skin and mucous membranes. Oral lichen planus is considered a facultative precancerous lesion for oral SCC. Ulcerations, tongue site, and female gender are risk factors for a malignant transformation of oral lichen planus into SCC. The overall transformation rate has been estimated in one study as high as 1.4% [8]. On the contrary, a meta-analysis for cutaneous lichen planus came to the conclusion that there is no increased risk for cutaneous SCC [9].

## Case Report

An 87-year-old female patient from a nursery presented with a malodorous verrucous tumour on her left leg. She had a medical history of a complicated

lower leg fracture 30 years ago. She had no weight loss or fever but reported a local pain.

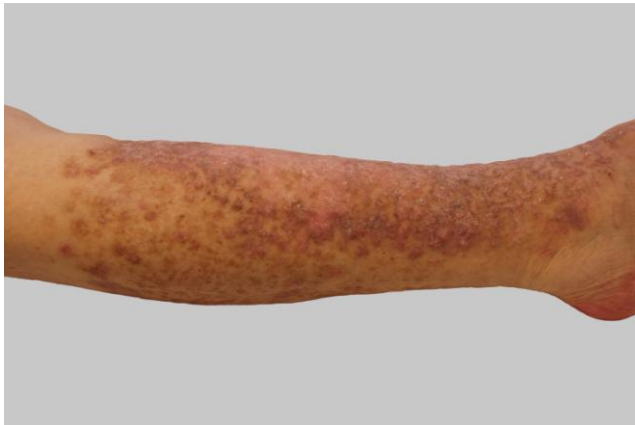

Figure 1: Disseminated lichen planus of the leg (right leg)

On examination, we observed a circumferential exophytic verrucous tumour on a chronic lichen planus lesion on the left ankle (Figure 1 and 2).

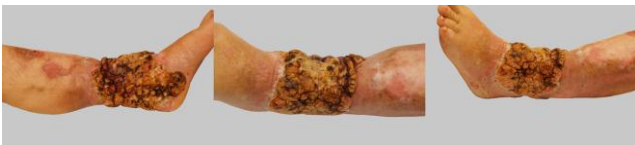

Figure 2: Circumferential verrucous squamous cell carcinoma on lichen planus (left leg)

We performed a deep skin biopsy for diagnosis. Histologic examination revealed a well-differentiated cutaneous squamous cell carcinoma (SCC), partly ulcerated, with bacterial colonization (Figure 3) on a verrucous lichen planus on the left leg and partly verrucous lichen planus on the right leg and left lower arm (Figure 4).

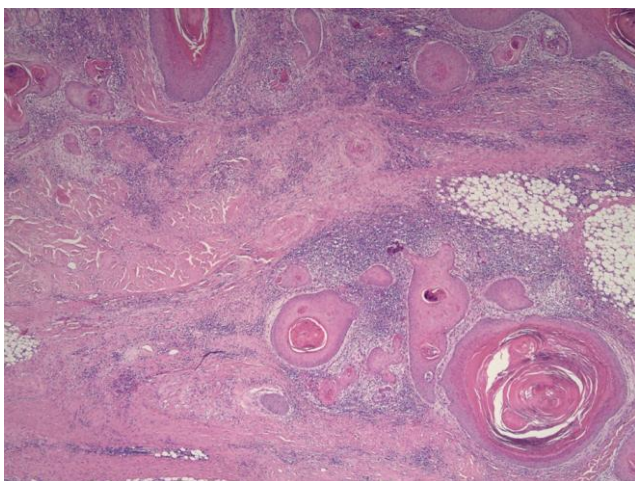


Figure 3: Histology of the squamous cell carcinoma composed of islands and cords of epithelial cells with keratin pearls in deep dermis (HE x 4)

Lymph node ultrasound demonstrated several

suspicious enlarged nodes in the left groin with up to 42 mm in diameter. X-ray of the left lower suggested old posttraumatic lesions with inhomogenous spongiosa of the distal third of the tibia bone. Chronic osteomyelitis could be ruled out for sure. A bony infiltration of the tumour was possible.

Computerised tomography of the trunk excluded a metastatic spread. Enlarged lymph nodes in the groins were considered to be reactive only.

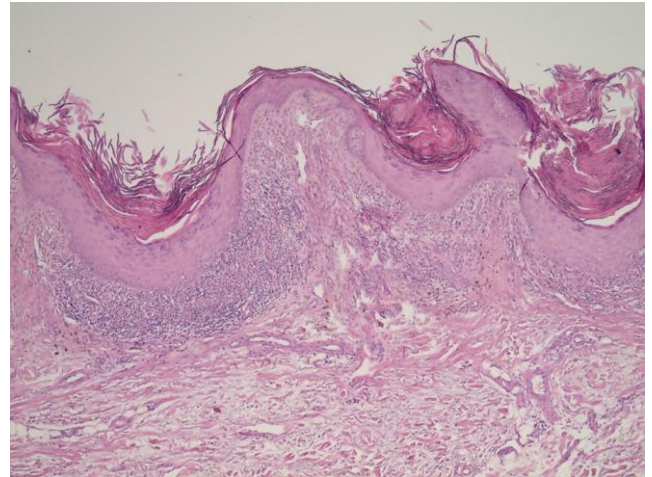


Figure 4: Histology of lichen planus with sawtooth-like epidermis, hyperkeratosis and hypergranulosis associated

Laboratory findings: Leucocytosis of 24 Gpt/L (normal range 4 to 10), stable hypochromic microcytic anaemia of with a haemoglobin level of 6 mmol/L (normal range 8.4 to 10.9), lactate dehydrogenase was normal.

The final diagnosis was SCC (pT3 cNX cM0 G1) on verrucous lichen planus.

The case was brought to the interdisciplinary tumour board. Radiotherapy was not considered to be curative, and chemotherapy was hardly tolerable by the elderly patient. Vascular and orthopaedic surgeons suggested a major amputation of the left leg, but the patient disagreed. We performed palliative therapy and good ulcer care.

Two weeks later, she developed fever, hypotonia, tachycardia and fatigue. Her procalcitonin level was 37 ng/mL. A venous blood culture identified the anaerobic germ *Bacteroides fragilis*. Laboratory findings disclosed leukocytosis of 24.7 Gpt/L, anaemia 5.30 mmol/L, thrombocytosis of 517 Tpt/L, and a C-reactive protein of 60.9 mg/L.

She was treated in the emergency department for sepsis. Three days later, a transfemoral amputation was necessary. Histological analysis revealed a verrucous SCC, R0 resection, and a verrucous lichen planus. After surgery, the patient rejected lymph node removal, radio or chemotherapy. Final tumour diagnosis was verrucous SCC pT3 NX G1 R0. The patient could be released into her nursery.

## Discussion

In contrast to oral lichen planus, development of an SCC on cutaneous lichen planus is rare. The incidence of SCC in lichen planus has been estimated between 0.4% [9] and 1.74% [10].

In the meta-analysis of Sigurgeirsson and Lindelöf (1991) 36 reports of SCC associated with lichen planus were analysed among 2071 lichen planus patients [10]. In 2011, Friedl et al. reported on three patients who developed an SCC on chronic lichen planus of the lower leg and analysed another 24 cases within five years [11]. Five more cases have been reported since then in the international literature, mostly on lower legs and in association with hypertrophic or verrucous lichen planus [12], [13], [14], [15], [16]. We identified another two cases between published 2003 and 2007 [17], [18]. This translates into only 72 cases, including the present one.

During the process of malignant transformation, keratinocytes lose the production of C-Jun, part of the AP-1 transcription factor complex for the regulation of cell proliferation, differentiation and transformation [19]. The late epidermal differentiation marker K2e, a polypeptide of 70 kd, becomes diminished in cutaneous SCC [20].

Cutaneous lichen planus, however, does not possess an increased risk for SCC [10]. These cases of concomitant lichen planus and SCC are extremely rare.

## References

- Green AC, Olsen CM. Cutaneous squamous cell carcinoma: an epidemiological review. *Br J Dermatol*. 2017; 177(2):373-381. <https://doi.org/10.1111/bjd.15324> PMID:28211039
- Thompson AK, Kelley BF, Prokop LJ, Murad MH, Baum CL. Risk Factors for Cutaneous Squamous Cell Carcinoma Recurrence, Metastasis, and Disease-Specific Death: A Systematic Review and Meta-analysis. *JAMA Dermatol*. 2016; 152(4):419-28. <https://doi.org/10.1001/jamadermatol.2015.4994> PMID:26762219 PMCid:PMC4833641
- Motswaledi MH, Khammissa RA, Wood NH, Meyerov R, Lemmer J, Feller L. Discoid lupus erythematosus as it relates to cutaneous squamous cell carcinoma and to photosensitivity. *SADJ*. 2011; 66(7):340-3.
- Chapman S, Delgadillo D III, Barber C, Khachemoune A. Cutaneous squamous cell carcinoma complicating hidradenitis suppurativa: a review of the prevalence, pathogenesis, and treatment of this dreaded complication. *Acta Dermatovenerol Alp Pannonica Adriat*. 2018; 27(1):25-28. <https://doi.org/10.15570/actaapa.2018.5> PMID:29589641
- Reich-Schupke S, Doerler M, Wollina U, Dissemmond J, Horn T, Strölin A, Erfurt-Berge C, Stücker M. Squamous cell carcinomas in chronic venous leg ulcers. Data of the German Marjolin Registry and review. *J Dtsch Dermatol Ges*. 2015; 13(10):1006-13. <https://doi.org/10.1111/ddg.12649>
- Wollina U, Helm C, Hansel G, Köstler E, Schönlebe J. Two cases of erythema ab igne, one with a squamous cell carcinoma. *G Ital Dermatol Venereol*. 2007; 142(4):415-418.
- Kim M, Murrell DF. Update on the pathogenesis of squamous cell carcinoma development in recessive dystrophic epidermolysis bullosa. *Eur J Dermatol*. 2015; 25 Suppl 1:30-2. <https://doi.org/10.1684/ejd.2015.2552> PMID:26083672
- Richards D. Malignant transformation rates in Oral Lichen Planus. *Evid Based Dent*. 2018; 19(4):122. <https://doi.org/10.1038/sj.ebd.6401349> PMID:30573869
- Singh SK, Saikia UN, Ajith C, Kumar B. Squamous cell carcinoma arising from hypertrophic lichen planus. *J Eur Acad Dermatol Venereol*. 2006; 20(6):745-6. <https://doi.org/10.1111/j.1468-3083.2006.01500.x> PMID:16836514
- Sigurgeirsson B, Lindelöf B. Lichen planus and malignancy. An epidemiologic study of 2071 patients and a review of the literature. *Arch Dermatol*. 1991; 127(11):1684-8. <https://doi.org/10.1001/archderm.1991.01680100084009> PMID:1952973
- Friedl TK, Flaig MJ, Ruzicka T, Rupec RA. Verruköses spinözelluläres Karzinom auf Lichen ruber hypertrophicus. Drei Fallberichte mit Literaturüberblick. *Hautarzt*. 2011; 62(1):40-5. <https://doi.org/10.1007/s00105-010-1961-4> PMID:20664992
- Haenen CCP, Buurma AAJ, Genders RE, Quint KD. Squamous cell carcinoma arising in hypertrophic lichen planus. *BMJ Case Rep*. 2018; 2018. <https://doi.org/10.1136/bcr-2017-224044> PMID:30002207
- Desroche T, Moawad S, Cuny JF, Lerondeau B, Simon E, Bursztejn AC, Schmutz JL. Bilateral squamous cell carcinoma arising from cutaneous ulcerative lichen planus of the extremities: two case reports. *Eur J Dermatol*. 2018; 28(3):391-392. <https://doi.org/10.1684/ejd.2018.3255> PMID:29547127
- Ali NM, Bhat R, Rao SB. Concurrent Presentation of Erythrodermic Lichen Planus and Squamous Cell Carcinoma: Coincidence or Malignant Transformation? *Indian J Dermatol*. 2015; 60(5):457-60. <https://doi.org/10.4103/0019-5154.164355> PMID:26538691 PMCid:PMC4601411
- Ghosh S, Kotne S, Ananda Rao PB, Turlapati SP, Kumar Soren D. Squamous cell carcinoma developing in a cutaneous lichen planus lesion: a rare case. *Case Rep Dermatol Med*. 2014; 2014:205638. <https://doi.org/10.1155/2014/205638> PMID:24839562 PMCid:PMC4006557
- Garrido Colmenero C, Martín Castro A, Valenzuela Salas I, Martínez García E, Blasco Morente G, Tercedor Sánchez J. Squamous cell carcinoma in lichen planopilaris. *J Dermatol Case Rep*. 2013; 7(3):84-7. <https://doi.org/10.3315/jdcr.2013.1147> PMID:24133562 PMCid:PMC3797015
- Giesecke LM, Reid CM, James CL, Huilgol SC. Giant keratoacanthoma arising in hypertrophic lichen planus. *Australas J Dermatol*. 2003; 44(4):267-9. <https://doi.org/10.1046/j.1440-0960.2003.00006.x> PMID:14616493
- Krasowska D, Bogaczewicz J, Chodorowska G. Development of squamous cell carcinoma within lesions of cutaneous lichen planus. *Eur J Dermatol*. 2007; 17(5):447-8.
- Abdou AG, Marae AH, Shoeib M, Dawood G, Abouelfath E. C-Jun expression in lichen planus, psoriasis, and cutaneous squamous cell carcinoma, an immunohistochemical study. *J Immunoassay Immunochem*. 2018; 39(1):58-69. <https://doi.org/10.1080/15321819.2017.1395347> PMID:29144206
- Bloor BK, Tidman N, Leigh IM, Odell E, Dogan B, Wollina U, Ghali L, Waseem A. Expression of keratin K2e in cutaneous and oral lesions: association with keratinocyte activation, proliferation, and keratinization. *Am J Pathol*. 2003; 162(3):963-75. [https://doi.org/10.1016/S0002-9440\(10\)63891-6](https://doi.org/10.1016/S0002-9440(10)63891-6)

# The Impact of Immunological Factors on Depression Treatment – Relation Between Antidepressants and Immunomodulation Agents

Jovana Vojvodic<sup>1</sup>, Goran Mihajlovic<sup>2</sup>, Petar Vojvodic<sup>1</sup>, Dusan Radomirovic<sup>3</sup>, Aleksandra Vojvodic<sup>4</sup>, Tatjana Vlaskovic-Jovicevic<sup>1</sup>, Zorica Peric-Hajzler<sup>5</sup>, Dusica Matovic<sup>5</sup>, Sanja Dimitrijevic<sup>6</sup>, Goran Sijan<sup>7</sup>, Maria Grazia Rocca<sup>8</sup>, Massimo Fioranelli<sup>8</sup>, Torello Lotti<sup>9</sup>

<sup>1</sup>*Clinic for Psychiatric Disorders “Dr. Laza Lazarevic”, Belgrade, Serbia;* <sup>2</sup>*Faculty of Medical Sciences, Department of Psychiatry, University of Kragujevac, Kragujevac, Serbia;* <sup>3</sup>*Faculty of Medicine, University of Nis, Serbia;* <sup>4</sup>*Department of Dermatology and Venereology, Military Medical Academy, Belgrade, Serbia;* <sup>5</sup>*Military Medical Academy, Belgrade, Serbia;* <sup>6</sup>*Department of Gynecology, Military Medical Academy, Belgrade, Serbia;* <sup>7</sup>*Clinic for Plastic Surgery and Burns, Military Medical Academy, Belgrade, Serbia;* <sup>8</sup>*Department of Nuclear Physics, Sub-nuclear and Radiation, G. Marconi University, Rome, Italy;* <sup>9</sup>*Department of Dermatology, University of G. Marconi, Rome, Italy*

## Abstract

**Citation:** Vojvodic J, Mihajlovic G, Vojvodic P, Radomirovic D, Vojvodic A, Vlaskovic-Jovicevic T, Peric-Hajzler Z, Matovic D, Dimitrijevic S, Sijan G, Rocca MG, Fioranelli M, Lotti T. The Impact of Immunological Factors on Depression Treatment – Relation Between Antidepressants and Immunomodulation Agents. *Open Access Maced J Med Sci.* 2019 Sep 30; 7(18):3064-3069. <https://doi.org/10.3889/oamjms.2019.779>

**Keywords:** Depression; Inflammation; Antidepressants; Cytokines

**\*Correspondence:** Massimo Fioranelli, Department of Nuclear Physics, Sub-nuclear and Radiation, G. Marconi University, Rome, Italy. E-mail: [massimo.fioranelli@gmail.com](mailto:massimo.fioranelli@gmail.com)

**Received:** 13-Jul-2019; **Revised:** 17-Aug-2019; **Accepted:** 18-Aug-2019; **Online first:** 12-Sep-2019

**Copyright:** © 2019 Jovana Vojvodic, Goran Mihajlovic, Petar Vojvodic, Dusan Radomirovic, Aleksandra Vojvodic, Tatjana Vlaskovic-Jovicevic, Zorica Peric-Hajzler, Dusica Matovic, Sanja Dimitrijevic, Goran Sijan, Maria Grazia Rocca, Massimo Fioranelli, Torello Lotti. This is an open-access article distributed under the terms of the Creative Commons Attribution-NonCommercial 4.0 International License (CC BY-NC 4.0)

**Funding:** This research did not receive any financial support

**Competing Interests:** The authors have declared that no competing interests exist

It is determined that 30% of patients with depression are resistant to antidepressant medication. The increased concentration of inflammation factors, such as C-reactive protein, and pro-inflammatory cytokines, have been detected in serum in these patients. It is necessary to establish new therapeutic possibilities and protocols that are created to overcome the difficulties caused by increased concentration of inflammatory biomarkers in depressive patients. The Selective Serotonin Reuptake Inhibitors (SSRIs) are considered to be the most powerful antidepressants, increasing the level of serotonin in endogenous depression, as well as in that caused by immunological mechanisms. It is believed that agents that influence cytokines, immunological signal pathways and cytokine syntheses, like the inhibitors of cyclooxygenase enzyme and other non-steroidal anti-inflammatory drugs (NSAIDs), are very important in the potential treatment of residual symptoms of depression. Treatment with cytokine antagonists is one of the potential adjuvant therapies, along with antidepressants. Signal pathways blockers, such as the inhibitors of cyclooxygenase and other NSAIDs, are in the phase of research, in terms of their antidepressant effects. Also, it has been shown that the inhibition of indoleamine 2,3-dioxygenase (IDO) and kynurenine (KYN) signal pathways in the synthesis of neurotransmitters, by application of IDO antagonists, are leading to suppression of pro-inflammatory cytokine effects. Antidepressants may have anti-inflammatory effects, depending on dose and type, and they achieve this effect through the decrease of pro-inflammatory cytokine production and increase of anti-inflammatory cytokines. Also, antidepressants modulate the humoral and cellular immune system. This work aims to summarise certain neurobiological and neuroimmunological specificities that have been observed in patients with depression, antidepressants and immunomodulation agents. The understanding of complex and heterogenic pathophysiology of depression through the prism of the altered immune system, is of major importance, in terms of better optimisation of pharmacotherapy, and options for a personalised approach in depressive disorder treatment.

## Introduction

In the last 20 years, the great expansion of biological psychiatry, that is neurosciences, has been observed. They aim to decode still insufficiently explored psychiatric diseases, like depression, which is a leading cause of morbidity worldwide, because of its high prevalence. This situation is certainly the result of the development of molecular, genetic and

neuroimaging techniques that enable the changing of current viewing of causes, course and treatment of psychiatric diseases.

The understanding of the comprehensive and heterogenic etiopathogenesis of depression, that more and more implements the role of the altered immune system is of major importance for better determination of pharmacotherapy. Because numerous studies confirm the contribution of the activated immune system and its factors in the



occurrence of depressive disorder, it is necessary to modify already existing pharmacotherapy, as well as to investigate new options, in terms of immunomodulating agents. The researches done so far have shown that innate immunity is mostly involved in the pathophysiology of depressive disorder, that is the activity of pro-inflammatory cytokines. It is believed that anti-inflammatory agents that establish the homeostasis of the immune system may have a role in the reduction of depressive symptoms. The levels of biomarkers such as C-reactive protein, tumour necrosis factor (TNF) and interleukin (IL)-1, as well as IL-6, are often increased in depressive patients, especially in those that are resistant to antidepressant treatment. They account for 30% of all patients with depression [1], [2]. This is often provoked by distress because distress activates the immune system, especially the one in earlier stages of life, and more likely if there is a genetic predisposition involved. Already mentioned pro-inflammatory cytokines activate pro-inflammatory prostaglandin E2 (PGE2), which has a leading role in inflammation mediation [1].

Pro-inflammatory cytokines created and released in the brain interact with neurotransmitters, by activating tryptophan and serotonin-degradation enzymes indoleamine-2, 3 dioxygenases (IDO) and by increasing the activity of serotonin transporters. This further leads to the decrease of serotonin available in the synaptic crack. Pro-inflammatory cytokines may be the future in the establishment of more successful antidepressant therapy, because they may be the target of anti-inflammatory therapy and modifiers of cytokine signals, in terms of defined biomarkers [3]. Tryptophan/kynurenine system (KYN) that is dominantly described in studies about immunopathogenesis of depression provides the subtlest relation between depression, distress and immunity [1], [4].

Metabolic product of KYN system are neurotoxic kynurenic acid which damages certain brain regions of depressive patients, on the one hand, and leads to the decrease of neurotransmitter level, on the other [5]. Finally, it is considered that patients with activated immune system are prone to weaker reaction to standard antidepressant therapy, and there is a hypothesis that this kind of patients would better react on therapy with antidepressants, along with the augmentation with immunosuppressive agents, that are expected to stable inflammation factors in non-responders to treatment [6]. On the other hand, it has been shown that antidepressants may inhibit the production and function of peripheral brain cytokines. They may decrease the level of pro-inflammatory cytokines, with the increase of anti-inflammatory cytokine levels which also contribute to depressive symptoms reduction [7].

## **Role of anti-inflammatory agents as antidepressants**

New possibilities in depression treatment are the target pathways by which the immune system influences the brain, such as cytokines or growth factors, as well as the activation of relevant brain immune cells, like microglial cells. Monocytes and microglial cells may be returned on a basic level of functioning by application of immunosuppressive medications, including non-steroidal anti-inflammatory agents, like Minocycline and N-acetylcysteine. Unfortunately, these agents are not investigated in psychiatric disorders quite enough, along with their potential for further and new immunosuppressive interventions. N-acetylcysteine, Minocycline and other non-steroidal anti-inflammatory agents are aggressively tested on animal models, aiming to get an estimation of their impact on behavioural abnormalities [6]. Immunosuppressive agents that are currently in the focus of interest are cytokine antagonists, most of all TNF and IL-6, non-steroidal anti-inflammatory agents, as well as certain immunomodulation agents. Also, it is determined that the inhibition of IDO and KYN pathways leads to the suppression of cytokine effects on the glutaminergic system, thus on behaviour disturbances in depression [2], [8]. The agents affecting hypothalamic-pituitary-adrenal (HPA) axis, glucocorticoid receptors (GRs), and post-receptor signal pathways are considered as possible therapeutic possibilities, with the potential to correct the dysregulation of this endocrine axis in depressive disorder. The medications classified as anti-glucocorticoids (GR antagonists, GR agonists, dehydroepiandrosterone – DEHA, the inhibitors of steroid synthesis) have potential abilities to stabilise the inflammation associated with the activity of glucocorticoids that may have the role in brain damage in depressive patients. The studies supporting this concept of development of the potential antidepressant therapy are still in the beginning phase [6]. The agglomeration of evidence on immunological distortions plays the crucial role in further discovering of still insufficiently defined aetiology of depressive disorder, along with distinguishing single groups of patients who share immunologic, genetic and brain alterations, and also an individual response to antidepressant treatment [9]. The side effects of anti-inflammatory medications must be beard in mind, primarily severe infections due to induced immunosuppression [10].

## **Cytokine inhibitors**

If it is supposed that cytokines are involved in depression development, then cytokine-like

antidepressants (e.g. receptors antagonists which can regulate pro-inflammatory cytokines and anti-cytokine antibodies) may improve depressive symptoms. Cytokine antagonists that are wide-spectrum anti-inflammatory cytokines, such as IL-4 and IL-10 may be more effective than cytokine antagonists which inhibit specific cytokines in depressive treatment. TNF antagonists, like Adalimumab, Etanercept and Infliximab have been used as therapeutic agents in the treatment of autoimmune diseases, such as rheumatoid arthritis, and are currently used in clinical trials in the treatment of depressive episodes of bipolar disorder [7]. Already mentioned Adalimumab, Infliximab, as well as Golimumab, are monoclonal antibodies, unlike Etanercept, which is circulating TNF receptor fusion protein. These agents have shown their potential antidepressant effects, first on animal models, and in patients with chronic inflammatory diseases, like Chron's disease, ankylosing spondylitis, along with accompanying depressive symptoms [11]. It is determined that anti-TNF therapy, like Etanercept, which is administered in patients who have psoriasis, has a potential adjuvant effect in combination with certain antidepressants [6], [10]. It is supposed that the antidepressant effect of Etanercept is a consequence of potentiation of serotonergic and noradrenergic neurotransmission, as well as of normalisation of stress hormone secretion.

Chronic therapy with Infliximab prevents the decreasing of brain neurotrophic factor (BDNF) in the hippocampus. It has been shown that chimeric monoclonal antibody Infliximab has a potential antidepressant effect in patients suffering from depression and resistant to treatment, but only in those with increased values of inflammatory factors, like CRP and TNF, in the way of preventing the binding of TNF to its surface cell receptors [1], [10]. Anti-TNF therapy affect serotonin transporters, so it may influence the efficacy of Fluoxetine, as it is described in certain researches. It is unclear if anti-TNF therapy has the effects of noradrenergic transporters. Also, it influences the increased production of BDNF, as well as the expression of the  $\alpha$ -amino-3-hydroxy-5-methyl-4-isoxazole acid receptor (AMPA), which is the effect of Fluoxetine itself. Changes in glutamate transmission are shown to be significant in response to antidepressant treatment [11]. The researches did so far propose the hypothesis that TNF represents the regulating factor of the apoptotic cascade that can be associated with neural and glial loss in bipolar disorder [7]. In a depressive episode of bipolar disorder, TNF levels are considered as trait markers of this disorder, and TNF modulation could be the target of antidepressant therapy [3]. In some studies, the link between anti-inflammatory cytokines and therapy resistance has been found [11]. It has been shown that in a group of therapy-resistant depressive patients those with higher pro-inflammatory cytokine levels better react to the cytokine antagonists, compared to placebo. This further contributes to the significance of better

distinction of biological markers which condition the individual response to therapy and personalised treatment. Also, it should be emphasised that the TNF antagonism concept shouldn't be generalised to all therapy-resistant patients [12].

Due to the heterogeneity of depressive aetiology and its complex nature, TNF level is increased in certain patients, and decreased in others, while it remains unchanged in some of them, even after pharmacological treatment [11]. Targeting of IL-6 pro-inflammatory cytokine with human monoclonal antibody Sirukumab may be the potential therapeutic approach in depressive patients. Sirukumab is the safe and tolerable agent, capable of modifying the immune response in a healthy population, as well as in patients with inflammatory diseases, such as rheumatoid arthritis. This monoclonal antibody may represent the prototype of an agent which proves that targeting and modifying pro-inflammatory cytokines, like IL-6, can considerably affect the pathogenesis and therapeutic outcome of mental disorders, primarily depressive disorder [13].

## Non-steroidal anti-inflammatory drugs

Non-steroidal anti-inflammatory drugs, as it is already mentioned, maybe potentially used as an adjuvant option in depression treatment, together with antidepressants. First of all, it is meant to the mechanism of cyclooxygenase-2 (COX-2) and cyclooxygenase-1 (COX-1) blocking, as well as to the reduction of oxidative stress, preventing of pro-inflammatory cytokines increasing, and thus increasing of serotonin and other brain neurotransmitters. Findings from animal and human trials have shown certain contradictories, meaning that certain studies have found the adjuvant effect of acetylsalicylate acid (ASA) and COX-2 selective inhibitor Celecoxib, mostly in combination with SSRIs [14]. In animal (rats) model, Rofecoxib – COX-2 inhibitor increases the level of serotonin in the frontal and tempo-parietal cortex, which may have an antidepressant effect. In a randomized, double-blind trial with antidepressants Reboxetine and Celecoxib, it has been shown that Celecoxib has a positive antidepressant effect, and similar results have been obtained from the studies investigating the combination of Celecoxib and Sertraline, as well as Celecoxib and Fluoxetine [1], [15]. Namely, recent studies showed that Celecoxib, as adjuvant agent together with Sertraline, more significantly improved mood disturbances in depressive patients. Compared to the nanotherapeutic approach with antidepressant, this is considered to be the consequence of IL-6 pro-inflammatory cytokine decreasing [10]. Certain animal models showed that the combination of antidepressant Bupropion and Celecoxib might be

potentially beneficial for the strategy of depressive treatment in patients with some chronic disease. It has been demonstrated that Celecoxib decreases IL-1 pro-inflammatory cytokine level, without any effect on BDNF decreasing [16].

One study on rat model investigated the influence of 3 different antidepressants (Citalopram, Sertraline and Paroxetine) and 2 NSAIDs (Ibuprofen and Indometacin) on BDNF and nerve trophic factor (NGF) releasing, that was dose-dependent, and also depended on drug combination and probably on incubation period [17]. There are certain investigations which support the hypothesis that Aspirin that is ASA may be potential antidepressant therapy, both individually and as adjuvant. Decreasing of inflammatory mediators during stressful procedures, or in any potential physiological or biochemical mechanism, may represent the possible antidepressant effect of Aspirin [18]. Some other investigations have shown that NSAIDs in general, as well as Paracetamol, inhibit the antidepressant effect of Citalopram (both in animal and human trials), unlike ASA and COX-2 inhibitors. This discrepancy is a result of different effects of NSAIDs, COX-2 inhibitors, and salicylates both on antidepressant effect. Also, increased risk of gastrointestinal bleeding and certain cardiovascular diseases should be considered during the chronic use of these medications, especially because these issues haven't been considered in earlier studies investigating the potential adjuvant effect of these drugs in depression treatment [19]. Current investigations neither support nor discourage the use of NSAIDs and Paracetamol together with antidepressant therapy, because conclusion about their favourable or unfavourable effect cannot be brought.

Further detailed investigations are necessary to make a distinction which NSAIDs is the safest, and the most potent at the same time, in terms of adjuvant therapy of depression [15].

## The other anti-inflammatory drugs and potential antidepressant agents

It has been shown that the expression of Toll-like receptors (TLRs) is associated with therapeutic outcome in depressive patients that indicates the relationship between inflammation, depression and therapy. Future studies on animal models will show the possible antidepressant effect of TLR antagonists [20], [21]. Antiglucocorticoid agents, including Ketoconazole and Metyrapone, are tested to antidepressant effects, but significant achievements have not been observed due to side effects and insufficiently known clinical potential of Metyrapone. Dexamethasone and Hydrocortisone may also be

shortly useful for certain depressive symptoms. Glutamate antagonists targeting with Ketamine that is N-methyl-d-aspartate receptor (NMDA) may be possibly efficient for depression therapy. Omega-3 polyunsaturated fatty acids affect the metabolic and inflammatory activity and show certain benefits in depressive symptoms reduction. It has been demonstrated that the antidepressant effect may be mediated by statins through certain neurobiological pathways [22]. Statins are agents primarily used to decrease lipid level in peripheral blood, but also show anti-inflammatory effects. In the context of the inflammatory hypothesis of depression, certain studies have found that depressive patients who had been using statins, along with SSRIs, had had more stable remission with the rarer occurrence of relapses, compared to those who had been on monotherapy with antidepressant [1]. It is interesting to say that a high level of homocysteine in serum is also associated with the risk of cardiovascular diseases and depression. B vitamin consumption (B6, B9 and B12) decreases homocysteine level by 15%, and it is also meant that antithrombotic therapy, namely Aspirin, decreases homocysteine level. That's why in older people who use Aspirin regularly in their therapy and who have higher homocysteine level, the occurrence of depression is uncommon. However, further randomised trials are necessary to confirm this Aspirin feature in people with an increased level of homocysteine [23].

Animal model of stress-induced depression that was presented with behavioural and biochemical alteration of the already mentioned KYN pathway has shown the antidepressant effect of IDO inhibitor (1-methyl-D-tryptophane) that is very similar to antidepressant Fluoxetine. It has been observed that 1-methyl-D-tryptophane and Fluoxetine decrease the level of pro-inflammatory cytokines in this animal model, so the antidepressant effect is achieved through an anti-inflammatory effect [24].

Curcumin is diarylheptanoid and polyphenol component of *Curcuma longa* which has therapeutic and nutritive characteristics. Namely, it is shown that curcumin stimulates BDNF and inhibits COX-2 on animal (rat) models exposed to chronic distress, so in that terms has neuroprotective, possible antidepressant effects, as well as the effect on neuroplasticity [25].

## Immunomodulating effect of antidepressants

Biochemical effect of antidepressants has been used because of their clinical benefits in certain medical disciplines, especially gastroenterology, neurology, and for some non-specific disease

symptoms. Anti-inflammatory effect of antidepressants may be the reason for the wide indications of their use [22]. There is certain evidence that antidepressants may have immunomodulation performances in animal models of depression.

For example, SSRI Escitalopram and Paroxetine are the agents which decrease pro-inflammatory markers (TNF, IL-1, IL-6 and PGE-2), besides the reduction of depressive symptoms. On the other hand, in certain animal models, it has been shown that Citalopram increases the level of central pro-inflammatory cytokines, like TNF and INF- $\gamma$ . These may be explained by the fact that immune cells have neurotransmitter receptors, so antidepressants affect these receptors and regulate the immune activity. T lymphocytes have 5-hydroxytryptamine (5-HT) receptors (5-HT<sub>1A</sub> and 5-HT<sub>2A / 2C</sub>) on their surface. Macrophages express 5-HT system of reuptake that is similar to the one of serotonin's reuptake of thrombocytes. Also, antidepressants regulate cytokine-induced GR of resistance, by which they normalise HPA axis function in depression. They inhibit nitrogen-oxide and PGE<sub>2</sub> production which is increased by cytokine effects and inhibit IDO activity as well. They affect macrophages and lymphocytes directly, inducing them to produce anti-inflammatory cytokines [7], [26]. Also, it was shown that SSRIs (Citalopram) performed down-regulation of CD4 receptor expression, as well as chemokines receptors (CCR5, CXR4), in patients infected with human immunodeficiency virus (HIV), and that is the manner of inhibition of the virus' entrance in cells and its replication. So, it could be told that SSRIs may have an adjuvant medication role in immune restitution of patients infected with HIV and suffering or not of depression [27].

There are some indications that SSRIs stimulate B lymphocytes proliferation in depressive patients, so they affect innate immunity. The studies investigating the effect of serotonin and noradrenaline reuptake inhibitors (SNRIs) on the immune system, both innate and acquired, are scarce. It seems they have anti-inflammatory effects, and that may be dose-dependent. The effects on the immune system depend on if patients are early responders, or don't respond to the therapy with SNRIs. It was found that they affected certain lymphocytic gene expression, so they influence migration, remodelling of cytoskeleton, and activation of lymphocytes. There is a small number of studies which estimate Venlafaxine and Duloxetine influence on inflammation markers. The fact is that they influence the levels of Th1 and Th2 type of cytokines [28]. The theory is that SSRIs target Th2 shift during the inflammation, while SNRIs affect Th1 shift [22]. Certain researches show more potent effects of SSRIs compared to SNRIs. When it is about tricyclic antidepressants, there are also a few studies investigating their influence on innate and acquired immunity, but it is generally accepted that they have anti-inflammatory effects, especially by decreasing the

efficacy of acquired immunity, that is T lymphocytes. The small number of studies is about the influence of antidepressants on chemokines and represents the field that is necessary to investigate further. Until now, there has been only one study investigating the effects of antidepressants on cytokines in cerebrospinal fluid (CSF). It is necessary to include more recent antidepressants in further studies, like Agomelatine, serotonin and melatonin active agent, because it is believed that it has anti-inflammatory effects [28]. Few studies are investigating the immunomodulation effect of SSRIs, SNRIs and monoamine oxidase inhibitors (MAOIs) [29]. It is suggested that decreased level of cytokines after antidepressant treatment may be connected to the increase of T regulatory cells number. Also, the immunomodulation effect of electroconvulsive therapy (ECT) has been shown in certain studies [10].

## Conclusion

The treatment of psychiatric disorders is high economic burden nowadays, even though the investments in the researches on alterations in molecular brain nets represent the platform for new therapeutic strategies, which is one of the greatest pharmacological and research challenges in XXI century.

So, what can be concluded until now with great caution, is that anti-inflammatory therapy can potentially be adjuvant treatment together with antidepressants, on the one hand, while antidepressants on the other, especially those of new generation, show inhibitory effects on immune processes. Finally, the interaction between neurotransmitters and innate and acquired immunity should be thoroughly investigated. At this moment, it is very hard to bring out definite conclusions, because there are still not enough evidence and researches which could confirm the clear and undoubted role of immune mechanisms in the pathogenesis of depression, and consequently the influence of anti-inflammatory drugs on its therapy. Further studies should define methods which would single out the components of the immune system in different neuroanatomic regions. More specifically, their role is to complete the palette of biomarkers which would enable a personalized approach to every single patient and deal with dilemmas referring to resistance to medications. Neurobiological and neuroimmunology studies done so far only partly explained complex pathophysiology of depressive disorder, so numerous proposed therapeutic interventions are still in conceptual and preclinical stages.

It is very important to emphasise that those immunomodulation drugs for which there are significant indications of clinical benefits should pass

the phase of more thorough testing on tolerability, efficacy, and safety, so after that, their implementation into therapeutic protocols for depression treatment can be considered.

## References

- Müller N. Immunological aspects of the treatment of depression and schizophrenia. *Dialogues in Clinical Neuroscience*. 2017; 19(1):55-63.
- Felger JC, Lotrich FE. Inflammatory cytokines in depression: neurobiological mechanisms and therapeutic implications. *Neuroscience*. 2013; 246:199-229. <https://doi.org/10.1016/j.neuroscience.2013.04.060>
- M Schmidt F, C Kirkby K, Lichtblau N. Inflammation and immune regulation as potential drug targets in antidepressant treatment. *Current neuropharmacology*. 2016; 14(7):674-87. <https://doi.org/10.2174/1570159X14666160115130414>
- Vogelzangs N, Duivis HE, Beekman AT, Kluff C, Neuteboom J, Hoogendijk W, Smit JH, de Jonge P, Penninx BW. Association of depressive disorders, depression characteristics and antidepressant medication with inflammation. *Translational psychiatry*. 2012; 2(2):e79. <https://doi.org/10.1038/tp.2012.8>
- Müller N. The role of anti-inflammatory treatment in psychiatric disorders. *Psychiatria Danubina*. 2013; 25(3):292-298.
- Hughes MM, Connor TJ, Harkin A. Stress-related immune markers in depression: implications for treatment. *International Journal of Neuropsychopharmacology*. 2016; 19(6):1-19. <https://doi.org/10.1093/ijnp/pyw001>
- Jeon SW, Kim YK. Neuroinflammation and cytokine abnormality in major depression: cause or consequence in that illness? *World journal of psychiatry*. 2016; 6(3):283-293. <https://doi.org/10.5498/wjp.v6.i3.283>
- Capuron L, Miller AH. Immune system to brain signaling: neuropsychopharmacological implications. *Pharmacology & therapeutics*. 2011; 130(2):226-38. <https://doi.org/10.1016/j.pharmthera.2011.01.014>
- Leboyer M, Berk M, Yolken RH, Tamouza R, Kupfer D, Groc L. Immuno-psychiatry: an agenda for clinical practice and innovative research. *BMC medicine*. 2016; 14(1):173. <https://doi.org/10.1186/s12916-016-0712-5>
- Gibney SM, Drexhage HA. Evidence for a dysregulated immune system in the etiology of psychiatric disorders. *Journal of Neuroimmune Pharmacology*. 2013; 8(4):900-20. <https://doi.org/10.1007/s11481-013-9462-8>
- Ma K, Zhang H, Baloch Z. Pathogenetic and therapeutic applications of tumor necrosis factor- $\alpha$  (TNF- $\alpha$ ) in major depressive disorder: a systematic review. *International journal of molecular sciences*. 2016; 17(5):733. <https://doi.org/10.3390/ijms17050733>
- Raison CL, Rutherford RE, Woolwine BJ, Shuo C, Schettler P, Drake DF, Haroon E, Miller AH. A randomized controlled trial of the tumor necrosis factor antagonist infliximab for treatment-resistant depression: the role of baseline inflammatory biomarkers. *JAMA psychiatry*. 2013; 70(1):31-41. <https://doi.org/10.1001/2013.jamapsychiatry.4>
- Zhou AJ, Lee Y, Salvatore G, Hsu B, Fonseka TM, Kennedy SH, McIntyre RS. Sirukumab: a potential treatment for mood disorders? *Advances in therapy*. 2017; 34(1):78-90. <https://doi.org/10.1007/s12325-016-0455-x>
- Köhler O, Petersen L, Mors O, Gasse C. Inflammation and depression: combined use of selective serotonin reuptake inhibitors and NSAIDs or paracetamol and psychiatric outcomes. *Brain and behavior*. 2015; 5(8):e00338. <https://doi.org/10.1002/brb3.338>
- McNamara RK, Lotrich FE. Elevated immune-inflammatory signaling in mood disorders: a new therapeutic target? Expert review of neurotherapeutics. 2012; 12(9):1143-61. <https://doi.org/10.1586/ern.12.98>
- Maciel IS, Silva RB, Morrone FB, Calixto JB, Campos MM. Synergistic effects of celecoxib and bupropion in a model of chronic inflammation-related depression in mice. *PLoS One*. 2013; 8(9):e77227. <https://doi.org/10.1371/journal.pone.0077227>
- Hochstrasser T, Ehrlich D, Sperner-Unterweger B, Humpel C. Antidepressants and Anti-Inflammatory Drugs Differentially Reduce the Release of NGF and BDNF from Rat Platelets. *Pharmacopsychiatry*. 2013; 46(1):29-34. <https://doi.org/10.1055/s-0032-1314843>
- Bhatt S, Shukla P, Raval J, Goswami S. Role of aspirin and dexamethasone against experimentally induced depression in rats. *Basic & clinical pharmacology & toxicology*. 2016; 119(1):10-8. <https://doi.org/10.1111/bcpt.12539>
- Andrade C. Antidepressant augmentation with anti-inflammatory agents. *The Journal of clinical psychiatry*. 2014; 75(9):975-7. <https://doi.org/10.4088/JCP.14f09432>
- Hung YY, Huang KW, Kang HY, Huang GY, Huang TL. Antidepressants normalize elevated Toll-like receptor profile in major depressive disorder. *Psychopharmacology*. 2016; 233(9):1707-14. <https://doi.org/10.1007/s00213-015-4087-7>
- Hung YY, Lin CC, Kang HY, Huang TL. TNFAIP3, a negative regulator of the TLR signaling pathway, is a potential predictive biomarker of response to antidepressant treatment in major depressive disorder. *Brain, behavior, and immunity*. 2017; 59:265-72. <https://doi.org/10.1016/j.bbi.2016.09.014>
- Strawbridge R, Young AH, Cleare AJ. Biomarkers for depression: recent insights, current challenges and future prospects. *Neuropsychiatric disease and treatment*. 2017; 13:1245-1262. <https://doi.org/10.2147/NDT.S114542>
- Almeida OP, Flicker L, Yeap BB, Alfonso H, Mccaul K, Hankey GJ. Aspirin decreases the risk of depression in older men with high plasma homocysteine. *Translational psychiatry*. 2012; 2(8):e151. <https://doi.org/10.1038/tp.2012.79>
- Laugeray A, Launay JM, Callebert J, Mutlu O, Guillemin GJ, Belzung C, Barone PR. Chronic treatment with the IDO1 inhibitor 1-Methyl-D-Tryptophan minimizes the behavioural and biochemical abnormalities induced by unpredictable chronic mild stress in mice-comparison with fluoxetine. *PLOS one*. 2016; 11(11):e0164337. <https://doi.org/10.1371/journal.pone.0164337>
- Choi GY, Kim HB, Hwang ES, Lee S, Kim MJ, Choi JY, Lee SO, Kim SS, Park JH. Curcumin alters neural plasticity and viability of intact hippocampal circuits and attenuates behavioral despair and COX-2 expression in chronically stressed rats. *Mediators of inflammation*. 2017; 2017. <https://doi.org/10.1155/2017/6280925>
- Raison CL, Capuron L, Miller AH. Cytokines sing the blues: inflammation and the pathogenesis of depression. *Trends in immunology*. 2006; 27(1):24-31. <https://doi.org/10.1016/j.it.2005.11.006>
- Greeson JM, Gettes DR, Spitsin S, Dubé B, Benton TD, Lynch KG, Douglas SD, Evans DL. The Selective Serotonin Reuptake Inhibitor Citalopram Decreases HIV Receptor and Coreceptor Expression in Immune Cells. *Biological psychiatry*. 2016; 80(1):33-39. <https://doi.org/10.1016/j.biopsych.2015.11.003>
- Eyre HA, Lavretsky H, Kartika J, Qassim A, Baune BT. Modulatory effects of antidepressant classes on the innate and adaptive immune system in depression. *Pharmacopsychiatry*. 2016; 26(03):85-96. <https://doi.org/10.1055/s-0042-103159>
- Horowitz MA, Wertz J, Zhu D, Cattaneo A, Musaelyan K, Nikkheslat N, Thuret S, Pariante CM, Zunszain PA. Antidepressant compounds can be both pro- and anti-inflammatory in human hippocampal cells. *International Journal of Neuropsychopharmacology*. 2015; 18(3):pyu076. <https://doi.org/10.1093/ijnp/pyu076>

# Successful Treatment of a Widespread Pemphigus Chronicus Familiaris (Hailey-Hailey) By Erbium-YAG-Laser

Uwe Wollina<sup>1\*</sup>, Gesina Hansel<sup>1</sup>, Torello Lotti<sup>2</sup>, Aleksandra Vojvodic<sup>3</sup>

<sup>1</sup>Department of Dermatology and Allergology, Städtisches Klinikum Dresden, Academic Teaching Hospital, Dresden, Germany; <sup>2</sup>Department of Dermatology, University of Rome "G. Marconi", Rome, Italy; <sup>3</sup>Military Medical Academy of Belgrade, Belgrade, Serbia

## Abstract

**Citation:** Wollina U, Hansel G, Lotti T, Vojvodic A. Successful Treatment of a Widespread Pemphigus Chronicus Familiaris (Hailey-Hailey) By Erbium-YAG-Laser. Open Access Maced J Med Sci. 2019 Sep 30; 7(18):3070-3072.  
<https://doi.org/10.3889/oamjms.2019.764>

**Keywords:** Pemphigus; Pemphigus chronic familiaris; Acantholytic dermatoses; Retinoids; Erbium-YAG-laser; Treatment

**\*Correspondence:** Uwe Wollina, Department of Dermatology and Allergology, Städtisches Klinikum Dresden, Academic Teaching Hospital, Dresden, Germany. E-mail: [uwollina@gmail.com](mailto:uwollina@gmail.com)

**Received:** 05-Apr-2019; **Revised:** 04-Jul-2019; **Accepted:** 05-Jul-2019; **Online first:** 30-Aug-2019

**Copyright:** © 2019 Uwe Wollina, Gesina Hansel, Torello Lotti, Aleksandra Vojvodic. This is an open-access article distributed under the terms of the Creative Commons Attribution-NonCommercial 4.0 International License (CC BY-NC 4.0)

**Funding:** This research did not receive any financial support

**Competing Interests:** The authors have declared that no competing interests exist

**BACKGROUND:** Familial chronic pemphigus or Hailey-Hailey disease (OMIM 169600) is a rare, autosomal dominant blistering skin disorder the genetic background are mutations of the *ATP2 C1* gene. The treatment is challenging.

**CASE REPORT:** A 48-year-old Caucasian female patient presented to the department with a relapse of her Pemphigus chronicus familiaris (Hailey-Hailey). No other medical diseases were known. On examination, we observed an otherwise healthy woman with widespread erosive lesions on the neck, axillae, groins, submammary fold and anal fold. She reported burning sensations and an unpleasant odour. The diagnosis had been confirmed earlier by histopathology of a skin biopsy with acantholysis, and the relapsing and remitting course. Family history was positive for father and brother. Since she had not responded well in the past to systemic retinoids and did not tolerate the adverse effects of these drugs, we suggested an ablative erbium-YAG laser treatment in general anaesthesia. Laser treatment was performed with the MCL 29 Dermablade (Asclepion Laser Technologies, Jena, Germany) on two occasions. We used a 5 mm focus, pulse energy of 1200 mJ at 8 Hz. The resulting superficial wounds were treated with an ointment containing fusidic acid 0.2% and betamethasone 0.1%. Wound healing was completed after 12 days. No adverse events were observed.

**CONCLUSIONS:** Ablative erbium-YAG therapy is an option for pemphigus chronicus familiaris, in particular in young women and patients who do not tolerate the adverse effects of retinoid therapy.

## Introduction

Familial chronic pemphigus or Hailey-Hailey disease (OMIM 169600) is a rare blistering skin disorder that affects both sexes equally. It affects the skin folds predominantly. The inheritance is autosomal dominant. The genetic background is mutations of the *ATP2 C1* gene encoding for calcium transporter protein secretory pathway calcium ATPase SPCA1a in the Golgi apparatus [1].

These mutations are responsible for abnormal high cytosolic calcium and magnesium concentration. Since there is a functional coupling of SPCA1a and Orai1, the store-independent calcium entry becomes also affected [2].

The genetic findings translate into altered protein expression for focal adhesion, extracellular matrix receptors, protein digestion and absorption, and PI3K-Akt signalling leading to acantholysis and disturbed epidermal barrier function [3].

The disease causes a significant reduction in patients' quality of life by itching and burning sensations, oozing, superinfections and unpleasant odour. The course is chronic with frequent relapses and rarely longer remissions [4]. Topical treatment alone is most often not successful in improving the disease. Therefore, many other different treatments have been reported in low numbers of patients. Acitretin 25 mg/day, etretinate (up to 0.5 mg per kg of body weight/day), alitretinoin (30 mg/day) oral steroids (variable dosages), dapsone (100-150 mg/d),

methotrexate (15 mg/week), cyclosporine 0.2 mg/kg body weight/day, glycopyrrolate (1 mg/day), afamelanotide (16 mg subcutaneously on day 0 and day 30), thalidomide (2 x 100 mg/day), nalotrexone (4.5 mg nightly/day), apremilast (3 x 60 mg/day), oral vitamin D, botulinum toxin A injections, electron beam radiation, photodynamic therapy or dermabrasion [5], [6], [7].

Another option is ablative laser therapy. Side effects are minimal, and costs are lower compared to many systemic drugs. We report on erbium-doped yttrium aluminium garnet (erbium-YAG) laser therapy of familial chronic pemphigus.

## Case report

A 48-year-old Caucasian female patient presented to the department with a relapse of her Pemphigus chronicus familiaris (Hailey-Hailey). No other medical diseases were known.

Previously, she had a topical corticosteroid ointment with only limited success. On examination, we observed an otherwise healthy woman with widespread erosive lesions on the neck, axillae, groins, submammary fold and anal fold. She reported burning sensations and an unpleasant odour.

The diagnosis had been confirmed earlier by histopathology of a skin biopsy with suprabasilar acantholysis, eccrine acantholysis, and dyskeratosis. There was an upper dermal infiltrate of neutrophils. The course was relapsing and remitting. Autoantibodies characteristic of autoimmune blistering disorders remained negative. Family history was positive for father and brother. Lesions remained restricted to frictional areas.

Since she had not responded well in the past to systemic retinoids and did not tolerate the adverse effects of these drugs, we looked for an alternative. Ablative erbium-YAG laser treatment was suggested, and a small area on the armpits was treated on a trial base. The effect was very good, and the healing was fast and uneventful. Therefore, we suggested the treatment of larger areas by erbium-YAG laser in general anaesthesia. Laser treatment was performed with the MCL 29 Dermablade (Asclepion Laser Technologies, Jena, Germany) on two occasions. We used a 5 mm focus, pulse energy of 1200 mJ at 8 Hz. The resulting superficial wounds were treated with an ointment containing fusidic acid 0.2% and betamethasone 0.1% (Fucicortcreme®, Leo Pharmaceutical Products Ltd. A/S). Wound healing was completed after 12 days (Figure 1). No adverse events were observed.

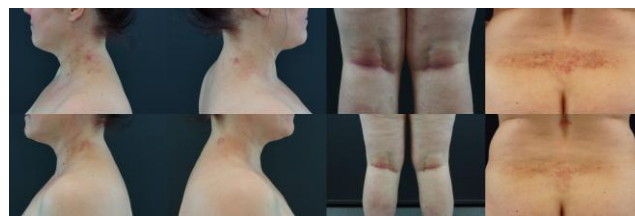

Figure 1: Morbus Hailey-Hailey. Upper row: Before treatment; Lower Row: Seven days after ablative laser therapy

## Discussion

Familial chronic pemphigus resistant to conventional therapy may be treated by laser ablation. In the past, the only “curative” therapy of the disease was excision of lesional skin followed by split-thickness. The success of surgery is attributed to the removal of affected epidermal structures and a decrease in sweating and maceration. Laser therapy offers a less invasive treatment without the need for grafting on treated areas and has a tradition since 1987 [8]. Reepithelization occurs by hair follicle keratinocytes.

In the case of CO<sub>2</sub> laser, 5 to 25 W with continuous mode, defocused or pulsed long-term improvement or remission have been obtained in the majority of patients. However, pain, scarring and pigmentary changes are possible adverse effects [9]. Alexandrite laser (12-20 J/cm<sup>2</sup>) has been employed with up to 13 treatment sessions. Hyperpigmentation is a possible adverse event [10].

The erbium-YAG laser is a solid-state crystal laser. The laser light of 2,940 nm is strongly absorbed by water. This prevents the laser cutting of skin and extensive scarring [11]. Partial to complete remission have been reported after erbium-YAG laser treatment during a follow-up of 8 to 12 months [12], [13]. This has been confirmed by the present investigation in a patient with widespread disease. Laser therapy should be considered in such cases. To improve tolerability in case of larger areas to be treated, general anaesthesia is recommended, while small areas can be treated under local anaesthesia.

The affected epidermis becomes substituted by keratinocytes from hair shafts leading to a re-epithelialization of the superficial wounds. SPCA1 has not been identified in hair shaft keratinocytes.

## References

1. Hu Z, Bonifas JM, Beech J, Bench G, Shigihara T, Ogawa H, Ikeda S, Mauro T, Epstein EH Jr. Mutations in ATP2C1, encoding a calcium pump, cause Hailey-Hailey disease. *Nat Genet.* 2000;

- 24(1):61-5. <https://doi.org/10.1038/71701> PMID:10615129
2. Smaardijk S, Chen J, Kerselaers S, Voets T, Eggermont J, Vangheluwe P. Store-independent coupling between the Secretory Pathway Ca<sup>2+</sup> transport ATPase SPCA1 and Orai1 in Golgi stress and Hailey-Hailey disease. *Biochim Biophys Acta Mol Cell Res*. 2018; 1865(6):855-862. <https://doi.org/10.1016/j.bbamcr.2018.03.007> PMID:29555205
3. Zhang D, Huo J, Li R, Zhang Y, Wang Z, Li X. Altered levels of focal adhesion and extracellular matrix-receptor interacting proteins were identified in Hailey-Hailey disease by quantitative iTRAQ proteome analysis. *J Cell Biochem*. 2019; 120(3):3801-3812. <https://doi.org/10.1002/jcb.27662> PMID:30506709
4. Engin B, Kutlubay Z, Çelik U, Serdaroğlu S, Tüzün Y. Hailey-Hailey disease: A fold (intertriginous) dermatosis. *Clin Dermatol*. 2015; 33(4):452-5. <https://doi.org/10.1016/j.clindermatol.2015.04.006> PMID:26051060
5. Farahnik B, Blattner CM, Mortazie MB, Perry BM, Lear W, Elston DM. Interventional treatments for Hailey-Hailey disease. *J Am Acad Dermatol*. 2017; 76(3):551-558.e3. <https://doi.org/10.1016/j.jaad.2016.08.039> PMID:27745906
6. Albers LN, Arbiser JL, Feldman RJ. Treatment of Hailey-Hailey Disease With Low-Dose Naltrexone. *JAMA Dermatol*. 2017; 153(10):1018-1020. <https://doi.org/10.1001/jamadermatol.2017.2446> PMID:28768313 PMCid:PMC5817589
7. Kieffer J, Le Duff F, Montaudié H, Chiaverini C, Lacour JP, Passeron T. Treatment of Severe Hailey-Hailey Disease With Apremilast. *JAMA Dermatol*. 2018; 154(12):1453-1456. <https://doi.org/10.1001/jamadermatol.2018.2191> PMID:30304341 PMCid:PMC6583319
8. Don PC, Carney PS, Lynch WS, Zaim MT, Hassan MO. Carbon dioxide laserabrasion: a new approach to management of familial benign chronic pemphigus (Hailey-Hailey disease). *J Dermatol Surg Oncol*. 1987; 13(11):1187-94. <https://doi.org/10.1111/j.1524-4725.1987.tb02430.x> PMID:3117856
9. Falto-Aizpurua LA, Griffith RD, Yazdani Abyaneh MA, Nouri K. Laser therapy for the treatment of Hailey-Hailey disease: a systematic review with focus on carbon dioxide laser resurfacing. *J Eur Acad Dermatol Venereol*. 2015; 29(6):1045-52. <https://doi.org/10.1111/jdv.12875> PMID:25418614
10. Awadalla F, Rosenbach A. Effective treatment of Hailey-Hailey disease with a long-pulsed (5 ms) alexandrite laser. *J Cosmet Laser Ther*. 2011; 13(4):191-2. <https://doi.org/10.3109/14764172.2011.594062> PMID:21692642
11. Wollina U. Erbium-YAG laser therapy - analysis of more than 1,200 treatments. *Glob Dermatol* 2016; 3(1):268-272. <https://doi.org/10.15761/GOD.1000171>
12. Beier C, Kaufmann R. Efficacy of erbium:YAG laser ablation in Darier disease and Hailey-Hailey disease. *Arch Dermatol*. 1999; 135(4):423-7. <https://doi.org/10.1001/archderm.135.4.423> PMID:10206049
13. Konrad H, Karamfilov T, Wollina U. Intracutaneous botulinum toxin A versus ablative therapy of Hailey-Hailey disease--a case report. *J Cosmet Laser Ther*. 2001; 3(4):181-4. <https://doi.org/10.1080/14764170160260762> PMID:12554326



# A Black Hole at the Center of Earth Plays the Role of the Biggest System of Telecommunication for Connecting DNAs, Dark DNAs and Molecules of Water on 4+N- Dimensional Manifold

Massimo Fioranelli<sup>1\*</sup>, Alireza Sepehri<sup>1</sup>, Maria Grazia Roccia<sup>1</sup>, Cota Linda<sup>1</sup>, Chiara Rossi<sup>1</sup>, Petar Vojvodic<sup>2</sup>, Jacopo Lotti<sup>1</sup>, Victoria Barygina<sup>3</sup>, Aleksandra Vojvodic<sup>4</sup>, Uwe Wollina<sup>5</sup>, Michael Tirant<sup>6</sup>, Nguyen Van Thuong<sup>7</sup>, Torello Lotti<sup>8</sup>

<sup>1</sup>Department of Nuclear Physics, Sub-nuclear and Radiation, G. Marconi University, Rome, Italy; <sup>2</sup>Clinic for Psychiatric Disorders "Dr. Laza Lazarevic", Belgrade, Serbia; <sup>3</sup>Department of Biomedical Experimental and Clinical Sciences, University of Florence, Florence, Italy; <sup>4</sup>Department of Dermatology and Venereology, Military Medical Academy, Belgrade, Serbia; <sup>5</sup>Department of Dermatology and Allergology, Städtisches Klinikum Dresden, Dresden, Germany; <sup>6</sup>G. Marconi University, Rome, Italy; <sup>7</sup>Vietnam National Hospital of Dermatology and Venereology, Hanoi, Vietnam; <sup>8</sup>Department of Dermatology, University of G. Marconi, Rome, Italy

**Citation:** Fioranelli M, Sepehri A, Roccia MG, Linda C, Rossi C, Vojvodic P, Lotti J, Barygina V, Vojvodic A, Wollina U, Tirant M, Van Thuong N, Lotti T. A Black Hole at the Center of Earth Plays the Role of the Biggest System of Telecommunication for Connecting DNAs, Dark DNAs and Molecules of Water on 4+N- Dimensional Manifold. Open Access Maced J Med Sci. 2019 Sep 30; 7(18):3073-3080.  
<https://doi.org/10.3889/oamjms.2019.776>

**Keywords:** Blackhole; Telecommunication; Earth; Dark DNA; Waves

**\*Correspondence:** Massimo Fioranelli. Department of Nuclear Physics, Sub-nuclear and Radiation, G. Marconi University, Rome, Italy. E-mail: [massimo.fioranelli@gmail.com](mailto:massimo.fioranelli@gmail.com)

**Received:** 16-Jun-2019; **Revised:** 04-Jul-2019; **Accepted:** 05-Jul-2019; **Online first:** 30-Aug-2019

**Copyright:** © 2019 Massimo Fioranelli, Alireza Sepehri, Maria Grazia Roccia, Cota Linda, Chiara Rossi, Petar Vojvodic, Jacopo Lotti, Victoria Barygina, Aleksandra Vojvodic, Uwe Wollina, Michael Tirant, Nguyen Van Thuong, Torello Lotti. This is an open-access article distributed under the terms of the Creative Commons Attribution-NonCommercial 4.0 International License (CC BY-NC 4.0)

**Funding:** This research did not receive any financial support

**Competing Interests:** The authors have declared that no competing interests exist

## Abstract

Recently, some scientists from NASA have claimed that there may be a black hole like structure at the centre of the earth. We show that the existence of life on the earth may be a reason that this black hole like object is a black brane that has been formed from biological materials like DNA. Size of this DNA black brane is 109 times longer than the size of the earth's core and compacted interior it. By compacting this long object, a curved space-time emerges, and some properties of black holes emerge. This structure is the main cause of the emergence of the large temperature of the core, magnetic field around the earth and gravitational field for moving around the sun. Also, this structure produces some waves which act like topoisomerase in biology and read the information on DNAs. However, on the four-dimensional manifold, DNAs are contracted at least four times around various axis's and waves of earth couldn't read their information. While, by adding extra dimensions on 4+n-dimensional manifold, the separation distance between particles increases and all of the information could be recovered by waves. For this reason, each DNA has two parts which one can be seen on the four-dimensional universe, and another one has existed in extra dimensions, and only it's effects is observed. This dark part of DNA called as a dark DNA in an extra dimension. These dark DNAs not only exchange information with DNAs but also are connected with some of the molecules of water and helps them to store information and have memory. Thus, the earth is the biggest system of telecommunication which connects DNAs, dark DNAs and molecules of water.

## Introduction

Black holes and their related subjects are of main puzzles in science which many scientists work on them [1]. Physics of these objects is approximately known. However, they are lost, and many cosmological detectors and telescopes try to find them. On the other hand, the concept of a black hole isn't limited to cosmology, and in some high energy colliders, some objects may emerge that change space-time [2]. These objects are known as Tev black holes or mini black holes that are formed from concentrating of a large amount of energy in a small

place at large hadron collider [3], [4], [5]. Thus, some types of black hole-like structures could be observed on earth. Newly, some scientists who worked in NASA claimed that there is a black hole at the centre of the earth which is the main cause of the high temperature of the core and magnetic field around the earth [6]. This idea may change some old beliefs about the formation of the earth and solar system. In this model, the earth is a planet that has been formed around a black hole and has properties of that object in its core. In this paper, we show that this idea could have more results and help us to explore the origin of life.

One of the main questions in science is about the relation between the inner core of the earth, life,

water and waves. Each of these subjects has its own puzzle centre, and all of them together make a more main puzzle. For example, our knowledge about the inner core of the earth isn't complete, and only limited information has been obtained from the waves of the earthquake [7], [8], [9], [10], [11]. These considerations have shown that there is equatorial anisotropy in the inner part of the Earth's inner core [7], [8]. Also, scientists have estimated the temperature of the inner core from the melting temperature of impure iron at the pressure which iron is under at the boundary of the inner core (about 330 GPa) [9]. From these considerations, they have estimated its temperature as between 5,400 K (5,100 C; 9,300 F) and 5,700 K (5,400 C; 9,800 F). However, in 2013, some others have obtained experimentally a substantially higher temperature for the melting point of iron, 6230 [10], [11]. The reason for this high temperature is unclear. However, some scientists believe that some nuclear interactions occur interior of the core that is the main cause of high temperature [12], [13], [14]. In parallel, the origin of life on the earth and its relation with evolutions of the core is unclear.

Also, there are some puzzles about controlling life by some special dark genes which couldn't be observed and detected by present devices. These genes have been discovered by

Hargreaves and his colleagues. They have encountered a dark part of DNA when sequencing the genome of the sand rat (*Psammomys obesus*), a species of gerbil that lives in deserts.

In particular, they wanted to study the gerbil's genes related to the production of insulin, to understand why this animal is particularly susceptible to type 2 diabetes. But when they looked for a gene called *Pdx1* that controls the secretion of insulin, they found it was missing, as were 87 other genes surrounding it. Some of these missing genes, including *Pdx1*, are essential and without them, an animal cannot survive. The first clue was that, in several of the sand rats body tissues, they found the chemical products that the instructions from the missing genes would create. This would only be possible if the genes were present somewhere in the genome, indicating that they weren't missing but just hidden [15]. Now, the question arises that how we can communicate with these special dark DNAs which their effects can be seen; however, they are themselves lost.

Another puzzle in science is the ability of molecules of water for exchanging information with DNAs and storing their information [16], [17], [18]. The chemical structure of water ( $H_2O$ ) is very simple and has no ability to store information. Thus, how these molecules communicate with other molecules and DNAs. Also, it seems that there is a relation between molecules of water, earth and DNA. Because the water of rain has a better effect on the plants and their growth.

To respond to all of these questions, we should design a model which explains the relationship between earth, water and life. To this aim, we can use ideas of scientists for the existence of a black hole at the centre of the earth. This black hole may be constructed from a DNA black brane with 109 times longer than the core of the earth which is compacted interior of the core. The number of excited states of this object is similar to the number of microstates of a black hole. However, its material is similar to the material of a DNA. This structure produces a temperature around 6000 K which is in agreement with the predicted temperature of the core. Also, this structure is the main cause of the emergence of the magnetic field around the earth and gravitational waves for moving around the sun. We show that DNA black brane of the earth is the biggest system of telecommunications which exchange waves with all DNAs and molecules of water. Also, we introduce a new type of DNAs called dark DNAs on the eleven-dimensional manifold. In fact, on the four-dimensional manifold, DNAs are contracted at least four times around various axes and waves of earth couldn't read their information. However, by adding extra dimensions, the separation distance between particles increases and all of the information could be recovered by waves.

For this reason, each DNA has two parts which one can be seen on the four-dimensional universe, and another one has existed in extra dimensions, and only its effects can be observed. This extra dark part of DNA called as a dark DNA in an extra dimension. Waves of the earth's DNA connect DNAs on four-dimensional universe and dark

DNAs in extra dimensions and act like topoisomerases in biology. These waves are different for males and females and also different from linear waves which radiate by electronic devices.

On the other hand, experiments show that radiated waves of the earth interact with molecules of water and store information in their memory. The memory of water is in contradiction to its chemical structure ( $H_2O$ ). Thus, there should be extra dark DNAs in related to the molecules of water that help them in storing information and exchanging waves with DNAs of earth. This means that molecules of water could have gender like DNAs. On the other hand, the earth could emit some special waves to molecules of water and extract DNA black brane from extra dimensions. This could be the origin of life on earth. Thus, earth, water and DNA form the best system of telecommunication which controls all evolutions of life.

The outline of the paper is as follows. In section II, we show that a DNA black brane interior of the core may be the cause of the emergence of the magnetic field, gravitational waves and high temperature. In section III, we show that the core of the earth, DNA, waves and molecules of water create

the biggest system of telecommunication.

## The emergence of Magnetic Field, Gravitational Wave and High Temperature of Earth's Core by a DNA Black Brane

In this section, we will show that all DNAs of creatures are imaged on its core and produce a DNA black brane in it (See Figure 1). This structure has around  $10^9$  times longer than the core of the earth and is compacted interior of the core. We will show that this structure is the main cause of the gravitational field, magnetic field and high temperature of the core.

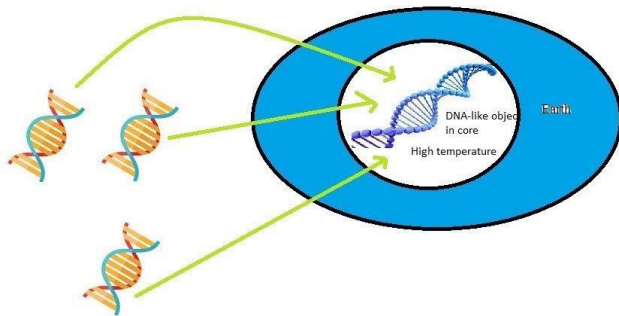


Figure 1: Induced DNA black brane interior of the core by imaging all DNAs on its meta

First, we calculate Hamiltonian of one DNA and then, we generalise it to a DNA black brane. Each DNA is formed from hexagonal and pentagonal molecules (See Figure 2).

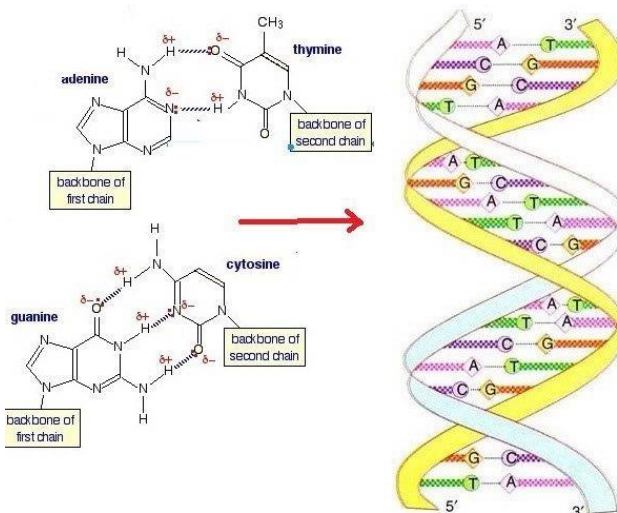


Figure 2: Each DNA is formed from joining hexagonal and pentagonal molecules [19]

Also, each hexagonal and pentagonal molecule is formed from six or -ve strings (See Figure 3).

Thus, we will use the action of strings for

them [20], [21];

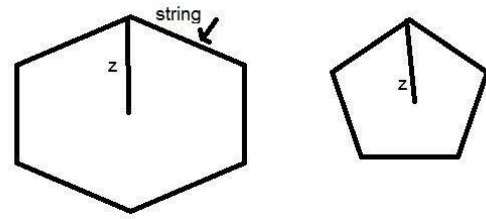


Figure 3: Each hexagonal molecule is formed from joining six strings

The topology of DNA has a direct effect on its radiation [19],

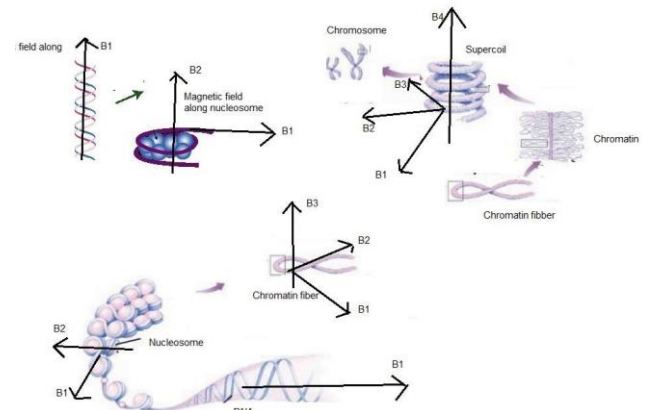


Figure 4: Each DNA and its hexagonal and pentagonal manifolds are coiled several times around the axis

$$ds^2 = -dt^2 + dr^2 + r^2(d\theta^2 + \sin^2\theta d\phi^2) + \sum_{i=1}^6 dx_i^2 \quad (1)$$

without background axes. Here,  $t$  is time,  $r$  is the radius of the page of DNA and  $\theta$  is the angle of rotation. The action of this DNA can be given by:

$$S = -T_{ir} \int d^3\sigma \sqrt{\eta^{ab} g_{MN} \partial_a \phi^M \partial_b \phi^N + 2\pi l_s^2 G(F)}$$

$$G = \left( \sum_{n=1}^N \frac{1}{n!} (-\frac{F_1 \cdot F_n}{\beta^2}) \right)$$

$$F = F_{\mu\nu} F^{\mu\nu} \quad F_{\mu\nu} = \partial_\mu A_\nu - \partial_\nu A_\mu \quad (2)$$

where  $g_{MN}$  is the background metric,  $\theta^M(\sigma^a)$ 's are scalar fields which are produced by pairing electrons ( $\phi = \psi_{up} \psi_{down}$ ),  $N$  is a number of exchanged photons between DNAs,  $\sigma^{a_i}$ 's are the DNA coordinates,  $a, b = 0, 1, \dots, 3$  are world-volume indices of DNA and  $M, N = 0, 1, \dots$  are a number of paired electrons. Also,  $G$  is the nonlinear field, and  $A$  is the photon which exchanges between DNAs.

Using the metric in equation (1), we can write below relations between coordinates of bulk and a DNA [20], [21]:

$$t(\sigma) = \tau \quad r(\sigma) = \sigma, \quad x_1(\sigma) = z \tag{3}$$

Using the above relations, for this DNA in at space time, the action is given by [20], [21]:

$$S = - \int d\sigma \sigma^2 \sqrt{1 + z'^2 - 2\pi l_s^2 G'(F)} \tag{4}$$

For this action, it has been asserted that momentum density is given by [20], [21]:

$$\Pi = \frac{2\pi l_s^2 G'(F) F_{01}}{\sqrt{1 + z'^2 - 2\pi l_s^2 G'(F)}} \tag{5}$$

where ' denotes the derivative respect to the field (F). On the other hand, it has been asserted that there is a relation between momentum density and  $\sigma$  [20], [21]:

$$\Pi = \frac{K}{\sigma^2} \tag{6}$$

Using equations (5 and 6) and assuming ( $z' \ll G(F)$ ) and also following method in [20], [21], [22], we can obtain:

### 3.3

$$H_6 = \sqrt{1 + z'^2} \sqrt{1 + \frac{K^2}{\sigma^4 \sqrt{1 + \frac{K^2}{\sigma^4}}}} \\ = \sqrt{1 + z'^2} \sqrt{1 + \frac{K^2}{\sigma^4}} \tag{7}$$

$$H_5 = \sqrt{1 + z'^2} \sqrt{1 + \frac{K^2}{\sigma^4 \sqrt{1 + \frac{K^2}{\sigma^4}}}} \\ = \sqrt{1 + z'^2} \sqrt{1 + \frac{K^2}{\sigma^4}} \tag{8}$$

Above equation shows that Hamiltonian of bases depends on their shape, the separation distance between atoms and angles. Each DNA is coiled several times, and thus, its hexagonal and pentagonal manifolds are coiled several times around various axes (See Figure 4 ).

Coiling around the axes leads to the motion of electrons in various directions and emergence of the magnetic field. Thus, radiation of DNAs depend on their topology, and for this reason, radiation of chromosomes of males is different respect to radiations of chromosomes of females.

For coiled hexagonal and pentagonal manifold, we obtain:

$$H_6 = \sqrt{1 + z'^2} \sqrt{1 + \frac{K^2}{\sigma^4}} = \sqrt{1 + z'^2} \sqrt{1 + \frac{K^2}{[z_1 \tan(\frac{\pi}{4} - \theta)]^4}} \tag{9}$$

$$H_5 = \sqrt{1 + z'^2} \sqrt{1 + \frac{K^2}{\sigma^4}} = \sqrt{1 + z'^2} \sqrt{1 + \frac{K^2}{[z_2 \tan(\frac{\pi}{4} - \theta)]^4}} \tag{10}$$

where, we have used of below relation:

$$\sigma' = z \tan(\frac{\pi}{4} - \theta) \tag{11}$$

which are rounded around axes, using Hamiltonians in (9 and 10), we can obtain below Hamiltonian:

$$H_{6-5} = \sqrt{1 + [z'_1]^2} \sqrt{1 + \frac{K^2}{[z_1 \tan(\frac{\pi}{4} - \theta_1)]^4}} \sqrt{1 + [z'_2]^2} \sqrt{1 + \frac{K^2}{[z_2 \tan(\frac{\pi}{4} - \theta_2)]^4}} \times \\ \sqrt{1 + \frac{K^2}{[r\phi]^4}} \tag{12}$$

where  $\frac{\pi}{4} - \theta$  is the angle between two atoms of respect to the center of hexagonal and pentagonal manifolds, and  $\phi$  is the angle between a hexagonal and a pentagonal manifold. Consequently, Hamiltonian of a DNA can be obtained as:

$$H_{DNA} = \Sigma_{m,n} \sqrt{1 + [z'_1]^2} \sqrt{1 + \frac{K^2}{[z_1 \tan(\frac{\pi}{4} - \theta_1)]^4}} \sqrt{1 + [z'_2]^2} \sqrt{1 + \frac{K^2}{[z_2 \tan(\frac{\pi}{4} - \theta_2)]^4}} \times \\ \dots \times \\ \sqrt{1 + [z'_m]^2} \sqrt{1 + \frac{K^2}{[z_m \tan(\frac{\pi}{4} - \theta_m)]^4}} \sqrt{1 + [z'_n]^2} \sqrt{1 + \frac{K^2}{[z_n \tan(\frac{\pi}{4} - \theta_n)]^4}} \times \\ [\sqrt{1 + \frac{K^2}{[r_1\phi_1]^4}}] \dots [\sqrt{1 + \frac{K^2}{[r_n\phi_n]^4}}] \tag{13}$$

This Hamiltonian depends on the separation distance and the angle between atoms. Topology of

DNA has a direct effect on its energy, and for example, the energy of DNAs in males and females are different. By using some special values for angles between atoms, we can obtain the known energy of the earth of the above Hamiltonian:

$$z_1 = z_2 \dots = z_n \\ \tan(\frac{\pi}{4} - \theta) = n^{\frac{1}{2}} z^{\frac{1}{2}} \\ E_{DNA} = \Sigma_{m,n} \sqrt{1 + [z'_1]^{m+n}} \sqrt{1 + \frac{K^2}{[r_1\phi_1]^4}} \dots \sqrt{1 + \frac{K^2}{[r_n\phi_n]^4}} \left[ \frac{1}{n z_1} \right] = \\ G_{earth} M \left[ \frac{1}{R} \right] \tag{14}$$

where

$$R = n z_1 \quad G_{earth} = K^n \quad M = \Sigma_{m,n} \sqrt{1 + [z'_1]^{m+n}} \left[ \frac{1}{[r_1\phi_1]^4} \right] \dots \left[ \frac{1}{[r_n\phi_n]^4} \right] \tag{15}$$

Above equation shows that DNA black brane interior of the core can produce expected gravitational energy. Thus, this theory is in agreement with known laws of physics. Now, we can assert that the magnetic of earth can be obtained by summing over exchanged electromagnetic fields between atoms:

$$G = \left( \sum_{n=1}^N \frac{1}{n!} (-\frac{F_1 \dots F_n}{\beta^2}) \right) \\ F = F_{\mu\nu} F^{\mu\nu} \quad F_{\mu\nu} = \partial_\mu A_\nu - \partial_\nu A_\mu \\ B_{earth} = B_1 + B_2 + \dots + B_n \tag{16}$$

where  $n$  is the number of magnetic fields between elements of DNA black brane. Above

equation shows that the magnetic field of the earth can be obtained by summing over magnetic fields of pentagonal and heptagonal manifolds. This magnetic field depends on the topology of DNA, and for example, for a DNA with the gender of male, the magnetic field is different respect to the DNA with the gender of female. Now, we want to obtain the temperature of the core. To this aim, we put a number of microstates of all pentagonal and hexagonal manifolds equal to the number of microstate of DNA black brane. To calculate a number of microstates, we use a normal thermal distribution which is used for Bose-Einstein correlation in statistics:

$$\begin{aligned}
 N_{DNA} &= N_{5-6,1} N_{5-6,2} N_{5-6,3} \dots N_{5-6,n} \\
 N_{DNA} &= \int_{core} d^3\sigma \frac{e^{-\frac{H_{DNA}}{T_{DNA}}}}{1 - e^{-\frac{H_{DNA}}{T_{DNA}}}} \\
 N_{5-6} &= \int_{core} d^3\sigma \frac{e^{-\frac{H_{5-6}}{T_{5-6}}}}{1 - e^{-\frac{H_{5-6}}{T_{5-6}}}}
 \end{aligned}
 \tag{17}$$

Consequently, temperature of DNA black brane or core can be obtained as:

$$T_{core} = T_{DNA-like} = H_{DNA} \frac{\partial^3}{\partial \sigma^3} \frac{1}{\int_{core} [e^{\frac{H_{5-6,1}}{T_{5-6,1}} - 1}] [e^{\frac{H_{5-6,2}}{T_{5-6,2}} - 1}] \dots [e^{\frac{H_{5-6,n}}{T_{5-6,n}} - 1}]}
 \tag{18}$$

This equation shows that the temperature of DNA black brane depends on the Hamiltonian of DNA black brane, Hamiltonian of hexagonal-pentagonal molecules and temperatures of each manifold.

Assuming that temperatures of hexagonal and pentagonal manifolds be constant and around the temperature of the room and using equations (12, 13 and 15), we can obtain dependency of temperature in terms of size of the core and plot it in Figure 5.

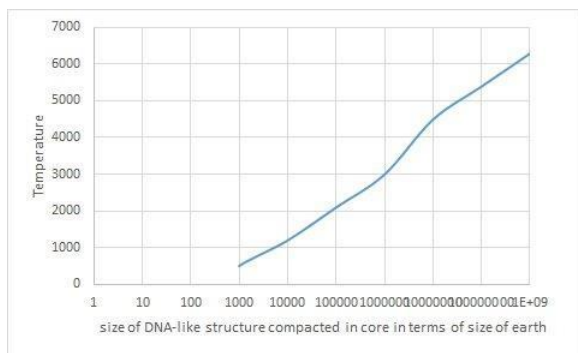


Figure 5: Temperature of DNA black brane in terms of its size

It is clear that for a DNA black brane with the size around  $10^9$  times longer than the core of the earth, the temperature will be around 6000 K. This temperature is in agreement with predicted temperature for the core. It is concluded that a DNA black brane with  $10^9$  meters which is compacted interior of core, can produce all known physics of the earth.

## Formation of a System of Telecommunication by Waves, DNAs, Dark DNAs and Molecules of Water

Now, we consider the process of communications between earth, DNAs and molecules of water. In Figure 6, we show that a system like a DNA may be coiled in four dimensions. However, by adding extra strings in extra dimensions, it will be open, and its topology will be transferred to a circle.

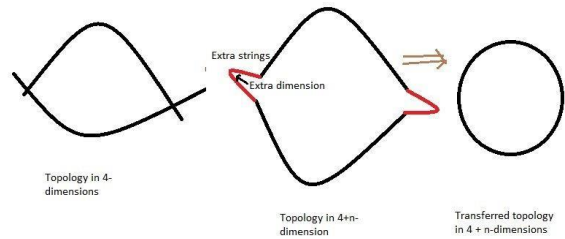


Figure 6: Topology of a system by adding some extra strings in extra dimensions change and shrinks to a circle

These extra strings may be related to waves or dark DNAs in extra dimensions. We can write below relation between waves, DNAs and dark DNAs in extra dimensions:

$$1 = N_{Circle} = N_{DNA} N_{Wave} N_{DarkDNA}
 \tag{19}$$

where  $N_{Circle}$  is the number of microstates for a circle which is produced by joining dark.

DNA, waves and DNA. Also,  $N_{DNA}$  is the number of microstates for DNA,  $N_{Dark-DNA}$  is the number of microstates for dark DNA, and  $N_{wave}$  is the number of microstates for waves. This equation shows that waves connect DNAs in four dimensions to dark DNAs in extra dimensions and deform their topology, open their coilings and transfer them to circles (See Figure 7).

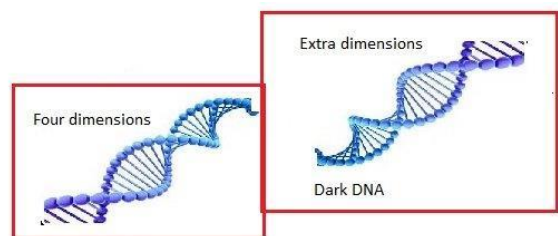


Figure 7: Dark DNA in extra dimensions

Thus, a number of microstates of waves depend on the number of microstates of DNAs and dark DNAs in extra dimensions. We can write below relation for the interaction of molecules of water with dark DNAs and waves:

$$1 = N_{Circle} = N_{water}N_{Wave}N_{DarkDNA} \quad (20)$$

where  $N_{Circle}$  is the number of microstates for a circle which is produced by joining dark DNA, waves and molecules of water. Also,  $N_{water}$  is the number of microstates for molecules of water,  $N_{Dark-DNA}$  is the number of microstates for dark DNA and  $N_{wave}$  is the number of microstates for waves. Above equation shows that waves connect molecules of water to dark DNAs in extra dimension (See figure 8). For this reason, molecules of water are able to store information, otherwise, the chemical structure of water in four dimension ( $H_2O$ ) isn't able to store information. This could be a main reason for the existence of memory for molecules of water.

Now, the question arises that what is the origin of 4+ n-dimensional waves. We can show that DNA black brane of the core is the main cause of production of these waves and their communications with dark DNAs and molecules of water. We can obtain:

$$1 = N_{Circle} \times N_{Circle} \times N_{Circle} = N_{DNA-like-structure-Earth}N_{Wave}N_{DarkDNA} \times N_{water}N_{Wave}N_{DarkDNA} \times N_{water}N_{Wave}N_{DarkDNA} \quad (21)$$

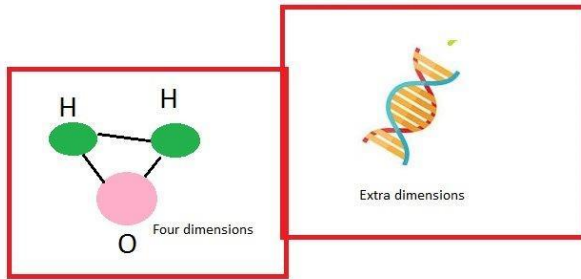


Figure 8: The relation between molecules of water and dark DNAs in extra dimensions

Above equation shows that there is a big system of telecommunication which is formed by the core of the earth, DNAs, waves, molecules of water and dark DNAs in an extra dimension. This big system of telecommunication controls all evolutions of life on the earth. Also, the shape of DNAs has a direct effect on their number of microstates and consequently is in relation to a number of microstates of waves, molecules of water and dark DNAs in an extra dimension.

### Some Results Of The Existence Of The Biggest System Of Telecommunication

We can write below results from our model and calculations: 1. Molecules of water are in related to dark DNAs in extra dimensions. On the other hand, dark DNAs have gender like normal DNAs.

Thus, molecules of water can have some properties like gender, and each molecule of water with the gender of the male can attract by DNAs with the gender of female and reversely, each molecule of water with the gender of a female can attract with molecules of water with the gender of male (See Figures 9 and 10).

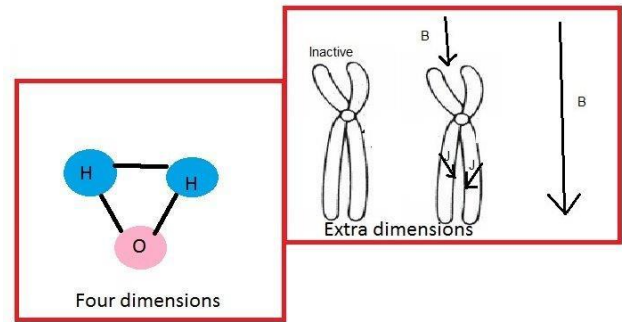


Figure 9: Molecules of water is related to dark DNAs with the gender of female

Equation (19, 20 and 21) give this possibility that the number of microstates of molecules of water has a relation with a number of microstates of DNAs and dark DNAs. This means that by radiating some waves to molecules of water, we can increase the number of microstates of molecules of water and obtain below relation:

$$1 = N_{Circle}N_{water} = N_{water}N_{Wave}N_{DarkDNA}N_{DNA} \quad (22)$$

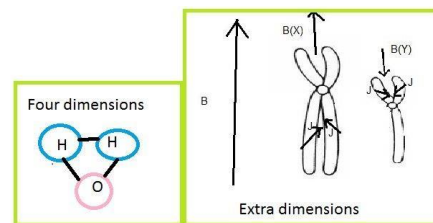


Figure 10: Molecules of water is related to dark DNAs with the gender of male

2. Above equation shows that by radiating some waves to water, we can extract properties of DNAs. This result is in good agreement with predictions of Montagnier and his colleagues (see Figure 11).

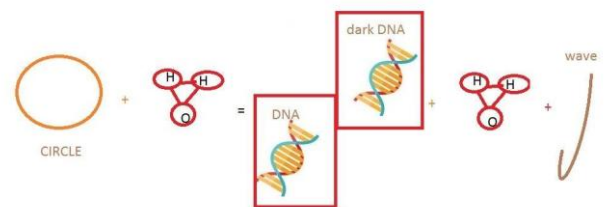


Figure 11: Emergence of life by waves of the earth in pure water

3. DNA black brane interior of core, DNAs on the earth, dark DNAs in extra dimensions, waves and molecules of water form the best system of telecommunication (See figure 12).

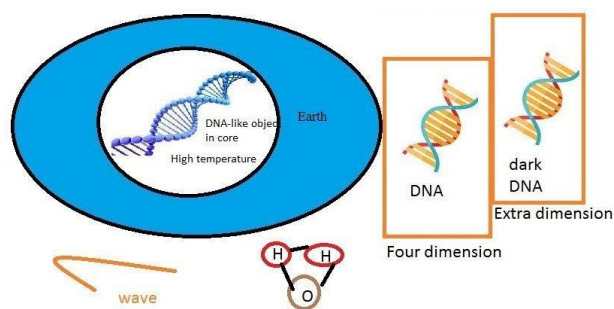


Figure 12: The biggest system of telecommunication from DNA black brane interior of core, DNAs on the earth, dark DNAs in extra dimensions and molecules of water

## Conclusions

In this paper, we have shown that the earth's core is the biggest system of telecommunication which exchanges waves with all DNAs and molecules of water. Imaging of DNAs on the interior of the metal of the core produces a DNA black brane with around  $10^9$  times longer than the core of the earth which is compacted and creates a structure similar to a black hole or black brane. We have shown that this DNA black brane is the main cause of high temperature of core and magnetic of earth.

Also, this structure produces gravitational fields of earth and leads to the motion of the earth around the sun. We have argued that DNA black brane of earth exchange some non-linear waves with DNAs and recover their information. The shape of these waves depends on the topology of DNAs and are different for DNAs of males and females. Each DNA is compacted several times around various axes and reading it's information is hard.

However, by adding extra dimensions to four dimensions of the universe, the separation distance between elements of DNAs increases and waves of earth could recover their information. Thus, each DNA has an extra dark part in extra dimension which we call them dark DNAs. These extra parts couldn't be observed, however, their effects can be seen. DNA black brane of the earth's core exchange waves with both dark and light parts of DNA and connect them. These waves are different for males and females and play the role of topoisomerases in biology.

On the other hand, our calculations and experiments show that these waves interact with molecules of water. However, the chemical structure of water ( $H_2O$ ) is very simple and cant store any information. This means that there are some extra dark DNAs on the 4+n-dimensional manifold which are related to molecules of water and play the role of memory for it. These dark DNAs have gender like other DNAs and give properties of gender to molecules of water. On the other hand, DNA black brane of the earth could emit some special waves to molecules of water and extract dark DNAs from extra

dimensions. This means that the origin of life could be a system of telecommunication which is formed by DNA black brane interior of the earth, dark DNAs, waves and molecules of water.

## References

- Hawking SW, Ellis GF. The large scale structure of space-time. Cambridge university press, 1973. <https://doi.org/10.1017/CBO9780511524646>
- Hawking SW. Virtual black holes. Physical Review D. 1996; 53(6):3099-3107. <https://doi.org/10.1103/PhysRevD.53.3099> PMID:10020307
- Dimopoulos S, Landsberg G. Black holes at the large hadron collider. Physical Review Letters. 2001; 87(16):161602. <https://doi.org/10.1103/PhysRevLett.87.161602> PMID:11690198
- Giddings SB, Thomas S. High energy colliders as black hole factories: The end of short-distance physics. Physical Review D. 2002; 65(5):056010. <https://doi.org/10.1103/PhysRevD.65.056010>
- CMS Collaboration. JHEP. 2018; 11:042. arxiv: 1805.06013.
- Riofrio L. Scientist Claims Theres a Black Hole in Center of the Earth. May 3, 2019. <https://mysteriousuniverse.org/2019/05/scientist-claims-theres-a-black-hole-in-center-of-the-earth>.
- Wang T, Song X, Xia HH. Equatorial anisotropy in the inner part of Earth's inner core from autocorrelation of earthquake coda. Nature Geoscience. 2015; 8(3):224. <https://doi.org/10.1038/ngeo2354>
- Tkalcic H, Pham TS. New Constraints on the Earth's Core From Global Correlation Wavefield. In EGU General Assembly Conference Abstracts. 2018; 20:5834.
- Souriau A, Souriau M. Ellipticity and density at the inner core boundary from subcritical PKiKP and PcP data. Geophysical Journal International. 1989; 98(1):39-54. <https://doi.org/10.1111/j.1365-246X.1989.tb05512.x>
- Alfe D, Gillan MJ, Price GD. Temperature and composition of the Earth's core. Contemporary Physics. 2007; 48(2):63-80. <https://doi.org/10.1080/00107510701529653>
- Anzellini S, Dewaele A, Mezouar M, Loubeyre P, Morard G. Melting of iron at Earth's inner core boundary based on fast X-ray diffraction. Science. 2013; 340(6131):464-6. <https://doi.org/10.1126/science.1233514> PMID:23620049
- Fukuhara M. Possible generation of heat from nuclear fusion in Earth's inner core. Scientific reports. 2016; 6:37740. <https://doi.org/10.1038/srep37740> PMID:27876860 PMID:PMC5120317
- de Meijer RJ, van Westrenen WS. Afr J Sci. (in the press).
- Schulling RD. Is there a Nuclear Reactor at the Center of the Earth? In: Dye S.T. (eds) Neutrino Geophysics: Proceedings of Neutrino Sciences 2005. Springer, New York, NY, 2006.
- Hargreaves A. The hunt for dark DNA - New Scientist. 2018; 237:3168. [https://doi.org/10.1016/S0262-4079\(18\)30440-8](https://doi.org/10.1016/S0262-4079(18)30440-8)
- Davenas E, Beauvais F, Amara J, et al. Human basophil degranulation triggered by very dilute antiserum against IgE. Nature. 1988; 333(6176): 8168. <https://doi.org/10.1038/333816a0> PMID:2455231
- Montagnier L, Assa J, Ferris S, Lavalley C. Electromagnetic signals are produced by aqueous nanostructures derived from bacterial DNA sequences. Interdiscip Sci Comput. Life Sci. 2009; 1:81-90. <https://doi.org/10.1007/s12539-009-0036-7> PMID:20640822
- Montagnier L, Giudice ED, Alssa J, Lavalley C, Motschwiller S,

- Capolupo A, Polcari A, Romano P, Tedeschi A, Vitiello G. Transduction of DNA information through water and electromagnetic waves. *Electromagnetic Biology and Medicine*. 2015; 34:106-112. <https://doi.org/10.3109/15368378.2015.1036072> PMID:26098521
19. Sepehri A, Fioranelli M, Rocchia MG, Shoorvazi S. The relation between Tsallis-entropy of DNA-Branes exterior and interior of shell. *Physica A: Statistical Mechanics and its Applications*. 2019; 524:73- 88. <https://doi.org/10.1016/j.physa.2019.03.003>
20. Grignani G, Harnack T, Marini A, Obers NA, Marta Orselli. *JHEP*. 2011; 1106:058. [https://doi.org/10.1007/JHEP06\(2011\)058](https://doi.org/10.1007/JHEP06(2011)058)
21. Grignani G, Harnack T, Marini A, Obers NA, Orselli M. *Nucl Phys*. 2011; B851:462-480. <https://doi.org/10.1016/j.nuclphysb.2011.06.002>
22. Sepehri A, Rahaman F, Capozziello S, Ali AF, Pradhan A. *Eur Phys J*. 2016; 5:231.



# Acanthosis Nigricans – A Two-Sided Coin: Consider Metabolic Syndrome and Malignancies!

Uwe Wollina<sup>1\*</sup>, Gesina Hansel<sup>1</sup>, Torello Lotti<sup>2</sup>, Georgi Tchernev<sup>3</sup>, Aleksandra Vojvodic<sup>4</sup>, Ivanka Temelkova<sup>3</sup>

<sup>1</sup>Department of Dermatology and Allergology, Teaching Hospital Dresden - Friedrichstadt, Dresden, Germany; <sup>2</sup>Professor & Chair of Dermatology, University of Rome "G. Marconi", Rome, Italy; <sup>3</sup>Onkoderma - Clinic for Dermatology, Venereology and Dermatologic Surgery, General Skobelev 26, 1606, Sofia, Bulgaria; <sup>4</sup>Department of Dermatology and Venereology, Military Medical Academy of Belgrade, Belgrade, Serbia;

## Abstract

**Citation:** Wollina U, Hansel G, Lotti T, Tchernev G, Vojvodic A, Temelkova I. Acanthosis Nigricans – A Two-Sided Coin: Consider Metabolic Syndrome and Malignancies! Open Access Maced J Med Sci. 2019 Sep 30; 7(18):3081-3084.  
<https://doi.org/10.3889/oamjms.2019.258>

**Keywords:** Acanthosis nigricans; Metabolic syndrome; Malignancies; Paraneoplasia

**\*Correspondence:** Uwe Wollina, Department of Dermatology and Allergology, Teaching Hospital Dresden - Friedrichstadt, Dresden, Germany. E-mail: uwollina@gmail.com

**Received:** 05-Apr-2019; **Revised:** 04-May-2019; **Accepted:** 05-May-2019; **Online first:** 13-May-2019

**Copyright:** © 2019 Uwe Wollina, Gesina Hansel, Torello Lotti, Georgi Tchernev, Aleksandra Vojvodic, Ivanka Temelkova. This is an open-access article distributed under the terms of the Creative Commons Attribution-NonCommercial 4.0 International License (CC BY-NC 4.0)

**Funding:** This research did not receive any financial support

**Competing Interests:** The authors have declared that no competing interests exist

**BACKGROUND:** Acanthosis nigricans (AN) is acquired hyperpigmentation of the intertriginous body regions. Histologically, AN is characterised by a thickened stratum corneum and a variable amount of acanthosis. Although benign and rarely symptomatic, AN may be a red flag for underlying pathologies.

**CASE PRESENTATION:** We analysed our patients with AN and could differentiate three different patterns, that are illustrated by one case report each. The first is the benign AN associated with metabolic syndrome including obesity. The second type is the paraneoplastic AN malignancy which is associated with a wider range of malignancies. This type may occur before, after or with the clinical appearance of the malignancy. The third type is relapsing AN after complete remission. We present a patient who had a malignant AN and was treated successfully for his cancer. Years later, however, AN relapsed. In that case in association with the appearance of skin tags. Cancer re-staging excluded a tumour relapse. His BMI was 31.2 kg/m<sup>2</sup>, and the diagnosis of benign AN was confirmed.

**CONCLUSIONS:** The diagnosis of AN remains incomplete without screening for metabolic syndrome and/or cancer. The combination of AN and skin tags is more often associated with metabolic syndrome. AN may be considered as a red flag for malignancies and the metabolic syndrome.

## Introduction

Acanthosis nigricans (AN) is acquired hyperpigmentation of the intertriginous body regions and sometimes the periareolar skin. Besides the colour change, the disease most often remains asymptotically. AN can occur as focal or diffuse papillomatous, hyperkeratotic, thickened lesions, which are symmetrically distributed. It rarely affects mucosa such as oral cavities.

Histologically, AN is characterised by a thickened stratum corneum and a variable amount of acanthosis. Horn pseudocysts can occasionally be

present. The darker colour of AN is likely due to hyperkeratosis. A subtly mixed cellular infiltrate may be seen [1].

AN can develop in children, adolescents and adults. In children, the commonly affected body region is the neck followed by the axillae [2].

The prevalence of AN differs between ethnic groups. In the US, among native Americans, the prevalence was up to 34.2% followed by African Americans, Hispanics and Caucasians [3].

The pathogenesis of AN is complex. Elevated insulin concentrations result in direct and indirect activation of insulin-like growth factor (IGF)-1

receptors on suprabasal keratinocytes and fibroblasts. Other tyrosine kinase receptors such as epidermal growth factor receptor (EGFR) and fibroblast growth factor receptor (FGFR) may also contribute to hyperproliferation of keratinocytes and fibroblasts [4]. However, in obesity, the insulin concentrations are lower than warranted for such effects [5]. Extensive AN has been associated to hypochondroplasia with FGFR3 mutations [6]. Another possible, but the very rare association is a mutation of the *ELOV1* gene that encoded ELOVL fatty acid elongase 1, which catalyses elongation of saturated and monounsaturated C22-C26-very long-chain fatty acids [7]. Malignancy-associated AN might be explained by elevated levels of growth factors such as transforming growth factor (TGF- $\alpha$ ), which can stimulate EGFR [8]. What causes the intertriginous areas to be most responsive has yet not been discovered.

### Differential diagnoses

AN may resemble other disorders such as terra firma forme dermatosis [9], confluent and reticulated papillomatosis [10], berloque dermatitis, Riehl's melanosis, poikiloderma of Civatte [11].

## Case reports

**Case 1:** A 48-year-old adipose male presented with hyperpigmented lesions on the thighs and scrotum. His body mass index (BMI) was 36 kg/m<sup>2</sup>. He suffered from arterial hypertension and hyperlipidemia. On examination, we observed diffuse brownish hyperpigmentation of thighs and scrotal skin with papillomatosis (Figure 1). No treatment was warranted. We recommended nutritional counselling. The diagnosis of benign AN was confirmed.

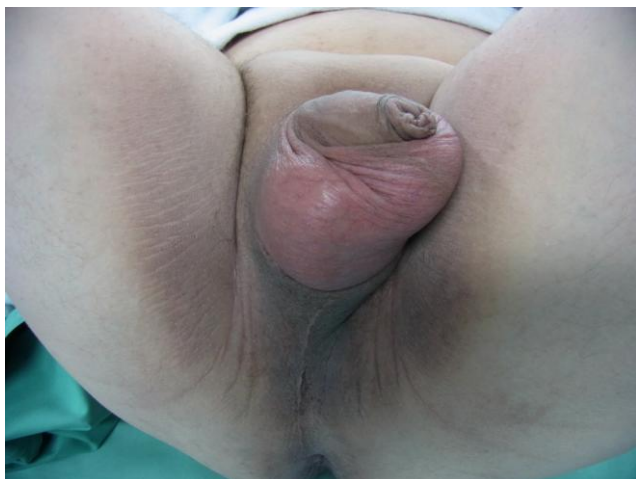

Figure 1: Figure 1: Benign AN in an obese man

**Case 2:** A 39-year-old male presented with a

relapse of intertriginous AN. His medical history was remarkable for kidney cancer in 2012 that was found after the first episode of AN and completely removed by surgery. The diagnosis of AN malignancy was confirmed. Five years later he demonstrated with a relapse of AN brownish-blackish hyperpigmentation in association with skin tags after complete remission in 2013 (Figure 2). We performed a computerised tomography of the abdomen and laboratory investigation that gave no hint of cancer relapse. His BMI was 31.2 kg/m<sup>2</sup>. The diagnosis of benign AN was confirmed, and surgical excision of the thigh lesions was performed. We also recommended nutritional counselling.

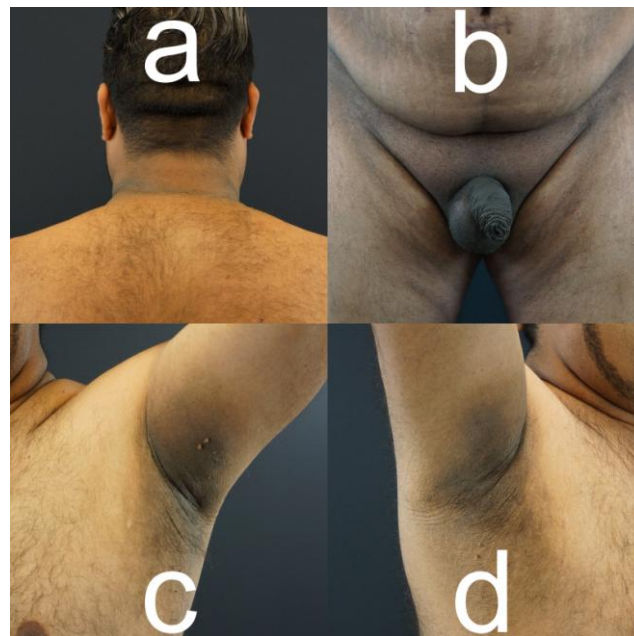


Figure 2: Relapse of AN after successful kidney cancer treatment on the neck (a), groins, scrotum and thighs (b), and axillae (c, d). In the axillae, skin tags are seen

**Case 3:** A 62-year female presented with brownish hyperpigmentation of the neck, the back and the anal fold was presented by the department of oncology (Figure 3). She suffered from cholangiocarcinoma with peritoneal metastases and was treated by chemotherapy with gemcitabine and cisplatin — AN developed shortly after tumour diagnosis. Malignant AN was confirmed, and anti-pruritic topical therapy with 5% povidone iodine ointment was recommended.

### *Acanthosis nigricans and the metabolic syndrome*

The major features of the metabolic syndrome are insulin resistance, visceral adiposity, atherogenic dyslipidemia and endothelial dysfunction [12]. AN has a strong association with overweight in adults, adolescents and children. Obesity in adults is defined as 30 kg/m<sup>2</sup>, whereas in children and adolescents, overweight is defined as  $\geq$  the 95th percentile of the

sex-specific BMI-for-age growth chart [13]. In a Turkish study on obese adults, 47.3% suffered from AN [14].

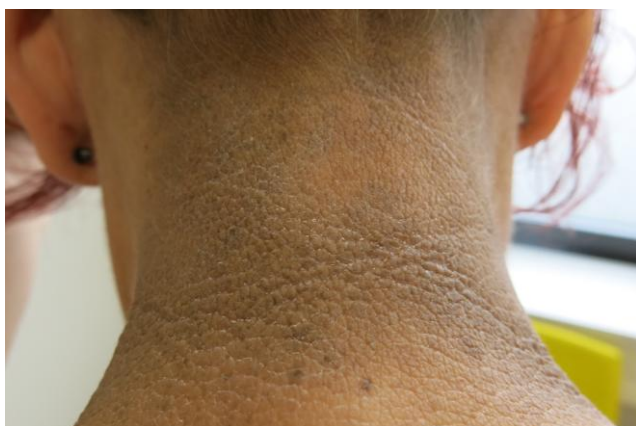

Figure 3: Malignant AN in a woman with cholangiocarcinoma

Overweight and obese children with AN demonstrate significantly higher levels for uric acid, fasting glycemia, insulin, glutamic oxalacetic transaminase, and homeostasis model assessment index than those without AN [15]. This suggests that AN is a marker of increased risk for metabolic syndrome in children, but the same has been demonstrated for other age groups as well [16]. Here, AN often is coexistent with multiple skin tags in contrast to malignant AN. Patients with AN showed be investigated for other symptoms of the metabolic syndrome such as blood pressure (BP), fasting lipoprotein profile, fasting glucose, haemoglobin A1C, fasting insulin, alanine aminotransferase (ALT), hyperlipidemia or hyperuricemia [17]. Women with polycystic ovary syndrome (POCS) show an increased prevalence of metabolic syndrome, type 2 diabetes (DM2) and cardiovascular disease. AN can be a cutaneous marker for POCS [18].

### ***Acanthosis nigricans and cancer***

AN is a possible paraneoplasia. Paraneoplasia is a disorder related to malignancy. It can frequently be the first sign of a subjacent malignant tumour. Although relatively rare, they need to be recognised to make an early diagnosis and improve the prognosis of the malignancy [19]. The malignant conditions that have been associated with AN are tumours of the gastrointestinal tract, gynecologic and urogenital tumours among others, although gastric cancer is the most common (Table 1). In most cases, AN occurs concomitantly (61.3%), however, in 17.6% of cases, the lesions occur before the tumour detection and in 21% of cases, after the tumour has become obvious [20]. In contrast to non-malignant AN, mucous membranes, in particular, the oral cavity, can be affected.

**Table 1: Malignant tumours associated with AN**

Tumour	Reference
Breast cancer	Levine et al., 2010 [21]
Cholangiocarcinoma	Scully et al., 2001 [22]
Clear-cell renal carcinoma	Ferraz de Campos et al. 2016 [23]
Endometrial adenocarcinoma	Deen et al., 2017 [24]
Fallopian tube carcinoma	West et al., 2018 [25]
Gallbladder adenocarcinoma	Ziadi et al., 2009 [26]
Gastric adenocarcinoma	Yu et al., 2017 [27]
Gastric diffuse B-cell lymphoma	Mignogna et al., 2009 [28]
Gastrointestinal stromal tumor	Park et al., 2013 [29]
Hepatocellular carcinoma	Antonio et al., 2018 [30]
Ileocecal adenocarcinoma	Gunduz et al., 2013 [31]
Insulinoma	Patra et al., 2016 [32]
Lung cancer	Owen 2016 [33]
Meningioma	Dainichi et al., 2008 [34]
Mycosis fungoides, Sézary syndrome	Cheng et al., 2015 [35]; Fahmy et al., 2016 [36]
Ovarian cancer	Singh & Rai 2013 [37]
Pancreatic adenocarcinoma	McGinnes & Greer 2006 [38]
Prostate cancer	Tammaro et al., 2016 [39]
Rectal adenocarcinoma	Marschner & Reinhardt 2011 [40]
Sarcoma	Brantsch & Moehrlie 2010 [41]

In conclusion, although AN by itself is most often an asymptomatic disease without significant impairment, the diagnosis is of great importance to identify underlying pathologies. The most important is the metabolic syndrome in overweight and obese patients of any age. The second is the role of malignant AN as an obligate paraneoplasia.

## References

- Schwartz RA. Acanthosis nigricans. *J Am Acad Dermatol.* 1994; 31(1):1-19. [https://doi.org/10.1016/S0190-9622\(94\)70128-8](https://doi.org/10.1016/S0190-9622(94)70128-8)
- Sinha S, Schwartz RA. Juvenile acanthosis nigricans. *J Am Acad Dermatol.* 2007; 57(3):502-8. <https://doi.org/10.1016/j.jaad.2006.08.016> PMID:17592743
- Stuart CA, Gilkison CR, Smith MM, Bosma AM, Keenan BS, Nagamani M. Acanthosis nigricans as a risk factor for non-insulin dependent diabetes mellitus. *Clin Pediatr (Phila).* 1998; 37(2):73-9. <https://doi.org/10.1177/000992289803700203> PMID:9492114
- Hodak E, Gottlieb AB, Anzilotti M, Krueger JG. The insulin-like growth factor 1 receptor is expressed by epithelial cells with proliferative potential in human epidermis and skin appendages: correlation of increased expression with epidermal hyperplasia. *J Invest Dermatol.* 1996; 106(3):564-70. <https://doi.org/10.1111/1523-1747.ep12344044> PMID:8648195
- Lee JM, Okumura MJ, Davis MM, Herman WH, Gurney JG. Prevalence and determinants of insulin resistance among U.S. adolescents: a population-based study. *Diabetes Care.* 2006; 29(11):2427-32. <https://doi.org/10.2337/dc06-0709> PMID:17065679
- Muguet Guenot L, Aubert H, Isidor B, Toutain A, Mazereeuw-Hautier J, Collet C, Bourrat E, Denis Musquer M, Barbarot S; Groupe de Recherche de la Société Française de Dermatologie Pédiatrique. Acanthosis nigricans, hypochondroplasia, and FGFR3 mutations: Findings with five new patients, and a review of the literature. *Pediatr Dermatol.* 2019; 36(2):242-246. <https://doi.org/10.1111/pde.13748> PMID:30762251
- Mueller N, Sassa T, Morales-Gonzalez S, Schneider J, Salchow DJ, Seelow D, Knierim E, Stenzel W, Kihara A, Schuelke M. De novo mutation in ELOVL1 causes ichthyosis, acanthosis nigricans, hypomyelination, spastic paraplegia, high-frequency deafness and optic atrophy. *J Med Genet.* 2019; 56(3):164-175. <https://doi.org/10.1136/jmedgenet-2018-105711> PMID:30487246
- Ellis DL, Kafka SP, Chow JC, Nanney LB, Inman WH, McCadden ME, King LE Jr. Melanoma, growth factors, acanthosis nigricans, the sign of Leser-Trélat, and multiple acrochordons. A possible role for alpha-transforming growth factor in cutaneous paraneoplastic syndromes. *N Engl J Med.* 1987; 317(25):1582-7. <https://doi.org/10.1056/NEJM198712173172506> PMID:2825016
- Unal E, Guarneri C, Chokoeva AA, Wollina U, Tchernev G. Terra

- firma-forme dermatosis. *Wien Med Wochenschr.* 2017; 167(3-4):66-69. <https://doi.org/10.1007/s10354-016-0519-1> PMID:27770322
10. Lim JH, Tey HL, Chong WS. Confluent and reticulated papillomatosis: diagnostic and treatment challenges. *Clin Cosmet Investig Dermatol.* 2016; 9:217-23. <https://doi.org/10.2147/CCID.S92051> PMID:27601929 PMCid:PMC5003519
11. Lautenschlager S, Itin PH. Reticulate, patchy and mottled pigmentation of the neck. Acquired forms. *Dermatology.* 1998; 197(3):291-6. <https://doi.org/10.1159/00018016> PMID:9812039
12. Samson SL, Garber AJ. Metabolic syndrome. *Endocrinol Metab Clin North Am.* 2014; 43(1):1-23. <https://doi.org/10.1016/j.ecl.2013.09.009> PMID:24582089
13. Ogden CL, Carroll MD, Curtin LR, McDowell MA, Tabak CJ, Flegal KM. Prevalence of overweight and obesity in the United States, 1999-2004. *JAMA.* 2006; 295(13):1549-55. <https://doi.org/10.1001/jama.295.13.1549> PMID:16595758
14. Ozlu E, Uzuncakmak TK, Takır M, Akdeniz N, Karadağ AS. Comparison of cutaneous manifestations in diabetic and nondiabetic obese patients: A prospective, controlled study. *North Clin Istanb.* 2018; 5(2):114-119. <https://doi.org/10.14744/nci.2017.68553> PMID:30374476 PMCid:PMC6191549
15. Palhares HMDC, Zaidan PC, Dib FCM, Silva APD, Resende DCS, Borges MF. Association between acanthosis nigricans and other cardiometabolic risk factors in children and adolescents with overweight and obesity. *Rev Paul Pediatr.* 2018;36(3):301-308. <https://doi.org/10.1590/1984-0462/2018;36:3:00017> PMID:30365811 PMCid:PMC6202888
16. Karadağ AS, You Y, Danarti R, Al-Khuzaei S, Chen W. Acanthosis nigricans and the metabolic syndrome. *Clin Dermatol.* 2018; 36(1):48-53. <https://doi.org/10.1016/j.clindermatol.2017.09.008> PMID:29241752
17. Higgins SP, Freemark M, Prose NS. Acanthosis nigricans: a practical approach to evaluation and management. *Dermatol Online J.* 2008; 14(9):2.
18. Kazemi M, Pierson RA, Lujan ME, Chilibeck PD, McBreairey LE, Gordon JJ, Serrao SB, Zello GA, Chizen DR. Comprehensive Evaluation of Type 2 Diabetes and Cardiovascular Disease Risk Profiles in Reproductive-Age Women with Polycystic Ovary Syndrome: A Large Canadian Cohort. *J Obstet Gynaecol Can.* 2019; S1701-2163(18)30991-5. <https://doi.org/10.1016/j.jogc.2018.11.026> PMID:30712903
19. Ramos-E-Silva M, Carvalho JC, Carneiro SC. Cutaneous paraneoplasia. *Clin Dermatol.* 2011; 29(5):541-7. <https://doi.org/10.1016/j.clindermatol.2010.09.022> PMID:21855730
20. Krawczyk M, Mykała-Cieśla J, Kołodziej-Jaskuła A. Acanthosis nigricans as a paraneoplastic syndrome. Case reports and review of literature. *Pol Arch Med Wewn.* 2009; 119:180-183. <https://doi.org/10.20452/pamw.642> PMID:19514649
21. Levine D, Miller S, Al-Dawsari N, Barak O, Gottlieb AB. Paraneoplastic dermatoses associated with gynecologic and breast malignancies. *Obstet Gynecol Surv.* 2010; 65(7):455-61. <https://doi.org/10.1097/OGX.0b013e3181efb12a> PMID:20723267
22. Scully C, Barrett WA, Gilkes J, Rees M, Sarnier M, Southcott RJ. Oral acanthosis nigricans, the sign of Leser-Trélat and cholangiocarcinoma. *Br J Dermatol.* 2001; 145(3):506-7. <https://doi.org/10.1046/j.1365-2133.2001.04393.x> PMID:11531848
23. Ferraz de Campos FP, Narvaez MR, Reis PV, Gomes AC, Paraskevopoulos DK, Santana F, Fugita OE. Acanthosis Nigricans associated with clear-cell renal cell carcinoma. *Autops Case Rep.* 2016; 6(1):33-40. <https://doi.org/10.4322/acr.2016.021> PMID:27284539 PMCid:PMC4880432
24. Deen J, Moloney T, Burdon-Jones D. Severe, Malignant Acanthosis Nigricans Associated with Adenocarcinoma of the Endometrium in a Young Obese Female. *Case Rep Dermatol.* 2017; 9(1):30-37. <https://doi.org/10.1159/000456652> PMID:28413386 PMCid:PMC5346941
25. West L, Carlson M, Wallis L, Goff HW. The Sign of Leser-Trélat and Malignant Acanthosis Nigricans Associated With Fallopiian Tube Carcinoma. *Obstet Gynecol.* 2018; 132(5):1116-1119. <https://doi.org/10.1097/AOG.0000000000002920> PMID:30303917
26. Ziadi T, Alahyane A, El Fahssi M, Makhmari R, Elhjouji A, Baba H, Ould Jiddou C, Nafae I, Mejdane A, Bounaim A, Ait Ali A, Zentar A, Hommadi A, Sair K. [Adenocarcinoma of gallbladder revealed by acanthosis nigricans]. *Gastroenterol Clin Biol.* 2009; 33(10-11):986-8. <https://doi.org/10.1016/j.gcb.2009.06.010> PMID:19765931
27. Yu Q, Li XL, Ji G, Wang Y, Gong Y, Xu H, Shi YL. Malignant acanthosis nigricans: an early diagnostic clue for gastric adenocarcinoma. *World J Surg Oncol.* 2017; 15(1):208. <https://doi.org/10.1186/s12957-017-1274-5> PMID:29178944 PMCid:PMC5702104
28. Mignogna MD, Fortuna G, Falletti J, Leuci S. Gastric diffuse large B-cell lymphoma (DLBCL) exhibiting oral acanthosis nigricans and tripe palms. *Dig Liver Dis.* 2009; 41(10):766-8. <https://doi.org/10.1016/j.dld.2009.02.049> PMID:19349220
29. Park KW, Lim DH, Lee SI. Malignant acanthosis nigricans in a patient with a gastrointestinal stromal tumor. *Korean J Intern Med.* 2013; 28(5):632-3. <https://doi.org/10.3904/kjim.2013.28.5.632> PMID:24009466 PMCid:PMC3759776
30. Antonio JR, Trídico LA, Antonio CR. Malignant Acanthosis nigricans associated with early diagnosis of liver cancer. *An Bras Dermatol.* 2018; 93(4):616-617. <https://doi.org/10.1590/abd1806-4841.20187560> PMID:30066784 PMCid:PMC6063124
31. Gunduz K, Coban M, Öztürk F, Ilmertcan AT. Malignant acanthosis nigricans associated with ileocecal adenocarcinoma. *Cutan Ocul Toxicol.* 2013; 32(2):173-5. <https://doi.org/10.3109/15569527.2012.713417> PMID:22916843
32. Patra S, Chakraborty PP, Barman H, Santra G. Acanthosis nigricans in insulinoma: before and after successful surgical enucleation. *BMJ Case Rep.* 2016; 2016:bcr2016218003. <https://doi.org/10.1136/bcr-2016-218003> PMID:27836838 PMCid:PMC5128931
33. Owen CE. Cutaneous manifestations of lung cancer. *Semin Oncol.* 2016; 43(3):366-9. <https://doi.org/10.1053/j.seminoncol.2016.02.025> PMID:27178690
34. Dainichi T, Moroi Y, Duan H, Urabe K, Koga T, Miyazono M, Sasaki T, Hashimoto T, Furue M. Paraneoplastic acanthosis nigricans and silent meningioma producing transforming growth factor-alpha. *Eur J Dermatol.* 2008; 18(6):721-2.
35. Cheng E, Roy DB, Magro CM. A case of acanthosis nigricans coexisting with mycosis fungoides. *Dermatol Online J.* 2015; 21(7).
36. Fahmy J, Halabi-Tawil M, Ram-Wolff C, Bagot M, Petit A. Paraneoplastic acanthosis nigricans: the first reported case associated with Sézary syndrome. *Br J Dermatol.* 2016; 174(1):233-4. <https://doi.org/10.1111/bjd.14065> PMID:26264676
37. Singh SK, Rai T. A rare case of malignant acanthosis nigricans in a lady with ovarian cancer. *Indian Dermatol Online J.* 2013; 4(2):125-7. <https://doi.org/10.4103/2229-5178.110640> PMID:23741672 PMCid:PMC3673379
38. McGinness J, Greer K. Malignant acanthosis nigricans and tripe palms associated with pancreatic adenocarcinoma. *Cutis.* 2006; 78(1):37-40.
39. Tammara A, Giulianelli V, Parisella F, Persechino S. Bilaterally mammary acanthosis nigricans as paraneoplastic manifestation of prostate adenocarcinoma. *G Ital Dermatol Venereol.* 2016; 151(5):578-9.
40. Marschner ML, Reinhardt JF. Malignant acanthosis nigricans in rectal adenocarcinoma. *Del Med J.* 2011; 83(8):247-9.
41. Brantsch KD, Moehrl M. Acanthosis nigricans in a patient with sarcoma of unknown origin. *J Am Acad Dermatol.* 2010; 62(3):527-8. <https://doi.org/10.1016/j.jaad.2009.02.010> PMID:20159329

# Recovery of Brain in Chick Embryos by Growing Second Heart and Brain

Massimo Fioranelli<sup>1\*</sup>, Alireza Sepehri<sup>1</sup>, Maria Grazia Roccia<sup>1</sup>, Cota Linda<sup>1</sup>, Chiara Rossi<sup>1</sup>, Amos Dawodo<sup>1</sup>, Petar Vojvodic<sup>2</sup>, Jacopo Lotti<sup>1</sup>, Victoria Barygina<sup>3</sup>, Aleksandra Vojvodic<sup>4</sup>, Uwe Wollina<sup>5</sup>, Michael Tirant<sup>6</sup>, Nguyen Van Thuong<sup>7</sup>, Torello Lotti<sup>8</sup>

<sup>1</sup>Department of Nuclear Physics, Sub-nuclear and Radiation, G. Marconi University, Rome, Italy; <sup>2</sup>Clinic for Psychiatric Disorders "Dr. Laza Lazarevic", Belgrade, Serbia; <sup>3</sup>Department of Biomedical Experimental and Clinical Sciences, University of Florence, Florence, Italy; <sup>4</sup>Department of Dermatology and Venereology, Military Medical Academy, Belgrade, Serbia; <sup>5</sup>Department of Dermatology and Allergology, Städtisches Klinikum Dresden, Dresden, Germany; <sup>6</sup>G. Marconi University, Rome, Italy; <sup>7</sup>Vietnam National Hospital of Dermatology and Venereology, Hanoi, Vietnam; <sup>8</sup>Department of Dermatology, University of G. Marconi, Rome, Italy

## Abstract

**Citation:** Fioranelli M, Sepehri A, Roccia MG, Linda C, Rossi C, Dawodo A, Vojvodic P, Lotti J, Barygina V, Vojvodic A, Wollina U, Tirant M, Van Thuong N, Lotti T. Recovery of Brain in Chick Embryos by Growing Second Heart and Brain. *Open Access Maced J Med Sci.* 2019 Sep 30; 7(18):3085-3089. <https://doi.org/10.3889/oamjms.2019.777>

**Keywords:** Chick; Embryo; Brain; Recovery

**\*Correspondence:** Massimo Fioranelli, Department of Nuclear Physics, Sub-nuclear and Radiation, G. Marconi University, Rome, Italy. E-mail: [massimo.fioranelli@gmail.com](mailto:massimo.fioranelli@gmail.com)

**Received:** 23-Jun-2019; **Revised:** 06-Jul-2019; **Accepted:** 07-Jul-2019; **Online first:** 30-Aug-2019

**Copyright:** © 2019 Massimo Fioranelli, Alireza Sepehri, Maria Grazia Roccia, Cota Linda, Chiara Rossi, Amos Dawodo, Petar Vojvodic, Jacopo Lotti, Victoria Barygina, Aleksandra Vojvodic, Uwe Wollina, Michael Tirant, Nguyen Van Thuong, Torello Lotti. This is an open-access article distributed under the terms of the Creative Commons Attribution-NonCommercial 4.0 International License (CC BY-NC 4.0)

**Funding:** This research did not receive any financial support

**Competing Interests:** The authors have declared that no competing interests exist

To recover chick embryos damaged the brain, two methods are presented. In both of them, somatic cells of an embryo introduced into an egg cell and an embryo have emerged. In one method, injured a part of the brain in the head of an embryo is replaced with a healthy part of the brain. In the second method, the heart of brain embryo dead is transplanted with the embryo heart. In this mechanism, new blood cells are emerged in the bone marrow and transmit information of transplantation to subventricular zone (SVZ) of the brain through the circulatory system. Then, SVZ produces new neural stem cells by a subsequent dividing into neurons. These neurons produce new neural circuits within the brain and recover the injured brain. To examine the model, two hearts of two embryos are connected, and their effects on neural circuits are observed.

## Introduction

Several years ago, some investigators proved the existence a little brain on the heart which acts like a real brain in the head [1]. This 'little brain' on the heart is comprised of spatially distributed sensory (afferent), interconnecting (local circuit) and motor (adrenergic and cholinergic efferent) neurones that communicate with others in intrathoracic extracardiac ganglia, all under the tonic influence of central neuronal command and circulating catecholamines. Neurones residing from the level of the heart to the insular cortex form temporally dependent reflexes that

control overlapping, spatially determined cardiac indices [2]. Until now, fewer discussions have been done on this subject. For example, some researchers have argued that cardiac function is under the control of the autonomic nervous system, composed by the parasympathetic and sympathetic divisions, which are finely tuned at different hierarchical levels. They have shown that while a complex regulation occurs in the central nervous system involving the insular cortex, the amygdala and the hypothalamus, a local cardiac regulation also takes place within the heart, driven by an intracardiac nervous system. This complex system consists of a network of ganglionic plexuses and interconnecting ganglions and axons [3].

Now, the question arises that what happens for this little brain during heart transplantation? Recent investigations show that patients who gave hearts from donors, obtain some characteristics of them. One of them was Sylvia who declared that soon after her operation, she felt like drinking beer, something she hadn't particularly been fond of before. Later, she observed an uncontrollable urge to eat chicken nuggets and found herself drawn to visiting the popular chicken restaurant chain, et al., [4]. This means that the little brain could be transformed from one body to another during heart transplantation.

On the other hand, the existence of the little brain on the heart could help to head transplantation and make it possible. In fact, during cutting heads, this little brain plays the main role in decisions and does all activities of a real brain. Until now, some scientists have reported the head transplantation in animals. For example, in 1908, some scientists have tried to graft the head of one dog on an intact second dog; the grafted head showed some reflexes early on but deteriorated quickly, and the animal was killed after a few hours [5]. There were few animal experiments on head transplantation for many years after this [6], [7]. In 2016 some investigators published a review of attempted as well as possible neuroprotection strategies that they said should be researched for potential use in a head transplantation procedure; they discussed various protocols for connecting the vasculature, the use of various levels of hypothermia, the use of blood substitutes, and the possibility of using hydrogen sulfide as a neuroprotective agent [8]. Besides these considerations, one of the interesting claims in head transplantation has been made by Sergio Canavero. He published a protocol and said would make human head transplantation possible [9]. This transplantation is possible if there be a second brain for doing activities of the brain in the absence of the head. This second brain could be a little brain in the heart.

On the other hand, using cells transplantation may save some brain-damaged patients. However, the new head or brain should be formed from cells of the patient his / her self. This may be possible through the reprogramming of cells. During reprogramming, cells can convert to induced pluripotent stems and then these cells produce new specialised cells [9], [10], [11], [12]. In one of the methods, an oocyte can reprogram an adult nucleus into an embryonic state after somatic cell nuclear transfer, so that a new organism can be developed from such cell [13]. In some other methods, some factors (Oct4, Sox2, Klf4, and c-Myc) are used to generate induced pluripotent stem cells (iPSCs) [14]. Using these methods, we can produce new neural stem cells that could produce new neurons and form new neural circuits within the injured or dead brain.

In this paper, we propose two methods for recovering chick embryos dead brains. In both methods, we injected a cell of the patient into an egg

cell (for women, we use their egg cell) and put it in a uterus. After a period of time, neural networks and blood circulatory systems are produced. For a dead brain, we could transplant initial circuits of the initial brain with circuits of the second brain. For an injured brain, we can transplant the initial heart with the second one. This causes the formation of new blood cells in bone marrows and new neural stem cells in the subventricular zone (SVZ) of the brain. New neurons which are emerged in this process, produce new neural circuits and cure injured brain.

The outline of this paper is as follows: In section II, we make a review of connections between the neural network and the circulatory system. In section III, we propose two methods for recovering injured brains. In section IV, we test one of the methods on chick embryos.

## A review of connections between nervous and circulatory systems

Previously, it has been shown that there is a little brain in the heart that can control some activities of the body [1], [2]. In Figure 1, the location and distribution of intrinsic cardiac ganglia are shown [15]. A ganglion is a nerve cell cluster or a group of nerve cell bodies located in the autonomic nervous system and sensory system, mostly outside the central nervous system except for certain nuclei [16]. This system is a bridge between the nervous system and neural network. The origin of these systems is genetic circuits of initial DNAs. These genetic circuits act as the receiver or sender of radio eaves [17].

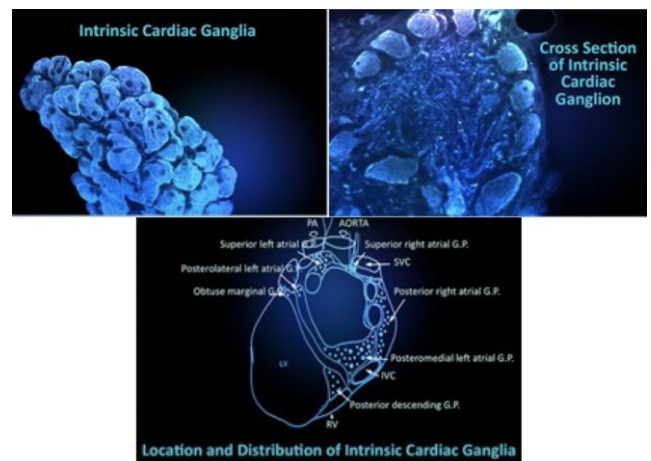


Figure 1: Distributions of neurons in a heart [1], [15]

To transfer information of these genetic circuits, two types of circuits have emerged. First circuits are built of neurons and form a neural network within the brain. Second circuits are formed from vessels of blood cells and form the circulatory system.

There are some connections between the nervous system and the heart which are known as cardiac ganglia. Also, there are some connections between the circulatory system and the neural network in the brain (see Figure 2).

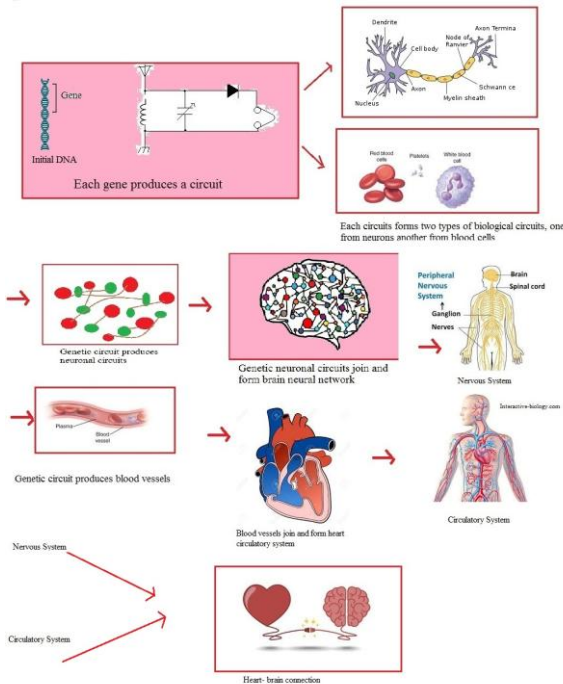


Figure 2: Connections between neural and circulatory systems

## Two methods for recovering injured and dead brains

To recover injured or dead brains, we should replace some hurt circuits with healthy ones. To produce these circuits, we can use of reprogramming. The best way for reprogramming is by removing the nucleus of an egg cell and replacing it by the nucleus of a body cell of a patient. If we put this system under normal conditions like conditions of a uterus, this cell divides into more cells, and an embryo emerges. This embryo has a brain and a heart which are like the initial brain and heart (See Figure 3).

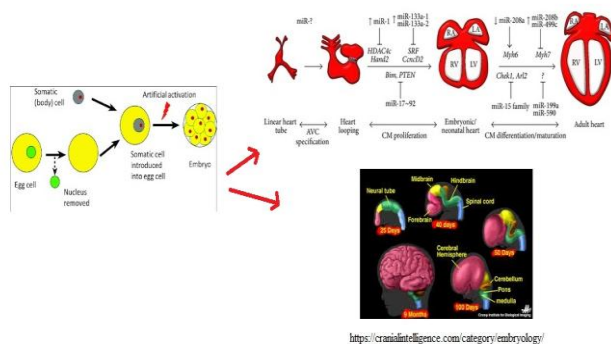


Figure 3: Formation of second heart and brain by introducing a somatic cell into an egg cell

During the formation of the brain in an embryo, first, neural plate and neural tube are emerged [18] (See Figure 4) which can be transplanted with the nervous system of the related patient and pass other stages inside his/her body.

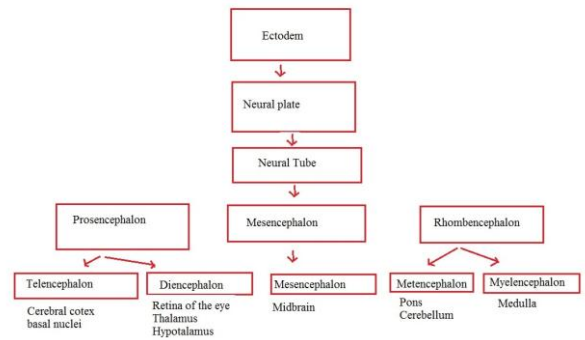


Figure 4: Stages of developments of a brain in a chick embryo [18]

For some brain-dead patients, some parts of initial brain should be replaced by normal and healthy parts of the second brain (See Figure 5).

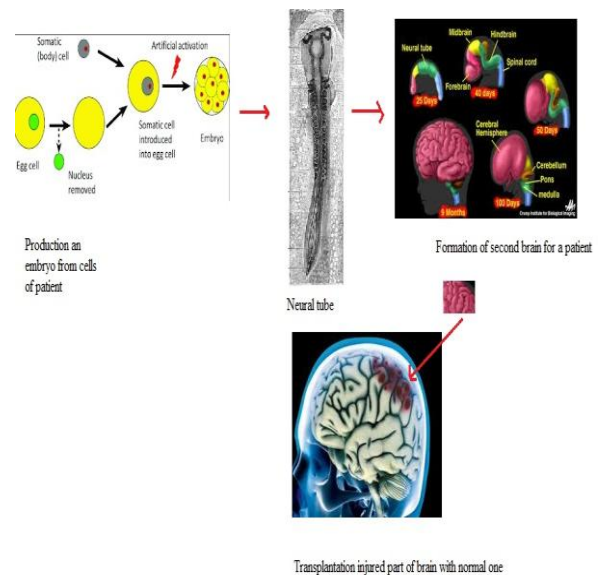


Figure 5: Formation and Transplantation of normal part of the second brain into the injured part of the first brain

Maybe this question arises that what is the fate of memory and personality during this replacement. We can hope that some information is exchanged between circuits of brain and heart, and thus, the initial heart has a copy of memory in its neural system. After replacing neural circuits of the dead brain with new ones, this memory can be transformed into the brain. For patients who their SVZ part of the brain isn't hurt and is healthy, one can transplant initial heart with the heart of related embryo. In these conditions, some new blood cells have emerged in bone marrows. These new cells reach the SVZ and communicate with neural stem cells. Consequently, some new neurons have

emerged which produce neural circuits and recover brain (See Figure 6).

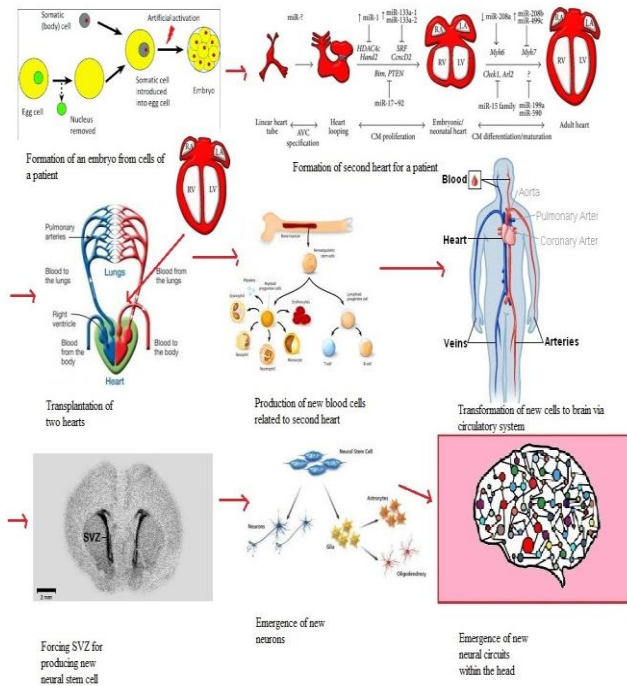


Figure 6: Emergence of new neural circuits after transplantation of second heart into an initial one

### Testing the model for chick embryos

To observe the effects of transplantation of two hearts on neural systems, we can use of chick embryos. First, we incubate fertilised eggs for 58 h. Then, we break them and pour them in a tube or vessel of a shell-less culture system. In this system, similar to [19], we apply a 450 ml polystyrene plastic cup as the pod for the culture vessel. We also make a 1-1.5 cm diameter hole in the side of the cup approximately 2 cm from the bottom and plug the hole with a cotton pledget as a filter.

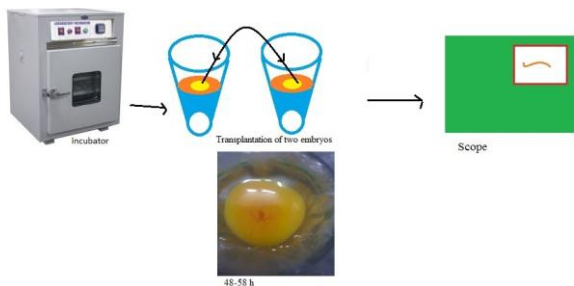


Figure 7: Transplantation of two embryos

We insert a 2 mm diameter plastic tube through the space between the pledget and the hole to provide an oxygen supply. We add an aqueous solution (40 ml) of benzalkonium chloride to the cup.

We form a polymethylpentene film into a concave shape, carefully avoiding wrinkles and installed as an artificial culture vessel in the pod. Finally, we place a polystyrene plastic cover on top of the culture vessel [19]. In one of the vessels, we put normal embryo, and in another, we try to connect two embryos from their hearts. We put two types of vessels in an incubator (see Figure 7).

We connect two systems to the scope and measure related currents. We observe that there is a significant difference between radiated waves of neurons within a normal vessel and vessel, including two connected embryos (See Figure 8). This shows that transplantation of two hearts has a direct effect on the formation of neural circuits.

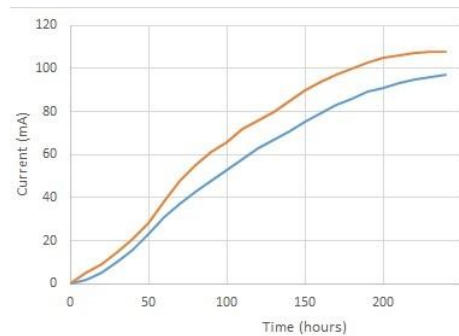


Figure 8: Comparing currents which are emerged by the neural system of a chick embryo (blue colour) with currents of two interacting embryos (red colour)

### Conclusion

In this paper, we have shown that there is a direct relation between the neural network and the blood circulatory system. Both of them are emerged to transfer information of initial genes in an initial stem cell. In fact, each gene acts as the receiver or sender of waves and produce two types of circuits, one related to the neural circuit and another related to the blood circuit. These circuits exchange information with each other through some connections. These connections are some neurons within the heart and some vessels with the head. This may help us to introduce some methods for recovering dead and injured brains. In these methods, we inject a cell of a patient into a bare egg cell and put this system in a uterus. After some time, two new neural and circulatory systems emerge. Then, we have two ways. In one way, we can transplant injured parts of the initial brain with some neural circuits of the second brain. In the second way, we can transplant the initial heart of a patient with a second heart of embryo. In these conditions, bone marrows produce new stem blood cells and cause to produce new blood cells. These blood cells move along the circulatory system and reach to SVZ part of brain. Then, SVZ produce some new neurons related to the second heart and



create new neural circuits. These circuits are replaced with ruined circuits and recover dead brain. We have tested the model in chick embryos and shown that transplantation has a direct effect on neural circuits.

## References

1. Armour JA. The little brain on the heart. *Cleve Clin J Med*. 2007; 74(1):S48-51. [https://doi.org/10.3949/ccjm.74.Suppl\\_1.S48](https://doi.org/10.3949/ccjm.74.Suppl_1.S48) PMID:17455544
2. Armour JA. Potential clinical relevance of the 'little brain' on the mammalian heart. *Exp Physiol*. 2015; 100(4):348-353.
3. Campos ID, Pinto V, Sousa N, Pereira VH. A brain within the heart: A review on the intracardiac nervous system. *Journal of molecular and cellular cardiology*. 2018; 119:1-9. <https://doi.org/10.1016/j.yimcc.2018.04.005> PMID:29653111
4. Pearsall, Paul. *The Heart's Code: Tapping the wisdom and power of our heart energy*. New York; Broadway Books, 1999.
5. Lamba N, Holsgrove D, Broekman ML. The history of head transplantation: a review. *Acta Neurochirurgica*. 2016; 158(12):2239-2247. <https://doi.org/10.1007/s00701-016-2984-0> PMID:27738901 PMCID:PMC5116034
6. Furr A, Hardy MA, Barret JP, Barker JH. Surgical, ethical, and psychosocial considerations in human head transplantation. *International journal of Surgery*. 2017; 41:190-5. <https://doi.org/10.1016/j.ijsu.2017.01.077> PMID:28110028 PMCID:PMC5490488
7. Čartolovni A, Spagnolo AG. Ethical considerations regarding head transplantation. *Surgical Neurology International*. 2015; 6(1):103. <https://doi.org/10.4103/2152-7806.158785> PMID:26110084 PMCID:PMC4476134
8. Ren X, Orlova EV, Maevsky EI, Bonicalzi V, Canavero S. Brain protection during cephalosomatic anastomosis. *Surgery*. 2016; 160(1):5-10. <https://doi.org/10.1016/j.surg.2016.01.026> PMID:27143608
9. Canavero S. HEAVEN: The head anastomosis venture Project outline for the first human head transplantation with spinal linkage (GEMINI). *Surgical Neurology International*. 2013; 4(1):S335-42. <https://doi.org/10.4103/2152-7806.113444> PMID:24244881 PMCID:PMC3821155
10. Gurdon JB. The developmental capacity of nuclei taken from intestinal epithelium cells of feeding tadpoles. *Journal of Embryology and Experimental Morphology*. 1962; 10:622-40.
11. Takahashi K, Yamanaka S. Induction of pluripotent stem cells from mouse embryonic and adult fibroblast cultures by defined factors. *cell*. 2006; 126(4):663-76. <https://doi.org/10.1016/j.cell.2006.07.024> PMID:16904174
12. Baker M. Adult cells reprogrammed to pluripotency, without tumors. *Nature Reports Stem Cells*. 2007. <https://doi.org/10.1038/stemcells.2007.124>
13. Hochedlinger K, Jaenisch R. Nuclear reprogramming and pluripotency. *Nature*. 2006; 441(7097):1061-7. <https://doi.org/10.1038/nature04955> PMID:16810240
14. Paull D, Sevilla A, Zhou H, Hahn AK, Kim H, Napolitano C, Tsankov A, Shang L, Krumholz K, Jagadeesan P, Woodard CM. Automated, high-throughput derivation, characterization and differentiation of induced pluripotent stem cells. *Nature methods*. 2015; 12(9):885-92. <https://doi.org/10.1038/nmeth.3507> PMID:26237226
15. <https://www.heartmath.org/our-heart-brain/>.
16. Brodal P. *The Central Nervous System*. Oxford University Press. In the CNS, such a group is called a nucleus and in the peripheral nervous system (PNS), a ganglion, 2010:5.
17. Sepehri A. A mathematical model for DNA. *Int J Geom Methods Mod. Phys*. 2017; 14:1750152. <https://doi.org/10.1142/S0219887817501523>
18. Estomih Mtui; Gregory Gruener (2006). *Clinical Neuroanatomy and Neuroscience*. Philadelphia: Saunders, 2006:1.
19. Tahara Y, Obara K. A Novel Shell-less Culture System for Chick Embryos Using a Plastic Film as Culture Vessels. *Journal of Poultry Science*. 2014; 51(3):307-312. <https://doi.org/10.2141/jpsa.0130043>
20. Sepehri A, Fioranelli M, Rocca MG, Shoorvazi S. The role of entropic penalties of circular DNA assembly in spectroscopy and imaging. *J Theor Appl Phys*. 2019. <https://doi.org/10.1007/s40094-019-0321-8>

## New Trends in Cutaneous Melanoma Surgery

Jacopo Scala<sup>1</sup>, Aleksandra Vojvodic<sup>2</sup>, Petar Vojvodic<sup>3</sup>, Tatjana Vlasovic-Jovicevic<sup>3</sup>, Zorica Peric-Hajzler<sup>4</sup>, Dusica Matovic<sup>4</sup>, Sanja Dimitrijevic<sup>5</sup>, Jovana Vojvodic<sup>3</sup>, Goran Sijan<sup>6</sup>, Nenad Stepic<sup>7</sup>, Uwe Wollina<sup>8</sup>, Michael Tirant<sup>1</sup>, Nguyen Van Thuong<sup>9</sup>, Massimo Fioranelli<sup>10\*</sup>, Torello Lotti<sup>11</sup>

<sup>1</sup>University G. Marconi, Rome, Italy; <sup>2</sup>Department of Dermatology and Venereology, Military Medical Academy, Belgrade, Serbia; <sup>3</sup>Clinic for Psychiatric Disorders "Dr. Laza Lazarevic", Belgrade, Serbia; <sup>4</sup>Military Medical Academy, Belgrade, Serbia; <sup>5</sup>Department of Gynecology, Military Medical Academy, Belgrade, Serbia; <sup>6</sup>Clinic for Plastic Surgery and Burns, Military Medical Academy, Belgrade, Serbia; <sup>7</sup>Chief of Clinic for Plastic Surgery and Burns, Military Medical Academy, Belgrade, Serbia; <sup>8</sup>Department of Dermatology and Allergology, Städtisches Klinikum Dresden, Dresden, Germany; <sup>9</sup>Vietnam National Hospital of Dermatology and Venereology, Hanoi, Vietnam; <sup>10</sup>Department of Nuclear Physics, Sub-nuclear and Radiation, G. Marconi University, Rome, Italy; <sup>11</sup>Department of Dermatology, University of G. Marconi, Rome, Italy

### Abstract

The main surgical treatment for melanoma consists in wide surgical excision of the primary lesion and the sentinel node but in recent times management of melanoma is rapidly evolving with the introduction of new systemic therapies, like BRAF inhibitors, MEK inhibitors and antibodies anti-PD-1 that show good results in controlling even advanced stages of the disease. This review aims to present data for the optimal surgical management of patients with malignant melanoma.

**Citation:** Scala J, Vojvodic A, Vojvodic P, Vlasovic-Jovicevic T, Peric-Hajzler Z, Matovic D, Dimitrijevic S, Vojvodic J, Sijan G, Stepic N, Wollina U, Tirant M, Thuong NV, Fioranelli M, Lotti T. New Trends in Cutaneous Melanoma Surgery. Open Access Maced J Med Sci. 2019 Sep 30; 7(18):3090-3092. <https://doi.org/10.3889/oamjms.2019.828>

**Keywords:** Cutaneous; Melanoma; Surgery

**\*Correspondence:** Massimo Fioranelli. Department of Nuclear Physics, Sub-nuclear and Radiation, G. Marconi University, Rome, Italy. E-mail: [massimo.fioranelli@gmail.com](mailto:massimo.fioranelli@gmail.com)

**Received:** 12-Jul-2019; **Revised:** 08-Aug-2019; **Accepted:** 09-Aug-2019; **Online first:** 14-Sep-2019

**Copyright:** © 2019 Jacopo Scala, Aleksandra Vojvodic, Petar Vojvodic, Tatjana Vlasovic-Jovicevic, Zorica Peric-Hajzler, Dusica Matovic, Sanja Dimitrijevic, Jovana Vojvodic, Goran Sijan, Nenad Stepic, Uwe Wollina, Michael Tirant, Nguyen Van Thuong, Massimo Fioranelli, Torello Lotti. This is an open-access article distributed under the terms of the Creative Commons Attribution-NonCommercial 4.0 International License (CC BY-NC 4.0)

**Funding:** This research did not receive any financial support

**Competing Interests:** The authors have declared that no competing interests exist

## Introduction

Surgical removal was the mainstay of therapy in early melanoma, and historically there has been only a marginal role for surgery in managing patients with regional or distant metastases, even if some Authors suggested that metastasectomy could improve survival in stage IV melanoma if compared to non-surgical therapy [1]. In present times management of melanoma is rapidly evolving with the introduction of new systemic therapies, like BRAF inhibitors, MEK inhibitors and antibodies anti-PD-1 that show good results in controlling even advanced

stages of the disease [2], [3]. It's easy to forecast that new treatment algorithms will be developed to utilise all new drugs, but there's still much to debate about the role of surgical treatment in combination with the most recent discoveries in biological therapies.

## Management of primary lesion

The main surgical treatment for invasive malignant melanoma consists of complete surgical

excision and removal and examination of the first draining lymph node possibly affected by metastatic disease. Surgical margins to be removed are based on the maximal melanoma Breslow thickness of the melanoma [4]. Usually, all suspicious pigmented lesions should be removed with a clear clinical margin of least 2mm but not exceeding 5 mm not to damage the lymphatic drainage to be assessed by a later SLNB. Usually, the excision should go through the skin and subcutaneous tissue and stop to the fascia/periosteum/ perichondrium, only for suspected melanoma in situ surgical excision could stop at the superficial subcutaneous tissue [5]. Partial biopsies are to be avoided mainly to not under stage the lesion.

For melanoma in situ, according to a late expert consensus statement, an excision margin of 5 mm is considered sufficient to have a radical treatment. However, more recent data recommends excisions up to 9 mm to obtain clear histological margins [5], [6]. There is no indication to widen surgical margins if histological free margins have already been achieved.

For invasive melanomas with less than 1 mm thickness, a 1 cm surgical margin is considered a sufficient margin according to three randomised control trials (RCTs) [7], [8], [9], [10]. For intermediate and thick melanomas, many RCTs comparing narrow (1 cm) and wide excision (up to 5 cm) have been published. A recent meta-analysis found no difference in overall survival (HR 1.09; 95% CI 0.98 – 1.22;  $p = 0.1$ ) between patients treated with narrow or wide excision, nor in loco-regional recurrence (HR 1.10; 95% CI 0.96 – 1.26;  $p = 0.2$ ). However, in a subgroup analysis including four trials only, reporting on melanoma-specific survival wide excision was favored HR 1.17 (95% CI 1.03 – 1.34;  $p = 0.02$ ) [11], [12], [13].

Surgical excision can in almost every case be performed under local anaesthesia and local flaps should be performed to cover after wide excision only if the surgeon is confident that histologically free margins have been achieved.

## Sentinel lymph node biopsy and Complete lymph node dissection

Sentinel node biopsy (SLNB) is the surgical procedure where the sentinel lymph node is identified and then removed using a radioactive tracer or a biological pigment and could be made even in small hospitals not needing advanced technological resources. SLNB became popular in the 1990s because it was supposed that with lymph node metastases a block dissection of their nodes would have improved survival but the two most important long-term prospective randomised trials of SLNB (MSLT1 and MSLT2) showed that SLNB and

subsequent completion lymphadenectomy does not improve 10-year melanoma-specific survival [14], [15] nevertheless the treatment is still offered because it can detect occult disease and improve staging and prognosis [16]. The complication rate associated with SLNB is approximately 10% [14]. SNB has a false negative rate of approximately 10 – 20% [17] A positive SN has been found in approximately 5% of melanomas  $\leq 1$  mm thickness and in approximately 14 – 20% in intermediate-thickness melanomas [18], [19], [20] thus SLNB may be considered for patients with melanomas with a thickness from 0.8 to 1.0 mm or less than 0.8 mm thickness with ulceration, classified as T1b lesion, or for intermediate-thickness melanomas as reported in AJCC 8th edition [18]. For melanomas  $> 4$  mm thickness, SLNB could be proposed only for staging because for potential disease control its therapeutic benefit is perhaps more limited. In certain cases of very thick melanomas, imaging could archive an appropriate staging, and thus surgery could be avoided [21].

Complete lymph node dissection (CLND) was considered a cornerstone in the management of melanoma patients with a positive SLNB both to prevent the melanoma from spreading and to attain accurate staging [22]. Two RCTs have been published: DeCOG and MSLT-2 comparing the CLND with observation after positive SNB. Even if DeCOG was stopped prematurely and the study finished underpowered, it didn't find any differences in survival. The MSLT-2 meta-analysis compared immediate CLND with observation / delayed CLND and also showed no survival benefit from CLND. However, melanoma-specific survival was higher after immediate CLND compared with delayed CLND in patients with nodal metastasis (HR = 0.63, 95% CI = 0.35 – 0.74,  $p = 0.0004$ ) [15], [23].

Review studies reported a complication rate after CLND variable between 24%-37% and a worse quality of life after CLND compared with SNB only so appears to be important to avoid completion lymphadenectomy to prevent unnecessary complications [15], [24], [25].

## Conclusions

Survival for patients with invasive melanoma still depends mostly on early diagnosis and surgery maintain his undisputed therapeutic role in small and intermediate lesions.

The role of surgery remains to be determined with advanced lesions and lymph nodal metastasis because is unclear if there is a benefit with node dissection compared with observation in combination with adjuvant treatment such as BRAF / MEK inhibition or PD-1 inhibition.

Treatment for invasive melanoma confirms to be a complex and multidisciplinary task that require oncologists and surgeons cooperation to guide treatment decisions.

## References

- Wasif N, Bagaria SP, Ray P, Morton DL. Does metastasectomy improve survival in patients with Stage IV melanoma? A cancer registry analysis of outcomes. *J Surg Oncol*. 2011; 104(2):111-115. <https://doi.org/10.1002/jso.21903> PMID:21381040  
PMCID:PMC3199373
- Tchernev G, Chokoeva AA, Wollina U, Lotti T. De novo congenital malignant melanoma: whats new in diagnosis and treatment? *Dermatol Ther*. 2016; 29(1):13-4. <https://doi.org/10.1111/dth.12279> PMID:26279460
- França K, Lotti T. Stress coping strategies for the optimal treatment of melanoma. *Dermatol Ther*. 2017; 30(1). <https://doi.org/10.1111/dth.12421> PMID:27592687
- Breslow A. Thickness, cross-sectional areas and depth of invasion in the prognosis of cutaneous melanoma. *Ann Surg*. 1970; 172(5): 902-8. <https://doi.org/10.1097/00000658-197011000-00017> PMID:5477666 PMCID:PMC1397358
- Kunishige JH, Brodland DG, Zitelli JA. Margins for standard excision of melanoma in situ. *J Am Acad Dermatol*. 2013; 69(1):164. <https://doi.org/10.1016/j.jaad.2013.01.040> PMID:23768291
- Sober AJ. Diagnosis and management of early melanoma: a con- sensus view. *Semin Surg Oncol*. 1993; 9(3):194-7.
- Managing melanoma. National Institute for Health and Care Excellence, 2018.
- Malignant Melanom. Swedish National Treatment Guidelines. Regional Cancer Centrum, 2017.
- Work G, Swetter SM, Tsao H, Bichakjian CK, Curiel-Lewandrowski C, Elder DE, et al. Guidelines of care for the management of primary cutaneous melanoma. *J Am Acad Dermatol*. 2018.
- Sladden MJ, Balch C, Barzilay DA, Berg DA, Freiman A, Handiside T, et al. Surgical excision margins for primary cutaneous melanoma. *Cochrane Database Syst Rev*. 2009; (4):CD004835. <https://doi.org/10.1002/14651858.CD004835.pub2> PMID:19821334
- Wheatley K, Wilson JS, Gaunt P, Marsden JR. Surgical excision margins in primary cutaneous melanoma: a meta-analysis and Bayesian probability evaluation. *Cancer Treat Rev*. 2016; 42:73- 81. <https://doi.org/10.1016/j.ctrv.2015.10.013> PMID:26563920
- Balch CM, Soong SJ, Smith T, Ross MI, Urist MM, Karakousis CP, et al. Long-term results of a prospective surgical trial comparing 2 cm vs. 4 cm excision margins for 740 patients with 1-4 mm melanomas. *Ann Surg Oncol*. 2001; 8(2):101-8. <https://doi.org/10.1007/s10434-001-0101-x> PMID:11258773
- Hayes AJ, Maynard L, Coombes G, Newton-Bishop J, Timmons M, Cook M, et al. Wide versus narrow excision margins for high- risk, primary cutaneous melanomas: long-term follow-up of surviv- al in a randomized trial. *Lancet Oncol*. 2016; 17(2):184-92. [https://doi.org/10.1016/S1470-2045\(15\)00482-9](https://doi.org/10.1016/S1470-2045(15)00482-9)
- Morton DL, Thompson JF, Cochran AJ, et al. Final trial report of sentinel-node biopsy versus nodal observation in melanoma. *N Engl J Med*. 2014; 370(7):599-609. <https://doi.org/10.1056/NEJMoa1310460> PMID:24521106  
PMCID:PMC4058881
- Faries MB, Thompson JF, Cochran AJ, et al. Completion dissection or observation for sentinel-node metastasis in melanoma. *N Engl J Med*. 2017; 376(23):2211-22. <https://doi.org/10.1056/NEJMoa1613210> PMID:28591523  
PMCID:PMC5548388
- Leiter U, Stadler R, Mauch C, Hohenberger W, Brockmeyer N, Berking C, German Dermatologic Cooperative Oncology Group (DeCOG), et al. Complete lymph node dissection versus no dissection in patients with sentinel lymph node biopsy positive melanoma (DeCOG-SLT): a multi-centre, randomised, phase 3 trial. *Lancet Oncol*. 2016; 17(6):757e67. [https://doi.org/10.1016/S1470-2045\(16\)00141-8](https://doi.org/10.1016/S1470-2045(16)00141-8)
- Lee DY, Huynh KT, Teng A, Lau BJ, Vitug S, Lee JH, et al. Predictors and survival impact of false-negative sentinel nodes in melanoma. *Ann Surg Oncol*. 2016; 23(3):1012-8. <https://doi.org/10.1245/s10434-015-4912-6> PMID:26586498  
PMCID:PMC4984404
- Wong SL, Faries MB, Kennedy EB, Agarwala SS, Akhurst TJ, Ariyan C, et al. Sentinel lymph node biopsy and management of regional lymph nodes in melanoma: American Society of Clinical Oncology and Society of Surgical Oncology Clinical Practice Guideline Update. *J Clin Oncol*. 2018; 36(4):399-413. <https://doi.org/10.1200/JCO.2017.75.7724> PMID:29232171
- Bartlett EK, Peters MG, Blair A, Etherington MS, Elder DE, Xu XG, et al. Identification of patients with intermediate thickness melanoma at low risk for sentinel lymph node positivity. *Ann Surg Oncol*. 2016; 23(1):250-6. <https://doi.org/10.1245/s10434-015-4766-y> PMID:26215202 PMCID:PMC4697873
- Han D, Zager JS, Shyr Y, Chen H, Berry LD, Iyengar S, et al. Clinicopathologic predictors of sentinel lymph node metastasis in thin melanoma. *J Clin Oncol*. 2013; 31(35):4387-93. <https://doi.org/10.1200/JCO.2013.50.1114> PMID:24190111
- Forschner A, Olthof SC, Guckel B, Martus P, Vach W, la Fougere C, et al. Impact of (18)F-FDG-PET/CT on surgical management in patients with advanced melanoma: an outcome based analysis. *Eur J Nucl Med Mol Imaging*. 2017; 44(8):1312-8. <https://doi.org/10.1007/s00259-017-3674-8> PMID:28315947
- Fioranelli M, Roccia MG, Pastore C, Aracena CJ, Lotti T. Completion dissection or observation for sentinel-node metastasis in melanoma. *Dermatol Ther*. 2017; 30(6). <https://doi.org/10.1111/dth.12544> PMID:28836714
- Delgado AF, Delgado AF. Complete lymph node dissection in melanoma: a systematic review and meta-analysis. *Anticancer Res*. 2017; 37(12):6825-9. <https://doi.org/10.21873/anticancerres.12143>
- Moody JA, Botham SJ, Dahill KE, Wallace DL, Hardwicke JT. Complications following completion lymphadenectomy versus therapeutic lymphadenectomy for melanoma - a systematic review of the literature. *Eur J Surg Oncol*. 2017; 43(9):1760-7. <https://doi.org/10.1016/j.ejso.2017.07.003> PMID:28756017
- de Vries M, Hoekstra HJ, Hoekstra-Weebers JE. Quality of life after axillary or groin sentinel lymph node biopsy, with or without completion lymph node dissection, in patients with cutaneous melanoma. *Ann Surg Oncol*. 2009; 16(10):2840-7. <https://doi.org/10.1245/s10434-009-0602-6> PMID:19639366  
PMCID:PMC2749179

# Anetoderma Schweninger-Buzzi: Two Case Reports

Uwe Wollina<sup>1\*</sup>, Diana Mühle<sup>1</sup>, Torello Lotti<sup>2</sup>, Aleksandra Vojvodic<sup>3</sup>

<sup>1</sup>Department of Dermatology and Allergology, Städtisches Klinikum Dresden, Academic Teaching Hospital, Dresden, Germany; <sup>2</sup>Department of Dermatology, University of Rome "G. Marconi", Rome, Italy; <sup>3</sup>Military Medical Academy of Belgrade, Belgrade, Serbia

## Abstract

**Citation:** Wollina U, Mühle D, Lotti T, Vojvodic A. Anetoderma Schweninger-Buzzi: Two Case Reports. Open Access Maced J Med Sci. 2019 Sep 30; 7(18):3093-3095.  
<https://doi.org/10.3889/oamjms.2019.560>

**Keywords:** Anetoderma; Connective tissue disorders; Chronic infections; Prothrombotic conditions; Histopathology

**\*Correspondence:** Uwe Wollina, Department of Dermatology and Allergology, Städtisches Klinikum Dresden, Academic Teaching Hospital, Dresden, Germany. E-mail: [Uwe.Wollina@klinikum-dresden.de](mailto:Uwe.Wollina@klinikum-dresden.de)

**Received:** 16-Apr-2019; **Revised:** 19-Jun-2019;  
**Accepted:** 20-Jun-2019; **Online first:** 19-Aug-2019

**Copyright:** © 2019 Uwe Wollina, Diana Mühle, Torello Lotti, Aleksandra Vojvodic. This is an open-access article distributed under the terms of the Creative Commons Attribution-NonCommercial 4.0 International License (CC BY-NC 4.0)

**Funding:** This research did not receive any financial support

**Competing Interests:** The authors have declared that no competing interests exist

**BACKGROUND:** Anetodermas are rare disorders of connective tissue with a focal loss of elastic fibres in the upper and mid dermis. Two types are separated, inflammatory and non-inflammatory.

**CASE REPORTS:** We report two cases of acquired anetoderma Schweninger-Buzzi type. This non-inflammatory subtype is characterised by skin-coloured or whitish atrophic sac-like protrusions of trunk skin in adult males. Chronic infections and autoimmune disorders have been excluded. The diagnosis had been confirmed by characteristic histopathology.

**CONCLUSIONS:** Anetodermas are symptomless disorders. They can be easily overlooked. The knowledge of such conditions is of importance to identify patients with a risk of thromboembolic events and underlying infections or autoimmune connective tissue diseases.

## Introduction

Cutaneous elastic tissue anomalies are classified as those with increased or abnormal elastic tissue and those with a loss of elastic tissue. To the first group belong disorders such as nevus elasticus, pseudoxanthoma elasticum, or elastosis perforans serpiginosa. Papular elastorrhexis, mid dermal elastolysis and anetoderma fall under the second group [1].

The loss of elastic tissue can be by decreased production of elastic fibers, increased activity of elastase and matrix metalloproteinases, activation of phagocytosis of elastic fibres by macrophages or a combination of these [2]. Here we report two cases of the rare anetoderma Schweninger-Buzzi type in two adult males.

## Case Reports

**Case 1:** A 48-year old male was referred from the rheumatologist to exclude scleroderma. The patient reported the development of asymptomatic skin lesions on his trunk. He was otherwise healthy and had no medical drug therapy.

On examination, we observed more than 100 skin-coloured herniated sac-like lesions on the trunk arranged in Langer's lines. The maximum diameter was about 1 cm. There was no erythema, no scaling, no pruritus (Figure 1).

Laboratory findings, including antinuclear antibodies (ANA), anti-cardiolipin antibodies, and Borrelia serology, were normal or negative.

A skin biopsy was obtained for histology. Narrowed collagen fibres were noted in the whole

dermis. In the upper dermis, there was a focal loss of elastic fibres. The skin appendages were preserved. An inflammatory infiltrate completely missing.

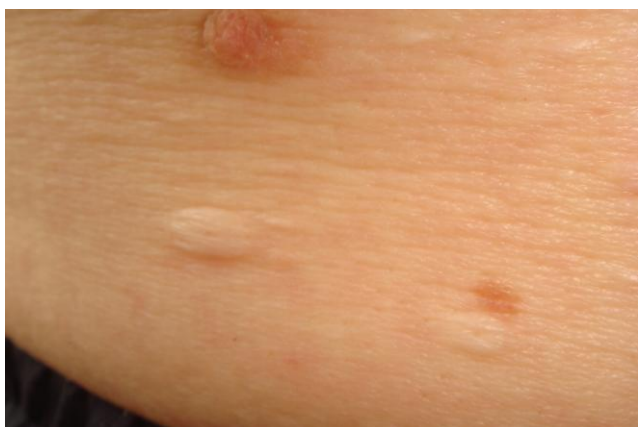

Figure 1: Anetoderma (case #1)

**Case 2:** A 33-year-old male presented with multiple asymptomatic lesions on the back. His medical history was unremarkable. He did not use any medical drugs.

On examination, we observed skin-coloured sac-like herniated lesions with a size of up to 7 mm arranged along Langer's lines (Figure 2).

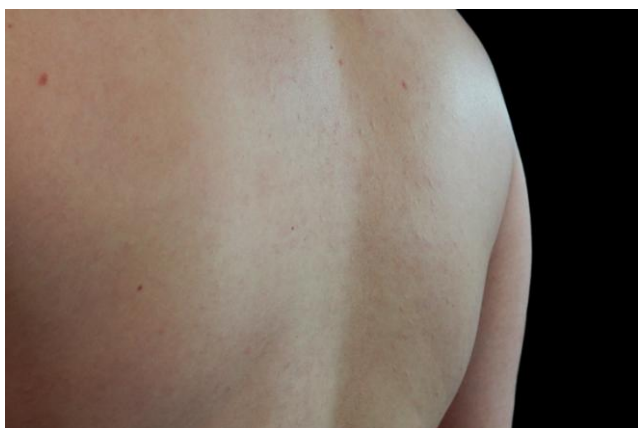

Figure 2: Anetoderma (case #2)

Laboratory investigations demonstrated antimitochondrial antibodies 1:320, mild eosinophilia of 9.6%. *Borrelia* serology and ANA screening remained negative.

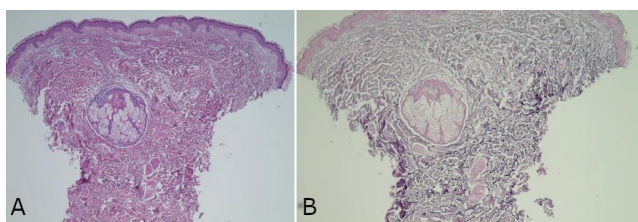


Figure 3: Histopathology of anetoderma Schweningen-Buzzi, case #2; A) Hematoxylin-eosin; B) elastica stain (x 4)

A skin biopsy revealed the same pattern as in the first patient (Figure 3).

In both patients, the diagnosis of anetoderma Schweningen-Buzzi type was confirmed by clinical appearance and histologic findings.

## Discussion

Anetoderma is a rare disease. It belongs to the acquired connective tissue disorders and is characterised by localised skin atrophy and loss of elastic fibres [3]. In electron microscopy, fibre fragments have been described [4].

Traditionally, anetoderma has been differentiated into an inflammatory subtype Jadassohn-Pellizari with prodromal urticaria-like lesions, followed by erythematous atrophic lesions [5]. The type Schweningen-Buzzi develops spontaneously without inflammation [6]. Lesions are either skin-coloured or whitish [7]. Hereditary antoderma is extremely rare [8].

Primary anetoderma can be a precursor of autoimmune disorders and a marker for prothrombotic conditions like anti-phospholipid syndrome [7], [9], [10]. Secondary anetoderma has been reported after granuloma annulare [11], secondary syphilis [12], pilomatricoma [13], and bullous Sweet syndrome [14]. Acquired anetoderma following folliculitis is known in patients with Down syndrome [15].

Infection with *Borrelia afzelii* has been considered a possible cause of secondary anetoderma as well [16], [17]. Since Lyme borreliosis is common in Southern Germany [18], it was of particular importance to rule out *Borrelia* infection in our cases (Table 1).

Table 1: Anetoderma – underlying pathologies

Type	Pathologies
Primary anetoderma	Autoimmune inflammation (connective tissue disorders) Thromboembolic events (anti-phospholipid syndrome, anti-thrombin III deficiency)
Secondary anetoderma	Infectious diseases (Lyme disease, syphilis, HIV, leprosy) Inflammatory disorders (granuloma annulare, Sweet Syndrome, Stevens-Johnson syndrome, folliculitis) Drug induced (penicillamine, penicillin) Metabolic disorders (Wilson's disease) Tumor-associated (Reed syndrome, pilomatricoma, cutaneous lymphomas, xanthogranuloma)

Differential diagnoses include morphea, cutis laxa, pseudoxanthoma elasticum-like papillary elastolysis, lichen sclerosus et atrophicus, lepromatous leprosy, and chalazodermic amyloidosis [1], [19], [20].

Treatment is dependent upon underlying

pathologies. Infectious disorders need antibiotics; inflammatory disorders require immune-modulating drugs and tumours warrant surgery, radiotherapy or anti-tumour drugs. Successful treatment of the underlying pathology may result in the prevention of the development of additional lesions. Once anetoderma has developed, there is no specific drug therapy for the condition available. Corticosteroids, dapsone, colchicine, aminocaproic acid, vitamin E, and niacin yielded meager improvement. Peels and radiofrequency devices have occasionally been employed [21]. Laser therapy has been used to improve the appearance by stimulation of the production of elastic fibres and a decrease in fibre fragmentation after combined 595 nm pulsed-dye laser plus 1550 nm non-ablative fractionated laser [22] and 10,600 nm CO<sub>2</sub> laser [23] [24]. In analogy to depressed scars, dermal filler injections may have a lifting effect [25].

## References

- Andrés-Ramos I, Alegría-Landa V, Gimeno I, Pérez-Plaza A, Rütten A, Kutzner H, Requena L. Cutaneous Elastic Tissue Anomalies. *Am J Dermatopathol*. 2019; 41(2):85-117.
- Persechino S, Caperci C, Cortesi G, Persechino F, Raffa S, Pucci E, Tammaro A, Torrisi MR. Anetoderma: evidence of the relationship with autoimmune disease and a possible role of macrophages in the etiopathogenesis. *Int J Immunopathol Pharmacol*. 2011; 24(4):1075-7. <https://doi.org/10.1177/039463201102400425> PMID:22230413
- Venencie P, Winkelmann R, Moore B. Anetoderma: clinical findings, associations, and long-term follow-up evaluations. *Arch Dermatol*. 1984; 120(8):1032-9. <https://doi.org/10.1001/archderm.1984.01650440062021> PMID:6465909
- Göebel-Pinto JB, de Almeida HL Jr, de Castro LAS, Rocha NM. Ultrastructural aspects of primary anetoderma. *J Cutan Pathol*. 2017; 44(9):786-9. <https://doi.org/10.1111/cup.12978> PMID:28605051
- Fabbri P, Lotti T, Panconesi E. A case of Pellizzari-Jadasshon anetoderma. Clinical and immunopathologic study. *G Ital Dermatol Venereol*. 1985; 120(5):333-7.
- Casigliani R, Difonzo EM, Ganucci Cancellieri GA, Lotti T. A case of Schweningen-Buzzi anetoderma. *G Ital Dermatol Venereol*. 1988; 123(3):83-5.
- Grandi V, Mori M, Mariotti G, Gunnella S, Maio V. Primary idiopathic anetoderma. *G Ital Dermatol Venereol*. 2016; 151:130-1.
- Fukayama M, Miyagaki T, Akamata K, Suzuki S, Tanaka M, Sato S. Japanese familial anetoderma: A report of two cases and review of the published work. *J Dermatol*. 2018; 45(12):1459-62. <https://doi.org/10.1111/1346-8138.14672> PMID:30320485
- Wollina U. Primary anetoderma of Schweningen-Buzzi type - a cutaneous sign for prothrombotic stage. *Kosmet Med*. 2015; 36:32-3.
- Morales-Raya C, Maroñas-Jiménez L, Burillo-Martínez S, Ortiz-Romero PL. Primary anetoderma: A cutaneous marker of prothrombotic states. *Med Clin (Barc)*. 2016; 147(8):e47. <https://doi.org/10.1016/j.medcle.2016.11.001>
- Kang HS, Paek JO, Lee MW, Yu HJ, Kim JS. Anetoderma developing in generalized granuloma annulare in an infant. *Ann Dermatol*. 2014; 26(2):283-5. <https://doi.org/10.5021/ad.2014.26.2.283> PMID:24882997 PMCid:PMC4037695
- Emer J, Roberts D, Sidhu H, Phelps R, Goodheart H. Generalized Anetoderma after Intravenous Penicillin Therapy for Secondary Syphilis in an HIV Patient. *J Clin Aesthet Dermatol*. 2013; 6(8):23-8.
- Chattopadhyay M, Rytina E, Sterling JC, Burrows NP. Anetodermic pilomatricoma in a patient with hypermobility syndrome. *Clin Exp Dermatol*. 2014; 39(2):218-20. <https://doi.org/10.1111/ced.12215> PMID:24313889
- Loyal J, Shagalov DR, Vatanchi M, Glick JB, Ferzli GM, Heilman E, Glick SA. Bullous sweet syndrome healing with prominent secondary anetoderma. *Pediatr Dermatol*. 2018; 35(6):e416-e417. <https://doi.org/10.1111/pde.13641> PMID:30152553
- Fölster-Holst R, Rohrer T, Jung AM. Dermatological aspects of the S2k guidelines on Down syndrome in childhood and adolescence. *J Dtsch Dermatol Ges*. 2018; 16(10):1289-95. <https://doi.org/10.1111/ddg.13665>
- Hofer T, Goldenberger D, Itin PH. Anetoderma and borreliosis: is there a pathogenetic relationship? *Eur J Dermatol*. 2003; 13(4):399-401.
- Bauer J, Leitz G, Palmedo G, Hügel H. Anetoderma: another facet of Lyme disease? *J Am Acad Dermatol*. 2003; 48(5 Suppl):S86-8. <https://doi.org/10.1067/mjd.2003.165> PMID:12734487
- Enkelmann J, Böhmer M, Fingerle V, Siffczyk C, Werber D, Littmann M, Merbecks SS, Helmeke C, Schroeder S, Hell S, Schlotthauer U, Burckhardt F, Stark K, Schielke A, Wilking H. Incidence of notified Lyme borreliosis in Germany, 2013-2017. *Sci Rep*. 2018; 8(1):14976. <https://doi.org/10.1038/s41598-018-33136-0> PMID:30297731 PMCid:PMC6175818
- Razmi TM, Narang T, Chatterjee D, Dogra S, Saikia UN. Lepromatous leprosy masquerading as anetoderma in a boy. *Indian J Dermatol Venereol Leprol*. 2019.
- Hazemann G, Gusdorf L, Mitcov M, Lenormand C, Lipsker D. Multifocal chalaodermic amyloidosis: The concept of immunoglobulinemic elastopathy. *Ann Dermatol Venereol*. 2018; 145(12):777-84. <https://doi.org/10.1016/j.annder.2018.07.021> PMID:30309631
- Emer J, Roberts D, Sidhu H, Phelps R, Goodheart H. Generalized Anetoderma after Intravenous Penicillin Therapy for Secondary Syphilis in an HIV Patient. *J Clin Aesthet Dermatol*. 2013; 6(8):23-8.
- Wang K, Ross NA, Saedi N. Anetoderma treated with combined 595-nm pulsed-dye laser and 1550-nm non-ablative fractionated laser. *J Cosmet Laser Ther*. 2016; 18(1):38-40. <https://doi.org/10.3109/14764172.2015.1039039> PMID:25968163
- Lee SM, Kim YJ, Chang SE. Pinhole carbon dioxide laser treatment of secondary anetoderma associated with juvenile xanthogranuloma. *Dermatol Surg*. 2012; 38(10):1741-3. <https://doi.org/10.1111/j.1524-4725.2012.02535.x> PMID:22861121
- Cho S, Jung JY, Lee JH. Treatment of anetoderma occurring after resolution of Stevens-Johnson syndrome using an ablative 10,600-nm carbon dioxide fractional laser.
- Cho S, Jung JY, Lee JH. Treatment of anetoderma occurring after resolution of Stevens-Johnson syndrome using an ablative 10,600-nm carbon dioxide fractional laser. *Dermatologic Surgery*. 2012; 38(4):677-9. <https://doi.org/10.1111/j.1524-4725.2011.02272.x> PMID:22251221
- Wollina U, Goldman A. Fillers for the improvement in acne scars. *Clin Cosmet Investig Dermatol*. 2015; 8:493-9. <https://doi.org/10.2147/CCID.S86478> PMID:26491364 PMCid:PMC4598204

## DNA Waves and Their Applications in Biology

Massimo Fioranelli<sup>1\*</sup>, Alireza Sepehri<sup>1</sup>, Maria Grazia Roccia<sup>1</sup>, Chiara Rossi<sup>1</sup>, Jacopo Lotti<sup>1</sup>, Petar Vojvodic<sup>2</sup>, Victoria Barygina<sup>3</sup>, Aleksandra Vojvodic<sup>4</sup>, Tatjana Vlaskovic-Jovicevic<sup>2</sup>, Zorica Peric-Hajzler<sup>5</sup>, Dusica Matovic<sup>5</sup>, Jovana Vojvodic<sup>2</sup>, Sanja Dimitrijevic<sup>6</sup>, Goran Sijan<sup>7</sup>, Uwe Wollina<sup>8</sup>, Michael Tirant<sup>9</sup>, Nguyen Van Thuong<sup>10</sup>, Torello Lotti<sup>11</sup>

<sup>1</sup>Department of Nuclear Physics, Sub-nuclear and Radiation, G. Marconi University, Rome, Italy; <sup>2</sup>Clinic for Psychiatric Disorders "Dr. Laza Lazarevic", Belgrade, Serbia; <sup>3</sup>Department of Biomedical Experimental and Clinical Sciences, University of Florence, Florence, Italy; <sup>4</sup>Department of Dermatology and Venereology, Military Medical Academy, Belgrade, Serbia; <sup>5</sup>Military Medical Academy, Belgrade, Serbia; <sup>6</sup>Department of Gynecology, Military Medical Academy, Belgrade, Serbia; <sup>7</sup>Clinic for Plastic Surgery and Burns, Military Medical Academy, Belgrade, Serbia; <sup>8</sup>Department of Dermatology and Allergology, Städtisches Klinikum Dresden, Dresden, Germany; <sup>9</sup>G. Marconi University, Rome, Italy; <sup>10</sup>Vietnam National Hospital of Dermatology and Venereology, Hanoi, Vietnam; <sup>11</sup>Department of Dermatology, University of G. Marconi, Rome, Italy

### Abstract

**Citation:** Fioranelli M, Sepehri A, Roccia MG, Rossi C, Lotti J, Vojvodic P, Barygina V, Vojvodic A, Vlaskovic-Jovicevic T, Peric-Hajzler Z, Matovic D, Vojvodic J, Dimitrijevic S, Sijan G, Wollina U, Tirant M, Van Thuong N, Lotti T. DNA Waves and Their Applications in Biology. Open Access Maced J Med Sci. 2019 Sep 30; 7(18):3096-3100.  
<https://doi.org/10.3889/oamjms.2019.767>

**Keywords:** Quantum Biology; Chick Embryo; DNA Wave; Bacterial DNA

**\*Correspondence:** Massimo Fioranelli. Department of Nuclear Physics, Sub-nuclear and Radiation, G. Marconi University, Rome, Italy. E-mail: [massimo.fioranelli@gmail.com](mailto:massimo.fioranelli@gmail.com)

**Received:** 02-Sep-2019; **Revised:** 14-Sep-2019; **Accepted:** 15-Sep-2019; **Online first:** 11-Sep-2019

**Copyright:** © 2019 Massimo Fioranelli, Alireza Sepehri, Maria Grazia Roccia, Chiara Rossi, Jacopo Lotti, Petar Vojvodic, Victoria Barygina, Aleksandra Vojvodic, Tatjana Vlaskovic-Jovicevic, Zorica Peric-Hajzler, Dusica Matovic, Jovana Vojvodic, Sanja Dimitrijevic, Goran Sijan, Uwe Wollina, Michael Tirant, Nguyen Van Thuong, Torello Lotti. This is an open-access article distributed under the terms of the Creative Commons Attribution-NonCommercial 4.0 International License (CC BY-NC 4.0)

**Funding:** This research did not receive any financial support

**Competing Interests:** The authors have declared that no competing interests exist

**AIM:** In this research, we show that DNA waves have many applications in biology. DNA is formed by the joining of quantum particles like electrons and charged atoms. DNA has different motions during transcription, translation, and replication, in which the charged particles move, accelerate, and emit waves. Thus, DNA could emit quantum waves.

**METHODS:** Two methods are proposed to observe the effect of DNA waves. The first proposed method measures DNA waves emitted by bacteria suspended in the milk. The vessel of milk is placed in the interior of an inductor. One side of the vessel is connected to a generator and another side to a scope. By sending a current to the inductor, an input electromagnetic field is produced. Bacteria interact with the input field, change it and produce new output signals. Using the scope, the output signals are observed and compared with the input signals. The number of DNA waves produced also depends on temperature.

**RESULTS:** At lower temperatures, bacterial replication is less, and fewer DNA waves are produced. Conversely, more bacteria are generated at higher temperatures, and more DNA waves are produced. The second proposed method acquires and images of DNA signals of chick embryos. In this method, a circuit is constructed that consists of a graphene or metal tube, generator, inductor, scope, DNA in the interior of eggs and DNA exterior to the eggs. Magnetic waves pass the interior and exterior DNA as well as the graphene. The DNA is excited and the exciting interior/exterior DNA exchanges waves. Some of these waves interact with electrons in the graphene tube, and a current is generated. Properties of the chick embryo DNA can be explored by analysing changes in the waves that emerge from the eggs.

**CONCLUSION:** It is concluded that DNA waves could be used extensively in imaging and provide for us the exact information about evolutions of DNAs interior of biological systems.

## Introduction

Quantum biology is a field of science that explores the applications of quantum mechanics in biology. Erwin Schrödinger first coined the term "quantum mechanics" in biology and proposed the idea of an "aperiodic crystal" that contains genetic information in its configuration of covalent chemical bonds [1]. Also, he suggested that mutations could be explained by "quantum leaps". The term "quantum biology" was coined by Per-Olov Löwdin for this new

field of science, when he introduced proton tunnelling as another mechanism for DNA mutation [2].

Quantum biology has many applications in the evolution and continuity of life. One application is to propose a model for DNA mutation. This mutation is, in fact, an error in the DNA code, which occurs during the copying of a DNA strand during cell reproduction. A DNA mutation model has been proposed in which a nucleotide may change its form through the process of quantum tunnelling. The changed nucleotide will lose its ability to pair with its original base pair, which will change the structure and order of the DNA strand [3].



This DNA mutation may be produced by exposure to ultraviolet rays and other types of radiation [4].

Another application of quantum biology in biological systems is to explain the mechanisms for vision and the involved scientific process of phototransduction. In this process, a photon is absorbed by a chromophore in a light receptor, which causes photoisomerisation. This change in structure induces a change in the structure of the photoreceptor and the resulting signal transduction pathways that lead to a visual signal [5]. This process is very rapid (< 200 femtoseconds) and has a high yield. Models have been proposed in which quantum effects shape the ground state and excited state potentials to achieve the visual signal [6]. Yet another application of quantum biology involves magnetoreception, in which animals can navigate using the inclination of the Earth's magnetic field [7]. This biological event can be described by the entangled radical pair mechanism in quantum mechanics [8], [9]. Other biological events, such as photosynthesis [10], [11] and enzymatic activity, have been described through the quantum field theory [12], [13].

In addition to these applications, some observations can only be explained by quantum biology. For example, Montagnier and his collaborators argued about the capacity of some bacterial DNA sequences to emit very low-frequency electromagnetic waves when extensively diluted in an aqueous fluid. The authors discussed that the genomic DNA of most pathogenic bacteria includes sequences that can create such signals [14]. Another study by the same group described the experimental conditions under which electromagnetic waves of low frequency can be emitted by dilute aqueous solutions of some bacterial and viral DNAs. Also, the authors observed this transduction process in living human cells exposed to electromagnetic wave irradiation and suggested a quantum field theory analysis of the phenomenon [15].

Given this importance of quantum biology in biological systems, its origin is important to consider. We have approached this issue by considering the structure of DNA. We demonstrate the involvement of quantum charged particles that join together. Due to the motion of these objects, their charged particles create electrical currents and emit electromagnetic waves. We suggest some mechanisms for applying quantum waves in imaging of DNA packages like viruses, bacteria, and embryonic cells.

The outline of the paper is as follows. In section II, we show that DNA is constructed from quantum particles and radiates quantum waves. In section III, we propose methods for detecting the signals of DNA inside the virus and bacteria. In section IV, we describe the use of quantum waves in imaging.

### DNA quantum waves

In this section, we propose several reasons (1-5) why DNA could radiate waves.

1. Each DNA is formed from a base pairing between A (Adenine) and T (Thymine), and between C (Cytosine) and G (Guanine). A and G are constructed from hexagonal and pentagonal manifolds. T and C are hexagonal [16], [17]. Each of these manifolds is constructed from charged atoms like nitrogen and carbon, and electrons. The electrical charges of each base differ from the others. Consequently, the A-T and C-G base pairs form two types of electrical moments (Figure 1).

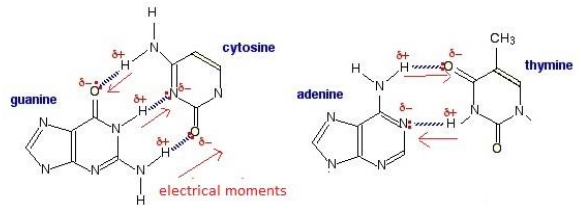


Figure 1: Each base in DNA is constructed from electrical moments

Moreover, different DNAs have different activities that cause the motion-related electrical charges and moments. For example, during transcription and translation, some regions of the genetic information on DNA are copied to form RNAs and proteins, which interact with DNA and lead to the motion of the DNA. According to the laws of physics, the motion of electrical charges produces a magnetic field and results in the emission of electromagnetic waves. Thus, each DNA can radiate various types of waves depending on the nature of its interaction with biological material like DNA and RNA (Figure 2).

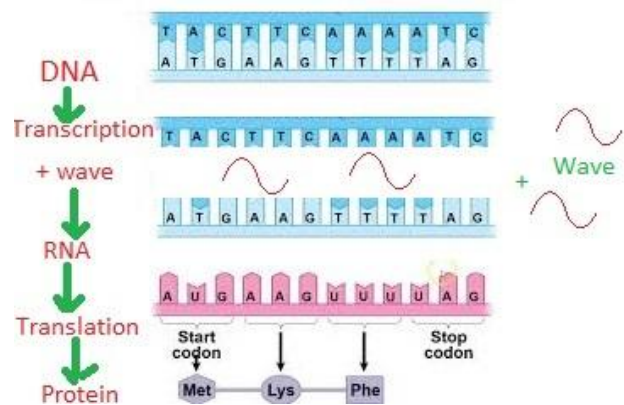


Figure 2: During transcription and translation, electrical pairs become separated, and some waves emerge

2. During cell division, the DNA in each cell replicates so that the two daughter cells have the same genetic information as the parent cell [18]. In this process, the two strands of the original DNA double helix separate and each strand's complementary DNA sequence is recreated as catalysed by DNA polymerase. In this mechanism,

charged pairs are separated and then joined to each other. Consequently, the motions of these charged particles produce electromagnetic waves (Figure 3).

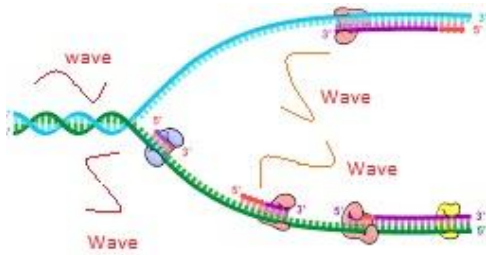


Figure 3: During replication, electrical pairs become separated, and electromagnetic waves emerge

3. The DNA structure is very similar to a solenoid or coil. Consequently, the motion of electrons the structure produces magnetic fields (Figure 4).

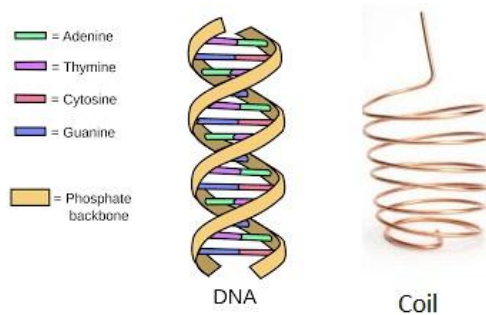


Figure 4: The structure of DNA is very similar to a coil

4. Each part of DNA acts similar to an electronic device. For example, hexagonal and pentagonal molecules store waves and energy and act as a capacitor. Coiled regions of DNA produce a solenoid. The collective circuits produce a system similar to a radio wave receiver or transmitter (Figure 5).

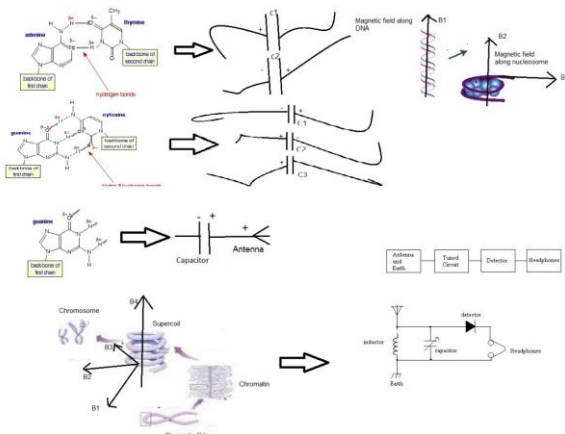


Figure 5: Each part of DNA acts similar to an electronic device [19]

5. Some waves act like topoisomerases and unwind DNA to allow reading of the information.

Topoisomerases are enzymes that participate in the rewinding or unwinding of DNA. The winding problem of DNA arises due to the intertwined nature of its double-helical structure. Topoisomerases act on the topology of DNA [20]. Similar to these enzymes, some waves participate in the unwinding of DNA. These waves are coupled to the structure of DNA and produce topologically simple structures. This causes the exchange of information between DNAs (Figure 6).

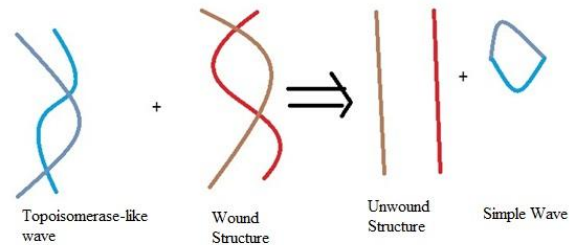


Figure 6: Topoisomerase-like wave couples to the wound structure of DNA and make it unwind topologically

**A method for detecting waves of DNA packages like bacteria**

To observe DNA waves, it is best to use biological versions of packaged DNA; virus and bacteria are suitable. When not packaged, DNA cannot undergo normal actions like replication and will not produce waves. For this method, bacteria and the viruses that infect them can be contained in a vessel that houses a fluid, such as milk, which can be used by the bacteria for growth. Also, since bacteria replicate autonomously, but virus do not (bacteriophage require bacteria to replicate), we need to bacterial packages. In this experiment, we didn't use the chemical medium and use of natural material like milk to show communication between DNAs and effects of DNA waves in a natural medium. In this procedure, a vessel of milk containing bacteria and virus were placed in an inductor. One side of the vessel was connected to a generator and the other side to a scope (Figure 7).

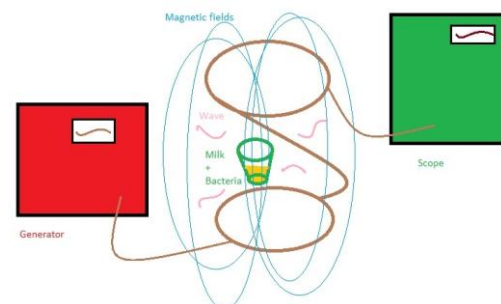


Figure 7: Detection of signals of DNA packages (bacteria) in a vessel of milk in an external magnetic field

A current is supplied to the inductor to produce a magnetic field. The bacteria and virus suspended in the milk interact with the magnetic field,

alter it, and produce a new type of output electromagnetic field. The entire system can be placed in an incubator to observe the types of interactions between bacteria, viruses and magnetic field changes at different temperatures.

The signals obtained from bacteria growing at various temperatures are displayed in Figure 8. With time, the number of DNA packages (i.e., bacteria) in the milk increases, and more waves are emitted. The pattern depends on temperature. For example, at 5°C, fewer bacteria are produced, and fewer waves are detected, while more bacteria (and hence more waves) are produced at higher temperatures.

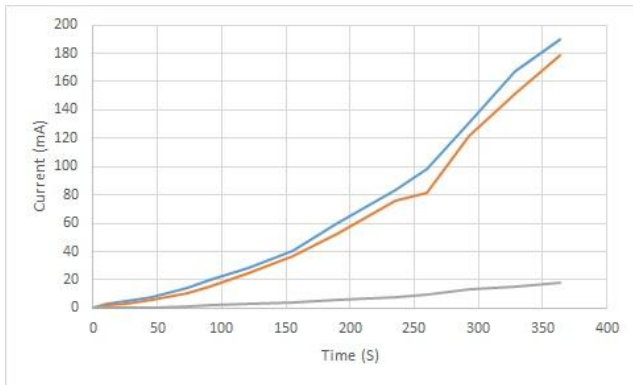


Figure 8: The growth signals of bacteria in milk in terms of time for 40°C (blue), 38°C (red), and 5°C (grey)

**Use of DNA waves in imaging**

The concepts of quantum biology and DNA waves can be exploited for imaging. For example, information about the properties of DNAs of chick embryos residing inside eggs might be obtained by analysing the waves exchanged between the DNA inside the egg with the DNA exterior to the egg. To this aim, we build a circuit from a graphene or metal tube, generator, inductor, scope, DNA in the interior of eggs, and DNA exterior to the eggs. Magnetic waves pass through the interior / exterior DNA, and the graphene. The DNAs are excited and exchange waves. Some of these waves interact with the electrons in the graphene tube, which generates a current. The changes that occur in these waves when exiting the eggs permit the analysis of the properties of the chick embryo DNA (Figure 9).

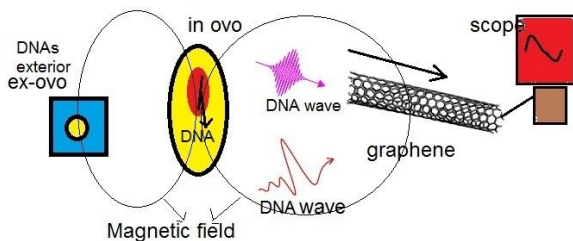


Figure 9: A circuit for using exchanged DNA waves between cells interior and exterior of egg in imaging

To obtain the exterior DNA, a culture system

devoid of the shell was used for chick embryos. Similar to Tahara and Obara (2014) [19] and Sepehri et al., (2019) [20], [21], [22], a 450 ml polystyrene plastic cup was used as the pod for the culture vessel. A whole 1 to 1.5 cm in diameter was made at the side of the cup approximately 2 cm from the bottom, and a cotton pledget was installed in the hole as a filter. Then, a 2 mm diameter plastic tube was positioned in the space between the pledget and the hole to provide oxygen that was necessary for bacterial growth. A concave polymethyl pentene film was placed in the pod as an artificial culture vessel. A polystyrene plastic cover was put on top of the culture vessel. The vessel containing broken fertilised eggs was put in an incubator, and the shell-less cultures were incubated at 38°C and rotated 120° clockwise twice a day. After 54 h, initial cells of chick embryos were evident (Figure 10).

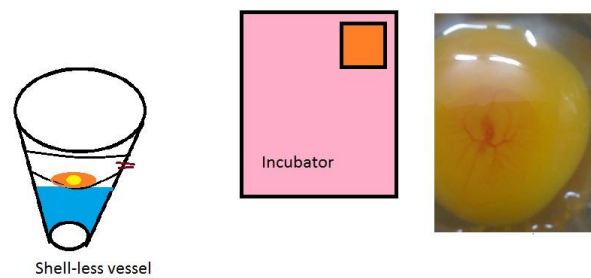


Figure 10: Incubation of shell-less cultures of chick embryos to observe the growth of cells

We explored whether the DNA waves that were generated could be used in imaging and to determine the gender of chick embryos. In Figure 11, the current value could distinguish males (red) and females (blue). The signal type differed between males and females. This is because that topology of some chromosomes in cells of males is different from the chromosomes of females. The motions of charged particles and electrons depend on the topology of the chromosomes and type of coiling, winding, and packing of DNA in them. Thus, by changing the shape of chromosomes and the DNA topology, ways and degrees of freedom of electrons change. Changing the motions of electrons changes their radiated waves, which explains the difference in the signals of males and females.

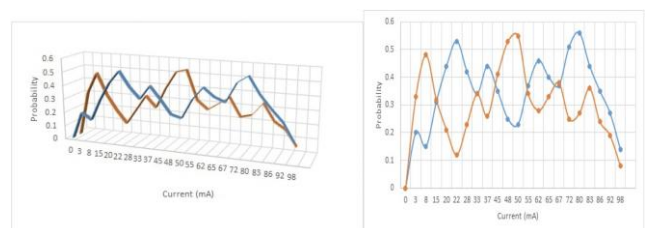


Figure 11: Comparison of signals of male (red) and female (blue)

In conclusion, in this research, we have shown that DNA waves play major roles in the

evolution of biological systems. We propose two models for imaging by using concepts of quantum biology and DNA waves. The models are useful in charting bacterial growth and in distinguishing the gender of chick embryos.

## References

1. Erwin Schrödinger. Cambridge University Press, New York, 1967:96. (Originally published in 1944.)
2. Lowdin PO. Quantum genetics and the aperiodic solid. Some aspects on the Biological problems of heredity, mutations, aging and tumours in view of the quantum theory of the DNA molecule. *Advances in Quantum Chemistry*. 1965; (2):213-360. [https://doi.org/10.1016/S0065-3276\(08\)60076-3](https://doi.org/10.1016/S0065-3276(08)60076-3)
3. Trixler F. Quantum Tunnelling to the Origin and Evolution of Life. *Current Organic Chemistry*. 2013; 17(16):1758-1770. <https://doi.org/10.2174/13852728113179990083> PMID:24039543 PMCid:PMC3768233
4. Yu SL, Lee SK. Ultraviolet radiation: DNA damage, repair, and human disorders. *Molecular- Cellular Toxicology*. 2017; 13(1):21-28. <https://doi.org/10.1007/s13273-017-0002-0>
5. Johnson PJ, Farag MH, Halpin A, Morizumi T, Prokhorenko VI, Knoester J, Jansen TL, Ernst OP, Miller RD. The primary photochemistry of vision occurs at the molecular speed limit. *J Phys Chem B* 2017; 121(16):4040-7. <https://doi.org/10.1021/acs.jpcc.7b02329> PMID:28358485
6. Schoenlein RW, Peteanu LA, Mathies RA, Shank CV. The first step in vision: femtosecond isomerization of rhodopsin. *Science*. 1991; 254(5030):412-5. <https://doi.org/10.1126/science.1925597> PMID:1925597
7. Hore PJ; Mouritsen H. The Radical-Pair Mechanism of Magnetoreception. *Annual Review of Biophysics*. 2016; 45(1):299-344. <https://doi.org/10.1146/annurev-biophys-032116-094545> PMID:27216936
8. Schulten K, Swenberg CE, Weller A. A biomagnetic sensory mechanism based on magnetic field modulated coherent electron spin motion. *Zeitschrift für Physikalische Chemie*. 1978; 111(1):1-5. <https://doi.org/10.1524/zpch.1978.111.1.001>
9. Kominis IK. The radical-pair mechanism as a paradigm for the emerging science of quantum biology. *Mod Phys Lett B*. 2015; 29(1):1530013. <https://doi.org/10.1142/S0217984915300136>
10. Lee H, Cheng YC, Fleming GR. Quantum coherence accelerating photosynthetic energy transfer. In *Ultrafast Phenomena XVI*. Springer, Berlin, Heidelberg, 2009:607-609. [https://doi.org/10.1007/978-3-540-95946-5\\_197](https://doi.org/10.1007/978-3-540-95946-5_197)
11. Fujihashi Y, Fleming GR, Ishizaki A. Impact of environmentally induced fluctuations on quantum mechanically mixed electronic and vibrational pigment states in photosynthetic energy transfer and 2D electronic spectra. *J Chem Phys*. 2015; 142(21):212403. <https://doi.org/10.1063/1.4914302> PMID:26049423
12. Nagel ZD, Klinman JP. Tunneling and Dynamics in Enzymatic Hydride Transfer. *ChemInform*. 2006; 37(43). <https://doi.org/10.1002/chin.200643274>
13. Nagel ZD, Klinman JP. Tunneling and Dynamics in Enzymatic Hydride Transfer. *Chemical Reviews*. 2006; 106(8):3095-3118. <https://doi.org/10.1021/cr050301x> PMID:16895320
14. Montagnier L, Aïssa J, Ferris S, Montagnier JL, Lavallée C. Electromagnetic signals are produced by aqueous nanostructures derived from bacterial DNA sequences. *Interdiscip Sci Comput Life Sci*. 2009; 1(2):81-90. <https://doi.org/10.1007/s12539-009-0036-7> PMID:20640822
15. Montagnier L, Del Giudice E, Aïssa J, Lavallée C, Motschwiller S, Capolupo A, Polcari A, Romano P, Tedeschi A, Vitiello G. Transduction of DNA information through water and electromagnetic waves. *Electromagnetic biology and medicine*. 2015; 34(2):106-12. <https://doi.org/10.3109/15368378.2015.1036072> PMID:26098521
16. Alberts B, Johnson A, Lewis J, Raff M, Roberts K, Walter P. *Molecular Biology of the Cell* (6th ed.). Garland. p. Chapter 4: DNA, Chromosomes and Genomes, 2014.
17. Watson JD, Crick FH. Molecular structure of nucleic acids; a structure for deoxyribose nucleic acid. *Nature*. 1953; 171(4356):737-38. <https://doi.org/10.1038/171737a0> PMID:13054692
18. Albà M. Replicative DNA polymerases. *Genome Biology*. 2001; 2(1):REVIEWS3002. <https://doi.org/10.1186/gb-2001-2-1-reviews3002> PMID:11178285
19. Sepehri A. A mathematical model for DNA. *International Journal of Geometric Methods in Modern Physics*. 2017; 14:11. <https://doi.org/10.1142/S0219887817501523>
20. Champoux JJ. DNA topoisomerases: structure, function, and mechanism. *Annual review of biochemistry*. 2001; 70(1):369-413. <https://doi.org/10.1146/annurev.biochem.70.1.369> PMID:11395412
21. Tahara Y, Obara K. A Novel Shell-less Culture System for Chick Embryos Using a Plastic Film as Culture Vessels. *Journal of Poultry Science*. 2014; 51(3):307-312. <https://doi.org/10.2141/jpsa.0130043>
22. Sepehri A, Fioranelli M, Rocchia MG. The role of entropic penalties of circular DNA assembly in spectroscopy and imaging. *J Theor Appl Phys*. 2019; 13(1):39-47. <https://doi.org/10.1007/s40094-019-0321-8>

# The Effects of Magnesium – Melatonin - Vit B Complex Supplementation in Treatment of Insomnia

Gorica Djokic<sup>1</sup>, Petar Vojvodic<sup>1</sup>, Davor Korcok<sup>2</sup>, Anita Agic<sup>2</sup>, Anica Rankovic<sup>1</sup>, Vladan Djordjevic<sup>1</sup>, Aleksandra Vojvodic<sup>3</sup>, Tatjana Vlaskovic-Jovicevic<sup>1</sup>, Zorica Peric-Hajzler<sup>4</sup>, Dusica Matovic<sup>4</sup>, Jovana Vojvodic<sup>1</sup>, Goran Sijan<sup>5</sup>, Uwe Wollina<sup>6</sup>, Michael Tirant<sup>7</sup>, Nguyen Van Thuong<sup>8</sup>, Massimo Fioranelli<sup>9</sup>, Torello Lotti<sup>10</sup>

<sup>1</sup>Clinic for Mental Disorders "Dr. Laza Lazarevic", Belgrade, Serbia; <sup>2</sup>Abela Pharm, Belgrade, Serbia; <sup>3</sup>Department of Dermatology and Venereology, Military Medical Academy, Belgrade, Serbia; <sup>4</sup>Military Medical Academy, Belgrade, Serbia; <sup>5</sup>Clinic for Plastic Surgery and Burns, Military Medical Academy, Belgrade, Serbia; <sup>6</sup>Department of Dermatology and Allergology, Städtisches Klinikum Dresden, Dresden, Germany; <sup>7</sup>Guglielmo Marconi University, Rome, Italy; <sup>8</sup>Vietnam National Hospital of Dermatology and Venereology, Hanoi, Vietnam; <sup>9</sup>Department of Nuclear Physics, Sub-nuclear and Radiation, G. Marconi University, Rome, Italy; <sup>10</sup>Department of Dermatology, G. Marconi University, Rome, Italy

## Abstract

**Citation:** Vojvodic P, Korcok D, Agic A, Rankovic A, Djordjevic V, Vojvodic A, Vlaskovic-Jovicevic T, Peric-Hajzler Z, Matovic D, Vojvodic J, Sijan G, Wollina U, Tirant M, Van Thuong N, Fioranelli M, Lotti T. The Effects of Magnesium – Melatonin - Vit B Complex Supplementation in Treatment of Insomnia. Open Access Maced J Med Sci. 2019 Sep 30; 7(18):3101-3105. https://doi.org/10.3889/oamjms.2019.771

**Keywords:** Insomnia; Magnesium; Melatonin; Athens insomnia scale; Supplement

**\*Correspondence:** Massimo Fioranelli. Department of Nuclear Physics, Sub-nuclear, and Radiation, G. Marconi University, Rome, Italy. E-mail: massimo.fioranelli@gmail.com

**Received:** 13-Jun-2019; **Revised:** 04-Jul-2019; **Accepted:** 05-Jul-2019; **Online first:** 30-Aug-2019

**Copyright:** © 2019 Gorica Djokic, Petar Vojvodic, Davor Korcok, Anita Agic, Anica Rankovic, Vladan Djordjevic, Aleksandra Vojvodic, Tatjana Vlaskovic-Jovicevic, Zorica Peric-Hajzler, Dusica Matovic, Jovana Vojvodic, Goran Sijan, Uwe Wollina, Michael Tirant, Nguyen Van Thuong, Massimo Fioranelli, Torello Lotti. This is an open-access article distributed under the terms of the Creative Commons Attribution-NonCommercial 4.0 International License (CC BY-NC 4.0)

**Funding:** This research did not receive any financial support

**Competing Interests:** The authors have declared that no competing interests exist

**Abbreviations:** APA- American Psychiatric Association; DSM-5- Diagnostic Criteria from Diagnostic and Statistical Manual of Mental Disorders, 5th edition; ACP- The American College of Physicians; CBT- Cognitive behavioral therapy; 5-HT<sub>2</sub>- Serotonergic receptors type 2; GABA-A- Gamma-aminobutyric acid receptors type A; H<sub>1</sub>- Histamine receptors type 1; D<sub>2</sub>- dopamine receptors type 2; OR1- orexin receptors type 1; OR2- orexin receptors type 2; Mel 1- melatonin receptors type 1; Mel 2- melatonin receptors type 2; 5-HT- Serotonin receptor system; DA- Dopamine receptor system

Insomnia means difficulty in falling asleep and/or stays asleep. Insomnia commonly leads to daytime sleepiness, lethargy, and a general feeling of being unwell. The most common treatment of insomnia includes GABAA receptor positive allosteric modulators or Melatonin agonists. Our study aimed to evaluate the efficacy of Magnesium- melatonin-vitamin B complex supplement in the treatment of insomnia. The study included 60 patients diagnosed with insomnia. The patients were randomly divided into study group (N = 30), and control group (N = 30), and study group was treated with Magnesium-melatonin-vitamin B complex (one dose contains 175 mg liposomal magnesium oxide, 10 mg Vit B6, 16 µg vit B12, melatonin 1 mg, Extrafolate-S 600 µg) once a day 1 hour before sleep, during the 3 months. The severity of insomnia symptoms was measured by self-reported Athens insomnia scale (AIS), with a cut-off score by Soldatos (AIS score ≥ 6). Mean AIS score at zero points was 14.93 ± 3.778 in the study group and 14.37 ± 4.081 in the control group (p = 0.476), indicating the compatibility of the groups, and both scores correspond to mild to moderate insomnia. Mean AIS score after 3 months of the Magnesium- melatonin- vitamin B complex supplementation was 10.50 ± 4.21 corresponding to mild insomnia, while median AIS score in the control group was 15.13 ± 3.76 which is referred to moderate insomnia, and difference among groups was significant (p = 0.000). Our findings indicating that 3 months of the Magnesium-melatonin-vitamin B complex supplementation has a beneficial effect in the treatment of insomnia regardless of cause.

## Introduction

Insomnia is a sleep disorder with difficulties to fall asleep or stay asleep or both. It is the most common sleep disorder, according to the American Psychiatric Association (APA), with approximately

30% of all adults and 6-10% of those who have severe symptoms diagnosed as insomnia disorder [1].

Diagnostic Criteria from the Diagnostic and Statistical Manual of Mental Disorders, 5th edition (DSM-5) include:

- Difficulty in initialisation or maintaining sleep

or early-morning awakening that leads to low quantity or quality of sleep.

- Sleep disturbance that leads to impairment in social, occupational, educational, academic, behavioural, or other important areas of functioning.

- Patients experience this even with adequate opportunity to sleep, at least 3 nights per week, and for at least 3 months.

- Insomnia is not explained by the presence of mental disorders or medical conditions and is not associated with another sleep disorder [2].

Pharmaceutical and nonpharmaceutical treatments are recognisable for insomnia. The American College of Physicians (ACP) advised cognitive-behavioural therapy (CBT) as a first-line treatment for chronic insomnia in adults. Sleep hygiene training (avoiding caffeine, exercise near bedtime, watching TV or surfing the internet from the bed) can help you change some of these disruptive behaviours [1].

Medications that have insomnia as an approved indication are:

- Benzodiazepine receptor agonist (non-selective GABA-A receptor positive allosteric modulator)-eszazolam, eszopiclone, flunitrazepam, flurazepam, lormetazepam, nitrazepam, quazepam, temazepam, triazolam, zaleplon, zolpidem (alpha 1 subunit selective benzodiazepine receptor agonist).

- Norepinephrine and serotonin reuptake inhibitor and 5-HT<sub>2</sub> receptor antagonist doxepine in very low doses 3mg and 6mg for insomnia in the USA

- H<sub>1</sub> and D<sub>2</sub> receptor antagonist promethazine

- OR<sub>1</sub> and OR<sub>2</sub> receptor antagonist suvorexant

- Mel<sub>1</sub> and Mel<sub>2</sub> receptor agonist ramelteon and melatonin [3].

The hormone melatonin is produced during the sleep cycle. Studies are inconclusive regarding whether melatonin can help treat insomnia in adults, but melatonin could promote sleep by helping to regulate the body's bio clock and sleep-wake cycles and to adhere to more healthful sleep patterns. Research indicates that melatonin may shorten the time it takes to fall asleep, increase overall sleep amounts, and may increase REM sleep [4], [5], [6].

Few sleep-promoting nutrients enhance sleep and relaxation. Magnesium is a muscle relaxant and inducer of the deeper sleep. Circadian rhythms dysregulation and compromised lifestyle also increase magnesium excretion, leading to deficiency [7]. Magnesium supplementation improves sleep efficiency, sleep time and sleep onset latency, early morning awakening, and insomnia objective measures such as the concentration of serum renin, melatonin,

and serum cortisol, in older adults [8]. Dietary magnesium intake may have long-term benefits in reducing the likelihood of daytime falling asleep in women [9]. Anxiety can cause insomnia, and vice versa which can result in a self-perpetuating cycle, which leads to chronic insomnia. According to Australia's Sleep Health Foundation, anxiety and worrying are leading causes of insomnia [1]. Existing evidence is suggestive of a beneficial effect of Mg on subjective anxiety in anxiety vulnerable samples, and for mild-to-moderate depression in adults within 2 weeks [10], [11]. According to the National Sleep Foundation, insomnia promotes depression and depression-induced insomnia. A meta-analysis of 34 studies concluded that insomnia is significantly associated with an increased risk of depression, which has implications for the prevention of depression in non-depressed individuals with insomnia symptoms [12]. Melatonin and the nonselective MT<sub>1</sub> / MT<sub>2</sub> receptor agonist agomelatine have displayed anxiolytic-like action and have been used in the elderly, but exact mechanisms of action are still unknown [13], [14]. Recent studies suggest that the MT<sub>2</sub> receptor is implicated in the antidepressant-like effects of melatonin [15], [16].

The recent results showed mixed effects of vitamin B<sub>12</sub> on sleep patterns [17] and promoting an effect of vitamin B6 on the reduction of psychological distress, which could induce sleep disturbance [18]. Contrary to that, there is clear evidence on the antidepressant effect of vitamin B12 [19] and vitamin B6 for therapy of hormone-related depression in women [20].

Our study aimed to evaluate the efficacy of Magnesium-melatonin-vitamin B complex supplement in the treatment of insomnia.

## Material and Methods

The study included 60 patients diagnosed with insomnia who refused to take drugs for insomnia and have a positive attitude towards the supplements. The patients were randomly divided (bias coin randomization) into study group (N = 30), and control group (N = 30), and study group was treated with Magnesium-melatonin-vitamin B complex (one dose contains 175 mg liposomal magnesium oxide, 10 mg Vit B6, 16 µg vit B12, melatonin 1mg, Extrafolate-S 600 µg) once a day 1 hour before sleep, during the 3 months. The manufacturer advertises it as mild rapid-acting natural sleep medicine containing magnesium, melatonin, and vitamin B complex. It is recommended to use one capsule daily, evening dose, an hour before sleep. We followed the manufacturer's recommendation regarding the supplement intake. The severity of insomnia symptoms was measured by self-reported Athens insomnia scale (AIS), with

Gamma-aminobutyric acid score by Soldatos (AIS score  $\geq 6$ ). The severity of insomnia measured by AIS was graded according to Morin's criteria: AIS score 7-14- mild insomnia; AIS score 15-21- moderate insomnia; AIS score 22-28- severe insomnia. AIS and CGI-S scores were evaluated at zero points and after 3 months of supplement consumption.

### Statistical analysis

All collected data were analysed using the IBM SPSS Statistics for Windows (IBM SPSS, IBM Corp., Armonk, NY, USA) software, version 22.0. The descriptive statistics are presented as a central tendency (means) and variability (standard deviation and variation interval). Means were compared with the independent samples t-test, while for testing data of different categories, we used Pearson's  $\chi^2$  test and Mann-Whitney test. We used repeated-measures analysis of covariance (RM ANCOVA) for the assessment on t0 and t90 between and within the groups. The level of statistical significance was set at  $p < 0.05$ .

## Results

Gender distribution was 67% male and 33% female in the study group and 77% male and 23% female in the control group. The average age in the study group was  $51.40 \pm 14.61$  years, and  $44.93 \pm 14.40$  years in the control group, the age distribution of subjects indicating the comparability of the studied groups ( $p = 0.090$ ). Mean AIS score at zero points was  $14.93 \pm 3.778$  in the study group and  $14.37 \pm 4.081$  in the control group ( $p = 0.476$ ), indicating the compatibility of the groups, and both scores correspond to mild to moderate insomnia. Mean AIS score after 3 months of the Magnesium-melatonin-vitamin B complex supplementation was  $10.50 \pm 4.21$ , corresponding to mild insomnia, while the median AIS score in the control group was  $15.13 \pm 3.76$  which refers to moderate insomnia, and difference among groups was significant ( $p = 0.000$ ) (Table 1).

**Table 1: AIS score at zero and endpoint**

	T0		T90		p**
	X $\pm$ SD; Med (min-max)	p*	X $\pm$ SD; Med (min-max)	p*	
Study group	14.93 $\pm$ 3.78; 15 (9-24)	0.476	10.50 $\pm$ 4.21; 9 (3-20)	0.000	0.000
Control group	14.37 $\pm$ 4.08; 13.5 (9-24)		15.13 $\pm$ 3.76; 14 (10-24)		

\*Mann-Whitney test; \*\*Wilcoxon test.

Mean CGI-S at zero point was  $3.57 \pm 0.568$  in study group, and  $3.43 \pm 0.58$  in control group ( $p = 0.328$ ). Difference became significant at the end point visit ( $p = 0.05$ ) with mean CGI-S score  $2.97 \pm 0.77$  in the study group, and  $3.53 \pm 0.63$  in control group (Table 2).

**Table 2: CGI-S at zero and endpoint**

	T0		T90		p**
	X $\pm$ SD; Med (min - max)	p*	X $\pm$ SD; Med (min - max)	p*	
Study group	3.57 $\pm$ 0.57; 4 (3-5)	0.328	2.97 $\pm$ 0.77; 3 (1-4)	0.005	0.005
Control group	3.43 $\pm$ 0.57; 3 (3-5)		3.53 $\pm$ 0.63; 3 (3-5)		

\*Mann-Whitney test; \*\*Wilcoxon test.

Mean CGI-I score after 3 months was  $3.23 \pm 0.73$  (minimally improved), which is significantly different in comparison with mean CGI-I score in control group  $4.07 \pm 0.25$  (no change) ( $p = 0.000$ ) (Table 3).

**Table 3: CGI-I at the endpoint**

	T90		p*
	X $\pm$ SD; Med (min - max)		
Study group	3.23 $\pm$ 0.73; 3 (2-4)		0.000
Control group	4.07 $\pm$ 0.25; 4 (4-5)		

\*Mann-Whitney test.

## Discussion

The results of this study demonstrate that supplementation with Magnesium-melatonin-vitamin B complex for 3 months has a significant positive effect on sleep disturbances and is highly effective for the treatment of patients with insomnia. Regardless of the insomnia aetiology, Magnesium-melatonin-vitamin B complex supplementation reduces insomnia symptoms, as well as its consequences, thus improving the patients' quality of life and preventing potential unwanted clinical, social, economic, or emotional repercussions.

Magnesium is one of the most important minerals in the human body. It is involved in more than 300 enzyme systems responsible for the maintenance of normal homeostasis [9]. One of the more recently discovered functions of magnesium is its effect on cellular timekeeping and regulation of circadian rhythm. Studies that back up this theory have shown that inadequately low levels of serum magnesium are associated with low quality sleep and insomnia [17]. Lack of magnesium intake seems to be involved in the development of depression, which increases the risk of insomnia [12].

A study performed by Abbasi et al. [8] examined the independent role of magnesium in the treatment of insomnia. After 8 weeks of magnesium supplementation, the patients had increased sleep time, as well as sleep efficiency. The results demonstrate that magnesium supplementation brings significant improvement, both subjective and objective, to the patients who have insomnia. These results are consistent with the results of our study, which demonstrates that magnesium, isolated or as a part of a combination supplement, is successful in treating insomnia. Interestingly, a statistically significant increase in serum melatonin concentration was recorded in the experimental group that received

dietary magnesium supplementation compared to the placebo group. This finding suggests the complicated interaction between these two elements that are both important for the regulation of sleep and the day-night cycle.

Melatonin is a hormone produced and secreted by the pineal gland. It has an important role in the maintenance of the organism circadian rhythm, which is being expressed through a wide range of different physiologic, neuroendocrine, and behavioural functions. Its plasma concentrations reach a peak during nighttime, while during the daytime, they are barely measurable [15]. Animal and human studies have demonstrated that melatonin binds to the receptors in the central nervous system, producing an effect on sleep promotion and sleeping phase shifts [13], [16].

Pharmacological agents that are prescribed for insomnia cannot reproduce the properties of physiological sleep and are associated with adverse effects like sedation, anxiety, tremor, tolerance to the drug or dependence [13]. The research conducted by Ochoa-Sanchez et al., [21] revealed that melatonin receptor agonists had much more favourable pharmacological properties in terms of sleep promotion and regulation when compared to prescribed benzodiazepines. Also, melatonin and its agonists did not produce adverse effects commonly attributable to benzodiazepines.

The study of Grima et al. [5], which dealt with melatonin administration for sleep disturbances after traumatic brain injury, reported a significant improvement in sleep quality and sleep efficiency, as well as a reduction in fatigue and anxiety symptoms, after only 4 weeks of melatonin treatment. This result is consistent with our study, although patients in our experimental group did not receive isolated melatonin, as a part of the Magnesium-melatonin-vitamin B complex supplement, and they received it for a substantially longer period as well.

From the B vitamins group, the best examined in terms of sleeping interactions is vitamin B12. The direct relationship between insomnia and vitamin B12 levels is yet to be established. However, vitamin B12 deficiency is known to be involved in the pathophysiology of depression, which can commonly be associated with insomnia [19].

Lichstein et al. [18] examined the influence of different vitamin supplementation on sleep quality and duration. The results suggest that the use of combined multivitamin supplements, as well as single vitamins, including vitamin B complex, hurts sleep maintenance, causes a higher rate of insomnia, and requires greater use of sleep medicine. In contrast to this study, our results show that vitamin B complex, in combination with magnesium and melatonin, has a positive effect on sleep regulation and can be used to treat insomnia. This could be attributed to the combined additive effect of the three components of

the prescribed supplement, in contrast to the single effects of isolated molecules that were previously tested.

Although there are studies that investigated the effect of different combined supplements for the treatment of insomnia, to the best of our knowledge, this is the first study that investigated the particular combination of Magnesium-melatonin-vitamin B complex supplement. The research conducted by Rondanelli et al. [22] investigated the influence of the supplement consisting of melatonin, magnesium, and zinc on insomnia in the elderly.

Their results showed that these elements were effective in managing sleep disorders after 2 months of treatment. This finding is consistent with our study, which shows that common elements from both studies – magnesium, and melatonin have a significant effect on sleep regulation.

Our findings indicate that 3 months of the Magnesium-melatonin-vitamin B complex supplementation has a beneficial effect in the treatment of insomnia regardless of cause. According to our results, Magnesium-melatonin-vitamin B complex augmentation improves AIS and CGI-S score with statistical significance relative to the control group. The global improvement according to the CGI-I score, was minimal but significant different compared with the control group where there was no change.

## References

1. Healthline Editorial Team, Lamoreux K. Everything You Need to Know About Insomnia, 2018. Available from: <https://www.healthline.com/health/insomnia>. Last accessed 26 Nov 2018.
2. American Psychiatric Association. Diagnostic and Statistical Manual of Mental Disorders, 5th ed. Arlington, VA: American Psychiatric Association Publishing, 2013. <https://doi.org/10.1176/appi.books.9780890425596>
3. Zohar J, Stahl S, Moller HJ, Blier P, Kupfer D, Yamawaki S, Ucheida S, Draggo F, Goodwin G, Nutt D. Neuroscience based Nomenclature- the second edition, 2018. Available from: <http://www.nbn2.com/> (Last accessed 27 Nov 2018).
4. Breus M. Understanding Melatonin: How Melatonin Can Help Sleep and Bio Time, 2018. Available from: <https://www.thesleepdoctor.com/2017/06/06/understanding-melatonin-melatonin-can-help-sleep-bio-time/> (Last accessed 27 Nov 2018).
5. Grima NA, Rajaratnam SMW, Mansfield D, Sletten TL, Spitz G, Ponsford JL. Efficacy of melatonin for sleep disturbance following traumatic brain injury: a randomised controlled trial. *BMC Med.* 2018; 16(1):8. <https://doi.org/10.1186/s12916-017-0995-1> PMID:29347988 PMCID:PMC5774131
6. Alzoubi, KH, Mayyas FA, Khabour OF, Bani Salama FM, Alhashimi FH, Mhaidat NM. Chronic Melatonin Treatment Prevents Memory Impairment Induced by Chronic Sleep Deprivation. *Molecular Neurobiology.* 2016; 53(5):3439-3447. <https://doi.org/10.1007/s12035-015-9286-z> PMID:26084441
7. Sochan J. Top 2 sleep promoting nutrients: Magnesium and



- Calcium, 2018. Available from: <https://www.naturimedita.com/top-2-sleep-promoting-nutrients-magnesium-and-calcium/> (Last accessed 27 Nov 2018).
8. Abbasi B, Kimiagar M, Sadeqnia K, Shirazi MM, Hedavati M, Rashidkhani B. The effect of magnesium supplementation on primary insomnia in elderly: A double-blind placebo-controlled clinical trial. *J Res med Sci.* 2012; 17(12):1161-9.
  9. Cao Y, Zhen S, Taylor AW, Appleton S, Atlantis E, Shi Z. Magnesium Intake and Sleep Disorder Symptoms: Findings from the Jiangsu Nutrition Study of Chinese Adults at Five-Year Follow-Up. *Nutrients.* 2018; 21(10):E1354. <https://doi.org/10.3390/nu10101354> PMID:30248967 PMCID:PMC6212970
  10. Boyle NB, Lawton C, Dye L. The Effects of Magnesium Supplementation on Subjective Anxiety and Stress-A Systematic Review. *Nutrients.* 2017; 9(5):429. <https://doi.org/10.3390/nu9050429> PMID:28445426 PMCID:PMC5452159
  11. Tarleton EK, Littenberg B, Maclean CD, Kennedy AG, Daley C. Role of magnesium supplementation in the treatment of depression: A randomized clinical trial. *PLoS One.* 2017; 12(6):e0180067. <https://doi.org/10.1371/journal.pone.0180067> PMID:28654669 PMCID:PMC5487054
  12. Li L, Wu C, Gan Y, Qu X, Lu Z. Insomnia and the risk of depression: a meta-analysis of prospective cohort studies. *BMC Psychiatry.* 2016; 16:375. <https://doi.org/10.1186/s12888-016-1075-3> PMID:27816065 PMCID:PMC5097837
  13. Comai S, Gobbi G. CCNP Award Paper: Unveiling the role of melatonin MT2 receptors in sleep, anxiety and other neuropsychiatric diseases: a novel target in psychopharmacology. *J Psychiatry Neurosci.* 2014; 39(1):6-21. <https://doi.org/10.1503/jpn.130009> PMID:23971978 PMCID:PMC3868666
  14. Garfinkel D, Zisapel N, Wainstein J, et al. Facilitation of benzodiazepine discontinuation by melatonin: a new clinical approach. *Arch Intern Med.* 1999; 159:2456-60. <https://doi.org/10.1001/archinte.159.20.2456> PMID:10665894
  15. Sumaya IC, Masana MI, Dubocovich ML. The antidepressant-like effect of the melatonin receptor ligand luzindole in mice during forced swimming requires expression of MT2 but not MT1 melatonin receptors. *J Pineal Res.* 2005; 39:170-7. <https://doi.org/10.1111/j.1600-079X.2005.00233.x> PMID:16098095
  16. Hickie IB, Rogers NL. Novel melatonin-based therapies: potential advances in the treatment of major depression. *Lancet.* 2011; 378:621-31. [https://doi.org/10.1016/S0140-6736\(11\)60095-0](https://doi.org/10.1016/S0140-6736(11)60095-0)
  17. Xiaopeng J, Grandner MA, Liu J. The relationship between micronutrient status and sleep patterns: a systematic review. *Public Health Nutr.* 2017; 20(4):687-701. <https://doi.org/10.1017/S1368980016002603> PMID:27702409 PMCID:PMC5675071
  18. Lichstein KL, Payne KL, Soeffing JP, Durrence HH, Taylor DJ, Riedel BW, Bush AJ. Vitamins and sleep: An exploration study. *Sleep Med.* 2008; 9(1):27-32. <https://doi.org/10.1016/j.sleep.2006.12.009> PMID:17825610 PMCID:PMC2174691
  19. Syed EU, Wasay M, Awan S. Vitamin B12 Supplementation in Treating Major Depressive Disorder: A Randomized Controlled Trial. *Open Neurol J.* 2013; 7:44-48. <https://doi.org/10.2174/1874205X01307010044> PMID:24339839 PMCID:PMC3856388
  20. Williams AI, Cotter A, Sabina A, Girard C, Goodman J, Katz DL. The role of vitamin B6 as treatment for depression: a systematic review. *Family Practice.* 2005; 22(5):532-37. <https://doi.org/10.1093/fampra/cmi040> PMID:15964874
  21. Ochoa-Sanchez R, Rainer Q, Comai S, et al. Anxiolytic effects of the melatonin MT(2) receptor partial agonist UCM765: comparison with melatonin and diazepam. *Prog neuropsychopharmacol Biol Psychiatry.* 2012; 39:318-25. <https://doi.org/10.1016/j.pnpbp.2012.07.003> PMID:22789661
  22. Rondanelli M, Opizzi A, Monteferrario F, Antoniella N, Manni R, Klersy C. The effect of melatonin, magnesium, and zinc on primary insomnia in long-term care facility residents in Italy: a double-blind, placebo-controlled clinical trial. *J Am Geriatr Soc.* 2011; 59:82-90. <https://doi.org/10.1111/j.1532-5415.2010.03232.x> PMID:21226679

## In Ovo Sexing of Chicken Eggs by Virus Spectroscopy

Massimo Fioranelli<sup>1</sup>, Alireza Sepehri<sup>1</sup>, Maria Grazia Roccia<sup>1</sup>, Chiara Rossi<sup>1</sup>, Petar Vojvodic<sup>2</sup>, Jacopo Lotti<sup>1</sup>, Victoria Barygina<sup>3</sup>, Aleksandra Vojvodic<sup>4</sup>, Uwe Wollina<sup>5</sup>, Michael Tirant<sup>6</sup>, Nguyen Van Thuong<sup>7</sup>, Sanja Dimitrijevic<sup>8</sup>, Goran Sijan<sup>9</sup>, Zorica Peric-Hajzler<sup>10</sup>, Dusica Matovic<sup>10</sup>, Tatjana Vlaskovic-Jovicevic<sup>2</sup>, Torello Lotti<sup>11</sup>

<sup>1</sup>Department of Nuclear Physics, Sub-nuclear and Radiation, G. Marconi University, Rome, Italy; <sup>2</sup>Clinic for Psychiatric Disorders "Dr. Laza Lazarevic", Belgrade, Serbia; <sup>3</sup>Department of Biomedical Experimental and Clinical Sciences, University of Florence, Florence, Italy; <sup>4</sup>Department of Dermatology and Venereology, Military Medical Academy, Belgrade, Serbia; <sup>5</sup>Department of Dermatology and Allergology, Städtisches Klinikum Dresden, Dresden, Germany; <sup>6</sup>G. Marconi University, Rome, Italy; <sup>7</sup>Vietnam National Hospital of Dermatology and Venereology, Hanoi, Vietnam; <sup>8</sup>Department of Gynecology, Military Medical Academy, Belgrade, Serbia; <sup>9</sup>Clinic for Plastic Surgery and Burns, Military Medical Academy, Belgrade, Serbia; <sup>10</sup>Military Medical Academy, Belgrade, Serbia; <sup>11</sup>Department of Dermatology, University of G. Marconi, Rome, Italy

### Abstract

Recently, some new methods for sexing of chicken eggs by fluorescence and Raman spectroscopy through the shell membrane have been proposed. On the other hand, in another investigation, a new virus medical imaging has been suggested. In this research, summing over these considerations, a new technique for sexing of chicken eggs by virus spectroscopy through the shell membrane is proposed. It is shown that viruses outside the shell of egg can communicate with materials inside it and determine the gender of chick embryo and it's evolutions.

**Citation:** Fioranelli M, Sepehri A, Roccia MG, Rossi C, Petar Vojvodic P, Lotti J, Barygina V, Vojvodic A, Wollina U, Tirant M, Thuong NV, Dimitrijevic S, Sijan G, Peric-Hajzler Z, Matovic D, Vlaskovic-Jovicevic T, Lotti T. In Ovo Sexing of Chicken Eggs by Virus Spectroscopy. Open Access Maced J Med Sci. 2019 Sep 30; 7(18):3106-3109.  
<https://doi.org/10.3889/oamjms.2019.768>

**Keywords:** Chicken; Eggs; DNA; Sex

**\*Correspondence:** Massimo Fioranelli. Department of Nuclear Physics, Sub-nuclear and Radiation, G. Marconi University, Rome, Italy. E-mail: [massimo.fioranelli@gmail.com](mailto:massimo.fioranelli@gmail.com)

**Received:** 03-Jul-2019; **Revised:** 14-Aug-2019; **Accepted:** 15-Aug-2019; **Online first:** 12-Sep-2019

**Copyright:** © 2019 Massimo Fioranelli, Alireza Sepehri, Maria Grazia Roccia, Chiara Rossi, Petar Vojvodic, Jacopo Lotti, Victoria Barygina, Aleksandra Vojvodic, Uwe Wollina, Michael Tirant, Nguyen Van Thuong, Sanja Dimitrijevic, Goran Sijan, Zorica Peric-Hajzler, Dusica Matovic, Tatjana Vlaskovic-Jovicevic, Torello Lotti. This is an open-access article distributed under the terms of the Creative Commons Attribution-NonCommercial 4.0 International License (CC BY-NC 4.0)

**Funding:** This research did not receive any financial support

**Competing Interests:** The authors have declared that no competing interests exist

## Introduction

Determination of the sex of birds is very important subject in science. Because, usually, birds with the gender of male have no commercial value and are culled immediately after hatching. Normal experimental techniques for in ovo sexing require taking samples and are applicable after embryos' sexual differentiation. Until now, scientists have proposed some models for biometric evolutions of chick embryo in ovo by using MRI. For example, a model was proposed to characterize embryonic

development during incubation in ovo and also to analyze the putative influence of repetitive ultrahigh-field MRI (UHF-MRI) measurements on this development [1]. In another research, scientists have used of MR microscopy. They have shown that MRM allows in vivo assessment of embryonic development of the chicken in ovo without affecting normal development. The method provided anatomical information supplemented by quantitative evaluation of lens development using DWI. With increasing availability of ultrahigh-field MR systems, this technique provided a noninvasive complementary tool in the field of experimental ophthalmology [2]. On the other hand, some other authors have demonstrated

that Raman spectroscopy enables contactless in ovo sex determination of the domestic chicken already at day 3.5 of egg incubation. A sexing accuracy of 90/100 have been obtained by analyzing the spectra of blood circulating in the extraembryonic vessels [3]. In another attempt, fluorescence spectroscopy has been applied to determine nondestructively in ovo the sex of early embryos of the domestic chicken. In this method, Sex-related differences in the fluorescence spectrum have been found at day 3.5, and principal component (PC) analysis showed that the blood of males was characterized by a specific fluorescence band located at  $\sim 910$  nm [4].

In ovo Raman and fluorescence spectroscopy of blood of eggs incubated until day 3.5 enables correct sexing rates over 90/100 barely affecting the hatching rate. Full automatization of the processes to guarantee high sexing speed and fulfill industrial demands is needed to permit transferring the technology inside the hatcheries in the next future [5].

In parallel, there are some other techniques that used of differences between electromagnetic signals for male and females for determining gender. In one of these researches, authors have argued that the type of packing of DNA in chromosomes of men and women are different. This causes radiated waves from DNAs of men and women to have opposite signs and cancel the effect of each other in a pair. Using this property, authors have suggested another mechanism to cancel the effect of extra waves, which are produced by DNAs in cancer cells of a male or a female, by extra waves which are produced by DNAs in similar cells of a female or a male and prevent the progression of the disease [6].

In another investigation, authors have proposed a new virus medical imaging technique. In this technique, viruses can communicate with cells, interior of human's body via two ways: 1) Viruses can form a wire that pass the skin and achieve to a special cell; and 2) Viruses can communicate with viruses interior of body in the wireless form and send some signals for controlling evolutions of cells interior of human's body [7].

Motivated by these researches, we suggest a new a new method for determining the gender of chicken eggs by virus spectroscopy through the shell membrane. In our method, virus outside the shell acts like the receiver of signals of cells inside the shell and give us this opportunity to analyze evolutions of chick embryo.

The outline of the paper is as follows. In section II, we consider materials and methods in this consideration. In section III, we will consider differences between radiated signals from viruses around chick embryos. The last section is devoted to conclusions.

## Material and Methods

### Chicken Eggs

All of the fertilized eggs used in this consideration were Dekalb Brown eggs, which were obtained from a village.

### Culture Vessels

We have two types of culture vessel. In one type, we use of in ovo system (Shell culture system). In another type, we use of ex-ovo system (Shell-less culture system).

Our culture vessels for ex-ovo method are the same used in Tahara [8] however type of incubating, temperature and rotation were different. Similar to Tahara [8], a 450 ml polystyrene plastic cup was applied as the pod for the culture vessel. A 1-1.5 cm diameter hole was made in the side of the cup approximately 2 cm from the bottom, and the hole was plugged with a cotton pledget as a filter. A 2 mm diameter plastic tube was inserted through the space between the pledget and the hole to provide an oxygen supply. An aqueous solution (40 ml) of benzalkonium chloride was then added to the cup. A polymethylpentene film was formed into a concave shape, carefully avoiding wrinkles and installed as an artificial culture vessel in the pod. A polystyrene plastic cover was placed on top of the culture vessel.

### Embryo culture, incubating, temperature and rotation

For in ovo method (Shell culture method), fertilized chicken eggs were incubated at  $38^{\circ}\text{C}$  and rotated with  $120^{\circ}$  clockwise twice a day. After 48 h, in most of eggs, chick embryos begin to grow.

For ex-ovo mechanism (Shell-less culture method), fertilized chicken eggs were not incubated before transferring to the culture vessels. Their eggshell was wiped and cracked and the whole egg contents were transferred to the culture vessel without pre-incubating period. The culture vessels were maintained at  $38^{\circ}\text{C}$  and rotated with  $120^{\circ}$  clockwise twice a day [8]. After 54 h, in most of vessels, chick embryo is emerged (See figure 1).

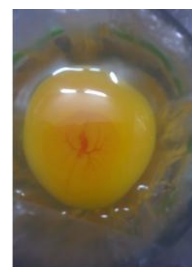

Figure 1: Formation of chick embryo in shell-less culture vessel (In-Ovo) less than 48 h after incubating at  $38^{\circ}\text{C}$

**Two systems for Taking signals of DNAs in a chick embryo by viruses**

Previously, it has been shown that viruses can communicate with DNAs. They can act like the receiver or sender in electronic devices (See Figure 2) [7].

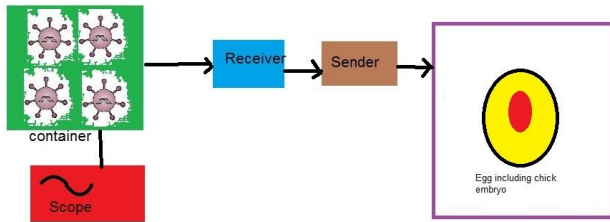


Figure 2: Viruses act like the receiver or sender of electromagnetic waves

Also, type of waves which exchange between viruses and DNAs of male is different respect to type of waves which exchange between viruses and DNAs of females (see Figure 3) [7]. We use of these properties for determining the gender of chick embryos in ovo and ex ovo.

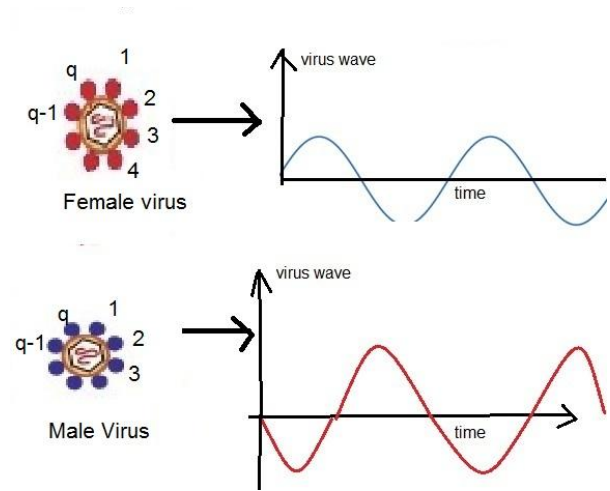


Figure 3: Viruses exchange two different waves with males and females

We form two systems for considering signals of chick embryos.

In first system, we take water around chick embryos in shell less culture systems (ex-ovo) and pour them in a tube of viruses. We use of viruses of influenza. We connect this tube to a computer or laptop with Radio-SkyPipe. This software helps us to consider evolutions of waves interior of tube. We also use of an Amperemeter for measuring currents (See Figure 4).

In second system, we put a tube of viruses and water around chick embryos in egg culture systems (in-ovo). We use of viruses of influenza. We connect this tube to a computer or laptop with Radio-SkyPipe. This software helps us to consider

evolutions of waves interior of tube.

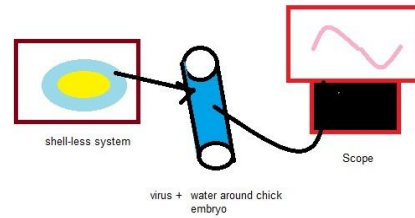


Figure 4: Viruses take signal of DNAs interior of shell-less culture system and send them to Radio-SkyPipe

We also use of an Amperemeter for measuring currents (See Figure 5). If signals couldn't be observed clearly, we can make a coil in a tube of viruses around egg and measure differences between output and input currents.

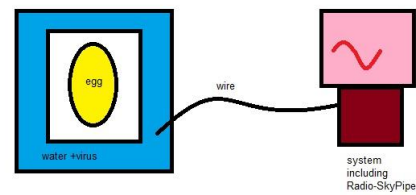


Figure 5: Viruses take signal of DNAs interior of egg system and send them to Radio-SkyPipe

**Results**

**Considering differences between radiated signals of viruses around chick embryos**

In figure 6, we present probability for producing each current which is taken from water + virus around a shell-less culture system by some scopes. We used of Radio-Skypipe software and converter for converting current to electrical signal. This probability is emerged by counting number of times which each current is emerged and dividing it to total current.

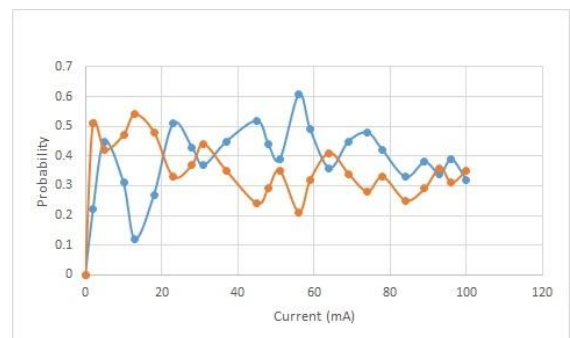


Figure 6: Comparing signals of viruses in a vessel of water which exchange waves with a chick embryo with the gender of female (red color) and male (blue color) interior of shell less culture system (For observing signals, we used of Radio-SkyPipe)

To produce viral system, we mix water with some small amount of milk and involve them with Influenza viruses. In this figure, blue line corresponds to male and red line is related to female. It is observed that male cells send middle currents, while, female cells emit lower currents.

In Figure 7, we show the probability for producing each current which is taken from water + virus around an egg. Egg is located in a container which makes it separated from water. We have added some amount of milk to water for growing viruses and bacteria and involve them with Influenza viruses. It is clear that signals of males (blue color) is different from signals of female (red color). Usually, cells of females produce lower and higher currents, while cells of males produce middle currents. This figure is different from Figure 6 which is due to the existence of shell and its effects on signals.

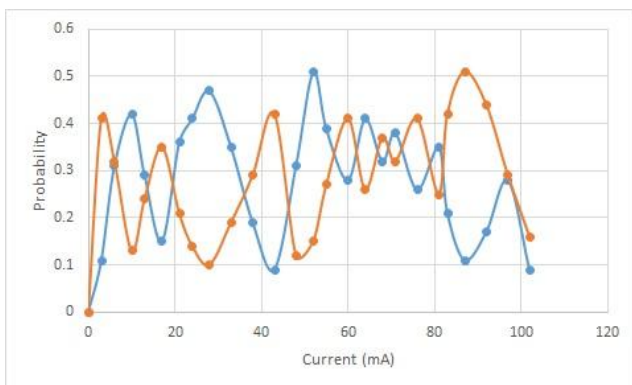


Figure 7: Comparing signals of viruses in water around an egg which exchange waves with a chick embryo with the gender of female (red color) and male (blue color) interior egg (For observing signals, we used of Radio-SkyPipe)

At final stage, using some devices like incubator and cooler, we change temperature and take signals of water and viruses around chick embryos again. In figure 8, we compare radiated signals of chick embryos with the gender of male with chick embryos with the gender of female. It is observed that in both type of embryos, radiated signals grow with temperature.

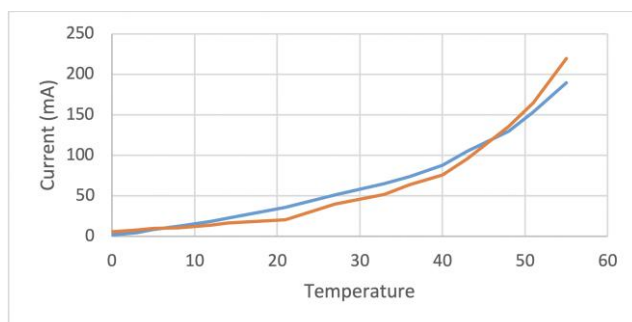


Figure 8: Comparing signals of chick embryo with gender of female (red color) and male with gender of male (blue color) in terms of temperature

This is because that at higher temperature, more viruses and bacteria are born and more signals are emerged. Also, in lower temperature, cells of embryos may be died. Also, for lower and higher temperatures, chick embryos with the gender of female interact more with viruses' respect to males, while for middle temperatures, radiated signals of cells of males are more.

## Discussion

Newly, some authors have suggested new techniques for sexing of chicken eggs by fluorescence and Raman spectroscopy through the shell membrane. On the other hand, other investigators have worked on the communications between viruses outside the shell and DNAs inside the shell and proposed a new virus medical imaging. In this investigation, by mixing two techniques, we have proposed a new virus spectroscopy technique for determining the gender of chick embryo inside the shell. We have shown that radiated electromagnetic waves by viruses outside the shell can help us to determine the gender of chick embryo inside the shell and consider its growth rate.

## References

- Lindner T, Klose R, Streckenbach F, Stahnke T, Hadlich S, Kühn JP, Guthoff RF, Wree A, Neumann AM, Frank M, Glass Ä. Morphologic and biometric evaluation of chick embryo eyes in ovo using 7 Tesla MRI. *Scientific reports*. 2017; 7(1):2647. <https://doi.org/10.1038/s41598-017-02755-4> PMID:28572591 PMCID:PMC5453995
- Streckenbach F, Klose R, Langner S, Langner I, Frank M, Wree A, Neumann AM, Glass Ä, Stahnke T, Guthoff RF, Stachs O, Lindner T. Ultrahigh-Field Quantitative MR Microscopy of the Chicken Eye In Vivo Throughout the In Ovo Period. *Mol Imaging Biol*. 2018.
- Galli R, Preusse G, Uckermann O, Bartels T, Krautwald-Junghanns ME, Koch E, Steiner G. In ovo sexing of domestic chicken eggs by Raman spectroscopy. *Anal chem*. 2016; 88(17):8657-63. <https://doi.org/10.1021/acs.analchem.6b01868> PMID:27512829
- Galli R, Preusse G, Uckermann O, Bartels T, Krautwald-Junghanns ME, Koch E, Steiner G. In ovo sexing of chicken eggs by fluorescence spectroscopy. *Anal Bioanal Chem*. 2017; 409(5):1185. <https://doi.org/10.1007/s00216-016-0116-6> PMID:27966169
- Galli R, Koch E, Preusse G, Schnabel C, Bartels T, Krautwald-Junghanns ME, Steiner G. Contactless in ovo sex determination of chicken eggs. *Current Directions in Biomedical Engineering*, 2017; 3(2):131-134. <https://doi.org/10.1515/cdbme-2017-0027>
- Sepehri A. A mathematical model for DNA. *Int J Geom Methods Mod Phys*. 2017; 14:1750152. <https://doi.org/10.1142/S0219887817501523>
- Fioranelli M, Sepehri A. A mathematical model for the virus medical imaging technique. *International Journal of Geometric Methods in Modern Physics*. 2018; 15(07):1850121. <https://doi.org/10.1142/S0219887818501219>
- Tahara Y, Obara K. A Novel Shell-less Culture System for Chick Embryos Using a Plastic Film as Culture Vessels. *Journal of Poultry Science*. 2014; 51(3):307-312. <https://doi.org/10.2141/jpsa.0130043>

## Beta Blockers and Melanoma

Aleksandra Vojvodic<sup>1</sup>, Petar Vojvodic<sup>2</sup>, Tatjana Vlaskovic-Jovicevic<sup>2</sup>, Goran Sijan<sup>3</sup>, Sanja Dimitrijevic<sup>4</sup>, Zorica Peric-Hajzler<sup>5</sup>, Dusica Matovic<sup>5</sup>, Uwe Wollina<sup>6</sup>, Michael Tirant<sup>7</sup>, Nguyen Van Thuong<sup>8</sup>, Massimo Fioranelli<sup>9</sup>, Torello Lotti<sup>10</sup>

<sup>1</sup>Department of Dermatology and Venereology, Military Medical Academy, Belgrade, Serbia; <sup>2</sup>Clinic for Psychiatric Disorders "Dr. Laza Lazarevic", Belgrade, Serbia; <sup>3</sup>Clinic for Plastic Surgery and Burns, Military Medical Academy, Belgrade, Serbia; <sup>4</sup>Department of Gynecology, Military Medical Academy, Belgrade, Serbia; <sup>5</sup>Military Medical Academy, Belgrade, Serbia; <sup>6</sup>Department of Dermatology and Allergology, Städtisches Klinikum Dresden, Dresden, Germany; <sup>7</sup>University G. Marconi, Rome, Italy; <sup>8</sup>Vietnam National Hospital of Dermatology and Venereology, Hanoi, Vietnam; <sup>9</sup>Department of Nuclear Physics, Sub-nuclear and Radiation, G. Marconi University, Rome, Italy; <sup>10</sup>Department of Dermatology, University of G. Marconi, Rome, Italy

### Abstract

**Citation:** Vojvodic A, Vojvodic P, Vlaskovic-Jovicevic T, Sijan G, Dimitrijevic S, Peric-Hajzler Z, Matovic D, Wollina U, Tirant M, Thuong NV, Fioranelli M, Lotti T. Beta Blockers and Melanoma. *Open Access Maced J Med Sci*. 2019 Sep 30; 7(18):3110-3112. <https://doi.org/10.3889/oamjms.2019.781>

**Keywords:** Beta-blockers; Melanoma

**\*Correspondence:** Massimo Fioranelli, Department of Nuclear Physics, sub-nuclear and radiation, G. Marconi University, Rome, Italy. E-mail: [massimo.fioranelli@gmail.com](mailto:massimo.fioranelli@gmail.com)

**Received:** 12-Jun-2019; **Revised:** 06-Jul-2019; **Accepted:** 07-Jul-2019; **Online first:** 30-Aug-2019

**Copyright:** © 2019 Aleksandra Vojvodic, Petar Vojvodic, Tatjana Vlaskovic-Jovicevic, Goran Sijan, Sanja Dimitrijevic, Zorica Peric-Hajzler, Dusica Matovic, Uwe Wollina, Michael Tirant, Nguyen Van Thuong, Massimo Fioranelli, Torello Lotti. This is an open-access article distributed under the terms of the Creative Commons Attribution-NonCommercial 4.0 International License (CC BY-NC 4.0)

**Funding:** This research did not receive any financial support

**Competing Interests:** The authors have declared that no competing interests exist

Understanding the mechanisms of cancer immune-tolerance is one of the most important challenges. Several studies have demonstrated the potential anticarcinogenic effects of beta-blockers, in patients with prostate cancer, breast cancer, and melanoma. At the other side variety of dermatoses may be caused or aggravated by  $\beta$ -blockers-psoriasis, lichen planus-like drug eruptions (LDE), acrocyanosis, alopecia etc. Beta-blockers have been shown to improve the prognosis of melanoma patients significantly. Propranolol inhibits melanoma by downregulating the tumour angiogenesis but also tumour cell proliferation, invasiveness and local immune suppression. Studies showed that only  $\beta_3$ -but, not  $\beta_2$ -adrenoceptors, were up-regulated under hypoxia in peripheral blood mononuclear cells and selectively expressed in immune cell sub-populations including Treg, MDSC, and NK. They increased NK and CD8 number and cytotoxicity. Catecholamines may retard melanoma progression and that  $\beta$ -blockers may have unrecognised potential as a therapeutic intervention for melanoma, in the prevention of the growth of melanoma in all stages and as adjuvant therapy with other targeted and immune therapies for melanoma.

### Introduction

Understanding the mechanisms of cancer immune-tolerance is one of the most important challenges. Melanoma is one of the most aggressive tumours. Metastatic melanoma remains a significant clinical problem, with five-year survival rates of only 15–20%. It is well known that stress-related catecholamines have a role in cancer and  $\beta$ -adrenoceptors.  $\beta_2$ -adrenoceptors have been identified as new targets in treating melanoma.

Recent studies showed  $\beta_3$ -adrenoceptors have a pleiotropic effect on melanoma microenvironment leading to cancer progression, but

the mechanisms are poorly understood.  $\beta$ -Blockers are one of the most widely used therapeutic agents in both cardiac and non-cardiac ailments, but also, have garnered interest amongst dermatologists based on the discovery of their demonstrated and potential effects in disorders such as pyogenic granulomas, vascular malformations, erythematous-telangiectatic rosacea and wound healing.

Several studies have demonstrated the potential anticarcinogenic effects of beta-blockers, in patients with prostate cancer, breast cancer, and melanoma. At the other side variety of dermatoses may be caused or aggravated by  $\beta$ -blockers-psoriasis, lichen planus-like drug eruptions (LDE), acrocyanosis, alopecia etc.

## Discussion

The use of  $\beta$ -blockers in patients with melanoma for the first time was published by De Giorgi et al. A median follow-up of 2.5 years, 34% of patients not using  $\beta$ -blockers had evidence of disease progression, while only 3% of those who used  $\beta$ -blockers (for other diseases) at the time of diagnosis showed melanoma progression.

Psychosocial factors as chronic stress and depression and anxiety are listed as risk factors for cancer onset and progression.

Under conditions of reduced physiological stress, the T cell-dependent anti-tumour immune response is greatly enhanced. These findings suggest that targeting the  $\beta$ AR signalling pathway directly to reduce stress signalling may provide an innovative approach to improve cancer treatment.

Beta-blockers have been shown to improve the prognosis of melanoma patients significantly. Propranolol inhibits melanoma by downregulating the tumour angiogenesis but also tumour cell proliferation, invasiveness and local immune suppression Calvani et al in their studies showed that only  $\beta_3$ -but not  $\beta_2$ -adrenoceptors, were up-regulated under hypoxia in peripheral blood mononuclear cells and selectively expressed in immune cell sub-populations including Treg, MDSC, and NK. They increased NK and CD8 number and cytotoxicity.

There are several studies with results support previous observation that  $\beta$ -blockers protect patients with thick cutaneous melanoma from disease recurrence and death. In one of them, after only 3 years of treatment, disease progression was observed in 41.2% of the patients in the untreated cohort compared with only 15.8% in the propranolol cohort. Overall survival, although not significant, showed a trend toward decreased mortality in the propranolol group after 3 years of follow-up.

Observational studies have reported the protective effect of  $\beta$ -blockers on the progression of different types of cancers. In total, 25% of them reported previous use of  $\beta$ -blockers that were administered at any time for any other diseases. After a median follow-up of 2.5 years, 34% of the patients in the untreated group showed disease progression. In contrast, only 3% of the patients in the treated group showed progression. After a median follow-up of 8 years and a median duration of  $\beta$ -blocker use of 7.6 years, 45% of the patients in the untreated group and 30% of the patients in the treated group showed disease progression. Notably, in the untreated group, 35% of patients died from melanoma, and only 17% of patients died from melanoma in the treated group. Results of this hospital-based prospective cohort study with a median follow-up of 8 years confirmed our previous results that the use of  $\beta$ -blockers significantly reduced the risk of

Propranolol treatment in the MT/Ret mouse model of melanoma delayed primary tumour growth and metastases development in MT/Ret mice. Propranolol induces a decrease in cell proliferation, and vessel density in the primary tumours and metastases and propranolol significantly reduced the infiltration of myeloid cells, particularly neutrophils, in the primary tumour. Cytotoxic tumour-infiltrating lymphocytes were more frequent in the tumour stroma of treated mice

It is conceivable that a therapeutic approach targeting the beta-adrenergic system could constitute a novel and promising strategy for melanoma treatment.

In one study daily treatment with propranolol slows down tumour development in immunodeficient mice transplanted with human melanoma cells, with the conclusion that non-cardioselective  $\beta$ -blockers affect melanoma progression, and bring first clues about the pathways involved in this antitumor effect.

In conclusion, randomised clinical studies are necessary (the type of  $\beta$ -blocker, characteristics of the tumour, appropriate treatment and efficacy) before  $\beta$ -blockers can be considered a therapeutic option for patients with melanoma. But so far, the observations described suggest that catecholamines may retard melanoma progression and that  $\beta$ -blockers may have unrecognised potential as a therapeutic intervention for melanoma, in the prevention of the growth of melanoma in all stages and as adjuvant therapy with other targeted and immune therapies for melanoma.

## References

1. De Giorgi V, et al. Epidemiology of melanoma: is it still epidemic? What is the role of the sun, sunbeds, Vit D, betablocks, and others? *Dermatol Ther.* 2012; 25(5):392-6. <https://doi.org/10.1111/j.1529-8019.2012.01483.x> PMID:23046017
2. De Giorgi V, Grazzini M, Gandini S, Benemei S, Lotti T, Marchionni N, Geppetti P. Treatment with  $\beta$ -blockers and reduced disease progression in patients with thick melanoma. *Arch Intern Med.* 2011; 171(8):779-81. <https://doi.org/10.1001/archinternmed.2011.131> PMID:21518948
3. De Giorgi V, et al. Epidemiology of melanoma: is it still epidemic? What is the role of the sun, sunbeds, Vit D, betablocks, and others? *Dermatol Ther.* 2012; 25(5):392-6. <https://doi.org/10.1111/j.1529-8019.2012.01483.x> PMID:23046017
4. Calvani M, et al.  $\beta_3$ -Adrenoreceptors Control Mitochondrial Dormancy in Melanoma and Embryonic Stem Cells. *Oxid Med Cell Longev.* 2018. <https://doi.org/10.1155/2018/6816508> PMID:30538804 PMCID:PMC6258109
5. Tatu AL, Elisei AM, Chioncel V, Miulescu M, Nwabudike LC. Immunologic adverse reactions of  $\beta$ -blockers and the skin. *Exp Ther Med.* 2019; 18(2):955-959. <https://doi.org/10.3892/etm.2019.7504> PMID:31384329 PMCID:PMC6639944
6. Kao J, Luu B. Can propranolol prevent progression of

melanoma? JAAPA. 2019; 32(6):1-5.

<https://doi.org/10.1097/01.JAA.0000558241.84003.91>

PMid:31136408

7. Dal Monte M, Calvani M, Cammalleri M, Favre C, Filippi L, Bagnoli P.

8.  $\beta$ -Adrenoceptors as drug targets in melanoma: novel preclinical evidence for a role of  $\beta$ 3-adrenoceptors. Br J Pharmacol. 2019; 176(14):2496-2508. <https://doi.org/10.1111/bph.14552> PMid:30471093

9. Sang Y, Deng Y. Current insights into the epigenetic

mechanisms of skin cancer. Dermatol Ther. 2019; 32(4):e12964. <https://doi.org/10.1111/dth.12964> PMid:31081988

10. Mervis JS, McGee JS. Epigenetic therapy and dermatologic disease: moving beyond CTCL. J Dermatolog Treat. 2019; 30(1):68-73. <https://doi.org/10.1080/09546634.2018.1473550> PMid:29726727



# Formation of Neural Circuits in an Expanded Version of Darwin's Theory: Effects of DNAs in Extra Dimensions and within the Earth's Core on Neural Networks

Massimo Fioranelli<sup>1\*</sup>, Alireza Sepehri<sup>1</sup>, Maria Grazia Roccia<sup>1</sup>, Cota Linda<sup>1</sup>, Chiara Rossi<sup>1</sup>, Amos Dawodo<sup>1</sup>, Petar Vojvodic<sup>2</sup>, Jacopo Lotti<sup>1</sup>, Victoria Barygina<sup>3</sup>, Aleksandra Vojvodic<sup>4</sup>, Uwe Wollina<sup>5</sup>, Michael Tirant<sup>6</sup>, Nguyen Van Thuong<sup>7</sup>, Torello Lotti<sup>8</sup>

<sup>1</sup>Department of Nuclear Physics, Sub-nuclear and Radiation, G. Marconi University, Rome, Italy; <sup>2</sup>Clinic for Psychiatric Disorders "Dr. Laza Lazarevic", Belgrade, Serbia; <sup>3</sup>Department of Biomedical Experimental and Clinical Sciences, University of Florence, Florence, Italy; <sup>4</sup>Department of Dermatology and Venereology, Military Medical Academy, Belgrade, Serbia; <sup>5</sup>Department of Dermatology and Allergology, Städtisches Klinikum Dresden, Dresden, Germany; <sup>6</sup>G. Marconi University, Rome, Italy; <sup>7</sup>Vietnam National Hospital of Dermatology and Venereology, Hanoi, Vietnam; <sup>8</sup>Department of Dermatology, University of G. Marconi, Rome, Italy

## Abstract

**Citation:** Fioranelli M, Sepehri A, Roccia MG, Linda C, Rossi C, Dawodo A, Vojvodic P, Lotti J, Barygina V, Vojvodic A, Wollina U, Tirant M, Van Thuong N, Lotti T. Formation of Neural Circuits in an Expanded Version of Darwin's Theory: Effects of DNAs In Extra Dimensions and within the Earth's Core on Neural Networks. Open Access Maced J Med Sci. 2019 Sep 30; 7(18):3113-3117. <https://doi.org/10.3889/oamjms.2019.769>

**Keywords:** Neural network; DNAs; Extra dimensions; Earth; Darwin; Earthquake

**\*Correspondence:** Massimo Fioranelli, Department of Nuclear Physics, Sub-nuclear and Radiation, G. Marconi University, Rome, Italy. E-mail: [massimo.fioranelli@gmail.com](mailto:massimo.fioranelli@gmail.com)

**Received:** 03-Sep-2019; **Revised:** 14-Sep-2019; **Accepted:** 15-Sep-2019; **Online first:** 10-Sep-2019

**Copyright:** © 2019 Massimo Fioranelli, Alireza Sepehri, Maria Grazia Roccia, Cota Linda, Chiara Rossi, Amos Dawodo, Petar Vojvodic, Jacopo Lotti, Victoria Barygina, Aleksandra Vojvodic, Uwe Wollina, Michael Tirant, Nguyen Van Thuong, Torello Lotti. This is an open-access article distributed under the terms of the Creative Commons Attribution-NonCommercial 4.0 International License (CC BY-NC 4.0)

**Funding:** This research did not receive any financial support

**Competing Interests:** The authors have declared that no competing interests exist

**AIM:** In this paper, inspiring Darwin's theory, we propose a model which connects evolutions of neural circuits with evolutions of cosmos. In this model, in the beginning, there are some closed strings which decay into two groups of open strings.

**METHODS:** First group couple to our universe from one side and produce matters like some genes of DNAs and couple to an anti-universe from another side with opposite sign and create anti-matters like some anti-genes of anti-DNAs. Second group couple to the star and planet's cores like the earth's core from one side and produce anti-matters like stringy black anti-DNA and couple to outer layers of stars and planets like the earth from other side and produce matters like some genes of DNAs on the earth. Each DNA or anti-DNA contains some genetic circuits which act like the circuits of receiver or sender of radio waves. To transfer waves of these circuits, some neurons emerge which some of them are related to genetic circuits of anti-DNAs in anti-universe, and some are related to genetic circuits of stringy black anti-DNA within the earth's core. A collection of these neural circuits forms the little brain on the heart at first and main brain after some time.

**RESULTS:** To examine the model, we remove effects of matters in outer layers of earth in the conditions of microgravity and consider radiated signals of neural circuits in a chick embryo. We observe that in microgravity, more signals are emitted by neural circuits respect to normal conditions. This is a signature of exchanged waves between neural circuits and structures within the earth's core.

**CONCLUSION:** These communications help some animals to predict the time and place of an earthquake.

## Introduction

Until now, two parallel theories have been proposed which one describes evolutions of biological systems and another explains evolutions of cosmos. In biology, Charles Darwin suggested the theory of evolutions and considers the process of developing Human and animals from single-cell creatures [1], [2]. In cosmology, string theory considers evolutions of cosmos and predicts that the origin of all cosmological

objects like black holes, stars, planets and even universes are some highly excited strings [3], [4], [5], [6]. Also, in this theory, there are some extra dimensions which have direct relations with the process of birth and expanding of universes [6], [7], [8]. However, there isn't a theory which considers the effects of cosmological evolutions on biological systems. Does the question arise that what is the relation between string theory and the theory of evolution in biology? For example, should there be a relationship between neural circuits of the brain and

extra dimensions?

Until now, many scientists believe that neural circuits in the brain have the main role in voluntary decisions. Although, some investigators have proved the existence a little brain on the heart which acts like a real brain in the head [9], [10]. Also, recent investigations show that patients who gave hearts from donors, obtain some characteristics of them [11]. Thus, there is a possibility that some characteristics be related to some neural circuits out of the head. These neural circuits may be emerged around initial DNA during developing of the embryo. Before the formation of the head, genes of initial DNAs have a structure like the electronic structures of sender or receiver of radio waves and emit some signals [12]. These signals are carried by molecules of blood and transferred to another place. For this reason, first, a heart emerges which in addition to its main roles, exchange waves with other cells and medium. Eventually, the first group of neurons are emerged near the heart and build a little brain. After some time, the second group of neurons from the neural circuits in the head. These considerations show that initial DNAs have direct effects on the creation of neural circuits.

On the other hand, some investigators showed that there are some missing genes that their effects could be observed in chemical products [13], [14]. If we assume that these missing genes are genes of DNAs in extra dimensions, thus, their effects should be observed in neural circuits. Some neural circuits should be produced by missing genes in extra dimensions.

In this research, we generalise Darwin's theory to cosmology and show that there is a direct relationship between the evolutions of neural circuits and evolutions of the universe. In our model, the origin of biological matters like DNAs and cosmological objects like planets, stars and even universes are closed strings. These closed strings decay into open strings. These strings not only produce cosmological objects but also create DNAs on the earth, anti-DNAs in another universe and stringy black anti-DNAs within the earth's core. Each of these DNAs contains genetic circuits like the circuits of receiver or sender of radio waves. To transfer waves of these genes, some neurons emerge which by joining them neural networks in the brain or little brain are emerged. Thus, some neural circuits in brains correspond to genetic circuits of anti-DNAs in anti-universe and stringy DNAs within the earth's core.

The outline of this paper as follows: In section II, we consider the role of genetic circuits of initial DNAs on the earth information of neural circuits. In section III, we study the effect of anti-DNAs in anti-universes and stringy anti-DNA within the earth's core on the formation of neural circuits. In section IV, we recover exchanged waves between neural circuits and stringy anti-DNA within the earth's core in the

condition of microgravity.

**The role of genetic circuits of initial DNAs information of neural circuits**

Previously, it has been shown that each gene could act as the receiver of the sender of radio waves [12]. This is because each part of a gene behaves like one element of an electronic circuit. For example, adenine and thymine have different topologies, and charge distributions and electric fields could be exchanged between their manifolds. This causes that one of them plays the role of the page with a positive charge and another plays the role of the page with a negative charge. Consequently, two pages with opposite charges emerge and a capacitor is emerged (See Figure 1).

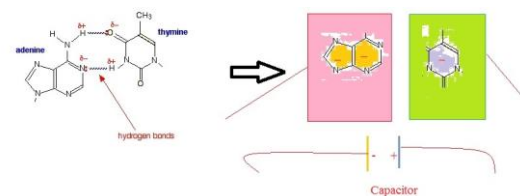


Figure 1: A capacitor is formed from Adenine and Thymine

Also, guanine and cytosine have different topologies and charge distributions. Consequently, an electric field emerges between them and a capacitor is produced (See Figure 2).

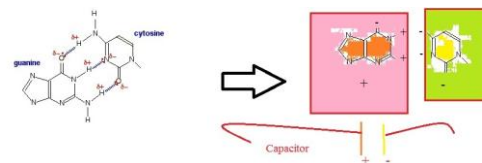


Figure 2: A capacitor is formed from guanine and cytosine

On the other hand, each gene is coiled several times around various axes and has the shape of an inductor (See Figure 3). Collecting these devices produces an electronic circuit like the circuit of a receiver or sender of waves (see Figure 4).

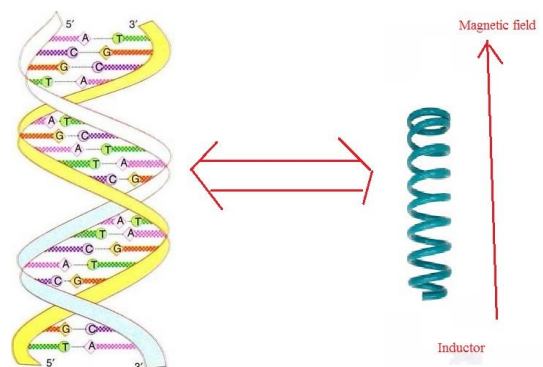


Figure 3: Each gene is coiled several times, and its structure is similar to an inductor

Each gene emits some waves to communicate with other genes and medium. For analysing signals of each gene, one circuit should emerge that receive signals, analyse and send responses. These circuits are formed from neurons. On the other hand, each of these genes emits several types of waves.

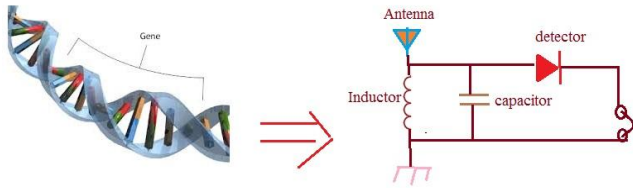


Figure 4: Each gene has a circuit like the circuit of the sender or receiver of radio waves

To transmit these waves between cells, there should be several terminals or receiver in dendrite and axons of a neuron. These neurons join to each other and form a circuit related to one special gene. A collection of these circuits builds neural network interior of a brain (see Figure 5). However, before the formation of the main brain, some neural circuits are emerged around stem cells to form the little brain. In these conditions, in the absence of head in the early stages of embryos, most of the initial signals of initial DNA are transformed by blood molecules from the heart to other cells, and thus, the little brain is formed on the heart first. Then, after some time, the second collection of neuronal circuits emerge which build the neural circuits of a brain.

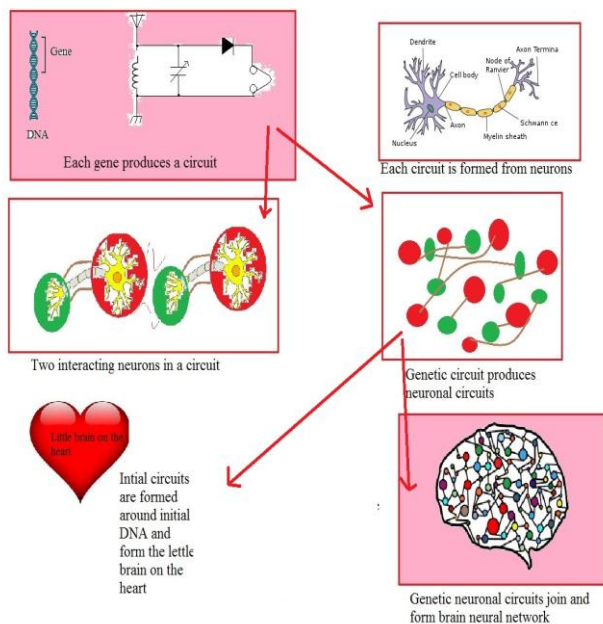


Figure 5: Emergence of neural circuits by exchanging waves between genetic circuits and medium

**The role of the black stringy anti-DNA interior of the earth's core and anti- DNA in anti- universe information of neural circuits of a brain**

One of the main questions in science is about the ability of animals for predicting earthquakes. This ability shows that there should be a relation between neuronal circuits in brain and structures within the earth's core. On the other hand, according to cosmological ideas, there are some anti-universes which are emerged on some anti-branes and interact with our universe. If these theories are true, there should be a relation between DNAs in our universe and DNAs in anti-universes? DNAs in anti-universes should have direct effects on neuronal circuits in the brain.

Summing over these ideas, we propose a new model which connects cosmological models with biological evolutions. In this model, there are some closed strings which decay and produce open strings coupled to two manifolds, one related to the universe and another related to anti-universe. Two sides of each open string have opposite signs and produce matters on one universe and anti-matters on another universe. Consequently, if a gene of a DNA emerges on one universe, an anti-gene of an anti-DNA is produced on another universe. On the other hand, some closed strings decay and produce two types of open strings, which one type produces genes of stringy black anti-DNAs within some stars and planets like the earth's core, and another type produces genes of DNAs on the planets like the earth.

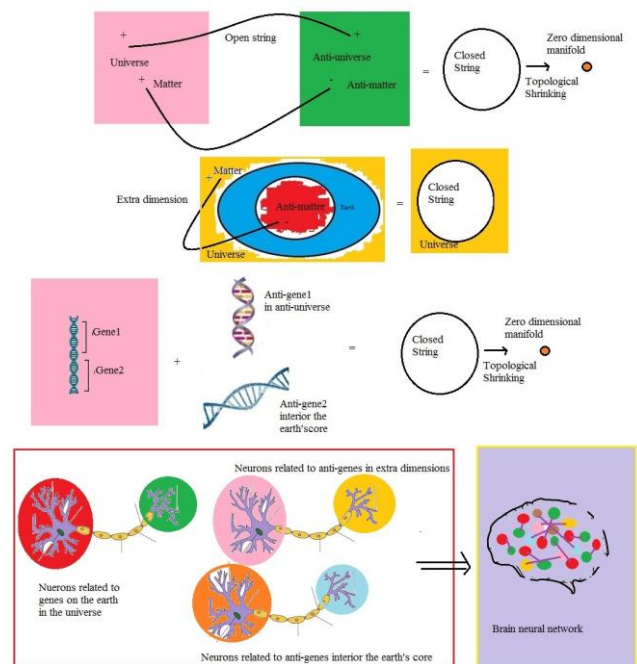


Figure 6: Neural circuits in a brain may be produced by exchanging waves between DNAs on the earth, anti-DNAs in anti-universe and stringy DNAs within the earth's core

Also, one side of open strings are placed within the earth's core, and another side is located on outer layers of earth. Consequently, around the stringy structure within the earth, some anti-matters emerge and in outer layers of earth, the matter emerges. Thus, each DNA on the earth has two parts, one part includes genes in connection with genes of anti-universe, and another includes genes in connection with genes of stringy black anti-DNA within the earth. These genes have some genetic circuits which exchange waves with each other and medium. To transfer these waves, some neuronal circuits emerge. Collections of these neural circuits produce little brain and brain. Thus, each neural network in each brain includes some neuronal circuits which exchange waves with DNAs on the earth, stringy black anti-DNAs within the earth and anti-DNAs in an anti-universe (See Figure 6).

**Using of microgravity for recovery of exchanged waves between neural circuits, anti-DNAs and stringy black anti-DNA within the earth**

To observe the effects of structures within the earth's core, we should remove the effects of matters which are existed on outer layers of earth. To this aim, we use a clinostat to produce the conditions of microgravity. Also, for analysing the process of formation of neuronal circuits, we use of chick embryos. We locate two groups of fertilised eggs in an incubator, one in the condition of microgravity and another in normal conditions. After ten hours, we take one egg of each group, break them and measure their waves by connecting them to a scope. We repeat this experiment for every ten hours until 17 days (See figure 7).

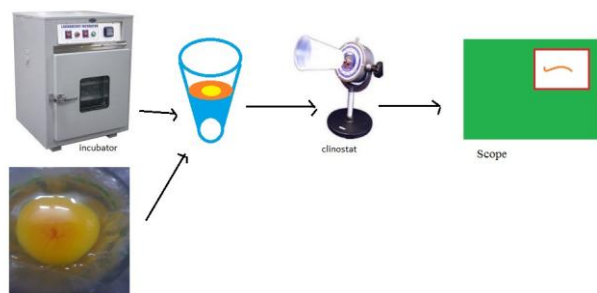


Figure 7: A method for considering the effects of stringy black DNA within the earth's core on the neuronal circuits

Our results show that in the condition of microgravity, larger values of currents could be observed. This means that in these conditions, the number of exchanged waves between the earth and neuronal circuits increases. This is because that by removing effects of gravity of the matter in outer layers, effects of stringy black anti-DNA within the earth's core on the neuronal circuits could be observed better.

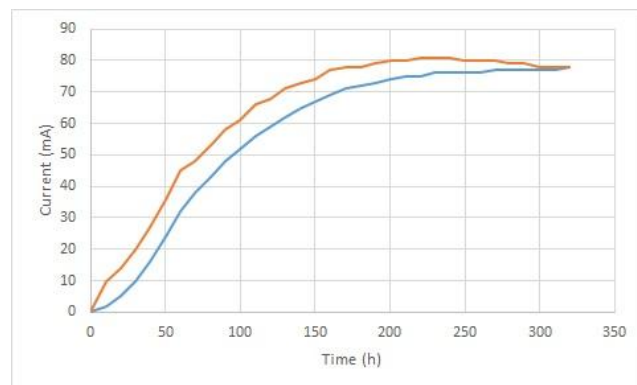


Figure 8: Currents of neuronal circuits in terms of time for a chick embryo

In this research, we have expanded Darwin's theory by connecting it to cosmology and proposed a model which shows that the origin of life is closed strings. In this theory, before the formation of the universe, there are some closed strings which live on the zero-dimensional manifold. These strings decay and two types of open strings emerge. Two sides of each open string have opposite signs. The first type of open strings connects two different manifolds. These strings produce matters like some genes of DNAs in our universe, and another side creates anti-matter like some anti-genes of anti-DNAs in anti-universe. The second type of open strings connects two points of one manifold. They create matters like some genes of some DNAs on the planets like the earth and another produce matters like some anti-genes of some anti-DNAs within the planet's cores like the earth's core. Each gene has a circuit and acts as the receiver or sender of radio waves. To transfer waves of genes, some neurons emerge which join to each other and form a neural network. Thus, some neural circuits exchange waves with stringy anti-DNA within the earth and anti-DNA in an anti-universe. To examine this assumption, we considered radiated waves of neural networks in a chick embryo in the condition of microgravity. Our experiments have shown that by removing the effects of gravity and matters in outer layers of earth, more waves were emitted by neurons. This means that in these conditions, neurons exchange more waves with structures within the earth's core.

## References

1. Bowler PJ. Evolution: The History of an Idea (3rd completely rev. and expanded ed. University of California Press, 2013.
2. Browne J. Charles Darwin: The Power of Place. 2. Jonathan Cape, 2002.
3. Smolin L. The Life of the Cosmos Oxford University Press. New York and Weidenfeld and Nicolson, London. 1997.
4. Dimopoulos S, Emparan R. String balls at the LHC and beyond.

- Physics Letters B. 2002; 526(3-4):393-8.
5. Susskind L. Some Speculations about Black Hole Entropy in String Theory. hep-th/9309145; Halyo E, Rajaraman A, Susskind L. Braneless Black Holes. Phys. Lett. B 1997; 392:319-322. [https://doi.org/10.1016/S0370-2693\(96\)01544-4](https://doi.org/10.1016/S0370-2693(96)01544-4)
6. Horowitz GT, Polchinski J. Correspondence principle for black holes and strings. Physical Review D. 1997; 55(10):6189-97. <https://doi.org/10.1103/PhysRevD.55.6189>
7. Randall L, Raman S. Large mass hierarchy from a small extra dimension. Phys Rev Lett. 1999; 83:3370-3373. <https://doi.org/10.1103/PhysRevLett.83.3370>
8. Shifman M. Large Extra Dimensions: Becoming acquainted with an alternative paradigm. Crossing the boundaries: Gauge dynamics at strong coupling. Int J Mod Phys A. 2009; 25:199-225.
9. Armour, JA. The little brain on the heart. Cleve Clin J Med. 2007; 74(1):S48-51.
10. Armour JA. Potential clinical relevance of the 'little brain' on the mammalian heart. Exp Physiol. 2015; 100(4):348-353.
11. Pearsall P. The Heart's Code: Tapping the wisdom and power of our heart energy. New York; Broadway Books, 1999.
12. Sepehri A. A mathematical model for DNA, Int J Geom Methods Mod Phys. 2017; 14:1750152.
13. Hargreaves A. The hunt for dark DNA. New Scientist. 2018; 237(3168):29-31. [https://doi.org/10.1016/S0262-4079\(18\)30440-8](https://doi.org/10.1016/S0262-4079(18)30440-8)
14. Hargreaves A. Introducing 'dark DNA'-the phenomenon that could change how we think about evolution. Academic rigour. journalistic flair. 2017.

# Psychotherapy Role in Treatment of Chronic Spontaneous Urticaria in a 32 Years Old Female Patient

Petar Vojvodic<sup>1</sup>, Tatjana Vlaskovic-Jovicevic<sup>1</sup>, Jovana Vojvodic<sup>1</sup>, Aleksandra Vojvodic<sup>2</sup>, Goran Sijan<sup>3</sup>, Sanja Dimitrijevic<sup>4</sup>, Zorica Peric-Hajzler<sup>5</sup>, Dusica Matovic<sup>5</sup>, Uwe Wollina<sup>6</sup>, Michael Tirant<sup>7</sup>, Nguyen Van Thuong<sup>8</sup>, Massimo Fioranelli<sup>9\*</sup>, Torello Lotti<sup>10</sup>

<sup>1</sup>Clinic for Psychiatric Disorders "Dr. Laza Lazarevic", Belgrade, Serbia; <sup>2</sup>Department of Dermatology and Venereology, Military Medical Academy, Belgrade, Serbia; <sup>3</sup>Clinic for Plastic Surgery and Burns, Military Medical Academy, Belgrade, Serbia; <sup>4</sup>Department of Gynecology, Military Medical Academy, Belgrade, Serbia; <sup>5</sup>Military Medical Academy, Belgrade, Serbia; <sup>6</sup>Department of Dermatology and Allergology, Städtisches Klinikum Dresden, Dresden, Germany; <sup>7</sup>University G. Marconi, Rome, Italy; <sup>8</sup>Vietnam National Hospital of Dermatology and Venereology, Hanoi, Vietnam; <sup>9</sup>Department of Nuclear Physics, Sub-nuclear and Radiation, G. Marconi University, Rome, Italy; <sup>10</sup>Department of Dermatology, University of G. Marconi, Rome, Italy

**Citation:** Vojvodic P, Vlaskovic-Jovicevic T, Vojvodic J, Vojvodic A, Sijan G, Dimitrijevic S, Peric-Hajzler Z, Matovic D, Wollina U, Tirant M, Van Thuong N, Fioranelli M, Lotti T. Psychotherapy Role in Treatment of Chronic Spontaneous Urticaria In A 32 Years Old Female Patient. Open Access Maced J Med Sci. 2019 Sep 30; 7(18):3118-3120.  
<https://doi.org/10.3889/oamjms.2019.773>

**Keywords:** Psychotherapy; Urticaria; Skin diseases; GAD; SSRI

**\*Correspondence:** Massimo Fioranelli, Department of Nuclear Physics, Sub-nuclear and Radiation, G. Marconi University, Rome, Italy. E-mail: [massimo.fioranelli@gmail.com](mailto:massimo.fioranelli@gmail.com)

**Received:** 13-Jun-2019; **Revised:** 04-Jul-2019; **Accepted:** 05-Jul-2019; **Online first:** 30-Aug-2019

**Copyright:** © 2019 Petar Vojvodic, Tatjana Vlaskovic-Jovicevic, Jovana Vojvodic, Aleksandra Vojvodic, Goran Sijan, Sanja Dimitrijevic, Zorica Peric-Hajzler, Dusica Matovic, Uwe Wollina, Michael Tirant, Nguyen Van Thuong, Massimo Fioranelli, Torello Lotti. This is an open-access article distributed under the terms of the Creative Commons Attribution-NonCommercial 4.0 International License (CC BY-NC 4.0)

**Funding:** This research did not receive any financial support

**Competing Interests:** The authors have declared that no competing interests exist

## Abstract

As indicated by the latest scientific evidence, the lines between different fields of medicine gradually blur and overlap more and more. Psychiatry and dermatology have seen this trend in the last decade as an ever-increasing number of studies suggest the strong connection of many dermatological syndromes and diseases with psychiatric conditions and vice versa. It seems that the relationship is more intertwined than previously believed and the effects of different multidisciplinary approaches to diagnostic and treatment are being considered.

The aim of this case report is to highlight the effect of psychotherapy on chronic spontaneous urticaria which is tightly related to the maladaptive stress response.

## Introduction

As indicated by the latest scientific evidence, the lines between different fields of medicine gradually blur and overlap more and more. Psychiatry and dermatology have seen this trend in the last decade as an ever-increasing number of studies suggest the strong connection of many dermatological syndromes and diseases with psychiatric conditions and vice versa. It seems that the relationship is more intertwined than previously believed and the effects of different multidisciplinary approaches to diagnostic and treatment are being considered.

This case report aims to highlight the effect of psychotherapy on chronic spontaneous urticaria which is tightly related to the maladaptive stress response.

## Case Presentation

A 32 years old female patient came into the psychiatrist office for an interview. This was the first interview, and she didn't have any prior history of mental conditions. During the interview, she disclosed

that her symptoms came about up three months ago when she got engaged to a man, she was dating for 3 years. The engagement triggered a memory of a traumatic event that happened early in their relationship when she was raped by an unknown man while under the influence of alcohol. The incident was not reported to the authorities, and she repressed the experience without further contemplation or seeking psychiatric help. She reported that, in the last three months, she started having recurring thoughts of the incident that produced severe anxiety followed by increased heart rate, muscle tension, dizziness, and acute urticaria, rash and lividity of the skin on the torso, arms and neck area. During this period, she had trouble sleeping with a recurring episode of night terrors, irritability, depressed mood and intense feelings of guilt, shame and unworthiness. Also, her ability to function in everyday tasks was, self reportedly, compromised. The novel skin condition caused her to feel more anxiety which in turn worsened the symptoms she had experienced so far. The acute urticaria seemed to be connected to her mental state as it dramatically flared up within 10 seconds of becoming anxious. She went for an examination to a dermatologist office, and upon completion, she was instructed to seek psychiatric opinion on diagnosis and treatment for her condition.

- There was no family history of mental illness or skin diseases;

- GAD7 test score 18/21 which correlates to severe anxiety;

- HAMD test score 10 which correlates to mild depression;

- The blood test showed no abnormalities;

- Common allergy testing battery report came back negative.

The working diagnosis was generalised anxiety disorder (GAD) as she satisfied most of the DSM 5 criteria with consideration of post-traumatic stress disorder. The dermatological diagnosis was chronic spontaneous urticaria with no proposed treatment.

The patient refused proposed treatment for GAD in the form of SSRI since she was trying to conceive with her partner, so the treatment consisted only of psychotherapeutic interventions. The psychotherapeutic approach used was rational emotive behavioural therapy (REBT) once per week over 4 months. The interventions used were: analysis of dysfunctional and irrational beliefs; empirical and functional dispute; formation of healthy, rational beliefs; discovering and refuting cognitive distortions; rational emotive imagination; behavioural exercises; home assignments to reinforce new insights and biblio-therapy. Throughout the treatment, the client and the doctor formed a satisfactory alliance and the patient actively participated. GAD7 test result on month two of treatment was 13 which correlates to

moderate anxiety, on month three was 9 which correlates to mild anxiety and on month four 6 which also correlates to mild anxiety. During the last month of the treatment, the patient haven had a single flair of urticaria, and her level of life function and efficacy returned to normal. The flairs of urticaria continued to manifest over the first month in the situations when the patient got anxious. By the end of the treatment, and with gaining valuable emotional insight, the patient gradually started reporting fewer anxiety episodes and less urticaria flaring.

## Discussion

Development of a comorbid mental condition in patients with chronic spontaneous urticaria is well documented [11], [12] and brief emotional arousal induced flare-ups [14] can, in turn, worsen the both mental and skin condition. As with our patient, scientific evidence suggests that psychological trauma and stressful life events often precede the development of chronic spontaneous urticaria [15], [16]. It is known that acute stress triggers the release of neuropeptides in the skin [18], [20]. Mast cells are an important target of cutaneous neuropeptides. Substance P as a neuropeptide stress mediator leads to enhanced mast cell response to IgE antibodies. This reaction is called neurogenic inflammation, and case studies suggest that it is especially potentiated with acute stress [14]. Therefore, acute stress can lower the threshold for urticaria and affect the severity of the disease. Acute stress triggers a typical stress reaction and Leeds release of hormones such as cortisol and adrenaline, while reducing stress lowers morning cortisol concentration and urticaria symptoms [13].

The effectiveness of psychotherapy is well documented when dealing with psychological stress and conditions such as generalised anxiety disorder. The scientific evidence also suggests that the effectiveness of psychotherapy is on par with the effects of psychotropic medication [1]. Psychotherapy is known to modulate stress responses and consequentially lower the excretion of adrenaline and cortisol [2]. Normalising the stress responses can, in turn, lead to reduced release of skin neuropeptides and thus raise the threshold for chronic spontaneous urticaria flareups. With our patient, irrational beliefs and cognitive distortions regarding the memory of the traumatic event were responsible for the intense emotional distress. It is safe to assume that this led to the development of the chronic spontaneous urticaria and periodic exacerbations as emotional stress repeated and got more severe. Physiological connections and interdependence of her body and her mental state led to the development of a somatic disease in the form of urticaria. Those same

connections enabled the psychiatrist to successfully administer the taking-therapy cure that led to the satisfactory remission of both symptoms of GAD and urticaria. As an approach to human health and wellbeing inevitably evolves and becomes more holistic, psychiatry doctrine and psychotherapy interventions gain more traction and become an integral part of treating and curing diseases of the body and soul.

## References

1. Zuberbier T, Asero R, Bindslev-Jensen C, Walter Canonica G, Church MK, Gimenez-Arnau A, et al. EAACI/GA(2)LEN/EDF/WAO guideline: definition, classification and diagnosis of urticaria. *Allergy*. 2009; 64(10):1417-1426. <https://doi.org/10.1111/j.1398-9995.2009.02179.x> PMID:19772512
2. Maurer M, Weller K, Bindslev-Jensen C, Gimenez-Arnau A, Bousquet PJ, Bousquet J, et al. Unmet clinical needs in chronic spontaneous urticaria. A GA(2)LEN task force report. *Allergy*. 2011; 66(3):317-330. <https://doi.org/10.1111/j.1398-9995.2010.02496.x> PMID:21083565
3. Czubalski K, Rudzki E. Neuropsychic factors in physical urticaria. *Dermatologica* 1977; 154(1):1-4. <https://doi.org/10.1159/000251023> PMID:844637
4. Fava GA, Perini GI, Santonastaso P, Fornasa CV. Life events and psychological distress in dermatologic disorders: psoriasis, chronic urticaria and fungal infections. *Br J Med Psychol*. 1980; 53(3):277-282. <https://doi.org/10.1111/j.2044-8341.1980.tb02551.x> PMID:7417387
5. Gupta MA, Gupta AK. Chronic idiopathic urticaria and post-traumatic stress disorder (PTSD): an under-recognized comorbidity. *Clin Dermatol*. 2012; 30(3):351-354. <https://doi.org/10.1016/j.clindermatol.2012.01.012> PMID:22507051
6. Theoharides TC, Stewart JM, Taracanova A, Conti P, Zouboulis CC. Neuroendocrinology of the skin. *Rev Endocr Metab Disord*. 2016; 17(3):287-294. <https://doi.org/10.1007/s11154-016-9369-9> PMID:27338934
7. Peters EM, Liezmann C, Klapp BF, Kruse J. The neuroimmune connection interferes with tissue regeneration and chronic inflammatory disease in the skin. *Ann N Y Acad Sci*. 2012; 1262(1):118-126. <https://doi.org/10.1111/j.1749-6632.2012.06647.x> PMID:22823443
8. Brahler C, Brosig B, Kupfer J, Brahler E. Sick role and psychoimmunologic parameters during the course of treatment--a quantitative single case analysis of urticaria. *Psychother Psychosom Med Psychol*. 1994; 44(9-10):323-330.
9. Cuijpers P1, Sijbrandij M, Koole SL, Andersson G, Beekman AT, Reynolds CF 3rd. The efficacy of psychotherapy and pharmacotherapy in treating depressive and anxiety disorders: a meta-analysis of direct comparisons. *World Psychiatry*. 2013; 12(2):137-48. <https://doi.org/10.1002/wps.20038> PMID:23737423 PMID:PMC3683266
10. Fischer S1, Strawbridge R2, Vives AH2, Cleare AJ2. Cortisol as a predictor of psychological therapy response in depressive disorders: systematic review and meta-analysis. *Br J Psychiatry*. 2017; 210(2):105-109. <https://doi.org/10.1192/bjp.bp.115.180653> PMID:27908897



# A Mathematical Model for the Signal of Death and Emergence of Mind Out of Brain in Izhikevich Neuron Model

Massimo Fioranelli<sup>1\*</sup>, Alireza Sepehri<sup>1</sup>, Maria Grazia Roccia<sup>1</sup>, Chiara Rossi<sup>1</sup>, Jacopo Lotti<sup>1</sup>, Victoria Barygina<sup>2</sup>, Petar Vojvodic<sup>3</sup>, Aleksandra Vojvodic<sup>4</sup>, Tatjana Vlaskovic-Jovicevic<sup>3</sup>, Jovana Vojvodic<sup>3</sup>, Sanja Dimitrijevic<sup>5</sup>, Zorica Peric-Hajzler<sup>6</sup>, Dusica Matovic<sup>6</sup>, Goran Sijan<sup>7</sup>, Uwe Wollina<sup>8</sup>, Michael Tirant<sup>9</sup>, Nguyen Van Thuong<sup>10</sup>, Torello Lotti<sup>11</sup>

<sup>1</sup>Department of Nuclear Physics, Sub-nuclear and Radiation, G. Marconi University, Rome, Italy; <sup>2</sup>Department of Biomedical Experimental and Clinical Sciences, University of Florence, Florence, Italy; <sup>3</sup>Clinic for Psychiatric Disorders "Dr. Laza Lazarevic", Belgrade, Serbia; <sup>4</sup>Department of Dermatology and Venereology, Military Medical Academy, Belgrade, Serbia; <sup>5</sup>Department of Gynecology, Military Medical Academy, Belgrade, Serbia; <sup>6</sup>Military Medical Academy, Belgrade, Serbia; <sup>7</sup>Clinic for Plastic Surgery and Burns, Military Medical Academy, Belgrade, Serbia; <sup>8</sup>Department of Dermatology and Allergology, Städtisches Klinikum Dresden, Dresden, Germany; <sup>9</sup>University G. Marconi, Rome, Italy; <sup>10</sup>Vietnam National Hospital of Dermatology and Venereology, Hanoi, Vietnam; <sup>11</sup>Department of Dermatology, University of G. Marconi, Rome, Italy

## Abstract

**Citation:** Fioranelli M, Sepehri A, Roccia MG, Rossi C, Lotti J, Barygina V, Vojvodic P, Vojvodic A, Vlaskovic-Jovicevic T, Vojvodic J, Dimitrijevic S, Peric-Hajzler Z, Matovic D, Sijan G, Wollina U, Tirant M, Van Thuong N, Lotti T. A Mathematical Model for the Signal of Death and Emergence of Mind Out of Brain in Izhikevich Neuron Model. Open Access Maced J Med Sci. 2019 Sep 30; 7(18):3121-3126.  
<https://doi.org/10.3889/oamjms.2019.774>

**Keywords:** Izhikevich; Neuron; Bio-Bion; Action Potential

**\*Correspondence:** Massimo Fioranelli, Department of Nuclear Physics, Sub-nuclear and Radiation, G. Marconi University, Rome, Italy. E-mail: [massimo.fioranelli@gmail.com](mailto:massimo.fioranelli@gmail.com)

**Received:** 03-Jul-2019; **Revised:** 14-Aug-2019; **Accepted:** 15-Aug-2019; **Online first:** 11-Sep-2019

**Copyright:** © 2019 Massimo Fioranelli, Alireza Sepehri, Maria Grazia Roccia, Chiara Rossi, Jacopo Lotti, Victoria Barygina, Petar Vojvodic, Aleksandra Vojvodic, Tatjana Vlaskovic-Jovicevic, Jovana Vojvodic, Sanja Dimitrijevic, Zorica Peric-Hajzler, Dusica Matovic, Goran Sijan, Uwe Wollina, Michael Tirant, Nguyen Van Thuong, Torello Lotti. This is an open-access article distributed under the terms of the Creative Commons Attribution-NonCommercial 4.0 International License (CC BY-NC 4.0)

**Funding:** This research did not receive any financial support

**Competing Interests:** The authors have declared that no competing interests exist

**AIM:** In this paper, using a mathematical model, we will show that for special exchanged photons, the Hamiltonian of a collection of neurons tends to a constant number and all activities is stopped. These photons could be called as the dead photons. To this aim, we use concepts of Bio-Bion in Izhikevich Neuron model.

**METHODS:** In a neuron, there is a page of Dendrite, a page of axon's terminals and a tube of Schwann cells, axon and Myelin Sheath that connects them. These two pages and tube form a Bio-Bion. In a Bio-Bion, exchanging photons and some charged particles between terminals of dendrite and terminals of axon leads to the oscillation of neurons and transferring information. This Bion produces the Hamiltonian, wave equation and action potential of Izhikevich Neuron model. Also, this Bion determines the type of dependency of parameters of Izhikevich model on temperature and frequency and obtains the exact shape of membrane capacitance, resting membrane potential and instantaneous threshold potential.

**RESULTS:** Under some conditions, waves of neurons in this Bion join to each other and potential shrinks to a delta function. Consequently, total Hamiltonian of the system tends to a constant number and system of neuron act like a dead system. Finally, this model indicates that all neurons have the ability to produce similar waves and signals like waves of the mind.

**CONCLUSION:** Generalizing this to biology, we can claim that neurons out of the brain can produce signals of minding and imaging and thus mind isn't confined to the brain.

## Introduction

Recently, Izhikevich has proposed a neuronal dynamical model which is a simple model that faithfully reproduces all the neurocomputational dynamical features of the neuron [1]. This model is obtained by reducing some Biological aspects of Hodgkin-Huxley (HH) neuron using bifurcation methods [2]. Until now, many discussions have been done on this subject. For example, in one research, authors have focused herein on the Izhikevich neuron

model and compared the characteristics of Chaotic resonance in the chaotic states arising through the period-doubling or tangent bifurcation routes. They have found that the signal response in Chaotic resonance had a unimodal maximum concerning the stability of chaotic orbits in the tested chaotic states [3]. In another research, authors have presented a Multiplier less Noisy Izhikevich Neuron (MNIN) model, which was used for digital implementation of Biological neural networks in large scale. Simulation results have shown that the MNIN model reproduces the same operations of the original noisy Izhikevich

neuron [4]. In another paper, authors have performed numerical simulations of synaptically coupled Izhikevich networks under the effect of general non-Gaussian Levy noise. Firing dynamics of an all-to-all coupled Izhikevich network and two excitatory coupled Izhikevich networks with differing adaptation properties have been studied in response to applied Levy noise [5]. And in one of newest works, authors have considered the effect of synaptic interaction (electrical and chemical) as well as structural connectivity on synchronisation transition in network models of Izhikevich neurons which spike regularly with beta rhythms. They have found a wide range of behaviour including continuous transition, explosive transition, as well as lack of global order [6].

In this paper, we show that in an Izhikevich Neuron model, neurons join to each other and build a stable system. In some conditions, exchanged photons between neurons join to each other produce a constant Hamiltonian. This leads to a stop in transferring information and the death of the system. To this aim, we show that a neuron has a structure similar to Bio-Blons. These Bio-Blons are formed from a page of Dendrite, a page of axon's terminals and a tube of Schwann cells, axon and Myelin Sheath that connects them. Previously, it has been shown that exchanged photons between sheets of a graphene system could produce a nano-Bion [7]. The same Bion can emerge along neurons. Hamiltonian, action potential and wave equation in this Bio-Bion is very similar to an action potential and wave equation in Izhikevich Neuron model. We also use the concepts in [8] and propose a new temperature model for oscillating neurons. For some temperatures and rotating velocity, total potential tends to delta function and system is dead. We can save the system by removing some neurons. For example, in a body, we can remove neurons of the brain and prevention of death. In these conditions, neurons of the spinal cord do tasks of brain-like minding.

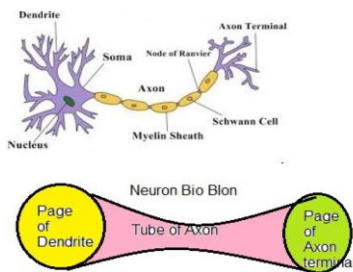


Figure 1: Similarity between the structure of a neuron and a Bio-Blon

The outline of the paper is as follows. In section II, we will construct  $c$  in a Bio-Bion. In section III, we will consider the dependency of Izhikevich parameters on temperature and frequency. In section IV, we will consider the origin of waves of death in the Izhikevich model. In section V, we will discuss the

results of experiments on birds. We also show that birds without a brain can continue minding. The last section is devoted to conclusions.

### Constructing the Izhikevich Neuron Model in Bio-Bion

The Izhikevich Neuron model which reproduce spiking and bursting behaviour of many known types of neurons are described by the pair of the differential equation:

$$\begin{aligned} C \frac{dV}{dt} &= k(V - V_r)(V - V_t) - DU + S \\ \frac{dU}{dt} &= a[b(V - V_r) - U] \end{aligned} \tag{1}$$

where  $t$  is time,  $C$  is membrane capacitor,  $V$  is membrane potential,  $V_r$  is the resting membrane potential,  $V_t$  is the instantaneous threshold potential,  $U$  is the recovery variable,  $S$  is stimulus (synaptic: excitatory or inhibitory, external, noise) and  $a, b, D$  are some constants.

To consider the rotating neuron, we specialise to an embedding of the neuron world volume in Minkowski space-time with metric [9];

$$ds^2 = -dt^2 + dr^2 + r^2(d\theta^2 + \sin^2\theta d\phi^2) + \sum_{i=1}^6 dx_i^2 \tag{2}$$

Without background fluxes. Here,  $t$  is time,  $r$  is the radius of the page of Dendrite and  $\theta$  is the angle of rotation. When neurons oscillate with frequency  $\omega$ , a rotating velocity emerges, and this velocity produces an acceleration ( $a$ ). We can write:

$$a = l_0 \omega^2 \tag{3}$$

In this case, the relation between the world volume coordinates of the rotating neuron ( $\tau, \sigma$ ) and the coordinates of Minkowski space-time ( $t, r$ ) are [9];

$$at = e^{a\sigma} \sinh(a\tau) \quad ar = e^{a\sigma} \cosh(a\tau) \tag{4}$$

where  $a$  is the acceleration of rotating neuron. We can suppose that the coordinate along the separation distance between Dndrite and axon's terminals ( $x^4 = z$ ) depends on the  $r = \pm \frac{1}{a} e^{\pm a\sigma} \cosh(a\tau)$  and by using equations (4), rewrite equations (2) as [9];

$$\begin{aligned} ds_7^2 &= -dt^2 + \left(1 + \left(\frac{dz}{dr}\right)^2\right) dr^2 + r^2(d\theta^2 + \sin^2\theta d\phi^2) + \sum_{i=1}^5 dx_i^2 = \\ &= \left(e^{2a\sigma} + \frac{1}{\sinh^2(a\tau)} \left(\frac{dz}{d\tau}\right)^2\right) d\tau^2 - \left(e^{2a\sigma} + \frac{1}{\cosh^2(a\tau)} \left(\frac{dz}{d\sigma}\right)^2\right) d\sigma^2 + \\ &= \frac{1}{\sinh(a\tau) \cosh(a\tau)} \left(\frac{dz}{d\tau} \frac{dz}{d\sigma}\right) d\tau d\sigma + \left(\frac{1}{a} e^{a\sigma} \cosh(a\tau)\right)^2 (d\theta^2 + \sin^2\theta d\phi^2) + \sum_{i=1}^5 dx_i^2 \end{aligned} \tag{5}$$

Now, we can replace acceleration with it's equivalent temperature. Previously, it has been shown that temperature has the below relation with acceleration [9]:

$$\begin{aligned} v &= a\tau \\ \rightarrow T &= \frac{T_0}{\sqrt{1 - \frac{v^2}{c^2}}} = \frac{T_0}{\sqrt{1 - \frac{a^2\tau^2}{c^2}}} \\ v = a\tau &= c\sqrt{1 - \frac{T_0^2}{T^2}} \end{aligned} \tag{6}$$

Where  $T$  is the temperature of the Blon and  $T_0$  is the critical temperature. However, this relation is questionable. Based on this relation, the superconductivity phenomena depend on the system velocity!! You can move a system with special velocities to reduce its temperature to the less than of its critical temperature, and then the system shows

superconductivity by itself!! It means that a physical phenomenon (superconductivity) depends on the system velocity, a result in direct conflict with the relativity law claiming that the physical laws are independent of the observer velocity. This relativistic relation for temperature is not a true relation, and in fact, the temperature's relation depends on the thermocouple apparatus used. A true thermocouple rejects this definition of temperature (For example, see [8], [10], [11]). Thus, to obtain a true relation between temperature and acceleration, we use concepts of Blon:

$$dM_{I-A/B} = T_{I-A/B} dS_{I-A/B} \rightarrow T_{I-A/B} = \frac{dM_{I-A/B}}{dS_{I-A/B}} \quad (7)$$

Previously, thermo-dynamical parameters have been obtained in [12]:

$$\begin{aligned} dM_{I-A} &= \frac{dM_{I-A}}{dz_{I-A}} dz_{I-A} \\ dz_{I-A} &= dz_{I-B} \simeq \left( e^{-4a\sigma} \sinh^2(a\tau) \cosh^2(a\tau) \right) \times \\ &\left( \frac{F_{DBIJ,A}(\tau, \sigma) \left( \frac{F_{DBIJ,A}(\tau, \sigma)}{F_{DBIJ,A}(\tau, \sigma_0)} - e^{-4a(\sigma - \sigma_0)} \frac{\cosh^2(a\tau_0)}{\cosh^2(a\tau)} \right)^{-\frac{1}{2}} \sinh^2(a\tau_0)}{F_{DBIJ,A}(\tau_0, \sigma) \left( \frac{F_{DBIJ,A}(\tau_0, \sigma)}{F_{DBIJ,A}(\tau_0, \sigma_0)} - e^{-4a(\sigma - \sigma_0)} \frac{\cosh^2(a\tau_0)}{\cosh^2(a\tau)} \right)^{-\frac{1}{2}} \sinh^2(a\tau)} \right)^{\frac{1}{2}} \\ \frac{dM_{I-A}}{dz} &= \frac{dM_{I-B}}{dz} = \frac{4T_{0J-A}^2}{\pi T_{0J-A}^4} \frac{F_{DBIJ,A}(\sigma, \tau) \left( \frac{1}{2} e^{a\sigma} \cosh(a\tau) \right)^2 \left( \sinh^2(a\tau) + \cosh^2(a\tau) \right)}{\sqrt{F_{DBIJ,A}^2(\sigma, \tau) - F_{DBIJ,A}^2(\sigma_0, \tau)}} \times \\ &\frac{4 \cosh^2 \alpha_{I-A} + 1}{\cosh^4 \alpha_{I-A}} \\ dS_{I-A} &= dS_{I-B} = \frac{4T_{0J-A}^2}{\pi T_{0J-A}^4} \frac{F_{DBIJ,A}(\sigma, \tau) \left( \frac{1}{2} e^{a\sigma} \cosh(a\tau) \right)^2 \left( \sinh^2(a\tau) + \cosh^2(a\tau) \right)}{\sqrt{F_{DBIJ,A}^2(\sigma, \tau) - F_{DBIJ,A}^2(\sigma_0, \tau)}} \times \\ &\frac{4}{\cosh^4 \alpha_{I-A}} \end{aligned} \quad (8)$$

using relation (8) in relation (7), we can obtain an explicit form of temperature in an accelerating neuron:

$$\begin{aligned} T_{I-A} &= T_{0J-A} \left( 4 \cosh^2 \alpha_{I-A} + 1 \right) \times \\ &\left( e^{-4a\sigma} \sinh^2(a\tau) \cosh^2(a\tau) \right) \times \\ &\left( \frac{F_{DBIJ,A}(\tau, \sigma) \left( \frac{F_{DBIJ,A}(\tau, \sigma)}{F_{DBIJ,A}(\tau, \sigma_0)} - e^{-4a(\sigma - \sigma_0)} \frac{\cosh^2(a\tau_0)}{\cosh^2(a\tau)} \right)^{-\frac{1}{2}} \sinh^2(a\tau_0)}{F_{DBIJ,A}(\tau_0, \sigma) \left( \frac{F_{DBIJ,A}(\tau_0, \sigma)}{F_{DBIJ,A}(\tau_0, \sigma_0)} - e^{-4a(\sigma - \sigma_0)} \frac{\cosh^2(a\tau_0)}{\cosh^2(a\tau)} \right)^{-\frac{1}{2}} \sinh^2(a\tau)} \right)^{\frac{1}{2}} \end{aligned} \quad (9)$$

Above equations show the explicit relation between temperatures and acceleration in a neuron. However, to obtain the relation between temperature and rotating velocity, we should take a derivation of the above equations, put  $(\omega = \frac{d\sigma}{dt})$  and obtain the below relation:

$$a \sim 2\pi T = \frac{T_0 \ln^{-1} \left[ 1 - \frac{\omega^2}{\omega_0^2} \right]}{\left| 1 - \frac{\omega^2}{\omega_0^2} \right|^{\frac{1}{2}}} \quad (10)$$

where  $T_0$  is the temperature of non-rotating neuron and  $\omega$  is the frequency. Also,  $\omega_0$  is the upper limit frequency of neurons. Substituting equation (10) in equations (5), we obtain:

$$\begin{aligned} ds_I^2 &= \\ &\left( e^{-\frac{T_0 \ln^{-1} \left[ 1 - \frac{\omega^2}{\omega_0^2} \right]}{\left| 1 - \frac{\omega^2}{\omega_0^2} \right|^{\frac{1}{2}}} \sigma} + \frac{1}{\sinh^2 \left( \frac{T_0 \ln^{-1} \left[ 1 - \frac{\omega^2}{\omega_0^2} \right]}{\left| 1 - \frac{\omega^2}{\omega_0^2} \right|^{\frac{1}{2}}} \tau \right)} \right) \left( \frac{dz}{d\tau} \right)^2 d\tau^2 - \\ &\left( e^{-\frac{T_0 \ln^{-1} \left[ 1 - \frac{\omega^2}{\omega_0^2} \right]}{\left| 1 - \frac{\omega^2}{\omega_0^2} \right|^{\frac{1}{2}}} \sigma} + \frac{1}{\cosh^2 \left( \frac{T_0 \ln^{-1} \left[ 1 - \frac{\omega^2}{\omega_0^2} \right]}{\left| 1 - \frac{\omega^2}{\omega_0^2} \right|^{\frac{1}{2}}} \tau \right)} \right) \left( \frac{dz}{d\sigma} \right)^2 d\sigma^2 + \\ &\frac{1}{\sinh \left( \frac{T_0 \ln^{-1} \left[ 1 - \frac{\omega^2}{\omega_0^2} \right]}{\left| 1 - \frac{\omega^2}{\omega_0^2} \right|^{\frac{1}{2}}} \tau \right) \cosh \left( \frac{T_0 \ln^{-1} \left[ 1 - \frac{\omega^2}{\omega_0^2} \right]}{\left| 1 - \frac{\omega^2}{\omega_0^2} \right|^{\frac{1}{2}}} \tau \right)} \left( \frac{dz}{d\tau} \frac{dz}{d\sigma} \right) d\tau d\sigma + \\ &\left( \frac{1}{\frac{T_0 \ln^{-1} \left[ 1 - \frac{\omega^2}{\omega_0^2} \right]}{\left| 1 - \frac{\omega^2}{\omega_0^2} \right|^{\frac{1}{2}}} e^{-\frac{T_0 \ln^{-1} \left[ 1 - \frac{\omega^2}{\omega_0^2} \right]}{\left| 1 - \frac{\omega^2}{\omega_0^2} \right|^{\frac{1}{2}}} \sigma} \cosh \left( \frac{T_0 \ln^{-1} \left[ 1 - \frac{\omega^2}{\omega_0^2} \right]}{\left| 1 - \frac{\omega^2}{\omega_0^2} \right|^{\frac{1}{2}}} \tau \right)} \right)^2 \times \\ &\left( d\theta^2 + \sin^2 \theta d\phi^2 \right) + \\ &\sum_{i=1}^5 dx_i^2 \end{aligned} \quad (11)$$

Above metrics correspond to thermal rotating neurons. These metrics depend on the temperature and rotating velocity of neurons. To obtain the spectrum of the rotating neuron, we should obtain the action. To this aim, we will use of the concept of Blon model for in [7]. For flat space-time, the action of a neuron is [9]:

$$\begin{aligned} S &= -T_{\text{tri}} \int d^3\sigma \sqrt{\eta^{ab} g_{MN} \partial_a X^M \partial_b X^N + 2\pi l_p^2 G(F)} \\ G &= \left( \sum_{n=1}^N \frac{1}{n!} \left( -\frac{F_{1..n} F_n}{\beta^2} \right) \right) \\ F_{\mu\nu} &= F_{\mu\nu} F^{\mu\nu} \quad F_{\mu\nu} = \partial_\mu A_\nu - \partial_\nu A_\mu \end{aligned} \quad (12)$$

where  $g_{MN}$  is the background metric,  $X^M$  ( $\sigma^a$ )'s are scalar fields,  $N$  is number of exchanged photons between Dendrite and axon,  $\sigma^a$ 's are the neuron coordinates,  $a, b = 0, 1, \dots, 3$  are world-volume indices of rotating neuron and  $M, N = 0, 1, \dots, 10$  are neuron dimensional spacetime indices. Also,  $G$  is the nonlinear field [9], and  $A$  is the photon which exchanges between Dendrite and axon. With the metric of equation (11), the action (12) should be re-written as:

$$\begin{aligned} S_{I, \text{end1}} &= - \int dt \int_{\sigma_0}^{\infty} d\sigma \left( e^{-\frac{T_0 \ln^{-1} \left[ 1 - \frac{\omega^2}{\omega_0^2} \right]}{\left| 1 - \frac{\omega^2}{\omega_0^2} \right|^{\frac{1}{2}}} \sigma} \cosh \left( \frac{T_0 \ln^{-1} \left[ 1 - \frac{\omega^2}{\omega_0^2} \right]}{\left| 1 - \frac{\omega^2}{\omega_0^2} \right|^{\frac{1}{2}}} \tau \right) \right)^2 \times \\ &\left( \sinh^2 \left( \frac{T_0 \ln^{-1} \left[ 1 - \frac{\omega^2}{\omega_0^2} \right]}{\left| 1 - \frac{\omega^2}{\omega_0^2} \right|^{\frac{1}{2}}} \tau \right) + \cosh^2 \left( \frac{T_0 \ln^{-1} \left[ 1 - \frac{\omega^2}{\omega_0^2} \right]}{\left| 1 - \frac{\omega^2}{\omega_0^2} \right|^{\frac{1}{2}}} \tau \right) \right) \times \\ &\left[ 1 + \frac{e^{-\frac{T_0 \ln^{-1} \left[ 1 - \frac{\omega^2}{\omega_0^2} \right]}{\left| 1 - \frac{\omega^2}{\omega_0^2} \right|^{\frac{1}{2}}} \sigma}}{\sinh^2 \left( \frac{T_0 \ln^{-1} \left[ 1 - \frac{\omega^2}{\omega_0^2} \right]}{\left| 1 - \frac{\omega^2}{\omega_0^2} \right|^{\frac{1}{2}}} \tau \right)} \left( \frac{dz}{d\tau} \right)^2 + \frac{e^{-\frac{T_0 \ln^{-1} \left[ 1 - \frac{\omega^2}{\omega_0^2} \right]}{\left| 1 - \frac{\omega^2}{\omega_0^2} \right|^{\frac{1}{2}}} \sigma}}{\cosh^2 \left( \frac{T_0 \ln^{-1} \left[ 1 - \frac{\omega^2}{\omega_0^2} \right]}{\left| 1 - \frac{\omega^2}{\omega_0^2} \right|^{\frac{1}{2}}} \tau \right)} \left( \frac{dz}{d\sigma} \right)^2 + \right. \\ &\left. \frac{e^{-\frac{T_0 \ln^{-1} \left[ 1 - \frac{\omega^2}{\omega_0^2} \right]}{\left| 1 - \frac{\omega^2}{\omega_0^2} \right|^{\frac{1}{2}}} \sigma}}{\sinh \left( \frac{T_0 \ln^{-1} \left[ 1 - \frac{\omega^2}{\omega_0^2} \right]}{\left| 1 - \frac{\omega^2}{\omega_0^2} \right|^{\frac{1}{2}}} \tau \right) \cosh \left( \frac{T_0 \ln^{-1} \left[ 1 - \frac{\omega^2}{\omega_0^2} \right]}{\left| 1 - \frac{\omega^2}{\omega_0^2} \right|^{\frac{1}{2}}} \tau \right)} \left( \frac{dz}{d\tau} \frac{dz}{d\sigma} \right) + (2\pi l_p^2 G(F)) \right]^{1/2} \end{aligned} \quad (13)$$

Using the method in ref [9], we can obtain the Hamiltonian from equation (13) for neuron:



Above equation indicates that all parameters of Izhikevich Neuron model could be produced in a Bio-Blon. Also, the exact form of these parameters and type of their dependency on frequency and temperature could be determined in a Bio-Blon.

Figure 2 shows the Membrane potential of Izhikevich Neuron model, which is produced in a Bio-Blon. This shape is very the same with results in [1], [2]. Neuron acts 13 like a Bio-Blon and transmits photons, Sodium and other charged particles which carry information.

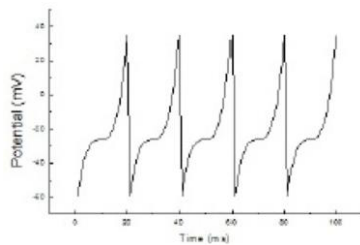


Figure 2: Membrane potential of Izhikevich Neuron model in a Bio-Blon

**Signal of Death in Izhikevich Neuron Model**

In this section, we will show that neurons can join to each other and produce a stable system. In these conditions, Hamiltonian of the system tends to a constant number, and no information is transferred. First, we rewrite equation (20) as:

$$\begin{aligned}
 H_{neuron} &= \int d\tau \int d^3\sigma \vartheta_{I,end1} = \int d\tau \int d^3\sigma Q(\tau, \sigma) O_{tot,1} \dots O_{tot,N} \\
 Q(\tau, \sigma) &= \left[ 1 + \frac{e^{-\frac{T_0 \ln^{-1} (1 - \frac{\sigma^2}{d^2})}}}{\sinh^2(\frac{T_0 \ln^{-1} (1 - \frac{\sigma^2}{d^2})}{\tau})} (V + \frac{dV}{d\tau})^2 + \frac{e^{-\frac{T_0 \ln^{-1} (1 - \frac{\sigma^2}{d^2})}}}{\cosh^2(\frac{T_0 \ln^{-1} (1 - \frac{\sigma^2}{d^2})}{\tau})} (U + \frac{dU}{d\tau})^2 \right. \\
 &\quad \left. + \frac{e^{-\frac{T_0 \ln^{-1} (1 - \frac{\sigma^2}{d^2})}}}{\sinh(\frac{T_0 \ln^{-1} (1 - \frac{\sigma^2}{d^2})}{\tau}) \cosh(\frac{T_0 \ln^{-1} (1 - \frac{\sigma^2}{d^2})}{\tau})} ((V + \frac{dV}{d\tau})(U + \frac{dU}{d\tau}))^{1/2} O_{tot,N} \right. \\
 O_{tot,N-1} &= \left[ 1 + \frac{k^2}{\frac{T_0 \ln^{-1} (1 - \frac{\sigma^2}{d^2})}{\sinh(\frac{T_0 \ln^{-1} (1 - \frac{\sigma^2}{d^2})}{\tau}) \cosh(\frac{T_0 \ln^{-1} (1 - \frac{\sigma^2}{d^2})}{\tau})}} \right]^{-1/2} \times \dots O_{tot,1} \\
 O_{tot,N-1} &\left( \frac{1}{\frac{T_0 \ln^{-1} (1 - \frac{\sigma^2}{d^2})}{\sinh(\frac{T_0 \ln^{-1} (1 - \frac{\sigma^2}{d^2})}{\tau}) \cosh(\frac{T_0 \ln^{-1} (1 - \frac{\sigma^2}{d^2})}{\tau})}} \right)^4 \\
 O_{tot,1} &= \left[ 1 + \frac{k^2}{\left( \frac{1}{\frac{T_0 \ln^{-1} (1 - \frac{\sigma^2}{d^2})}{\sinh(\frac{T_0 \ln^{-1} (1 - \frac{\sigma^2}{d^2})}{\tau}) \cosh(\frac{T_0 \ln^{-1} (1 - \frac{\sigma^2}{d^2})}{\tau})}} \right)^4} \right]^{-1/2} \quad (20)
 \end{aligned}$$

Some of the neurons oscillate reverse to some others and emit some photons with opposite momentums. We can sum over Hamiltonians of all neurons:

$$\begin{aligned}
 H_{System} &= [\sum_{m=1}^M H_{neuron,\tau,\sigma} + \sum_{n=1}^N H_{neuron,-\tau,-\sigma}] = \int d\tau \int d^3\sigma [\sum_{m=1}^M \vartheta_{I,end1,M} + \sum_{n=1}^N \vartheta_{I,end1,N}] = \\
 &\int d\tau \int d^3\sigma Q(\tau, \sigma) O_{tot,1} \dots O_{tot,N} + \int d\tau \int d^3\sigma \bar{Q}(\tau, \sigma) O_{tot,1} \dots O_{tot,N} = \\
 &\int d\tau \int \Sigma [dO_{tot,M} \lim_{K^2 \rightarrow 0} \frac{K^2}{K^2 + (O_{tot,M} - O_{tot,M}^-)^2}] = \int d\tau \int \Sigma [dO_{tot,M} \delta(O_{tot,M} - O_{tot,M}^-)] = 1 \quad (21)
 \end{aligned}$$

Above equation shows that Hamiltonian of the neuron system may be a constant number. In these conditions, this system is strongly stable, and there

isn't any equation of state. This means that information couldn't be transformed and thus, the system has been dead.

**Birds Without Brain In Izhikevich Neuron Model: Emergence Of Mind Out Of Brain**

Until now, we have considered some conditions that Hamiltonian of the total system tends to one. To prevent this state, we can remove some neurons of the system. For example, in a system which includes brain and spinal cord, we can remove neurons of the brain. As a result, equation (21) can be re-written as:

$$\begin{aligned}
 H_{System} &= H_{brain} + H_{spinalcord} = 1 \\
 \Rightarrow H_{spinalcord} &= 1 - H_{brain} \\
 H_{brain} &= [\sum_{m=1}^M H_{neuron,\tau,\sigma} \\
 H_{spinalcord} &= \sum_{n=1}^N H_{neuron,-\tau,-\sigma}] = \int d\tau \int d^3\sigma [\sum_{m=1}^M \vartheta_{I,end1,M} + \sum_{n=1}^N \vartheta_{I,end1,N}] \quad (22)
 \end{aligned}$$

Above equation shows that Hamiltonian of the spinal cord depends on the Hamiltonian of the brain. Thus, after cutting the brain, the spinal cord could do some activities of brain-like minding.

**Discussion**

In this research, we have shown that neurons in the Izhikevich Neuron model may join to each other, and the total Hamiltonian of the system tends to a constant number. For some exchanged waves, transferring of information between neurons is stopped, and the system of neuron acts as a dead system. These waves are known as the waves of death. Also, we have considered the 15 origins of these waves and Izhikevich Neuron model in a Bio-Bion system. This system was constructed from a page of Dendrite, a page of axon's terminals and a tube of Schwann cells, axon and Myelin Sheath that connects them. Evolutions of parameters of Izhikevich Neuron model like membrane capacitance, resting membrane potential and instantaneous threshold potential depend on temperature and frequency of Bio-Bion. Our calculations in Izhikevich Neuron model show that before death, a signal is emerged in the brain and suggest to all parts of bod to stop their activities. If we remove this signal, other parts of the body could continue to their activities. To show this in experiments, we cut the brain of some birds suddenly and observe that their other parts of bodies continue to activity for a long time and we hope that control their life for more times. Also, until now, scientists believed that by cutting the brain, the mind is disappeared. However, our calculations show that Hamiltonian of the spinal cord depends on the Hamiltonian of the brain. Thus, after cutting the brain, the spinal cord could do some activities of brain-like

minding. Also, our experiments show that birds without a brain can determine the best way to escape or passing barriers. This means that other neurons out of the brain have also a role in imaging.

## References

1. Izhikevich EM. Simple model of spiking neurons. IEEE Transactions on neural networks. 2003; 14(6):1569-72. <https://doi.org/10.1109/TNN.2003.820440> PMID:18244602
2. Izhikevich EM. Dynamical systems in neuroscience. MIT press; 2007. <https://doi.org/10.7551/mitpress/2526.001.0001> PMCid:PMC1487169
3. Nobukawa S, Nishimura H, Yamanishi T. Chaotic resonance in typical routes to chaos in the Izhikevich neuron model. Scientific reports. 2017; 7(1):1331. <https://doi.org/10.1038/s41598-017-01511-y> PMID:28465524 PMCid:PMC5430992
4. Haghiri S, Zahedi A, Naderi A, Ahmadi A. Multiplierless implementation of noisy Izhikevich neuron with low-cost digital design. IEEE transactions on biomedical circuits and systems. 2018; 12(6):1422-30. <https://doi.org/10.1109/TBCAS.2018.2868746> PMID:30188839
5. Vinaya M, Ignatius RP. Effect of Lévy noise on the networks of Izhikevich neurons. Nonlinear Dynamics. 2018; 94(2):1133-50. <https://doi.org/10.1007/s11071-018-4414-8>
6. Montakhab A, Khoshkhou M. Beta-rhythm oscillations and synchronization transition in network models of Izhikevich neurons: effect of topology and synaptic type. Frontiers in Computational Neuroscience. 2018; 12:59. <https://doi.org/10.3389/fncom.2018.00059> PMID:30154708 PMCid:PMC6103382
7. Sepehri A. The nano-Blon in nanostructure. Physics Letters A. 2016; 380(16):1401-7. <https://doi.org/10.1016/j.physleta.2016.02.026>
8. Montakhab A, Ghodrat M, Barati M. Statistical thermodynamics of a two-dimensional relativistic gas. Physical Review E. 2009; 79(3):031124. <https://doi.org/10.1103/PhysRevE.79.031124> PMID:19391919
9. Sepehri A, Shoorvazi S, Ghaforyan H. The European Physical Journal Plus. 2018; 133:280. <https://doi.org/10.1140/epjp/i2018-12127-6>
10. Ghodrat M, Montakhab A. Time parametrization and stationary distributions in a relativistic gas. Physical Review E. 2010; 82(1):011110. <https://doi.org/10.1103/PhysRevE.82.011110> PMID:20866568
11. Farias C, Pinto VA, Moya PS. What is the temperature of a moving body? Scientific reports. 2017; 7(1):17657. <https://doi.org/10.1038/s41598-017-17526-4> PMID:29247189 PMCid:PMC5732238
12. Beesham A, Sepehri A. Emergence and expansion of cosmic space in an accelerating Blon. The European Physical Journal C. 2018; 78(11):968. <https://doi.org/10.1140/epjc/s10052-018-6463-z>